

# Comparison of endoscopically determined gross tumor volume and metabolic tumor volume in esophageal cancer

Tae Hoon Lee, MD<sup>a</sup> , Hyun Gee Ryoo, MD<sup>b</sup> , Reeree Lee, MD<sup>c</sup> , Jin Chul Paeng, MD, PhD<sup>b</sup> , Hyunsoo Chung, MD, PhD<sup>d</sup> , Hak Jae Kim, MD, PhD<sup>a,e,f,\*</sup> 

## Abstract

The purpose of this study is to compare the longitudinal location of endoscopically-defined gross tumor volume (GTV) and positron emission tomography-based metabolic tumor volume (MTV) of esophageal cancer.

A retrospective review of medical records was performed of the nine patients who underwent endoscopic placement of fiducial markers for radiotherapy of esophageal squamous cell carcinoma. Endoscopic hemoclips were used as the fiducial markers, and GTV was newly delineated solely based on the locations of the fiducial markers. The standardized uptake value (SUV) threshold corresponding to the superior and inferior borders of GTV was defined as the highest threshold that made MTV reach each border of GTV.

The median fixed relative and absolute thresholds were 32% and 3.8, respectively. The coefficient of variation of the threshold values was 0.781 for the fixed relative threshold method and 0.400 for the fixed absolute threshold method, indicating more consistent results from the fixed absolute threshold method. All but two GTV borders were included in MTV with a SUV threshold of 2.5. Esophageal tumors with a maximum SUV > 20 tended to have closer threshold values corresponding to the GTV borders to 2.5 (median 2.8 vs 3.6,  $P = .069$ ).

The fixed absolute threshold method was suitable for determining the MTV threshold for esophageal lesions. A SUV of 2.5 was appropriate for esophageal tumors with a maximum SUV > 20. Endoscopic hemoclips were stable enough for using as the fiducial marker.

**Abbreviations:** CT = computed tomography, GTV = gross tumor volume, MTV = metabolic tumor volume, PET/CT = positron emission tomography/computed tomography, RT = radiotherapy, SUV = standardized uptake value.

**Keywords:** endoscopy, esophageal cancer, positron emission tomography scan, tumor volume

## 1. Introduction

Radiotherapy, often combined with chemotherapy, has an essential role as a definitive or neoadjuvant treatment in the

management of esophageal cancer.<sup>[1,2]</sup> After implementing conformal radiotherapy (RT), delineating an accurate target volume is an important stage of RT planning. There is no single definitive imaging modality to delineate precise gross tumor volume (GTV). As esophageal cancer can spread through the mucosa and submucosa, using a computed tomography (CT) scan alone to determine GTV of an esophageal tumor is challenging, particularly in the longitudinal direction, though a simulation CT scan is still essential for planning purposes. It is recommended that radiation oncologists incorporate information from multiple studies.<sup>[3]</sup>

Endoscopy is used to access esophageal tumors, and an endoscopic description of the location and the length of the tumor correlates well with the pathological tumor extension and clinical features, such as prognosis.<sup>[4]</sup> Translation of the endoscopic description to a simulation CT scan is not intuitive,<sup>[3]</sup> but the use of fiducial markers can be helpful in this process. Machiels et al showed that endoscopy-guided implantation of a fiducial marker reduces variation in the inter- and intra-observer GTV delineation.<sup>[5]</sup> The same group compared endoscopically defined tumor borders and pathological findings using fiducial markers, and concluded that they are well-correlated.<sup>[6]</sup> Although not a routine process, placing a fiducial marker can be very accurate to determine GTV for esophageal cancer RT planning, particularly for tumors with mucosal or submucosal spread.

<sup>18</sup>F-fluorodeoxyglucose positron emission tomography/computed tomography (PET/CT) is a recommended study for staging and target delineation purposes, and introducing PET/CT to GTV delineation decreases uncertainty, such as interobserver variability.<sup>[7]</sup> PET/CT has higher sensitivity and specificity for detecting

Editor: Shashank Hambarde.

This study was supported by a grant of the Korea Institute of Radiological and Medical Sciences (KIRAMS), funded by Ministry of Science and ICT (MSIT), Republic of Korea. (No. 50571-2021).

The authors have no conflicts of interest to disclose.

The datasets generated during and/or analyzed during the current study are available from the corresponding author on reasonable request.

<sup>a</sup> Department of Radiation Oncology, <sup>b</sup> Department of Nuclear Medicine, Seoul National University College of Medicine and Hospital, <sup>c</sup> Department of Nuclear Medicine, Chung-Ang University Hospital, <sup>d</sup> Department of Internal Medicine and Liver Research Institute, Seoul National University College of Medicine and Hospital, <sup>e</sup> Cancer Research Institute, Seoul National University, Seoul, <sup>f</sup> Institute of Radiation Medicine, Medical Research Center, Seoul National University, Seoul, Korea (Republic of).

\* Correspondence: Hak Jae Kim, Seoul National University College of Medicine, Seoul, Seoul Korea, Korea (Republic of) (e-mail: khjae@snu.ac.kr).

Copyright © 2021 the Author(s). Published by Wolters Kluwer Health, Inc. This is an open access article distributed under the terms of the Creative Commons Attribution-Non Commercial License 4.0 (CCBY-NC), where it is permissible to download, share, remix, transform, and buildup the work provided it is properly cited. The work cannot be used commercially without permission from the journal.

How to cite this article: Lee TH, Ryoo HG, Lee R, Paeng JC, Chung H, Kim HJ. Comparison of endoscopically determined gross tumor volume and metabolic tumor volume in esophageal cancer. *Medicine* 2021;100:24(e26338).

Received: 10 February 2021 / Received in final form: 19 May 2021 / Accepted: 24 May 2021

<http://dx.doi.org/10.1097/MD.00000000000026338>

regional or distant metastases, but an esophageal primary tumor is not always accessible by PET/CT, particularly when the tumor is small or superficial.<sup>[8]</sup> It can be problematic to determine the cranial and caudal borders of the GTV based on PET/CT, as the tumor can spread through the superficial layer of the esophageal wall and this superficial spread might not be detected by PET/CT. Considering that PET/CT is already widely used in diagnostic process and RT planning, deciding a specific method to interpretate PET/CT scan to GTV delineation would be useful. Furthermore, assuming that the fiducial markers are enough accurate to indicate superficial spread of esophageal tumors in simulation CT scan, comparing PET/CT scan and fiducial markers is applicable to determine such method. The purpose of this study is to compare the longitudinal location of the GTV of esophageal squamous cell carcinoma based on fiducial markers placed by endoscopy and metabolic tumor volume (MTV) based on hypermetabolic uptake on PET, and determine the optimal measures to delineate MTV using endoscopy-based GTV as a reference.

## 2. Methods

### 2.1. Study population

This study was approved by the Institutional Review Board of Seoul National University Hospital (IRB number 1912-137-1091) before collecting patient information. The medical records of 100 patients with esophageal squamous cell carcinoma who had undergone RT between 2018 and 2019 were retrospectively reviewed. Among them, 27 patients had fiducial markers placed via endoscopy. Eight patients were excluded because the endoscope could not be passed through the esophageal tumor due to narrowing of the lumen, so the fiducial markers were placed only in the proximal margin of the esophageal tumor and the longitudinal margin was not determined by endoscopy. Two patients did not undergo pre-RT PET, and six patients had no or minimal hypermetabolism in the primary esophageal tumor, so these patients were excluded. Two other patients were excluded as they had diffuse malignant lesions of the esophagus. After these exclusions, nine patients remained and were included in this study.

### 2.2. Fiducial marker placement

All patients underwent endoscopy to examine the esophageal lesions before treatment. Endoscopic procedures for placing the fiducial markers were performed separately from diagnostic (echo) endoscopy. Two patients underwent endoscopy with midazolam-based sedation. Endoscopic stainless steel hemoclips (EZ Clip, HX-610-090L, Olympus, Tokyo, Japan) with a 10-mm open width were used as the fiducial markers. At least one fiducial marker was placed in each superior and inferior border of the endoscopically visible esophageal lesion, with a 0.5 to 1.0 cm interval and the actual margins of the observed lesion. An experienced gastroenterologist performed the procedure, and explanations of the exact location of the fiducial markers relative to the esophageal tumor were written for each patient.

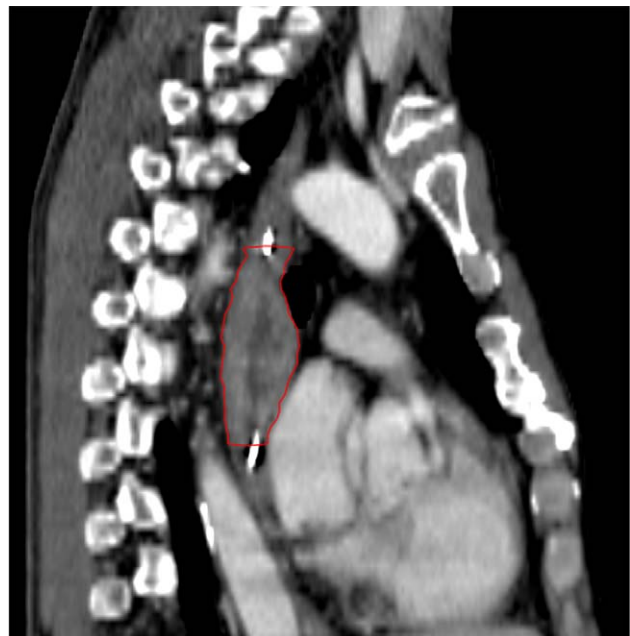
### 2.3. GTV delineation

A simulation CT scan was acquired after placing the fiducial markers on the same day, while maintaining nil per os before the CT scan, due to potential hemoclip displacement from food intake. Patients were positioned with both arms abducted over

their head and immobilized using a wing board. Patients with cervical or high upper thoracic esophageal lesions were immobilized in the supine position with IMRT Aquaplast to reduce RT set-up error. The thickness of the axial cut for the simulation CT scan was 3 mm. GTVs for this study were newly delineated by a contouring system (ARIA Oncology Information System 13.6, Varian Medical Systems, Palo Alto, CA) for each eligible patient based on the simulation CT scan, independently from the GTVs and other volumes used in the actual treatment. An experienced radiation oncologist delineated the GTVs based on the appearance of the radio-opaque fiducial markers on the simulation CT scans only. A fiducial marker often appeared in several axial cuts of the CT scan, and the fiducial marker was considered placed in the middle of these axial cuts. The cranial and caudal borders of GTV were determined based on the location of the fiducial markers and the gastroenterologist's description about the spatial relationship between the fiducial markers and mucosal spread of the esophageal tumor. After determining the cranial and caudal borders, the whole esophagus, which appeared in axial cuts between these borders, was included in the GTV. This is consistent with GTV delineation protocol of CALGB 80803 trial, which indicates the entire esophageal wall including any disease extension should be contoured as GTV.<sup>[9]</sup> Figure 1 illustrates the example of contoured esophageal GTV. Body contour was acquired using the Search Body function in the contouring software during RT planning, and this contour was used for fusing the simulation CT and PET images.

### 2.4. PET image acquisition

Patients fasted for at least 6 hours, and PET/CT was performed 1 hour after intravenous injection of <sup>18</sup>F-fluorodeoxyglucose (5.18 MBq/kg) using a dedicated PET/CT scanner (Biograph mCT40 or mCT64, Siemens Healthcare, Erlangen, Germany). A low-dose CT scan for attenuation correction and anatomical localization



**Figure 1.** The example of esophageal gross tumor volume based on endoscopic fiducial marker.

was acquired first, followed by acquisition of the PET images from the vertex to the proximal thigh (1 min/bed position). While acquiring images, patients were positioned with both arms abducted over their head, except for one patient who maintained supine position. The PET images were reconstructed using an iterative algorithm and displayed by fusing with the CT image.

### 2.5. Metabolic tumor volume and threshold corresponding to the GTV borders

GTV based on placement of the fiducial markers via endoscopy was transferred from the contouring system to the PET imaging system in the DICOM RTstruct format. The simulation CT scan and PET images were fused by contour-based alignment offered by the PET imaging system using the body contour acquired in the contouring system. For the purpose of determining the location of the primary esophageal tumor based on PET, MTV, which relies on hypermetabolism that appeared on the pre-RT PET of each patient, was delineated on the PET imaging system (MIM 6.1.7, MIM Software Inc., Beachwood, OH, USA). The threshold-based method was applied to delineate MTV. Figure 2 illustrates the example of MTV contouring. Both fixed relative and fixed absolute thresholds were used. The fixed relative threshold is defined as a certain percentage of the maximum standardized uptake value (SUV) of a tumor, while the fixed absolute threshold is defined as the absolute value of the SUV. To determine the thresholds corresponding to each end of the GTV, the highest threshold that could make MTV to reach the most superior or most inferior axial plane of the GTV on the CT scan was established. The highest threshold was found by changing the threshold of MTV by 1% for fixed relative threshold, and by 0.1 for fixed absolute threshold. Thus, two threshold values, each corresponding to the superior and inferior borders of the GTV were obtained for each patient and

each thresholding method. Threshold values by location were compared using the paired *t*-test.

The threshold values were verified to determine any correlations with other covariates, by linear regression when the covariate was continuous, and by the Kruskal–Wallis rank sum test when the covariate was categorical. The coefficient of variation, which is defined as standard deviation divided by the average, was calculated from the threshold values to compare the consistency of the different methods to obtain a threshold. All statistical analyses were performed using R 3.6.0 (The R Foundation for Statistical Computing, Vienna, Austria).

## 3. Results

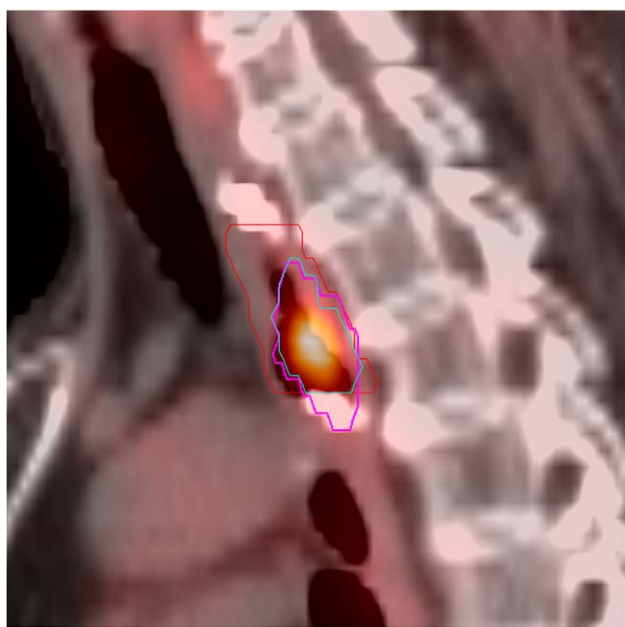
### 3.1. Patient characteristics

The characteristics of the nine patients included in this study are summarized in the left columns of Table 1. Seven patients were male and two were female. All but one patient was > 60 years. The range of T stages for the esophageal primary lesion was T1b to T3. Five patients had suspected or pathologically confirmed lymph node metastasis. The borders of the cervical and the upper, middle, and lower thoracic cancer were the thoracic inlet, the azygos vein, and the inferior pulmonary veins, respectively. Two patients had cervical esophageal lesions, three had upper thoracic, two had middle thoracic, and two had lower thoracic lesions. Three patients underwent the simulation CT scan in the supine position, due to the superior location of their esophageal lesions, as stated before. The range of endoscopically defined GTV was 0.9 to 8.0 cm, and the average was 4.7 cm. The range of maximum SUV from the PET scan for each patient was 7.1 to 28.6, and the average was 16.2.

### 3.2. Thresholds corresponding to the GTV borders

The thresholds corresponding to the superior and inferior GTV borders are summarized in the right columns of Table 1. The median threshold value for the fixed relative threshold method was 24% for the superior border, and 44% for the inferior border. The median threshold value of all threshold values was 32%. No significant difference was observed in the threshold values by location ( $P=.159$ ). The median threshold value using the fixed absolute threshold method was 3.3 for superior borders and 5.7 for inferior borders. The median threshold value of all threshold values was 3.8. No significant difference in the threshold value was observed by location ( $P=.061$ ). The distribution of the threshold values is summarized in Figure 3. The coefficient of variation was 0.781 for every threshold value from the fixed relative threshold method, and it was 0.400 for the fixed absolute threshold method. Thus, the fixed absolute threshold method showed more consistent results.

Several thresholds for delineating MTV for esophageal cancer have been suggested, and a fixed absolute threshold of SUV 2.5 is one of them.<sup>[10,11]</sup> All but two superior and inferior GTV borders were included by MTV with a SUV threshold of 2.5. Threshold values from the patients with a maximum SUV > 20 had a tendency to be closer to 2.5. The median threshold of patients with a maximum SUV > 20 was 2.8, while the median threshold of the others was 3.6. Nevertheless, no significant difference was observed between threshold values with a maximum SUV of 20 ( $P=.069$ ).



**Figure 2.** The example of delineation of metabolic tumor volume (MTV). Gross tumor volume based on endoscopic fiducial marker was delineated as the red line, and MTV with fixed relative threshold of 30% was contoured as the magenta line. The cyan line indicates the intersection of both volumes.

**Table 1**  
Patient characteristics and threshold corresponding to the gross tumor volume (GTV) borders.

Patient number	Sex	Age at diagnosis	T stage	LN metastasis	Disease location	Position at simulation CT	Longitudinal length of GTV (cm)	Maximum SUV	Fixed relative threshold method		Fixed absolute threshold method	
									Superior border	Inferior border	Superior border	Inferior border
1	M	52	T3	+	Middle thoracic	Arm abducted	7.5	26.5	10%	16%	2.8	4.6
2	F	69	T1b	-	Cervical	Supine <sup>†</sup>	3.0	10.6	27%	70%	2.9	7.4
3	M	74	T2	-	Upper thoracic	Supine	2.4	13.6	24%	53%	3.3	7.3
4	M	71	T1b	-	Upper thoracic	Arm abducted	3.0	6.5	59%	36%	3.8	2.4
5	M	67	T3	+	Lower thoracic	Arm abducted	8.1	13.0	51%	69%	6.7	9.0
6	M	74	T3	+	Middle thoracic	Arm abducted	7.2	28.6	13%	8%	3.7	2.5
7	M	80	T1b	-	Upper thoracic	Arm abducted	0.9	7.1	84%	80%	6.0	5.7
8	F	66	T2	+	Cervical	Supine	5.7	23.6	7%	11%	1.7	2.8
9	M	79	T3	+	Lower thoracic	Arm abducted	4.5	16.4	16%	44%	2.7	7.3

CT = computed tomography, GTV = gross tumor volume, LN = lymph node, SUV = standardized uptake value.

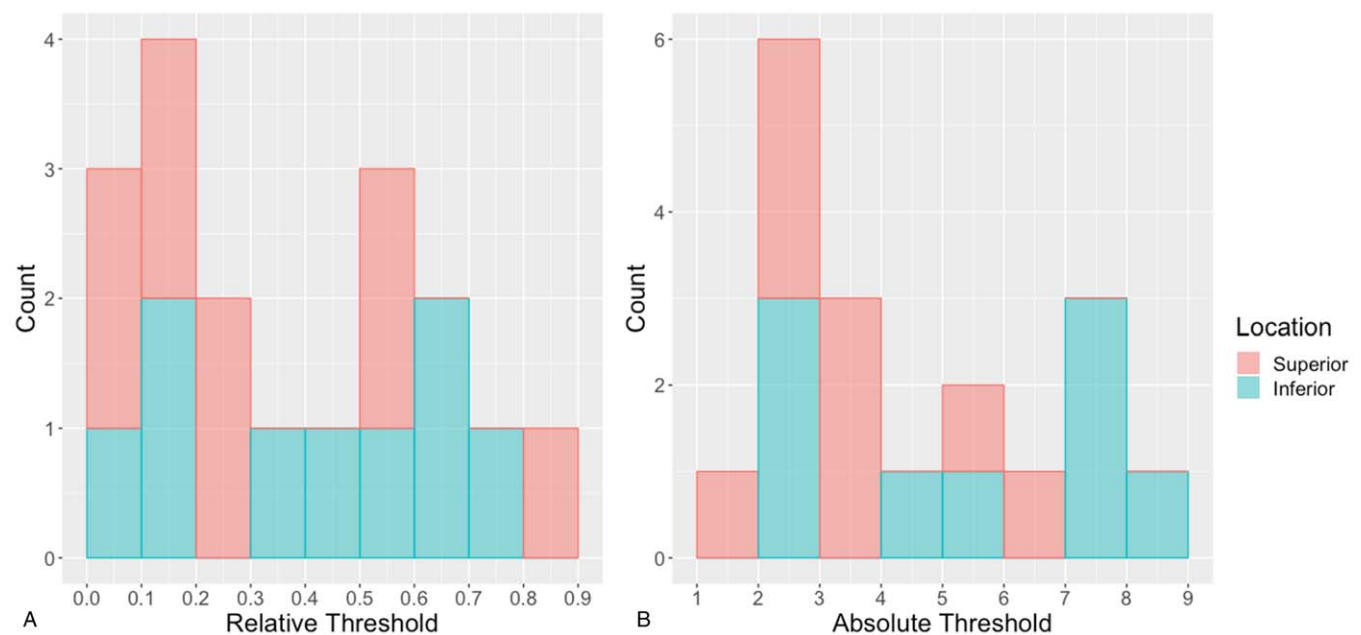
<sup>†</sup> The patients had a PET scan in the supine position

Linear regression was performed for the fixed relative and absolute thresholds to check the correlation between the threshold values and the continuous covariates, which were the longitudinal length of GTV and the maximum SUV. Figure 4 illustrates dot plots from these analyses, and a significant linear regression model was constructed for the fixed absolute thresholds and both continuous covariates. Significant differences in fixed relative thresholds were observed by T stage ( $P=.038$ ), lymph node positivity ( $P=.011$ ), and location of the tumor ( $P=.044$ ). No significant difference in the fixed absolute thresholds by these covariates were found.

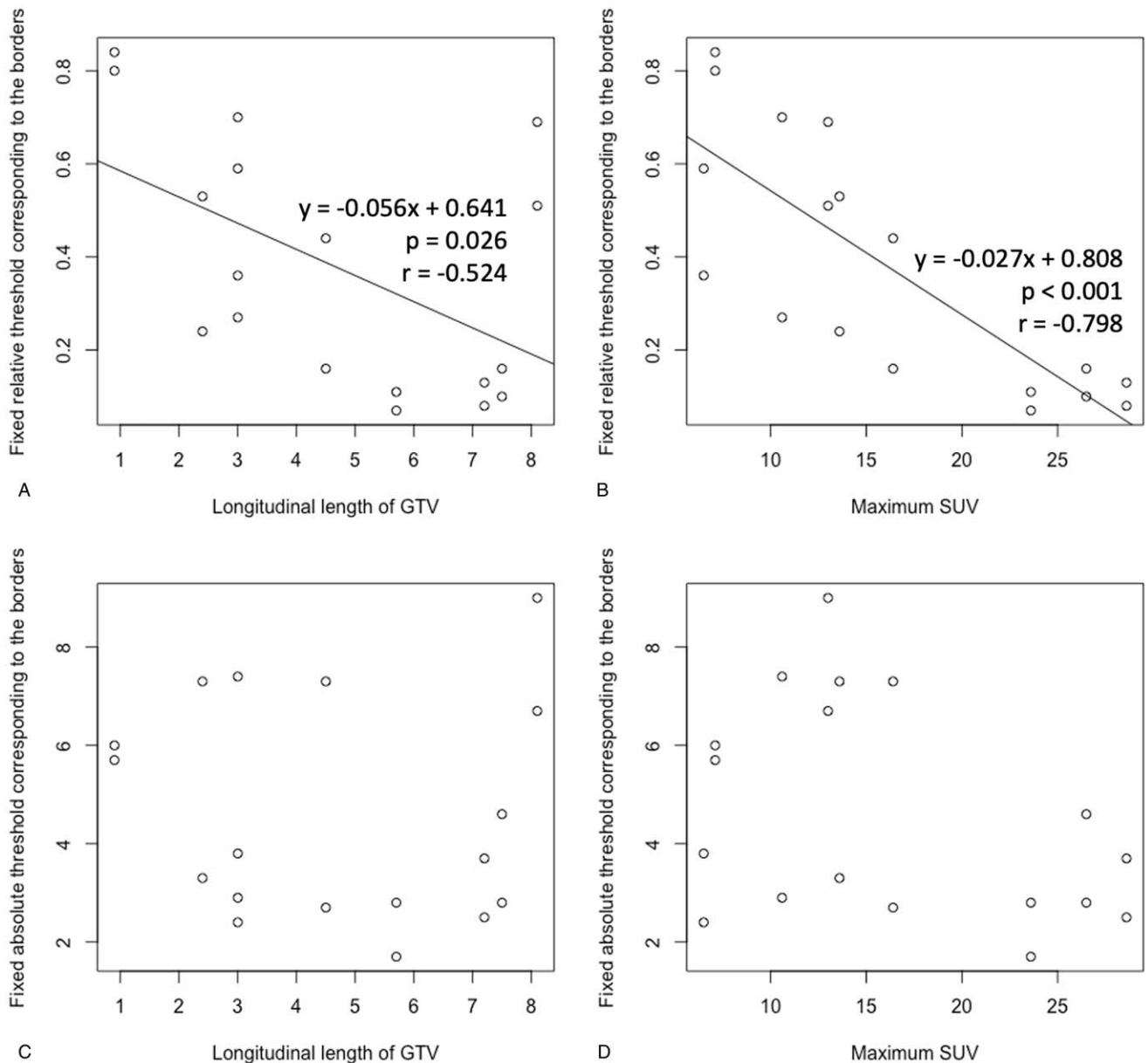
**4. Discussion**

PET/CT has been integrated into RT planning and utilized by many clinicians. As superficial tumors often cannot be detected by PET,<sup>[8]</sup> PET-based tumor borders may not be accurate if the

tumor tends to spread superficially. Konski et al compared the lengths of esophageal primary tumors measured by CT scan, PET, and endoscopic ultrasonography and found no significant difference between tumor lengths measured by PET and endoscopic ultrasonography, while tumor lengths measured by CT scan were significantly longer than those measured by PET.<sup>[10]</sup> This previous study revealed the superiority of implementing PET/CT to delineate GTV, but the analysis was only based on measured tumor length, and no actual geometric comparison of hypermetabolism appeared on PET/CT, which is different from the current study. Vali et al also compared CT/endoscopic ultrasound-based tumor volume and PET-based MTV of esophageal tumors,<sup>[11]</sup> but as previously stated, endoscopic description alone is often inaccurate to delineate exact boundary of the GTV. Furthermore, the study of Vali et al used 1-cm-long subsection of original GTV as reference to decide the best SUV thresholding method for approximation of radial



**Figure 3.** Histogram of (A) fixed relative threshold, (B) fixed absolute threshold corresponding to the gross tumor volume (GTV) borders.



**Figure 4.** Dot plot of (A) fixed relative thresholds corresponding to the gross tumor volume (GTV) borders and GTV longitudinal length, (B) fixed relative thresholds and the maximum standardized uptake value (SUV), (C) fixed absolute thresholds and longitudinal length of GTV, (D) fixed absolute thresholds and maximum SUV. A significant linear regression model was constructed in plots (A) and (B).

extent of esophageal GTV, while the present study concentrated in craniocaudal extent, which is more practically applicable.

The delineation of MTV has been studied primarily in lung cancer, and various segmentation methods and cut-off values for thresholds have been used.<sup>[12]</sup> An early study by Erdi et al showed that a fixed relative threshold of 36% to 44% was well-correlated with lung lesion volumes > 4 mL.<sup>[13]</sup> Also, Yu et al examined PET images and lobectomy specimens of 15 non-small-cell lung cancer patients, and proposed that a relative threshold of 31% and an absolute threshold of 3.0 would be appropriate to define the target volume.<sup>[14]</sup> Previous studies on esophageal cancer used similar absolute cut-off SUV values. Konski et al used a SUV of 2.5 to determine the extent of esophageal tumors by PET.<sup>[10]</sup> Vali et al proposed MTV with SUV threshold 2.5 would be best

approximates the CT-based GTV.<sup>[11]</sup> We propose that a fixed absolute threshold of SUV 2.5 is sufficient to set MTV, and this is consistent with other reports that proposed SUV thresholds of 2.5 to 3.0.<sup>[10,11,15]</sup> The current study also shows that not every lesion had a threshold corresponding to the borders close to a SUV of 2.5. This result is consistent with the report of Biehl et al which concluded that no single threshold could be determined to define lung lesion volume, compared with GTV based on a CT scan.<sup>[16]</sup> We propose that esophageal lesions with a maximum SUV > 20 are more suitable for MTV with a threshold SUV of 2.5. More studies are needed to suggest a feasible threshold for every esophageal tumor.

Endoscopy is widely accepted as useful tool to access esophageal tumors, particularly those with superficial spread.

Previous studies have shown that placing fiducial markers can be very helpful to interpret endoscopic findings for volume delineation.<sup>[5,6]</sup> In this present study, GTV was delineated solely based on the location of fiducial markers appearing on the simulation CT scan, and various MTV delineation methods were compared with this endoscopically defined GTV. These methods are based on the assumption that a fiducial marker placed by endoscopy accurately reflects mucosal spread of an esophageal tumor, as the above-mentioned study stated. Geometric differences in MTV and GTV were analyzed using fiducial markers, and the result showed discordance between GTV based on the endoscopic fiducial markers and MTV in some patients.

Contrary to previous studies from other groups, endoscopic hemoclips, which are used for hemostasis, were used as fiducial markers in the present study. Hemoclips are useful as fiducial markers because they are readily available in many medical centers. When the simulation CT scan was conducted after placing the hemoclips while maintaining nil per os, the hemoclips were stable enough to locate the esophageal tumors on the simulation CT scan. As most gastroenterologists are familiar with hemoclips, we expect that this procedure could be accurately performed to locate esophageal tumors. Nevertheless, hemoclips were not stable enough for the pathologic examination, as no hemoclip was left in a surgical specimen in the present study, contrary to dedicated fiducial markers.<sup>[17]</sup>

The present study had some limitations. This study was conducted retrospectively and PET/CT scans were not intended to be fused with a simulation CT scan. Therefore, geographic differences existed between PET scan and simulation CT scan and could have influenced the analyses. The longitudinal resolution of the simulation CT scan was too low to have sufficient accuracy for the longitudinal length comparisons. Furthermore, the hemoclips as fiducial markers on the CT scan usually appeared on three or four axial planes with an axial cut thickness of 3.0 mm, and this could have affected the accuracy of GTV delineation based on the fiducial markers. The patients in this study might be less representative due to the small number of patients. Based on this preliminary data, further research will be proceed when sufficient number of the patients are recruited. The suggested SUV threshold may need to be re-evaluated by each PET scanner as SUV values would not be same. Nevertheless, this study hypothesized that integrating the placement of endoscopic fiducial markers was helpful to delineate esophageal GTV.

In conclusion, the fixed absolute threshold method resulted in more consistent threshold values than the fixed relative threshold method, and the fixed relative threshold method tended to be more influenced by other properties of the tumor. A SUV of 2.5, which was validated in previous studies, allowed the MTV to include all but two borders of the GTV, but thresholds corresponding to the GTV borders tended to be higher for esophageal tumors with maximum SUVs < 20. We proposed that a SUV of 2.5 is more suitable for esophageal lesions with a maximum SUV of 20. Endoscopic hemoclips were stable enough for using as the fiducial marker. Additional studies with a larger patient population and various other MTV delineation methods are warranted.

### Author contributions

**Conceptualization:** Jin Chul Paeng, Hyunsoo Chung, Hak Jae Kim.

**Data curation:** Tae Hoon Lee.

**Formal analysis:** Tae Hoon Lee.

**Investigation:** Tae Hoon Lee, Hyun Gee Ryoo, Reeree Lee.

**Methodology:** Tae Hoon Lee, Hyun Gee Ryoo, Reeree Lee, Jin Chul Paeng, Hyunsoo Chung, Hak Jae Kim.

**Project administration:** Hak Jae Kim.

**Resources:** Jin Chul Paeng, Hyunsoo Chung, Hak Jae Kim.

**Supervision:** Hak Jae Kim.

**Writing – original draft:** Tae Hoon Lee, Hyun Gee Ryoo.

**Writing – review & editing:** Tae Hoon Lee.

### References

- [1] Stahl M, Walz MK, Stuschke M, et al. Phase III comparison of preoperative chemotherapy compared with chemoradiotherapy in patients with locally advanced adenocarcinoma of the esophagogastric junction. *J Clin Oncol* 2009;27:851–6.
- [2] Shapiro J, van Lanschot JJB, Hulshof MCCM, et al. Neoadjuvant chemoradiotherapy plus surgery versus surgery alone for oesophageal or junctional cancer (CROSS): long-term results of a randomised controlled trial. *Lancet Oncol* 2015;16:1090–8.
- [3] Hazard L, Yang G, McAleer MF, Hayman J, Willett C. Principles and techniques of radiation therapy for esophageal and gastroesophageal junction cancers. *J Natl Compr Cancer Netw* 2008;6:870–8.
- [4] Wang BY, Liu CY, Lin CH, et al. Endoscopic tumor length is an independent prognostic factor in esophageal squamous cell carcinoma. *Ann Surg Oncol* 2012;19:2149–58.
- [5] Machiels M, Jin P, van Hooft JE, et al. Reduced inter-observer and intra-observer delineation variation in esophageal cancer radiotherapy by use of fiducial markers. *Acta Oncol* 2019;58:943–50.
- [6] Machiels M, Van Montfoort ML, Thuijs NB, et al. Microscopic tumor spread beyond (echo)endoscopically determined tumor borders in esophageal cancer. *Radiat Oncol* 2019;14:1–8.
- [7] Vesprini D, Ung Y, Dinniwell R, et al. Improving Observer Variability in Target Delineation for Gastro-oesophageal Cancer—the Role of 18Ffluoro-2-deoxy-D-glucose Positron Emission Tomography/Computed Tomography. *Clin Oncol* 2008;20:631–8.
- [8] Kato H, Kuwano H, Nakajima M, et al. Comparison between positron emission tomography and computed tomography in the use of the assessment of esophageal carcinoma. *Cancer* 2002;94:921–8.
- [9] Wu AJ, Bosch WR, Chang DT, et al. Expert consensus contouring guidelines for intensity modulated radiation therapy in esophageal and gastroesophageal junction cancer. *Int J Radiat Oncol Biol Phys* 2015;92:911–20.
- [10] Konski A, Doss M, Milestone B, et al. The integration of 18-fluoro-deoxy-glucose positron emission tomography and endoscopic ultrasound in the treatment-planning process for esophageal carcinoma. *Int J Radiat Oncol Biol Phys* 2005;61:1123–8.
- [11] Vali FS, Nagda S, Hall W, et al. Comparison of standardized uptake value-based positron emission tomography and computed tomography target volumes in esophageal cancer patients undergoing radiotherapy. *Int J Radiat Oncol Biol Phys* 2010;78:1057–63.
- [12] Im HJ, Bradshaw T, Solaiyappan M, et al. Current methods to define metabolic tumor volume in positron emission tomography: which one is better? *Nucl Med Mol Imaging* 2018;52:5–15.
- [13] Erdi YE, Mawlawi O, Larson SM, et al. Segmentation of lung lesion volume by adaptive positron emission tomography image thresholding. *Cancer* 1997;80:2505–9.
- [14] Yu J, Li X, Xing L, et al. Comparison of tumor volumes as determined by pathologic examination and FDG-PET/CT images of non-small-cell lung cancer: a pilot study. *Int J Radiat Oncol Biol Phys* 2009;75:1468–74.
- [15] Paulino AC, Johnstone PAS. FDG-PET in radiotherapy treatment planning: Pandora's box? *Int J Radiat Oncol Biol Phys* 2004;59:4–5.
- [16] Biehl KJ, Kong FM, Dehdashti F, et al. 18F-FDG PET definition of gross tumor volume for radiotherapy of non-small cell lung cancer: is a single standardized uptake value threshold approach appropriate? *J Nucl Med* 2006;47:1808–12.
- [17] Fernandez DC, Hoffe SE, Barthel JS, et al. Stability of endoscopic ultrasound-guided fiducial marker placement for esophageal cancer target delineation and image-guided radiation therapy. *Pract Radiat Oncol* 2013;3:32–9.