

Case report

# Encephalocraniocutaneous lipomatosis (Fishman syndrome): A rare neurocutaneous syndrome

Mohammad Sharifi\*, Maral Namdari

Eye Research Center, Mashhad University of Medical Sciences, Mashhad, Iran

Received 11 May 2016; accepted 12 June 2016

Available online 15 July 2016

## Abstract

**Purpose:** To report a rare case of encephalocraniocutaneous lipomatosis (ECCL) presented with characteristic multiple organ involvement.

**Methods:** A 7-day-old white Iranian girl was referred with ocular, skin and brain abnormalities.

**Results:** The findings of nevus psiloliparus, eyelid choristoma and intracranial lipoma were consistent with ECCL.

**Conclusion:** Since the skin and ocular manifestations can be easily observed at birth examination, pediatricians and ophthalmologists should be aware of this condition.

Copyright © 2016, Iranian Society of Ophthalmology. Production and hosting by Elsevier B.V. This is an open access article under the CC BY-NC-ND license (<http://creativecommons.org/licenses/by-nc-nd/4.0/>).

**Keywords:** Choristoma; Encephalocraniocutaneous lipomatosis; Neurocutaneous; Nevus psiloliparus

## Introduction

Encephalocraniocutaneous lipomatosis (ECCL), also known as Fishman syndrome, is a rare congenital neurocutaneous disease that commonly involves ectomesodermal tissues, such as eye, skin, and central nervous system.<sup>1,2</sup> Nevus psiloliparus (NP), a rare skin anomaly characterized by alopecia and an excessive amount of fat tissue is the hallmark of ECCL.<sup>2</sup> Eyelid choristoma is the predominant ocular feature, while intracranial lipoma is the major central nervous system (CNS) manifestation. We present a 7-day-old girl with ocular, skin, and CNS malformations consistent with ECCL.

## Case report

A 7-day-old white Iranian girl was referred to the oculoplasty clinic for ophthalmic evaluation. She was a full-term

infant from healthy, non-consanguineous parents after an uncomplicated pregnancy. She was born with cesarean-section (C/S) due to previous C/S. Family history was negative. General physical examination showed a length of 49 cm, weight of 3.2 kg and head circumference of 35 cm, which were in normal ranges. Routine laboratory examinations in pregnancy were normal. Maternal screening tests for trisomy 13, trisomy 18, and Down Syndrome were negative. Ophthalmic examination showed multiple skin-colored papules and pedunculated lesions located on her right and left eyelids, and lateral canthus, right upper eyelid coloboma, right bulbar conjunctival hypertrophy, right limbal dermoid, corneal haziness and corneal peripheral vascularization extending from 2 to 6 o'clock in the left eye (Fig. 1).

Fundus examination of the right eye was not possible due to corneal opacity, but left fundus showed a peripapillary hypopigmented creamy-white irregular choroidal lesion (6–7 disc diameters). Optic disc and peripheral retina were normal (Fig. 2). Ultrasonographic scan showed high intensity echo spikes and highly reflective choroidal mass with posterior acoustic shadowing in favor of posterior globe calcification (Fig. 3).

\* Corresponding author.

E-mail address: [sharifim@mums.ac.ir](mailto:sharifim@mums.ac.ir) (M. Sharifi).

Peer review under responsibility of the Iranian Society of Ophthalmology.

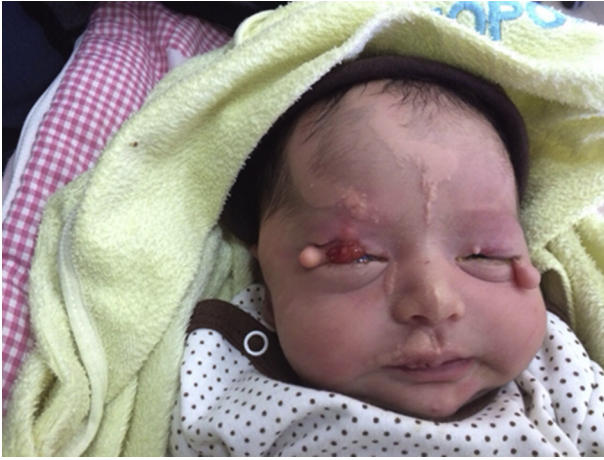

Fig. 1. Ocular and dermal findings include: right upper lid coloboma, multiple soft skin-colored pedunculated periocular lesions, bulbar conjunctiva hypertrophy, corneal clouding and right limbal dermoid and soft, elevated, area of patchy hair loss in the frontotemporal region (nevus psiloliparus).

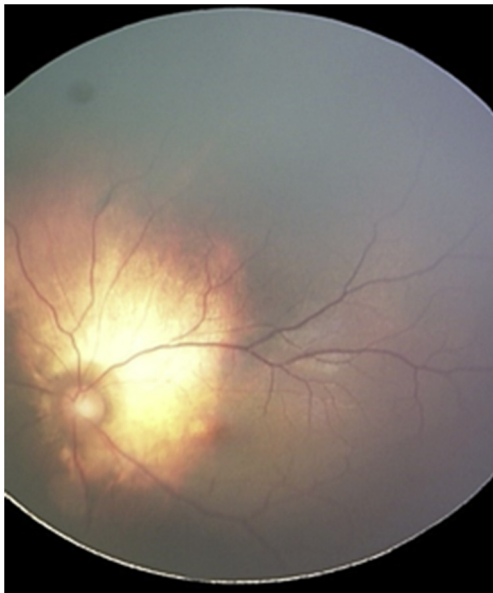


Fig. 2. Left fundus Retcam showing peripapillary hypopigmented creamy-white irregular choroidal lesion with normal optic disc and peripheral retina.

Dermatological examination showed a soft, elevated area of patchy hair loss on the right scalp extending to the forehead without signs of inflammation or scarring, clinically compatible with NP (Fig. 1).

Routine laboratory examination including complete blood count, erythrocyte sedimentation rate, and C-reactive protein were normal. TORCH screening serology tests were negative. Axial non-contrast computed tomography (CT) scanning of the brain and orbit revealed fat density lesions in subcutaneous tissues of the right temporal region and ipsilateral suprasellar, and cerebellopontine angle hypodense lesion suggestive of lipomas. Focal calcifications were seen in the posterior globe of both eyes as well as extraconal area of the right eye. Eye-balls seemed normal in size (Fig. 4).

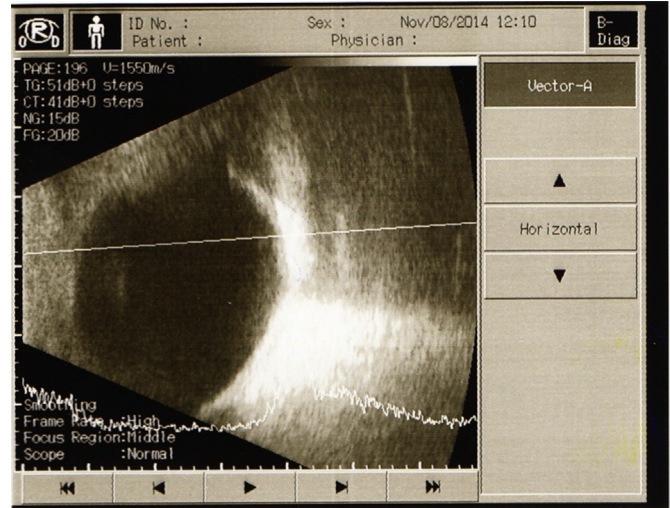


Fig. 3. Ultrasound of both eyes showed A scan with high intensity echo spikes and highly reflective choroidal mass with posterior acoustic shadowing in favor of posterior globe calcification.

Echocardiography revealed a patent foramen ovale. The constellation of these clinical and imaging findings led to a diagnosis of ECCL.

**Discussion**

The ECCL or Fishman syndrome is presented with congenital skin, eye and brain lesions. The etiology is most likely due to dysgenesis of the anterior neural tube and cephalic neural crest.<sup>3</sup> All reported cases of ECCL are sporadic. A nonhereditary, autosomal mutation that may survive only in a mosaic state may be a cause of the clinical picture of ECCL.<sup>4</sup> The first description of this syndrome as ‘Encephalocranio-cutaneous lipomatosis’ was by Haberland and Perou in 1970.<sup>5</sup> Afterwards, Fishman *et al*<sup>6</sup> in 1987 reported more cases of ECCL. In a literature search on PubMed database, 77 patients with Fishman syndrome were found (accessed on September 2013). There is no clear gender, racial, or geographical predilection. The diagnosis of ECCL is mainly based on history, clinical examination, and imaging studies. MacLaren *et al* in 1995 and Hunter in 2006<sup>7</sup> have laid down diagnostic criteria, but Moog in 2009 proposed revised diagnostic criteria for ECCL.<sup>8</sup> Table 1 shows Moog's revised criteria for diagnosis of ECCL.

Ocular lesions are always present and consist of conjunctival choristoma, with or without associated anterior chamber anomalies.<sup>7</sup> Persistent hyaloid vessels, lens dislocation, iris dysplasia, aniridia, colobomas, microphthalmia, ocular calcifications, and optic disc pallor have also been reported.<sup>9,10</sup> The most characteristic scalp lesion in ECCL is NP, a soft, subcutaneous mass with demarcated area of alopecia. Dermal lesions in the face are multiple papular or polypoid nodules. Histologically, facial and scalp lesions are hamartomas and choristomas. These lesions are unilateral in most cases, but they can be bilateral.<sup>8</sup> Brain abnormalities include cerebral and spinal lipomas, intracranial calcifications, abnormal

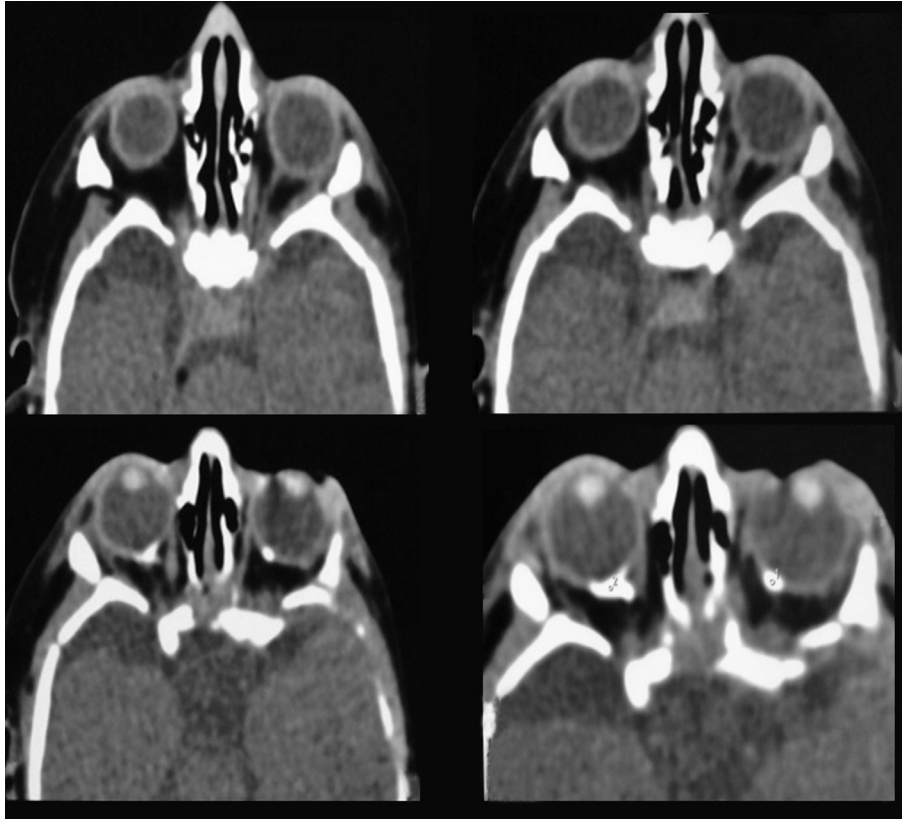


Fig. 4. Axial non-contrast CT scan of brain and orbit shows fat density lesions in subcutaneous tissues of right temporal region, Ipsilateral suprasellar, and cerebellopontine angle hypodense lesion suggestive of lipomas. Focal calcifications are seen in posterior globe of both eyes.

Table 1  
Criteria for diagnosis of Fishman syndrome.

Eye	Skin	Central nervous system	Other
<i>Major criteria</i> Choristoma, with or without associated anomalies	<i>Major criteria</i> Proven nevus psiloliparus (NP)	<i>Major criteria</i> Intracranial lipoma	<i>Major criteria</i> Jaw tumor (osteoma, odontoma, or ossifying fibroma) Multiple bone cysts
<i>Minor criteria</i> Corneal and other anterior chamber anomalies Ocular or eyelid coloboma	Possible NP and >1 of minor criteria 2–5 >2 of minor criteria 2–5 <i>Minor criteria</i> Possible NP	Intraspinal lipoma  >2 of minor criteria <i>Minor criteria</i> Abnormal intracranial vessels (eg, angioma, excessive vessels) Arachnoid cyst or other abnormality of meninges	Aortic coarctation
Calcification of globe	Patchy or streaky nonscarring alopecia (without fatty nevus) Subcutaneous lipoma(s) in frontotemporal region Focal skin aplasia/hypoplasia on scalp Small nodular skin tags on eyelids or between outer and tragus canthus	Complete or partial atrophy of a hemisphere Porencephalic cyst(s) Asymmetrically dilated ventricles or hydrocephalus Calcification (not basal ganglia)	

NP: Nevus Psiloliparus.

intracranial vessels, ventricular and subarachnoid enlargement, agenesis of the corpus callosum, intracranial cysts, cortical dysplasia, and brain atrophy.<sup>7,8,10</sup> There is no clinical correlation between the clinical manifestations of ECCL and severity of brain malformations.

Differential diagnosis with other neuroectodermal syndromes such as oculocerebrocutaneous syndrome (OCCS or

Delleman syndrome), focal dermal dysplasia, (or Goltz syndrome), sebaceous nevus syndrome (epidermal nevus syndrome), oculo-auriculo-vertebral syndrome (Goldenhar syndrome) should be considered.

In OCCS syndrome, typical crescent-shaped supra auricular skin hypoplasia are present. Brain malformations are not rare and often show a consistent pattern of forebrain anomalies and

a very characteristic mid-hindbrain anomaly, both of which are unknown in ECCL or any other syndrome.<sup>8</sup>

In Goltz syndrome, brain anomalies are rare and much less frequent than in ECCL, OCCS, or sebaceous nevus syndrome.<sup>11</sup> Sebaceous nevus syndrome is a mosaic condition with various linear nevi, Epilepsy, and mental retardation. These nevi are composed of hyperplastic sebaceous glands, atypical apocrine glands, and immature hair follicles.

In Goldenhar syndrome, epibulbar choristomas are characteristic features, but in this syndrome, there is a variety of abnormalities including preauricular appendages, hemifacial microsomia, and vertebral, digital, urogenital, or heart anomalies not present in ECCL. In contrast, lesions in ECCL are usually static and limited to the head.

The treatment of ocular lesions includes the excision of the conjunctival tumors and lamellar or penetrating keratoplasties.<sup>12</sup> Large cutaneous lesions may require surgical treatment. ECCL patients may have a normal development or be severely retarded.<sup>8</sup>

In conclusion, this is the first case of Fishman syndrome in the Iranian population who presented with characteristic multiple organ involvement. Since the skin and ocular manifestations are always present in ECCL and can easily be observed at birth examination, pediatricians and ophthalmologists should be aware of this condition. Neuroimaging studies must be carried out in all patients suggestive for ECCL to rule out brain abnormalities. Parents should be reassured that this genetic syndrome will not be transmitted to the offspring.

---

#### Application of the criteria to the diagnosis of encephalocraniocutaneous lipomatosis

##### Definite case

Three systems involved (major criteria) or

Three systems involved, proven Nevus psiloliparus (NP) or possible NP + > 1 of minor skin criteria

Two systems involved with major criteria, one of which is proven NP or possible NP > 1 of minor skin criteria

##### Probable case

Two systems involved, major criteria in both

Two systems involved, proven or possible NP

---

## References

1. Thakur S, Thakur V, Sood RG, Thakur CS, Khanna S. Encephalocraniocutaneous lipomatosis with calvarial exostosis: case report and review of literature. *Indian J Radiol Imag.* 2013;23:333–336.
2. Kim D, Park S, Lee Y, Im M, Choi S, Lee J. Encephalocraniocutaneous lipomatosis without neurologic anomalies. *Ann Dermatol.* 2012;24:476–478.
3. Gokhale NR, Mahajan PM, Belgaumkar VA, Pradhan SN, Uttarwar NS. Encephalocraniocutaneous lipomatosis: a rare neurocutaneous syndrome. *Indian J Dermatol Venereol Leprol.* 2007;73:40–42.
4. Jozwiak S, Elstone D. Heberland syndrome clinical presentation in: e-medicine.medscape.com/117060-overview
5. Haberland C, Perou M. Encephalocraniocutaneous lipomatosis: a new example of ectomesodermal dysgenesis. *Arch Neurol.* 1970;22:144–155.
6. Fishman MA, Chang CS, Miller JE. Encephalocraniocutaneous lipomatosis. *Pediatrics.* 1978;61:580–582.
7. Hunter AG. Oculocerebrocutaneous and encephalocraniocutaneous lipomatosis syndromes: blind men and an elephant or separate syndromes? *Am J Med Genet A.* 2006;140:709–726.
8. Moog U. Encephalocraniocutaneous lipomatosis. *J Med Genet.* 2009;46:721–729.
9. Amor D, Kornberg A, Smith L. Encephalocraniocutaneous lipomatosis (Fishman syndrome): a rare neurocutaneous syndrome. *J Paediatr Child Health.* 2000 Dec;36:603–605.
10. Donaire A, Carreno M, Bargalló N, et al. Presurgical evaluation and cognitive functional reorganization in Fishman syndrome. *Epilepsy Behav.* 2005 May;6:440–443.
11. Gokhale N, Mahajan P, Belgaumkar V, Pradhan SN, Uttarwar NS. Encephalocraniocutaneous lipomatosis: a rare neurocutaneous syndrome. *Indian J Dermatol Venereol Leprol.* 2007;73:40–42.
12. Kalyan K, Vijayalakshmi B, Srinivas D, Ramanareddy G. Encephalocraniocutaneous lipomatosis (Haberland syndrome): a case report and review of literature. *Indian J Dermatol.* 2013;58:232–234.