

Repigmentation of vitiligo-associated eyelash leukotrichia with topical tofacitinib



Sa Rang Kim, MD,^a and Brittany G. Craiglow, MD^{a,b}
New Haven and Fairfield, Connecticut

Key words: JAK inhibitor; Janus kinase; leukotrichia; pediatric; therapy; tofacitinib; topical; treatment; vitiligo.

INTRODUCTION

Vitiligo is an autoimmune disorder that is characterized by depigmented patches. The presence of vitiligo-associated leukotrichia represents the exhaustion of melanocyte reservoir and is associated with poor response to medical treatments.¹ In such cases, surgical modalities such as follicular unit extraction and transplantation may be an option² but are rarely used, especially in pediatric patients. However, recent studies have demonstrated that Janus kinase (JAK) inhibitors, such as tofacitinib, may be an effective therapy for vitiligo, and the response is enhanced by concurrent phototherapy.³ Herein, we present a case of vitiligo-associated leukotrichia that showed near-complete repigmentation with topical tofacitinib in a pediatric patient.

CASE REPORT

A 17-year-old girl with no prior medical history presented with a 4-month history of vitiligo. The examination was notable for depigmented patches on the bilateral upper eyelids with associated leukotrichia involving approximately 10% of the right and 70% of the left upper eyelashes (Fig 1, A). There was no family history of autoimmune disorders. However, she had used tacrolimus 0.1% ointment for 6 weeks without improvement and had experienced a mild but persistent burning sensation with the application.

Given the recent evidence supporting the efficacy of JAK inhibitors in vitiligo, the patient was started on tofacitinib 2% cream twice daily to the eyelids. After 2 months of treatment, partial repigmentation of the bilateral upper eyelids and eyelashes was evident (Fig 1, B), and after 5 months, the bilateral eyelashes

Abbreviation used:

JAK: Janus kinase

showed near-complete repigmentation (Fig 1, C). The patient tolerated tofacitinib cream without adverse effects. The patient did not have concurrent phototherapy, though notably, treatment occurred during the summer and fall.

DISCUSSION

Traditional therapies for vitiligo, including topical corticosteroids, calcineurin inhibitors, and narrowband ultraviolet B phototherapy are often inadequate. JAK inhibitors suppress interferon γ signaling in the skin,³ which is implicated in the pathogenesis of vitiligo, and have recently emerged as a promising targeted therapy.³⁻⁶

In vitiligo, the hair follicle bulge stem cells are thought to be the source of melanocytes for skin repigmentation.^{1,3} Therefore, it is not surprising that vitiligo-associated leukotrichia is associated with poor response to medical treatments.¹ In a study of 2 patients with vitiligo-associated leukotrichia, white hair follicles had fewer melanocytes than black hair follicles and had no tyrosinase-positive melanocytes.⁷ In another study, melanocytes were absent in all of the white hairs from vitiligo lesions.⁸ Surgical modalities are thought to lead to improvement by replenishing absent or deficient melanocyte reservoirs in hair follicles.^{1,2} In our patient, there was near-complete repigmentation of her eyelashes with topical tofacitinib. This may indicate either the presence of melanocytes in white

From the Department of Dermatology, Yale School of Medicine, New Haven,^a and Dermatology Physicians of Connecticut, Fairfield.^b

Funding sources: None.

IRB approval status: Not applicable.

Correspondence to: Brittany G. Craiglow, MD, Department of Dermatology, Yale University School of Medicine, PO Box 208059, New Haven, CT 06520. E-mail: brittany.craiglow@yale.edu.

JAAD Case Reports 2021;16:90-1.
2352-5126

© 2021 by the American Academy of Dermatology, Inc. Published by Elsevier, Inc. This is an open access article under the CC BY-NC-ND license (<http://creativecommons.org/licenses/by-nc-nd/4.0/>).

<https://doi.org/10.1016/j.jdc.2021.07.021>

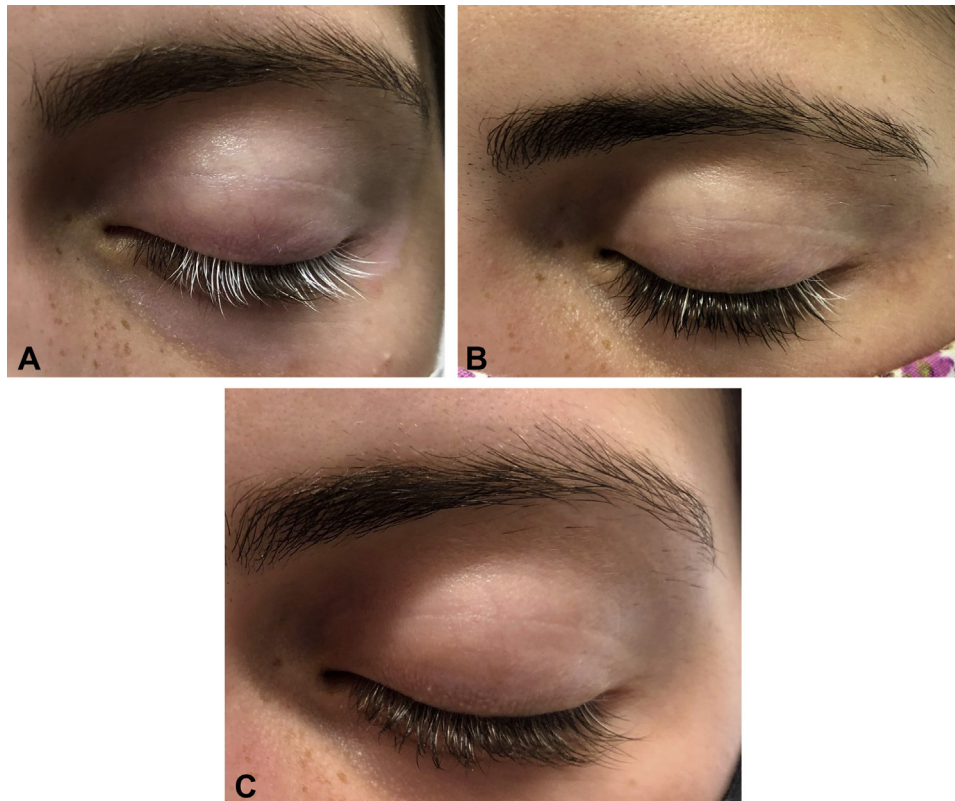


Fig 1. Vitiligo-associated eyelash leukotrichia treated with tofacitinib 2% cream. **A**, Before treatment with topical tofacitinib, leukotrichia involved approximately 70% of the left upper eyelashes. **B**, After 2 months of tofacitinib, there was partial repigmentation of the eyelashes. **C**, After 5 months, there was near-complete repigmentation of the eyelashes.

hair follicles, though in smaller numbers, or the migration of melanocytes from adjacent hair follicle melanocyte reservoirs.

To our knowledge, this is the first report demonstrating the efficacy of a topical JAK inhibitor for vitiligo-associated leukotrichia. We suspect that intervening early in the disease course plus exposure to ambient sunlight likely contributed to the dramatic response. We look forward to the results of ongoing prospective clinical trials of topical JAK inhibitors for vitiligo, including their impact on associated leukotrichia.

Conflicts of interest

Dr Craiglow has received honoraria and/or fees from Aclaris, Arena Pharmaceuticals, Eli Lilly, Regeneron, Sanofi-Genzyme, and Pfizer. Dr Kim has no conflict of interest.

REFERENCES

1. Lee DY, Kim CR, Park JH, Lee JH. The incidence of leukotrichia in segmental vitiligo: implication of poor response to medical treatment. *Int J Dermatol*. 2011;50(8):925-927.

2. Pangti R, Gupta V, Gupta S. Follicular unit extraction of leukotrichia and replacement with follicular units from scalp in combination with epidermal cell suspension in a case of vitiligo. *Dermatol Ther*. 2020;33(6):e13916.
3. Liu LY, Strassner JP, Refat MA, Harris JE, King BA. Repigmentation in vitiligo using the Janus kinase inhibitor tofacitinib may require concomitant light exposure. *J Am Acad Dermatol*. 2017;77(4):675-682.e1.
4. McKesey J, Pandya AG. A pilot study of 2% tofacitinib cream with narrowband ultraviolet B for the treatment of facial vitiligo. *J Am Acad Dermatol*. 2019;81(2):646-648.
5. Olamiju B, Craiglow BG. Tofacitinib cream plus narrowband ultraviolet B phototherapy for segmental vitiligo in a child. *Pediatr Dermatol*. 2020;37(4):754-755.
6. Rosmarin D, Pandya AG, Lebowohl M, et al. Ruxolitinib cream for treatment of vitiligo: a randomised, controlled, phase 2 trial. *Lancet*. 2020;396(10244):110-120.
7. Song HJ, Choi GS, Shin JH. Preservation of melanoblasts of white hair follicles of segmental vitiligo lesions: a preliminary study. *J Eur Acad Dermatol Venereol*. 2011;25(2):240-242.
8. Anbar TS, Abdel-Raouf H, Awad SS, Ragaie MH, Abdel-Rahman AT. The hair follicle melanocytes in vitiligo in relation to disease duration. *J Eur Acad Dermatol Venereol*. 2009;23(8):934-939.