

Case Report

---

# Secondary Colo-Colic Intussusception Caused by Giant Polyp of Sigmoid Colon in a 5-Year-Old Girl

Tan Haizhi Xiao Xiaobing Deng Jianrong

Department of Pediatrics, Yuebei people's Hospital, Shaoguan, China

## Keywords

Intestinal obstruction · Sigmoid colon · Polyp

## Abstract

Intussusception is common in infants and young children. The most common type is small intestinal intussusception or ileo-colic intussusception. Colonic intussusception is rare. Intestinal polyps, especially large polyps or multiple polyps, can cause intussusception. Here, we report a rare case of colo-colic intussusception caused by a giant juvenile polyp of sigmoid colon, and the patient achieved good clinical effect through polypectomy under colonoscopy. So, when children have colonic intussusception, the possibility of colonic polyps should be considered.

© 2023 The Author(s).  
Published by S. Karger AG, Basel

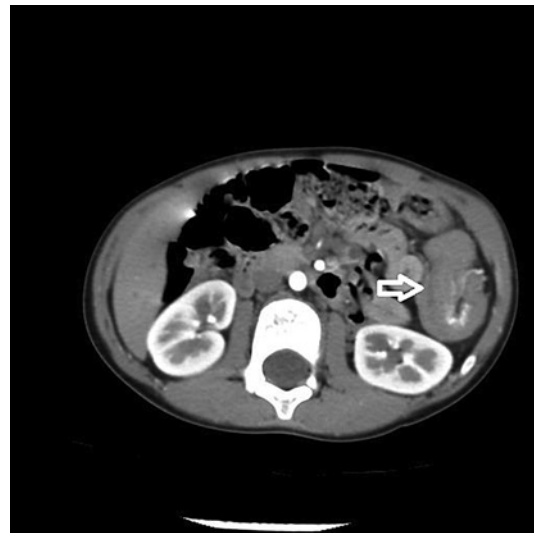
## Introduction

Colonic polyps are quite common in children, which are always isolated and benign. Painless lower gastrointestinal bleeding represents the most common presentation of colonic polyps in children [1, 2]. Intussusception mainly occurs during infancy and early childhood. According to report, the most common causes of secondary intussusception in children older than 2 years were intestinal polyps, Meckel's diverticulum, and Peutz-Jeghers syndrome [3]. Children's intussusception is always an idiopathic ileo-colic invagination; however, colo-colonic intussusception is rare [4]. Here, we report a rare case of colo-colic intussusception caused by a giant juvenile polyp of sigmoid colon, and the patient achieved good clinical effect through polypectomy under colonoscopy.

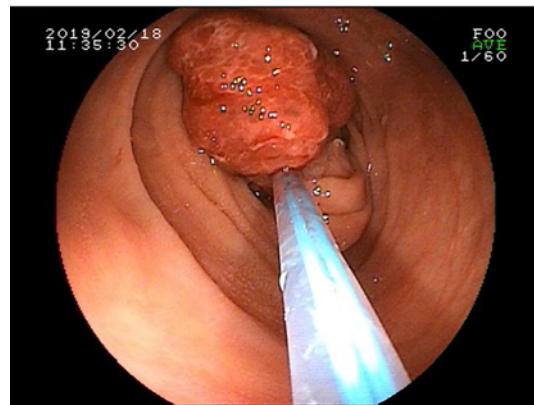
---

Correspondence to:  
Xiao Xiaobing, 706492155@qq.com

**Fig. 1.** CT scan showing the left mid-abdominal bowel, mesentery, and blood vessels were embedded in the bowel, presenting mass and double tubular changes (arrow). Strip vascular shadow was seen in the center of the lesion on enhanced scanning.



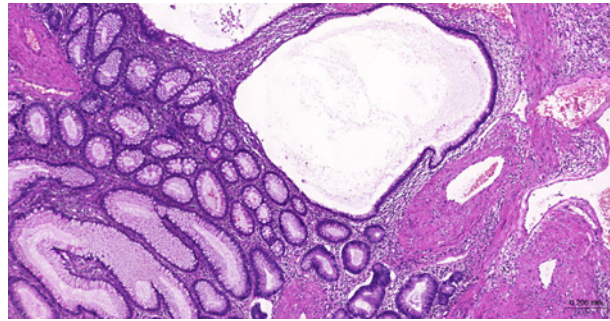
**Fig. 2.** Colonoscopy showed a long-pedicle polyp which was located at 30 cm from sigmoid colon to anus. The polyp surface is rough and congested, and its size is about 3.0 cm\*3.0 cm.



### Case Report

A 5-year-old girl presented with repeated bloody stool for 3 months, accompanied by crying, no fever, no vomiting, etc. She had been treated in other hospitals, considered constipation and anal fissure, and was given softening stool and defecation treatment, but her symptoms did not improve. She came to the outpatient department of our hospital and underwent abdominal CT examination. The results of abdominal CT showed intussusception (Fig. 1). Then, the patient was hospitalized. The blood tests of the children during hospitalization, including blood routine examination, procalcitonin, liver and kidney function, coagulation function, etc, were normal. The results of air enema showed no obvious signs of obstruction, but a dense shadow could be seen in the sigmoid colon. The symptoms of abdominal pain and bloody stool were relieved after enema, anti-infection, hemostasis, and air enema therapies during the hospitalization. There was no bloody stool within 1 month after discharge, but after that, the patient repeatedly underwent bloody stools, and the amount of bloody stools was more or less. Two months later, the patient came to our hospital for hospitalization again. During hospitalization, the patient underwent colonoscopy. Colonoscopy showed that there were many blood stains in sigmoid colon and rectum, and there was a long-pedicle polyp at sigmoid colon. The polyp surface is rough and congested, and its size is about 3.0 cm\*3.0 cm (Fig. 2). The base of polyp was ligated with nylon rope and the polyps

**Fig. 3.** Pathological report suggest JPs. Polyps are mainly composed of proliferative glands of different sizes, with abundant fibrous connective tissue stroma between glands ( $\times 50$ ).



were completely removed by high-frequency electrocautery after ligation with a snare device. No bleeding, perforation, and other complications occurred during the operation. The polyp stumps were clipped with peptide clips. The whole operation takes about 37 min. The pathological findings suggest juvenile polyps (JPs) (Fig. 3).

### Discussion

Intussusception is a form of intestinal obstruction in which a segment of the bowel prolapses into a more distal segment. Li CL et al. [5]. reported that the proportion of intussusception secondary to intestinal polyps in children was 12.96%. Large polyps, multiple polyps, and lobulated polyps are the high-risk factors of secondary intussusception, and early endoscopic intervention can improve the prognosis. Mostly, intussusception is an idiopathic ileo-colic invagination, and colo-colonic intussusception due to a colonic polyp is rare [6]. We searched the PubMed database with polyps and intussusception as keywords. The population was limited to 18 years old, and only a few cases of colonic obstruction caused by polyps could be retrieved [4, 6–9]. In these reports, the polyps causing intussusception were located in the transverse colon [6–8] and descending colon [4, 8], and the number of polyps was single [7] or multiple [4, 6, 8]. So far, there is no case report of intussusception caused by single polyp of sigmoid colon. Painless bloody stool is the most common symptom of intestinal polyps in children. Most of the polyps are sporadic, isolated, and benign [2, 10]. JPs are the most common gastrointestinal polyps diagnosed in children [11], and most JPs are hamartomatous with little malignant potential [12]. Cold biopsy forceps, cold snare polypectomy, hot snare polypectomy are polypectomy techniques. Large polyps (more than 5–7 mm in diameter) are usually removed with snare electrocautery, especially JPs which tend to be very vascular [13]. In our case, the base of the polyp was ligated with nylon rope, high-frequency electrocautery was performed with a snare, and the wound was clamped with a peptide clamp. This method can effectively remove polyps and prevent postoperative bleeding.

In conclusion, we report a rare case of colo-colic intussusception caused by a giant juvenile polyp of sigmoid colon, and the patient achieved good clinical effect through polypectomy under colonoscopy. When children have colonic intussusception, the possibility of colonic polyps should be considered. The CARE Checklist has been completed by the authors for this case report, attached as supplementary material (for all online suppl. material, see <https://doi.org/10.1159/000528436>).

### Acknowledgments

We would like to thank Dr. Guo Yinxia for the help in translating this article into English and thank Dr. Zhu Zhanglong for his contribution to the document format editing of this article.

## Statement of Ethics

Ethical approval is not required for this study in accordance with local or national guidelines. The decision made by Ethics Committee of Yuebei people's Hospital. Written informed consent was obtained from the participants' parent for publication of this case report and any accompanying images.

## Conflict of Interest Statement

The authors have no conflicts of interest to declare.

## Funding Sources

There is no fund support for this project.

## Author Contributions

Dr. Tan Haizhi is responsible for writing the manuscript. Dr. Deng Jianrong obtained patient data. Dr. Xiao Xiaobing approved the final draft submitted and provided expertise on the field. All contributions of this article including Dr. Tan Haizhi, Dr. Xiao Xiaobing, Dr. Deng Jianrong, Dr. Guo Yinxia, and Dr. Zhu Zhanglong read and approved the final manuscript.

## Data Availability Statement

All data generated or analyzed during this study are included in this article. Further inquiries can be directed to the corresponding author.

## References

- 1 Campbell AM, Sugarman I. Does painless rectal bleeding equate to a colonic polyp? *Arch Dis Child*. 2017 Nov; 102(11):1049–51.
- 2 Vermeulen D, Van Winckel M, Vande Velde S, De Bruyne R, Van Biervliet S, De Moerloose B, et al. Not all pediatric intestinal polyps are alike. *Acta Gastro-ent Belg*. 2020 Jan;83(3):393–7.
- 3 Zhao L, Feng SG, Wu P, Lai XH, Lv CL, Chen GR. Clinical characteristics and surgical outcome in children with intussusceptions secondary to pathologic lead points: retrospective study in a single institution. *Pediatr Surg Int*. 2019 Jul;35(7):807–11.
- 4 Maghbool M, Azarpira N, Ezzat SR, Zeraatian S. Colocolonic intussusception secondary to juvenile polyp, case report. *Acta Gastr-Ent Belg*. 2013 Jun;76(2):255–6.
- 5 Li CL, Luo YH, Ouyang HJ, Liu L, Zhang WT, Jiang N, et al. Clinical features of intestinal polyps and risk factors for secondary intussusception in children: an analysis of 2,669 cases. *Zhongguo Dang Dai Er Ke Za Zhi*. 2022 May;24(5):530–5.
- 6 Takahashi T, Miyano G, Kayano H, Lane GJ, Arakawa A, Yamataka A. A child with colo-colonic intussusception due to a large colonic polyp: case report and literature review. *Afr J Paediatr Surg*. 2014 Jan;11(3):261–3.
- 7 Raymond J, Ippolito MD, Robert J, Touloukian MD. Colocolic intussusception in an older child. Caused by a polyp of the distal colon. *Clin Pediatr*. 1978 Sep;17(9):720–1.
- 8 Woodruff SA, Sokol RJ. Colonic polyp as lead point for intussusception. *J Pediatr Gastr Nutr*. 2007 Sep;45(3): 279–80.
- 9 Arthur AL, Garvey RV, Vaness DG. Colocolic intussusception in a three-year-old child caused by a colonic polyp. *Conn Med*. 1990 sep;54(9):492–4.

- 10 Dipasquale V, Romano C, Iannelli M, Tortora A, Princiotta A, Ventimiglia M, et al. The management of colonic polyps in children: a 13-year retrospective study. *Eur J Pediatr*. 2021 Jul;180(7):2281–6.
- 11 Ibrahimi N, Septer SS, Lee BR, Garola R, Shah R, Attard TM. Polyp characteristics of nonsyndromic and potentially syndromic juvenile polyps: a retrospective cohort analysis. *J Pediatr Gastr Nutr*. 2019 Dec;69(6):668–72.
- 12 Malandra M, Kaur S, Chogle A. Utility of routine colonic biopsies in pediatric colonoscopic polypectomy for benign juvenile hamartomatous polyps. *J Pediatr Gastr Nutr*. 2017 Apr;64(4):555–8.
- 13 Kay M, Wyllie R. Pediatric colonoscopic polypectomy technique. *J Pediatr Gastr Nutr*. 2020 Mar;70(3):280–4.