



Case report

Spontaneous rupture of the umbilical vein associated with liver cirrhosis: A case report



Naruhiko Honmyo^{a,*}, Toshihiko Kohashi^{a,b}, Keishi Hakoda^a, Koichi Oishi^a, Akira Nakashima^a, Ryuta Shintakuya^a, Jun Hihara^a

^a Department of Surgery, Hiroshima City Asa Citizens Hospital, 2-1-1 Kabeminami, Asakita-ku, Hiroshima 731-0293, Japan

^b Department of Gastroenterological and Transplant Surgery, Graduate School of Biomedical and Health Science, Hiroshima University, 1-2-3 Kasumi, Minami-ku, Hiroshima 734-8551, Japan

ARTICLE INFO

Keywords:

Hemoperitoneum
Umbilical vein
Cirrhosis
Collateral circulation
Emergency surgery

ABSTRACT

Introduction: A decompensated cirrhosis sometimes develops collateral circulation due to severe fibrosis. Rupture of this collateral circulation can induce a fatal situation.

Case presentation: A 59-year-old man with alcoholic cirrhosis was admitted to our emergency department with a chief complaint of impaired consciousness. The patient had hypotension upon arrival, and enhanced computed tomography (CT) revealed a massive hemoperitoneum. Imaging examinations, including interventional radiography, could not identify the source of bleeding preoperatively; therefore, emergency surgery was performed. Intraoperatively, a collapsed small vessel connecting liver segment 4 and the expanded umbilical vein as collateral circulation due to portal hypertension was detected as the source of bleeding. Ligating the stump of the small vessel and postoperative intensive care saved the patient's life. The patient was discharged from our hospital 14 days after the surgery.

Clinical discussion: A rupture of the umbilical vein associated with cirrhosis is rare and causes a critical situation because of the fast blood flow in the collateral circulation caused by portal hypertension. Moreover, the amount of bleeding tends to increase since the abdominal cavity is a free space and patients with cirrhosis have coagulopathies, including thrombocytopenia and prolonged prothrombin time. Although a retrospective review of the enhanced CT image could identify the minute findings, arterial portography was insufficient to detect bleeding from the umbilical vein. Therefore, emergency exploratory laparotomy was required for the diagnosis and treatment.

Conclusion: Rupture of the reopened umbilical vein can cause idiopathic spontaneous hemoperitoneum in patients with decompensated cirrhosis.

1. Introduction

Liver cirrhosis develops from chronic liver diseases, such as viral hepatitis type B or C, alcoholic hepatitis, and nonalcoholic steatohepatitis [1]. The progression of cirrhosis induces portal hypertension due to severe fibrosis. Patients with cirrhosis reaching a decompensated phase, may develop ascites, encephalopathy, and collateral circulations, such as gastroesophageal varices [2,3]. Although the esophageal vein or splenorenal shunt is the dominant route of collateral circulation, we sometimes encounter a route via the umbilical vein, namely, the round ligament of the liver and paraumbilical veins. The collateral circulations may cause hepatic encephalopathy and/or gastrointestinal bleeding;

however, they rarely induce hemoperitoneum without a traumatic event.

Here, we report a case of emergency laparotomy for a spontaneous hemoperitoneum caused by rupture of collateral circulation due to liver cirrhosis. This case report is reported in line with the SCARE 2020 criteria [4].

2. Presentation of case

The patient was a 59-year-old man with obesity (body mass index, 29.5 kg/m²) and alcoholic liver cirrhosis. He experienced dull abdominal pain without a traumatic event. The next evening, his wife noticed

* Corresponding author.

E-mail address: naruhiko.honmyo@gmail.com (N. Honmyo).

<https://doi.org/10.1016/j.ijscr.2021.106183>

Received 28 May 2021; Received in revised form 6 July 2021; Accepted 6 July 2021

Available online 7 July 2021

2210-2612/© 2021 The Authors. Published by Elsevier Ltd on behalf of IJS Publishing Group Ltd. This is an open access article under the CC BY-NC-ND license

(<http://creativecommons.org/licenses/by-nc-nd/4.0/>).

him fallen on the floor at their house, and called for an ambulance. Thereafter, the patient was admitted to the emergency department of our hospital.

Upon admission, the patient had hypotension (82/48 mmHg), tachycardia (119 bpm), and cold sweat; therefore, rapid infusion was initiated immediately. The abdomen was hard and bulged markedly; there were no abdominal injury scars. No yellowing of the skin or conjunctiva of the eyes was observed. The patient had a history of visits to our hospital. The results of blood examination at the time of arrival and 18 months prior are presented in Table 1. The patient had obvious anemia, abnormal coagulation, and renal dysfunction, although previous blood examinations revealed only increased liver enzymes. The liver function had worsened and was the severity was classified as Child-Pugh grade C with a score of 11. Ultrasonography showed a large amount of ascites around the liver and spleen and in the pelvic cavity. Enhanced computed tomography (CT) after hemodynamic stabilization revealed cirrhotic appearance, rough surface, and atrophy of the liver and a large amount of bloody ascites in the abdominal cavity (Fig. 1). The size of the spleen was almost equivalent to normal ($9.8 \times 7.5 \times 4.8$ cm). Although the umbilical vein expanded due to portal hypertension, there was no finding of esophageal varices or splenorenal shunt. Leakage of contrast agents outside the vessels had not been detected preoperatively. Interventional radiology (IVR) was performed subsequently; however, no arterial bleeding was identified (Fig. 2). During IVR, the patient's hemodynamics became unstable again; therefore, an emergency exploratory laparotomy was performed.

After the laparotomy under general anesthesia, the source of bleeding was identified as an independent vessel, measuring 2 mm in diameter, which connected the Couinaud's segment 4 of the liver and the umbilical vein, expanding 10 mm in diameter as collateral circulation (Fig. 3). Active bleeding had persisted and was controlled by ligating the stump of the small vessel. The total volume of bloody ascites was 6200 mL. Transfusion, including red blood cells (840 mL), fresh-frozen plasma (720 mL), and platelets (220 mL), was initiated intraoperatively. Postoperative management in the intensive care unit was required for two days. Bleeding did not recur, and the patient's condition improved with the transfusion of fresh-frozen plasma for prolonged coagulation abnormality and ascites. The results of blood examination on the 13th day after surgery are similarly presented in Table 1. The patient was discharged on postoperative day 14. A retrospective review of the enhanced CT images revealed the source of bleeding from the umbilical vein as slightly high-density leakage of contrast agents (Fig. 1, arrow).

3. Discussion

This report demonstrated that rupture of the collateral circulation via the reopened umbilical vein in decompensated alcoholic cirrhosis was the cause of idiopathic spontaneous hemoperitoneum. Although the situation was critical, due to active and severe bleeding, the emergency surgery successfully saved the patient's life.

Table 1
Results of the blood examinations.

	18-month before	On arrival	Postoperative day-13
Total bilirubin (mg/dL)	1.1	3.3	2.3
Aspartic aminotransferase (U/L)	125	85	93
Alanine transaminase (U/L)	64	22	34
Albumin (g/dL)	4.1	2.0	2.2
Prothrombin time index (%)	83	31	37
Creatinine (mg/dL)	0.63	1.01	0.69
White blood cells (/ μ L)	6890	10,400	8460
Red blood cells ($\times 10^6$ / μ L)	4.47	2.49	2.67
Hemoglobin (g/dL)	15.9	8.0	8.8
Platelet counts ($\times 10^3$ / μ L)	174	116	6.6
Child Pugh score (grade)	5 (A)	11 (C)	10 (C)

Atraumatic hemoperitoneum is mostly caused by bleeding from tumors, gynecological causes, and rupture of an intra-abdominal blood vessel in some vascular pathologies such as aneurysms and arteriovenous malformations. Previous case reports have introduced some rare situations regarding rupture of several blood vessels: inferior pancreaticoduodenal artery aneurysm [5], pseudoaneurysm from the middle colic artery [6], rupture of a vein in the colorenal ligament [7], retroperitoneal varix [8], rupture of the left gastric vein [9], and gallbladder hemangioma [10]. To our knowledge, there are only a few reports regarding a hemoperitoneum caused by a spontaneous rupture of the umbilical vein [11–15]. Of these, one was diagnosed by post-mortem CT [15], and one was dead postoperatively [14].

In healthy adults, the round ligament of the liver is the remnant of the umbilical vein, which degenerates into fibrous tissues after birth. It is well known that portal hypertension due to advanced cirrhosis causes reopening of the umbilical vein as a collateral circulation. A rupture of the umbilical vein associated with cirrhosis may be a fatal situation because the blood flow in the collateral circulation is fast, and the abdominal cavity is a free space.

In this case, an expanded umbilical vein was confirmed on enhanced CT; however, there was no expansion of the paraumbilical veins in the abdominal skin, namely a caput medusae. The liver function of the patient 18 months before was classified as Child-Pugh grade A. In contrast, the liver function had severely deteriorated upon admission (Table 1). Although recent data before the bleeding event could not be obtained, cirrhosis might have become decompensated because the patient had continued his drinking habit. The patient's liver function did not show recovery two weeks after the surgery (Table 1). Cirrhosis can induce coagulopathy due to thrombocytopenia caused by splenomegaly and prolonged prothrombin time as a result of decrement of protein synthesis ability of the liver. These coagulation abnormalities may be associated with massive bloody ascites. Preoperative enhanced CT and intraoperative findings depicted progressed cirrhosis in this case. Although the cause of the collateral vessel rupture could not be identified, we hypothesized that progressive atrophy of the cirrhotic liver might have stretched the small collateral vessel connecting segment 4 of the liver and the umbilical vein, causing it to collapse on slight irritation; the possibility of a minor abdominal compression due to a fall cannot be excluded because the details of the situation following the patient's fall were unknown. According to the literature, in cases of sudden death caused by abdominal apoplexy, the source of bleeding is sometimes unassessable and liver cirrhosis is present in most cases [16]. It may be possible that rupture of small vessels branching from the collateral circulations, as in our case, is the cause of fatal hemoperitoneum.

Emergency laparotomy successfully saved the patient's life. Before performing surgery, IVR was performed to investigate a small ruptured aneurysm. IVR is a minimally invasive therapy that can identify the source of active bleeding and perform hemostatic treatment simultaneously. IVR is useful for arterial hemorrhages from the series of intra-abdominal arteries: the celiac artery, superior mesenteric artery, and inferior mesenteric artery. In several case reports, transarterial embolization successfully controlled hemoperitoneum caused by rupture of aneurysms in the intra-abdominal arteries [5,6,17,18]. Arterial portography is not sufficient for detecting portal hemorrhage. IVR, being technique-sensitive, might sometimes be time-consuming. In the present case, the source of bleeding could not be identified using arterial angiography. Therefore, it is necessary to prepare for an emergency surgery in cases of idiopathic spontaneous intra-abdominal bleeding.

4. Conclusion

We report a case of hemoperitoneum caused by rupture of the umbilical vein, associated with liver cirrhosis. Cirrhotic liver in the decompensated stage can establish unexpected collateral circulations, which may cause spontaneous hemoperitoneum. Therefore, rapid decision-making for emergency laparotomy may be required in such

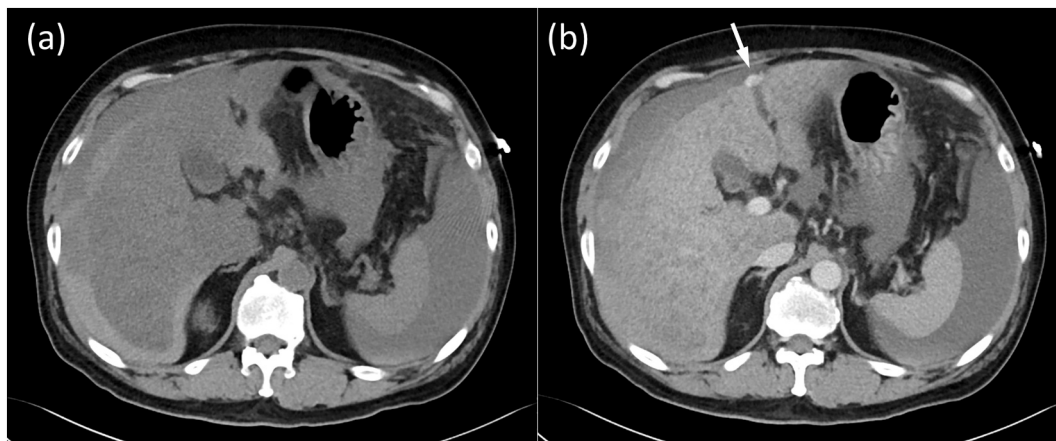


Fig. 1. Computed tomography (CT) images showing a large amount of high-density bloody ascites (a). The liver is atrophied, with an irregular surface. In an enhanced view (b), there are no space-occupying lesions, such as hepatocellular carcinoma, in the liver and no aneurysm or other sources of bleeding confirmed preoperatively. Careful retrospective observation reveals a slight leakage of contrast agents near the expanded umbilical vein (arrow).

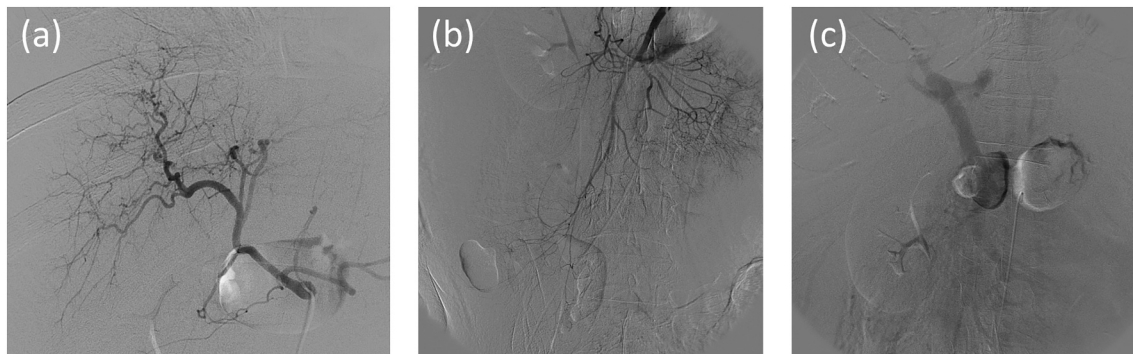


Fig. 2. Interventional radiology did not identify the source of bleeding or any small aneurysms of the intra-abdominal arteries. The celiac artery arteriogram (a), the superior mesenteric artery arteriogram (b), and the arterial portogram (c).

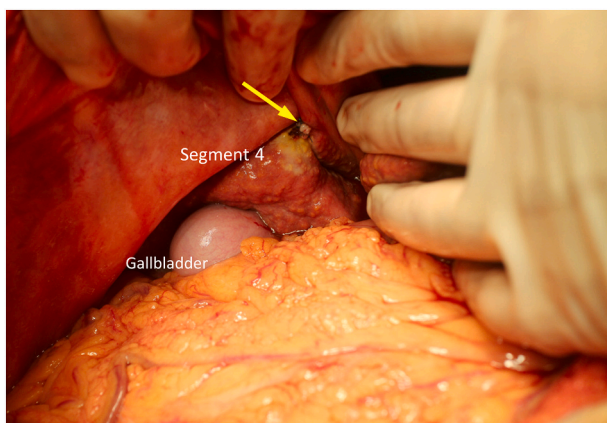


Fig. 3. Intraoperative findings. A large amount of bloody ascites (6200 mL) was observed in the abdominal cavity. The liver was hard, and its surface was rough, indicating cirrhosis. A small vessel, measuring 2 mm in diameter, which connected the Couinaud's segment 4 and umbilical vein, (a collateral circulation due to portal hypertension) is ruptured; active bleeding persisted at the time of laparotomy. The stump of the small vessel was ligated immediately (arrow).

cases.

Sources of funding

This research did not receive any specific grant from agencies in the public, commercial, or not-for-profit sectors.

Ethical approval

All procedures used in this research were approved by the Ethical Committee of Hiroshima City Asa Citizens Hospital.

Consent

Informed consent was obtained from the patient for publication of this case report and any accompanying images. A copy of the written consent form is available for review by the Editor-in-Chief of this journal on request.

Research registration

This case is registered in National Clinical Database; the major database of surgical case in Japan.

Guarantor

Toshihiko Kohashi has accepted full responsibility for this work and the decision to publish it.

CRedit authorship contribution statement

Naruhiko Honmyo: Conceptualization, Data analysis and interpretation, Writing – Original Draft.

Toshihiko Kohashi: Conceptualization, Data analysis and interpretation, Writing – Review & Editing.

Keishi Hakoda: Conceptualization, Investigation, Data analysis and interpretation.

Koichi Oishi: Investigation, Data analysis and interpretation.

Akira Nakashima: Investigation, Data analysis and interpretation.

Ryuta Shintakuya: Data analysis and interpretation.

Jun Hihara: Data analysis and interpretation, Supervision.

All authors read and approved the final manuscript.

Declaration of competing interest

The authors declare that they have no competing interests.

Acknowledgment

The authors would like to thank Editage (<http://www.editage.com>) for editing and reviewing our manuscript for English language.

Provenance and peer review

Not commissioned, externally peer-reviewed.