

REVIEW

The echocardiography of replacement heart valves

John B Chambers

Guy's and St Thomas Hospitals, London, UK

Correspondence should be addressed to J B Chambers
Email
john.chambers@gstt.nhs.uk

Abstract

This is a practical description of how replacement valves are assessed using echocardiography. Normal transthoracic appearances including normal variants are described. The problem of differentiating normal function, patient–prosthesis mismatch and pathological obstruction in aortic replacement valves with high gradients is discussed. Obstruction and abnormal regurgitation is described for valves in the aortic, mitral and right-sided positions and when to use echocardiography in suspected infective endocarditis. The roles of transoesophageal and stress echocardiography are described and finally when other imaging techniques may be useful.

Key Words

- ▶ echocardiography
- ▶ prosthetic valve
- ▶ replacement heart valve
- ▶ transcatheter valve
- ▶ biological valve
- ▶ mechanical valve

Introduction

First of all some explanations: ‘replacement’ is used in place of ‘prosthetic’, which implies being made of artificial materials and does not adequately describe homografts, stentless valves or even stented biological valves; all manufactured valves consist of a sewing ring around a housing (for mechanical valves) or stents (for stented biological valves); inside the housing or stents are the cusps of the biological valve or the ‘occluder’ of the mechanical valve which is the disc, leaflet or ball that closes the orifice; mechanical valves are made of pyrolytic carbon and are not ‘metal’.

Replacement heart valves are one of the hardest subjects for echocardiography. Almost all are obstructive compared with a normal native valve and it may be difficult to differentiate normal from pathological obstruction. Minor regurgitation through the valve is usually normal and the pattern differs between the types of valve. The mechanical parts make imaging hard because of artefact and also the effects of shielding.

New recommendations have just been published (1) and this review incorporates these in describing a practical approach to assessing replacement heart valves.

Types of replacement valve

Replacement valves are either biological or mechanical. The most frequently implanted biological types are those made from animal tissue, ‘xenografts’ (Fig. 1A and B) (2), usually made from pig aortic valves or bovine pericardium. Stentless xenograft valves were introduced in the hope of improving haemodynamic function, durability and complications (Fig. 1C). They are less frequently implanted now but still require echocardiography. Homografts (‘allografts’) are stentless human valves and do not require anticoagulation. If harvested soon after death and preserved carefully they can have long durability even in younger subjects although, when they fail, calcification affects the aorta as well as the cusps making a conventional redo procedure hard. Because they have no artificial parts, they resist infection and can be useful for patients with infective endocarditis. The Ross procedure involves autotransplanting the patient’s pulmonary valve to the aortic position and replacing it with a homograft. This means that a living valve is in the aortic position while a preserved valve is in the lower-pressure right side. It has good durability, may grow in children and is less likely to become infected than a xenograft.

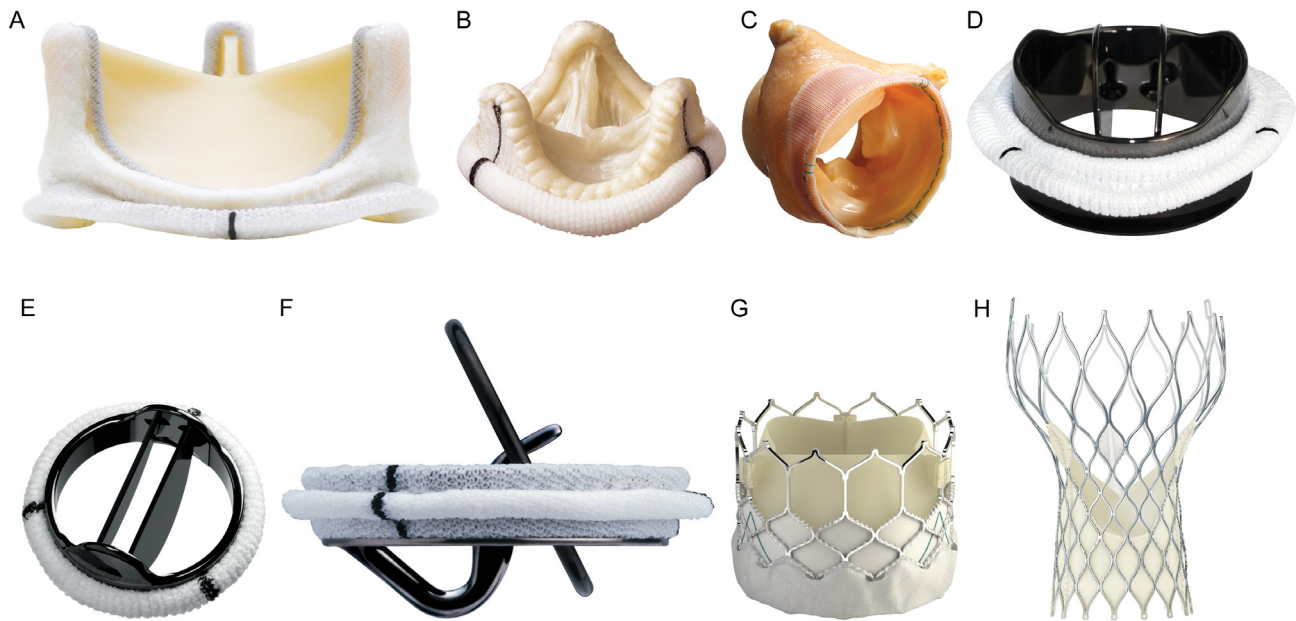


Figure 1

Images of replacement heart valves. Stented biological valves: (A) Magna-Ease (bovine pericardial), (B) Epic (porcine); Stentless biological valve: (C) Medtronic Freestyle; Bileaflet mechanical mitral valves: (D) OnX, (E) Master HP; Single tilting disc: (F) Medtronic-Hall; Transcatheter: (G) Edwards SAPIEN, (H) Medtronic CoreValve. Reproduced with permission from Rimington H & Chambers JB (2016) Echocardiography: A practical guide for reporting and interpretation, 3rd edition; CRC Press; Copyright 2016 Taylor & Francis Group, LLC; ISBN 978-1-4822-3192-2.

The most frequently implanted mechanical valve now is the bileaflet mechanical valve (Fig. 1D and E), but tilting disc valves are still used (Fig. 1F) and caged-ball valves will still require echocardiography. An important new class of valve is the transcatheter valve (TAVI). There are many available or in production but the most commonly implanted are the Edwards SAPIEN (Fig. 1G) and the Medtronic CoreValve (Fig. 1H). These are almost exclusively for use in aortic stenosis but some types of transcatheter device (e.g. Jena) can be implanted in native aortic regurgitation. Increasingly transcatheter valves are being used inside failed stented aortic and mitral replacement valves.

Echocardiography is the mainstay for the assessment of replacement valves and is indicated (Table 1) immediately after surgery to confirm normal function and establish a haemodynamic ‘fingerprint’ for the individual valve. Routine studies after this are not indicated for mechanical valves since their risk of primary failure is effectively zero, but should be performed for older biological valves (Table 1). The American Heart Association currently recommends routine annual follow-up beyond 10 years after replacement (3) while the European Society of Cardiology recommends 5 years (4). In general, the failure rate at 10 years is 20% for xenograft valves in the

aortic position and 40% for those in the mitral position (5). However the failure rate is dependent on a number of factors including valve design, age at implantation, patient–prosthesis mismatch, systemic hypertension and diabetes (6, 7). For these reasons, the frequency of follow-up may need to be individualised according to the design of the valve, the age at implantation and the position of the valve (8).

In patients with abnormal symptoms or signs, echocardiography has to differentiate replacement valve dysfunction from left ventricular (LV) or right ventricular (RV) dysfunction, dysfunction of other valves or

Table 1 Guideline indications for echocardiography for replacement heart valves.

Immediately after surgery to confirm normal function
Routinely late after implantation to detect structural degeneration:
<ul style="list-style-type: none"> • ≥5 years for biological mitral valves or biological aortic valves in patients aged <50 (4) • ≥10 years for biological aortic valves in patients aged >50 (3)
If dysfunction is suspected based on a new murmur or symptom
If there is clinical evidence of infective endocarditis
Before and during pregnancy (every trimester)
Before major non-cardiac surgery

Table 2 Complications of replacement heart valves.

Complication	Mechanical	Biological	Echocardiographic effect
Structural valve deterioration (primary failure)	–	+++	Thickened cusps with regurgitation >>>stenosis
Thrombosis	+++	+	Obstruction
Thromboembolism	+++	++	Nil
Infection	++	++	Vegetations, abscess, dehiscence
Pannus	+	+	Obstruction of closure or opening of leaflet. May be intermittent
Dehiscence	++	++	Paraprosthetic regurgitation
Bleeding	+++	+	Nil

pericardial tamponade. The complications of replacement valves (Table 2) (8) cause either obstruction, regurgitation or both which are detected on echocardiography.

Replacement valves in the aortic position

Normal appearance

Rocking of the replacement valve implies that there is a large paraprosthetic leak. The cusps of a biological valve should be thin and open fully. In a parasternal long-axis view, the tips of the leaflets of a bileaflet mechanical valve will be seen beyond the housing in systole if the valve is placed horizontally. On M-mode, mechanical leaflets often flutter slightly. A tilting disc or ball may appear as an indistinct mass in a parasternal long-axis view and may be difficult to tell apart; the cage of a caged-ball valve is usually better seen in an apical long-axis view. In all types of valves colour should fill the orifice in all planes during systole.

Normal physiological regurgitation through the valve occurs in all mechanical valves and, depending on the design, can occur during closing or after closure or throughout diastole (Fig. 2). Trivial or mild regurgitation across the valve occurs in about 10% of normal biological valves. To establish whether the regurgitation is normal or pathological it is necessary to determine its origin and grade and whether there is thickening of the cusps. Mild regurgitation through a biological valve associated with a thickened cusp is an early sign of primary failure especially if either the regurgitation or thickening increases on serial studies. Localising its origin as either paraprosthetic or through the valve can only be certain if the base or neck of the jet can be imaged in relation to the sewing ring. The site of a paraprosthetic aortic jet can be described on the sewing ring as a clock face in the parasternal short-axis view.

Steerable continuous wave Doppler (CW) from the apex is sufficient if the patient is well and the valve is clearly normal but, if there is doubt, the stand-alone probe should be used in at least two windows as for native aortic

stenosis. Valve opening and closing artefacts ('clicks') are normal and bileaflet mechanical valves commonly flutter causing multiple perturbations of the spectral display (Fig. 3). It is important to exclude these artefacts from measurements. It is also important not to position the pulsed sample too close to the replacement valve which results in an artefactually high effective orifice area (EOA). The minimum dataset is peak velocity, mean gradient and EOA using the continuity equation. High velocities are a common dilemma. The challenge is to differentiate normal from patient–prosthesis mismatch (see 'Patient–prosthesis mismatch' section) from pathological obstruction (see 'Is there evidence of obstruction?' section).

Patient–prosthesis mismatch This means that the valve is functioning normally but is too small for the patient.

All xenografts have at least mild patient–prosthesis mismatch because the sewing ring and other valve parts occupy the space normally taken up by blood flow. It does not cause significant problems unless it is severe. Significant patient–prosthesis mismatch is defined echocardiographically by:

- Indexed EOA for moderate 0.66–0.85 cm²/m² and severe ≤0.65 cm²/m² (1). The cut-point varies in different documents between 0.6 and 0.65. For larger patients with BMI ≥30 kg/m², moderate mismatch is defined (1) by a range 0.56–0.7 cm²/m² and severe mismatch is defined by ≤0.55 cm²/m².
- Peak velocity, mean gradient and indexed EOA in the normal range for the types and size of valve (see BSE app).
- Normal cusp or occluder opening. This can be difficult to image on transthoracic echocardiography (TTE) and even on transoesophageal imaging (TOE). Fluoroscopy is then a good way of imaging the moving parts of a mechanical valve provided that it has been impregnated with a radio-opaque marker. CT scanning can image biological as well as mechanical replacement valves.

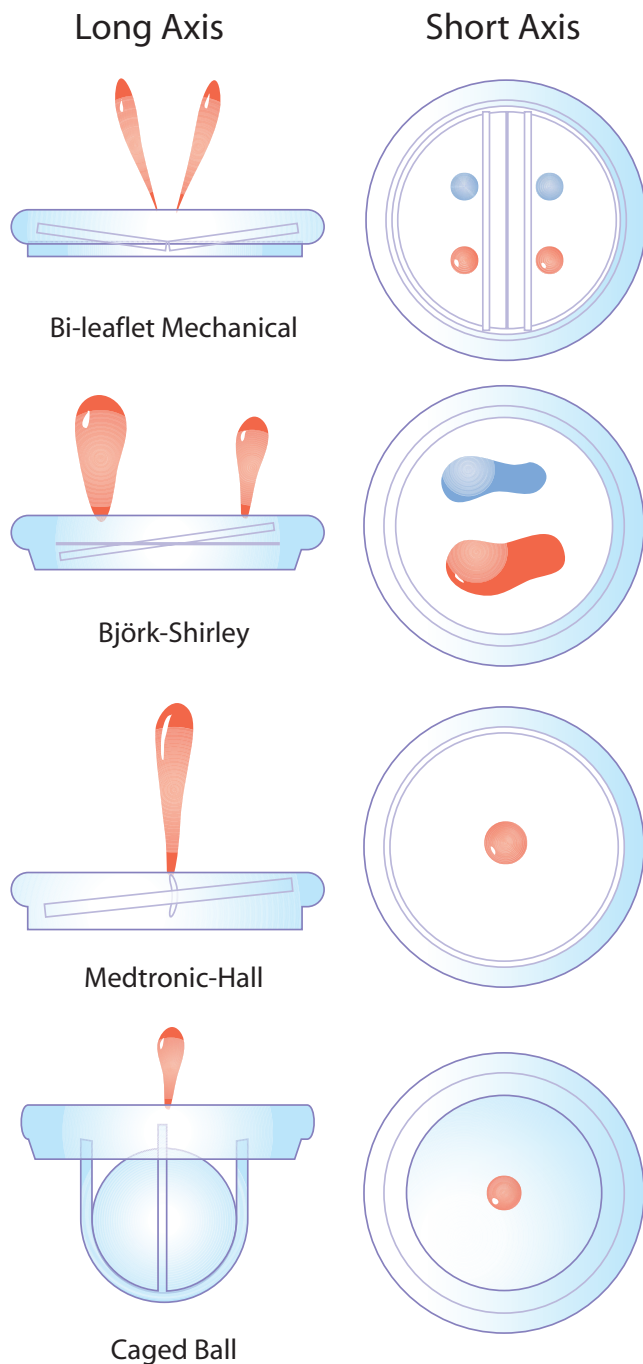


Figure 2
Patterns of normal regurgitation. Reproduced with permission from Rimington H & Chambers JB (2016) *Echocardiography: A practical guide for reporting and interpretation*, 3rd edition; CRC Press; Copyright 2016 Taylor & Francis Group, LLC; ISBN 978-1-4822-3192-2.

Severe patient–prosthesis mismatch is associated with a greatly increased early surgical mortality if the LV ejection fraction is <40% (9). In the long term it is associated with an increased risk of events, of slower

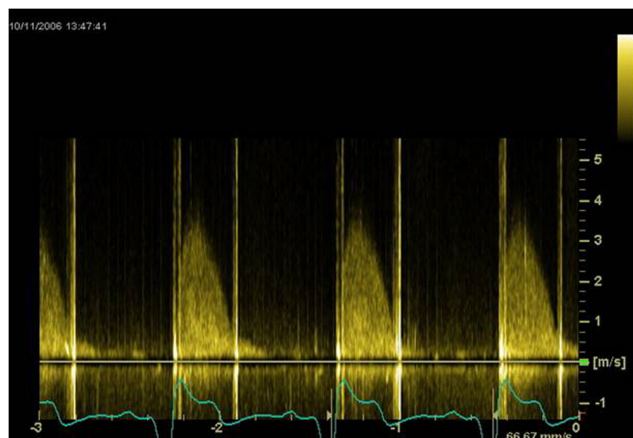


Figure 3
Continuous wave signal through a bileaflet mechanical replacement aortic valve.

regression of LV hypertrophy and accelerated valve failure (10). In practical terms it becomes a problem if the patient is symptomatic, usually with breathlessness, and a decision then has to be made whether to offer redo surgery with a different less obstructive type of valve.

Is there evidence of obstruction? The definitive signs of obstruction are thickened and immobile biological cusps or stuck mechanical occluder (Videos 1, 2 and Table 3). The disc or leaflets of an obstructed mechanical valve may be difficult to image parasternally, but may be seen more easily from the apical 5-chamber and long-axis views. TOE may show the leaflets or occluder but often fluoroscopy or CT scanning is more useful. CT may image pannus better than echocardiography (11). Pannus is endothelial overgrowth developing late after implantation in around 0.5% p.a. depending on valve type and size (Fig. 4). It forms a shelf over the sewing ring on the upstream side of the valve and may interfere with the opening or closing of a mechanical valve or may act as a nidus for thrombus formation.

Video 1

Parasternal short-axis view showing normal forward flow filling the orifice. View Video 1 at <http://movie-usa.glencoesoftware.com/video/10.1530/ERP-16-0032/video-1>.

Video 2

Parasternal short-axis view of the same valve as in Video 1 after one leaflet became immobilised by thrombus. Colour can be seen filling only half the available orifice. View Video 2 at <http://movie-usa.glencoesoftware.com/video/10.1530/ERP-16-0032/video-2>.

Table 3 When to suspect severe obstruction of an aortic replacement valve (1).

Thickening or reduced mobility of cusps or occluder
Narrowed colour map across the aortic valve
Echo-Doppler measurements outside normal values (see BSE app) (observed EOA $>0.35\text{ cm}^2$ less than expected)
Change in measurements by $>$ about 25% on serial studies. In the absence of serial studies suspect if:
<ul style="list-style-type: none"> • Peak velocity (V max) $\geq 4.0\text{ ms}$ • Mean pressure difference $\geq 35\text{ mmHg}$ • Effective orifice area (EOA) $<0.8\text{ cm}^2$ • Acceleration time $>100\text{ ms}$

A narrowed colour flow map complements the imaging but a comparison of peak velocity, mean gradient and effective orifice area by the continuity equation with normal values for type and size (see BSE app) and/or with previous studies in the same patient (Table 3) is more useful. Obstruction is corroborated or suggested by a difference from these by approximately 25% from previous studies as an arbitrary cut-point allowing for measurement error.

The phenomenon of pressure recovery may explain the occasional finding in a small bileaflet mechanical valve of a combination of normal leaflet opening and a peak velocity higher than the normal range. A bileaflet mechanical valve effectively has three individual orifices, one between the leaflets and the other two on either side between the leaflets and the housing. The maximum pressure drop may be lower in the central orifice and rapid pressure recovery occurs before blood leaves the valve. This phenomenon has been demonstrated *in vitro* and in one study in transoesophageal echocardiography

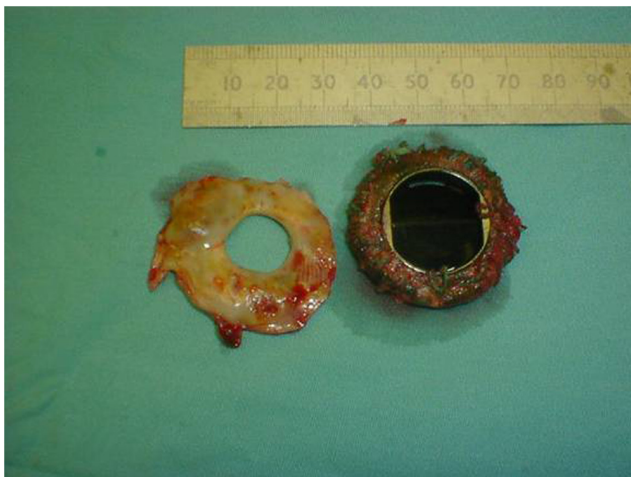

Figure 4
Pannus separated from a mechanical mitral valve after redo surgery.

in replacement valves in the mitral position (12). It is probably possible to insonate unrecovered blood flow selectively on occasion in replacement aortic valves. This mechanism is difficult to prove but is the default explanation if all pathological processes have been excluded after finding a higher transaortic velocity than expected for the valve size and type. A separate pressure recovery occurs downstream in all replacement valves other than, for example, some pericardial bioprostheses that behave haemodynamically as funnels. This does not cause confusion since Doppler normal ranges are calculated using continuous wave Doppler recorded at the point of maximum pressure drop.

Severity of regurgitation

Normal regurgitation through a mechanical valve is usually low in momentum (relatively homogeneous colour) with an incomplete or very low intensity continuous wave signal. For larger jets, the same methods as for native regurgitation are used (13). Assessing the height of a jet relative to LV outflow diameter may be difficult since paraprosthetic jets are often eccentric. The circumference of the sewing ring occupied by the aortic jet is another guide: mild ($<10\%$), moderate (10–20%) and severe ($>20\%$). This is less reliable if there are multiple jets. A hyperdynamic LV is a clue that there is severe prosthetic aortic (or mitral) regurgitation.

Transcatheter valves (TAVI)

The assessment of TAVI valves is similar to other designs of replacement valve (14). There are two concerns. First, if the valve has a long stent then placing the pulsed sample volume too low in the LV outflow tract, in other words too close to the valve, can lead to an artefactually high effective orifice area. Secondly, there are often multiple paraprosthetic regurgitant jets and even a combination of jets through the valve as well as paraprosthetic jets. These can be difficult to quantify although, in general, the same modalities as for native aortic regurgitation are used. The width of the colour map in the LV outflow tract may not be reliable, but the pattern of flow reversal in the aortic arch should reflect the total regurgitant volume. A distinct continuous wave signal with a short pressure half-time may sometimes be revealing and indirect signs like a hyperdynamic LV may also be helpful. In theory, cardiac magnetic resonance (CMR) may be used to quantify regurgitation but this is rarely needed clinically.

Replacement valves in the mitral position

Normal appearance

Biological cusps and mechanical leaflets are more easily imaged than replacement valves in the aortic position. Some appearances which are normal but can cause confusion are: bubbles in the LV (Video 3) which occur with all types of valve but especially bileaflet mechanical valves (caused by aggregations of red cells as a result of sheer stresses at the leaflet edge as it closes); retained loose chordae causing vegetation-like echos; the valve being sewn to a retained posterior leaflet allowing the valve to rock slightly despite there being no paraprosthetic regurgitation; fibrin strands attached to the valve (seen best on TOE). Colour mapping filling the orifice in all views during diastole is a useful corroboration of normal opening.

Video 3

Apical 4-chamber view showing intra-left ventricular bubbles; a normal finding. View Video 3 at <http://movie-usa.glencoesoftware.com/video/10.1530/ERP-16-0032/video-3>.

Is there regurgitation?

On TTE normal transprosthetic regurgitation tends to be hidden by flow shielding so an easily seen jet is usually paraprosthetic. The intraventricular flow recruitment region of paraprosthetic regurgitation can usually be seen even when the intra-atrial jet is invisible. This allows the regurgitation to be localised. Severe paraprosthetic regurgitation may be obvious from: a large region of flow convergence within the LV; a broad neck; a hyperdynamic left ventricle; a dense continuous wave signal especially with early depressurisation (dagger shape).

If there is doubt, TOE is necessary to evaluate jet width, the size of the intra-atrial jet and pulmonary vein flow (looking for systolic flow reversal). The same criteria as for organic native mitral regurgitation (8) are used to grade prosthetic regurgitation. The length of the sewing ring occupied by a paraprosthetic jet and its maximum width shown on 3D TOE are needed to determine whether percutaneous closure is feasible (14).

Is there evidence of obstruction?

Most information for the diagnosis of obstruction is found from imaging and colour flow mapping. Compare measured peak velocity and mean gradient with normal values (see BSE app). Pressure half-time does not reflect

Table 4 When to suspect significant obstruction of a replacement mitral valve (1).

- Thickening and reduced mobility of cusps or occlude
- Narrowed colour inflow
- Pressure half-time >200ms with peak velocity ≥ 2.5 m/s
- Change in measurements by >about 25% from previous study
- Increase in pulmonary artery pressure
- Effective orifice area < 1.0 cm²
- Difference in EOA from normal > 0.35 cm²
- $VTI_{mv}/VTI_{LVOT} > 2.5$

VTI_{mv} is diastolic transmitral velocity integral; VTI_{LVOT} is systolic subaortic velocity integral.

orifice area in normally-functioning prosthetic mitral valves and the Hatle orifice area formula is not valid. However the pressure half-time lengthens significantly when the valve becomes obstructed (Table 4).

The effective orifice area is not routinely calculated. However, if the patient remains breathless or the pulmonary artery pressure fails to normalise after surgery despite a normal or equivocal mean gradient, effective area can be calculated from the stroke volume in the LV outflow tract divided by the transmitral diastolic velocity integral.

Moderate patient–prosthesis mismatch is defined by an indexed effective orifice area of 0.91–1.2 cm²/m² and severe ≤ 0.9 cm²/m². In people with a BMI ≥ 30 kg/m², moderate is defined by a range 0.76–1.0 cm²/m² and severe is defined by a range ≤ 0.75 cm²/m². A rise in pulmonary artery pressure can be a sign of prosthetic mitral valve obstruction.

Right-sided replacement valves

These are infrequently implanted and data available for calculating normal ranges are sparse leading to larger variability in the cut-points for abnormal function between guideline documents. Tricuspid regurgitation is usually treated with an annuloplasty ring but a replacement valve is implanted if there is organic involvement of the valve (e.g. rheumatic fever or carcinoid), if the valve is severely damaged (e.g. endocarditis) or if functional tricuspid regurgitation is caused by significant leaflet retraction.

Pulmonary stenosis is often treated percutaneously but replacement valves may be used to correct severe regurgitation after percutaneous dilatation of a stenotic valve e.g. in tetralogy of Fallot or to replace the harvested native pulmonary valve during a Ross procedure.

Tricuspid replacement valve

The modified parasternal long-axis view often gives excellent views of the tricuspid valve. Normal function is established by normal thickness and movement of the biological cusps or mechanical leaflets, the colour map filling the orifice in all views, no rocking of the valve (as a sign of dehiscence), and no extraneous masses (suggesting vegetations or thrombus).

Regurgitation is graded as for native tricuspid valve regurgitation (15). Severe regurgitation is suggested by a jet width >7 mm, holosystolic flow reversal in the hepatic vein and a hyperdynamic RV.

Thrombosis of right-sided mechanical replacements is more common than for left-sided valves (Video 4). The minimum dataset for assessing obstruction is peak velocity, mean gradient and pressure half-time (Table 5) (16, 17). Because of respiratory variability, measurements should be made over 3–5 cycles even in sinus rhythm. Thrombolysis is the first-line treatment for thrombosis whatever the size of the thrombus in contradistinction to left-sided thrombosis.

Primary failure of a biological valve is usually obvious transthoracically. Confirming the cause of obstruction of a mechanical valve usually requires TOE.

Video 4

Transthoracic four-chamber view showing the leaflets of a bileaflet mechanical tricuspid valve stuck in the half-open, half-closed position. View Video 4 at <http://movie-usa.glencoesoftware.com/video/10.1530/ERP-16-0032/video-4>.

Pulmonary valve

Imaging the valve leaflets may be difficult and all views including subcostal should be used. Pulmonary regurgitation is graded as for native regurgitation (13).

Obstruction is suggested by a serial change (Table 6) (1, 18) more reliably than a single measurement,

Table 5 When to suspect severe obstruction of a replacement tricuspid valve (1, 5, 6).

Thickening and reduced mobility of cusps or occluder
Narrowed colour inflow
Dilated inferior vena cava or right atrium
Peak velocity ≥ 1.6 m/s (in the absence of severe tricuspid regurgitation)
Mean gradient ≥ 6 mmHg
Pressure half-time >230 ms (unreliable because of respiratory variability)

Table 6 When to suspect pulmonary obstruction (1, 7).

Cusp thickening or immobility
Narrowing of colour flow
Peak velocity ≥ 2.5 m/s for homograft or ≥ 3.2 m/s for all other valve types (suspicious, not diagnostic)
Mean gradient ≥ 15 mmHg for homograft or ≥ 20 mmHg for other types
Increase in peak velocity on serial studies (more reliable)
Impaired right ventricular function

and published normal ranges are derived from small populations. New or progressive RV dysfunction is a further indirect sign of valve pathology. Long-axis excursion and tissue Doppler systolic velocity are always reduced after any cardiac surgery.

Endocarditis

The most important consideration is not to perform the echocardiogram at all unless there is a reasonable clinical suspicion of endocarditis. If echocardiography is performed as part of a 'fever-screen' the yield is close to zero (19) but more importantly there is the real risk of over-interpreting the scan. Structures mistaken for vegetations include fibrin strands, stitches, chordal ends after mitral replacement surgery, side lobe artefact, and age-related thickening of the valve cusps. Structures mistaken for complications include normal transprosthetic regurgitation, mild paraprosthetic leaks, dropout, oedema or haematoma of the aortic root.

If echocardiography is indicated TTE may prove the diagnosis especially if the replacement valve is biological and therefore has less shielding than a mechanical valve. Views of valves in the tricuspid position may also be better on TTE than on TOE. However TOE is often necessary

Table 7 Indications for TOE in assessing replacement heart valves.

Endocarditis clinically likely
Obstruction suggested by TTE to:
- image leaflets or
- detect thrombus, pannus or vegetations
To image leaflet opening to differentiate patient–prosthesis mismatch from pathological obstruction in an aortic valve replacement
Haemolysis (small regurgitant jet often not detected on TTE)
Symptomatic patient and suboptimal TTE imaging
Paraprosthetic mitral regurgitation of uncertain severity
Thromboembolism despite therapeutic INR (to detect pannus or thrombus)

since the sensitivity for vegetations on TTE is generally around 15% compared with 90% on TOE (20, 21).

When is TOE or stress echocardiography indicated?

TTE and TOE are complementary and TOE is rarely used without initial TTE (Table 7). Although TOE is usually necessary to image vegetations and posterior root abscesses, anterior root abscesses may be better seen transthoracically. TOE is essential in the presence of mitral replacement pathology (Video 5) and for determining the feasibility of percutaneous repair of a paraprosthetic mitral regurgitation (Fig. 5).

Stress echocardiography is never indicated routinely but should be considered in patients who are breathless despite a normal resting study (22). The main aim is to detect myocardial ischaemia. It cannot differentiate patient–prosthesis mismatch from pathological obstruction and sufficient data do not exist to establish reliable cut-points. Based on studies in native valve disease, an increase in mean gradient by >20 mmHg in the aortic position or a mean gradient reaching >20 mmHg in a mitral replacement valve are suggested as thresholds for abnormal (22). However the test is most easily interpreted when there is a large increase in gradient associated with breathlessness on dobutamine stress (1, 23).

Video 5

Transoesophageal long-axis view showing pannus. View Video 5 at <http://movie-usa.glencoesoftware.com/video/10.1530/ERP-16-0032/video-5>.

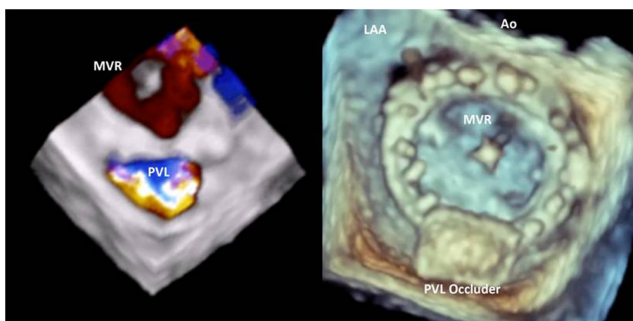


Figure 5
3D TOE showing a paraprosthetic mitral leak before and after percutaneous closure. Image by kind permission of Dr Stam Kapetanakis.

When are other imaging modalities needed?

Echocardiography is the mainstay for assessing replacement heart valves. Fluoroscopy or CT may be used to image occluder motion and CT may be useful to show pannus (24). Otherwise the use of other techniques remains largely in the research or anecdotal stage. CMR can help with flow assessment in mechanical replacement valves, both of the forward flow pattern and regurgitant flow location and quantification. This is especially so for paravalvar leaks (both in conventional and transcatheter replacement valves), which can be challenging to assess with echocardiography (11). CMR is also useful for ventricular volumes and function if TTE images are suboptimal.

Declaration of interest

The author declares that there is no conflict of interest that could be perceived as prejudicing the impartiality of this review.

Funding

This article received no funding.

References

- Lancellotti P, Pibarot P, Chambers J, Edvardsen T, Delgado V, Dulgheru R, Pepi M, Cosyns B, Dweck M, Garbi M, *et al.* 2016 Recommendations for the imaging assessment of prosthetic heart valves. A report from the European Association of Cardiovascular Imaging endorsed by the Chinese Society of Echocardiography. *European Heart Journal: Cardiovascular Imaging*. **17** 589–590. (doi:10.1093/ehjci/jew025)
- Jamieson WR 2002 Current and advanced prostheses for cardiac valvular replacement and reconstruction surgery. *Surgical Technology International* **10** 121–149.
- Nishimura RA, Otto CM, Bonow RO, Carabello BA, Erwin JP, Guyton RA, O’Gara PT, Ruiz CE, Skubas NJ, Sorajja P, *et al.* 2014 AHA/ACC guideline for the management of patients with valvular heart disease: a report of the American College of Cardiology/American Heart Association Task Force on Practice Guidelines. *Circulation* **129** e521–e643. (doi:10.1161/CIR.0000000000000031)
- Vahanian A, Alfieri O, Andreotti F, Antunes MJ, Baron-Esquivias G, Baumgartner H, Borger MA, Carrel TP, De Bonis M, Evangelista A, *et al.* 2012 Guidelines on the management of valvular heart disease (version 2012). *European Heart Journal* **33** 2451–2496. (doi:10.1093/eurheartj/ehs109)
- Grunkemeier GL, Li H-H, Naftel DC, Starr A & Rahimtoola SH 2000 Long-term performance of heart valve prostheses. *Current Problems in Cardiology* **25** 73–156. (doi:10.1053/cd.2000.v25.a103682)
- Rahimtoola SH 2010 Choice of prosthetic heart valve in adults. *Journal of the American College of Cardiology* **55** 2413–2426. (doi:10.1016/j.jacc.2009.10.085)
- Flameng W, Herregods M-C, Vercaalsteren M, Herijgers P, Bogaerts K & Meuris B 2010 Prosthesis-patient mismatch predicts structural valve degeneration in bioprosthetic heart valves. *Circulation* **121** 2123–2129. (doi:10.1161/CIRCULATIONAHA.109.901272)
- Akins CW, Miller DC, Turina MI, Kouchoukos NT, Blackstone EH, Grunkemeier GL, Takkenberg JJM, David TE, Butchart EG,

- Adams DH, *et al.* 2008 Guidelines for reporting mortality and morbidity after cardiac valve interventions. *Journal of Thoracic and Cardiovascular Surgery* **135** 732–738. (doi:10.1016/j.jtcvs.2007.12.002)
- 9 Blais C, Dumesnil JG, Baillot R, Simard S, Doyle D & Pibarot P. 2003 Impact of valve prosthesis-patient mismatch on short-term mortality after aortic valve replacement. *Circulation* **108** 983–938. (doi:10.1161/01.CIR.0000085167.67105.32)
- 10 Vohra HA, Whistance RN, de Kerchove L, Glineur D, Noirhomme P & El Khoury G 2013 Influence of higher valve gradient on long-term outcome after aortic valve repair. *Annals of Cardiothoracic Surgery* **2** 30–39.
- 11 Chambers J, Myerson S, Rajani R, Morgan-Hughes G & Dweck M on behalf of the British Heart Valve Society. 2016 Multimodality imaging in heart valve disease. *OpenHeart* **3** e000330. (doi:10.1136/openhrt-2015-0003312)
- 12 Baumgartner H, Khan S, DeRobertis M, Czer L & Maurer G 1990 Discrepancies between Doppler and catheter gradients in aortic prosthetic valves in vitro. A manifestation of localized gradients and pressure recovery. *Circulation* **82** 1467–1475. (doi:10.1161/01.cir.82.4.1467)
- 13 Lancellotti P, Tribouilloy C, Hagendorff A, Moura L, Popescu BA, Agricola E, Monin J-L, Pierard LA, Badano L & Zamorano JL 2010 European Association of Echocardiography recommendations for the assessment of valvular regurgitation. Part 1: aortic and pulmonary regurgitation (native valve disease). *European Journal of Echocardiography* **11** 223–244. (doi:10.1093/ejechocard/jeq030)
- 14 Zamorano JL, Badano LP, Bruce C, Chan K-L, Goncalves A, Hahn RT, Keane MG, La Canna G, Monaghan MJ, Nihoyannopoulos P, *et al.* 2011 EAE/ASE recommendations for the use of echocardiography in new transcatheter interventions for valvular heart disease. *Journal of the American Society of Echocardiography* **24** 937–965 and *European Heart Journal* **32** 2189–2214. (doi:10.1016/j.echo.2011.07.003)
- 15 Lancellotti P, Moura L, Pierard LA, Agricola E, Popescu BA, Tribouilloy C, Hagendorff A, Monin, Badano L, Zamorano JL, *et al.* 2010 European Association of Echocardiography recommendations for the assessment of valvular regurgitation. Part 2: mitral and tricuspid regurgitation (native valve disease). *European Journal of Echocardiography* **11** 307–332. (doi:10.1093/ejechocard/jeq031)
- 16 Connolly HM, Miller FA, Taylor CL, Naessens JM, Seward JB & Tajik AJ 1993 Doppler hemodynamic profiles of 82 clinically and echocardiographically normal tricuspid valve prostheses. *Circulation* **88** 2722–2727. (doi:10.1161/01.CIR.88.6.2722)
- 17 Kobayashi Y, Nagata S, Ohmori F, Eishi K, Nakano K & Miyatake K 1996 Serial Doppler echocardiographic evaluation of bioprosthetic valves in the tricuspid position. *Journal of the American College of Cardiology* **27** 1693–1697. (doi:10.1016/0735-1097(96)00056-3)
- 18 Novaro GM, Connolly HM & Miller FA 2001 Doppler hemodynamics of 51 clinically and echocardiographically normal pulmonary valve prostheses. *Mayo Clinic Proceedings* **76** 155–160. (doi:10.1016/S0025-6196(11)63122-4)
- 19 Thangarooopam M & Choy JB 2005 Is transesophageal echocardiography overused in the diagnosis of infective endocarditis? *American Journal of Cardiology* **95** 295–297. (doi:10.1016/j.amjcard.2004.09.022)
- 20 Schulz R, Werner GS, Fuchs JB, Andreas S, Prange H, Ruschewski W & Kreuzer H 1996 Clinical outcome and echocardiographic findings of native and prosthetic valve endocarditis in the 1990s. *European Heart Journal* **17** 281–288. (doi:10.1093/oxfordjournals.eurheartj.a014846)
- 21 Habib G, Badano L, Tribouilloy C, Vilacosta I, Zamorano JL, Galderisi M, Voigt J-U, Sicari R, Cosyns B, Fox K, *et al.* 2010 Recommendations for the practice of echocardiography in infective endocarditis. *European Journal of Echocardiography* **11** 202–219. (doi:10.1093/ejechocard/jeq004)
- 22 Garbi M, Chambers J, Vannan MA & Lancellotti P 2015 Valve stress echocardiography: a practical guide for referral, procedure, reporting and clinical implementation of results. On behalf of the HAVEC group. *JACC Imaging* **8** 724–736. (doi:10.1016/j.jcmg.2015.02.010)
- 23 Das P & Chambers J 2000 When is an aortic prosthesis too small? The need for dobutamine stress echocardiography. *International Journal of Clinical Practice* **54** 261–262.
- 24 Teshima H, Hayashida N, Yano H, Nishimi M, Tayama E, Fukunaga S, Akashi H, Kawara T & Aoyagi S 2003 Obstruction of St Jude Medical valves in the aortic position: histology and immunohistochemistry of pannus. *Journal of Thoracic and Cardiovascular Surgery* **126** 401–407. (doi:10.1016/S0022-5223(03)00702-5)

Received in final form 5 September 2016

Accepted 6 September 2016

Accepted Preprint published online 6 September 2016