

# In Situ Neurolysis of Ulnar Nerve for Patients With Failed Anterior Subcutaneous Transposition – A Case Series

Ji Sup Hwang, MD<sup>‡\*</sup>

Yohan Lee, MD<sup>§\*</sup>

Kee Jeong Bae, MD<sup>§</sup>

Jihyeung Kim, MD, PhD<sup>‡</sup>

Goo Hyun Baek, MD, PhD<sup>¶</sup>

<sup>‡</sup>Department of Orthopaedic Surgery, Seoul National University Hospital, Seoul, Republic of Korea; <sup>§</sup>Department of Orthopaedic Surgery, Seoul National University Boramae Hospital, Seoul, Republic of Korea; <sup>¶</sup>Department of Orthopaedic Surgery, College of Medicine, Seoul National University, Seoul, Republic of Korea

\*Ji Sup Hwang and Yohan Lee contributed equally to this work.

#### Correspondence:

Goo Hyun Baek, MD, PhD,  
Department of Orthopedic Surgery,  
College of Medicine,  
Seoul National University Hospital,  
101 Daehak-ro,  
Seoul 03080, Korea.  
Email: [ghbaek@snu.ac.kr](mailto:ghbaek@snu.ac.kr)

Received, December 29, 2020.

Accepted, March 19, 2021.

Published Online, June 7, 2021.

© Congress of Neurological Surgeons 2021.

This is an Open Access article distributed under the terms of the Creative Commons Attribution-NonCommercial-NoDerivs licence (<http://creativecommons.org/licenses/by-nc-nd/4.0/>), which permits non-commercial reproduction and distribution of the work, in any medium, provided the original work is not altered or transformed in any way, and that the work is properly cited. For commercial re-use, please contact [journals.permissions@oup.com](mailto:journals.permissions@oup.com)

**BACKGROUND:** Various surgical techniques have been attempted to treat patients with failed anterior subcutaneous transposition performed for cubital tunnel syndrome.

**OBJECTIVE:** To analyze intraoperative findings of failed anterior subcutaneous transposition and to report the outcome of in Situ neurolysis of ulnar nerve.

**METHODS:** Patients who, under diagnosis of failed anterior subcutaneous transposition of ulnar nerve, underwent in Situ neurolysis between 2001 and 2018 were included in this study. We excluded patients with follow-up of less than one year, records of traumatic ulnar nerve injury, and concomitant double crush syndrome such as cervical spondylosis causing radicular pain, ulnar tunnel syndrome, or thoracic outlet syndrome. Surgical outcomes were evaluated using visual analog scale (VAS) pain score and Disabilities of the Arm, Shoulder, and Hand (DASH) score, which were assessed before and after surgery. A total of 28 elbows in 27 patients whose average age was 58.5 (range, 31-76) yr were enrolled, and the duration of follow-up was 5.8 (range, 1.0-14.9) yr.

**RESULTS:** The most common pathologic finding identified during operation was severe adhesion of the transposed nerve in all elbows, followed by incomplete decompression of deep flexor-pronator aponeurosis in 26 elbows (93%). The average VAS pain score improved from 4.9 (range, 2-7) to 1.3 (range, 0-5), and the average DASH score from 31.7 (range, 18.1-66.7) to 14.1 (range, 5.0-46.6). Of the 28 elbows, 27 (96.4%) showed improvement of preoperative symptoms.

**CONCLUSION:** In Situ neurolysis of ulnar nerve for patients with failed anterior subcutaneous transposition resulted in satisfactory outcome.

**KEY WORDS:** Cubital tunnel syndrome, Failed anterior subcutaneous transposition, In Situ neurolysis, Anterior transposition, Revision cubital tunnel syndrome, Case series

*Operative Neurosurgery* 21:111–117, 2021

DOI: 10.1093/ons/opab171

Cubital tunnel syndrome (CuTS) is the second most common compressive neuropathy in the upper extremity.<sup>1</sup> The estimated prevalence is 30 cases per 100 000 person-years.<sup>2</sup> Approximately 45% of patients diagnosed with CuTS do not benefit from conservative treatment,<sup>3</sup> and therefore, they are indicated for surgical management.<sup>4</sup> Several operative techniques have been reported, such as in Situ decompression, medial epicondylectomy, and anterior transposition.<sup>5,6</sup> Because no one

technique is superior than the others, the selection of the technique has depended on surgeon's preference.<sup>7</sup>

The anterior transposition technique has been widely used.<sup>8,9</sup> The ulnar nerve, of which the original location is behind the medial epicondyle, is moved anteriorly through the technique. The transposition could be either subcutaneous, intramuscular, or submuscular. Among these different methods within anterior transposition, the subcutaneous transposition is the most frequently used.<sup>5,10</sup> Prospective studies showed that patient-reported outcomes after anterior transposition technique were favorable in 75% to 90%.<sup>11,12</sup> Complications that might follow the anterior transposition procedure include hematoma formation,

**ABBREVIATIONS:** CuTS, cubital tunnel syndrome; DASH, Disabilities of the Arm, Shoulder, and Hand; VAS, visual analog scale

**TABLE 1. A Rating Scale for Ulnar Neuropathy at the Elbow**

Score (points)	Pain	Sensory	Motor
0	Needs regular narcotics	Anesthesia	Intrinsic paralysis
1	Intermittent medication; constant pain	Constant numbness	Obvious atrophy
2	Intermittent pain	Intermittent paresthesia	Weaker than opposite side
3	No pain	No numbness	No weakness

surgical site infection, and injuries in small posterior branches of the ulnar nerve.<sup>13</sup>

Despite favorable outcomes, anterior transposition is not always successful. Failure is reported to occur in up to 25% of the patients with CuTS who underwent anterior transposition as primary surgery.<sup>14</sup> For these patients, revision surgery with a more extensive approach is attempted. Repeat anterior transposition technique is one of the options,<sup>15</sup> but 21% to 25% of the cases of anterior submuscular transposition showed deterioration according to objective grading system.<sup>16,17</sup> Other methods, such as anterior subcutaneous transposition,<sup>18</sup> nerve wrapping with saphenous vein,<sup>19</sup> or tissue-engineered biomatrix,<sup>20</sup> have been tried as well. However, results of these revision surgeries are less predictable and satisfactory than primary surgery.<sup>21</sup>

At our institute, in Situ neurolysis of the ulnar nerve was performed for the treatment of patients with failed anterior subcutaneous transposition. During the operation, the ulnar nerve was observed from arcade of Struthers to the flexor-pronator aponeurosis to determine the causes of the recurrent symptoms. The surgical outcome of in Situ neurolysis performed as revision surgery for failed CuTS was evaluated. In this study, we sought to analyze intraoperative findings of failed anterior subcutaneous transposition, and to report the outcome of in Situ neurolysis performed as a revision surgery.

## METHODS

### Study Design and Data Collection

This retrospective study was approved by the Institutional Review Board (IRB No. H-2002-066-1101), which waived informed consent. Medical records of patients who had in Situ neurolysis of the ulnar nerve for failed anterior subcutaneous transposition from January 2001 to December 2018 were reviewed. Inclusion criteria were those who were diagnosed as failed anterior subcutaneous transposition and underwent in Situ neurolysis. The diagnosis was made when the patients had persistent or worsened symptoms after anterior subcutaneous transposition, or recurrence of symptoms after a period of initial relief. The chief complaint of the patients was commonly pain, and ulnar neuropathy was confirmed by electrodiagnostic studies in all patients. Exclusion criteria included patients with a follow-up period of less than 1 yr, iatrogenic injury of the ulnar nerve, or concomitant double crush syndrome such as cervical spondylosis causing radicular pain, Guyon canal syndrome, or thoracic outlet syndrome.

For assessment of symptomatic outcome, we used the same rating system for ulnar neuropathy as described by Gabel and Amadio<sup>17</sup> and

Caputo et al.<sup>18</sup> This system uses a score for each category of pain, sensory, and motor. Patients were evaluated based on the total score and the status at the last follow-up, for a minimum 1 yr, as excellent, good, fair, or poor (Table 1). The amount of pain recorded in the visual analog scale (VAS) and functional outcome measurement using Disabilities of the Arm, Shoulder, and Hand (DASH) score, which were evaluated when the patients were admitted for surgery and at least 1 yr after the surgery, were collected.<sup>22</sup> As surgical finding, operative records on the severity of perineural adhesion, sites of incomplete decompression, and injury of the cutaneous branches were analyzed. When the perineural adhesion was circumferential around the nerve, causing tethering and immobilization of the ulnar nerve, it was considered as severe.<sup>23</sup> When the part of the nerve was flattened, pale, and smaller in diameter than the adjacent part, it was considered incomplete decompression.

Among 34 elbows in 33 patients who underwent revision cubital tunnel surgery during the study period, 28 elbows in 27 patients were included in the study. There were 17 male and 10 female patients, whose average age was 58.5 (range, 31-76) yr. Eight patients had a history of fracture around the elbow: lateral condyle fracture in four patients, bicondylar fracture two, and olecranon fracture two. All 4 patients with a history of lateral condylar fracture showed valgus deformity of their elbows. On the review of surgical records written in the hospitals where the patients underwent surgery, we found that the ulnar nerves were anteriorly transposed subcutaneously in all 28 elbows. The mean interval between the primary and revision surgeries was 3.3 (range, 0.1-10.4) yr. In 23 elbows, preoperative symptoms were persistent despite the primary surgery, and symptoms of 5 elbows improved for quite some time but recurred. Before surgery, patients were examined by Tinell's sign along the course of ulnar nerve, 2-point discrimination, and ulnar innervated extrinsic and intrinsic motor function. The average follow-up period after the in Situ neurolysis was 5.8 (range, 1.0-14.9) yr (Table 2).

### Surgical Procedure

Skin incision was made along the prior surgical incision and extended one inch proximally and distally. The ulnar nerve was identified at proximally extended incision site, and it was dissected distally (Figure 1A and 1B). During dissection, presence of any injuries of the cutaneous nerves was observed and recorded. When the cutaneous nerves were intact, they were carefully isolated and protected. The ulnar nerve at the elbow was checked from the arcade of Struthers, medial intermuscular septum, flexor retinaculum, and flexor carpi ulnaris aponeurosis and to the deep flexor-pronator aponeurosis. Structures that compressed the ulnar nerve were examined, and neurolysis was done in Situ (Figure 1C-1E). When neuroma(s) of the cutaneous branches were found, they were excised, and the stumps were embedded in the subcutaneous tissue. All operations were performed by a single surgeon (G.H.B.), who is a senior orthopedic surgeon with more than 10 yr of surgical specialty training in hand surgery. Patients were immobilized by a long arm splint for 7 d with their

Age (yr) <sup>a</sup>	58.5 (35-76)
Sex (female) <sup>b</sup>	10 (37%)
Length of follow-up (yr) <sup>a</sup>	5.8 (1.0-14.9)
<b>Persistent or recurrent symptom<sup>b</sup></b>	
Persistent	23 (82%)
Recurrent	5 (18%)
Associated comorbidities <sup>b</sup>	6 (22%)
<b>History of elbow fracture<sup>b</sup></b>	8 (29%)
Lateral condylar fracture	4
Bicondylar fracture	2
Olecranon fracture	2
Interval between the primary and revision surgery (yr)	3.3 (0.1-10.4)

<sup>a</sup>Data are presented as numbers and (ranges).  
<sup>b</sup>Data are presented as counts and (percentages).

elbows flexed by 30 degrees, and they were subsequently allowed to begin full active range of motion.

## RESULTS

### Surgical Findings

In all 28 elbows, the ulnar nerves were anteriorly transposed subcutaneously. Findings of incomplete decompression were found, and their locations were identified in 26 elbows (93%). We found an average of 1.8 (range, 1-3) incomplete decompression

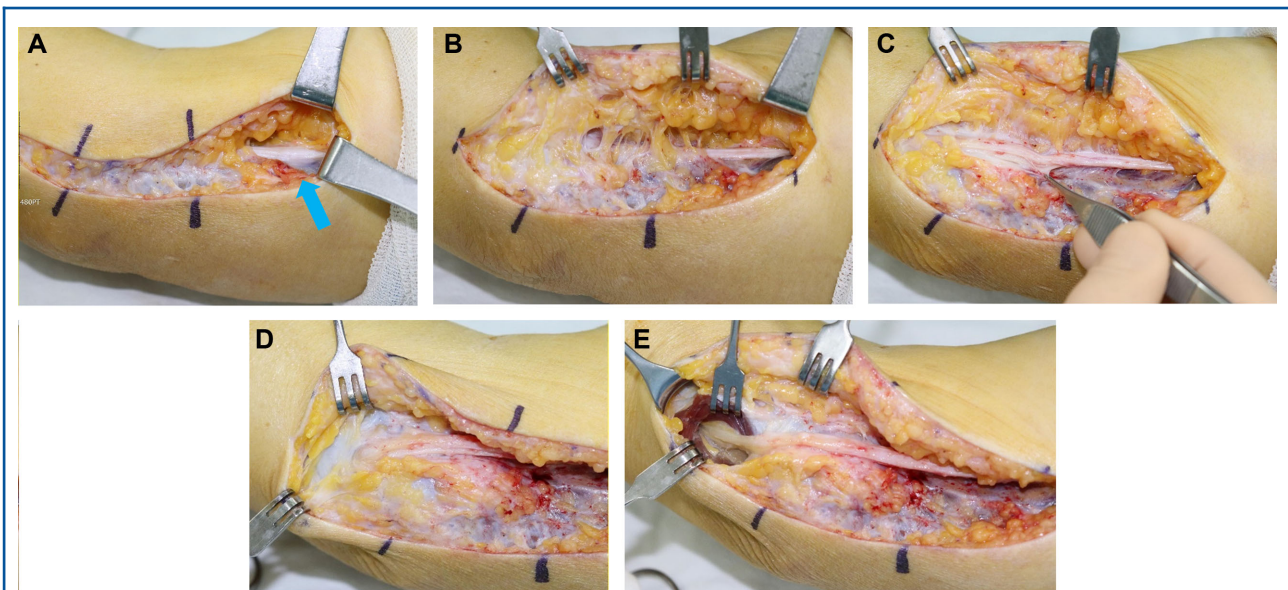
sites. Incomplete release of the deep flexor-pronator aponeurosis (26/26) was the most common, followed by flexor carpi ulnaris aponeurosis (18/26), medial intermuscular septum (3/26), and the arcade of Struthers (2/26). All 28 elbows showed severe perineural adhesions (Figure 2). Neuroma at the branch of the medial antebrachial cutaneous nerve was found in three elbows, which were excised and embedded in the subcutaneous tissue. A summary of our surgical findings is illustrated in Figure 3 and Table 3.

### Surgical Outcomes

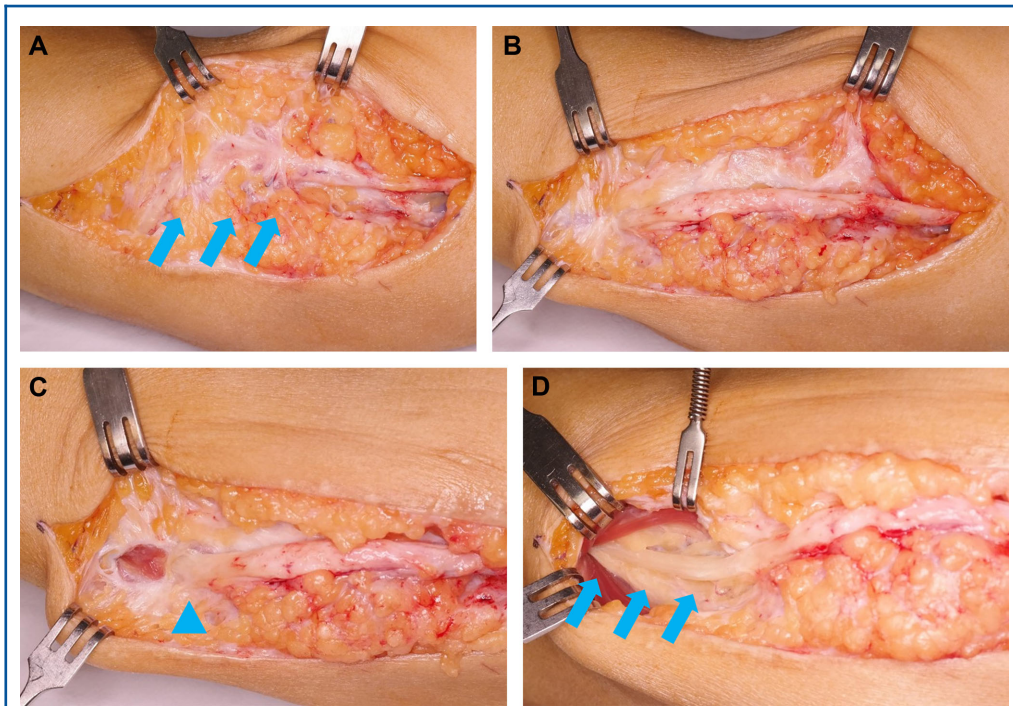
Degree of pain was improved in 25 elbows (89%) postoperatively, sustained in 3 (11%), and aggravated in none. The VAS score was improved from 4.9 (range, 2-7) to 1.3 (range, 0-5). Degree of numbness was improved in 24 elbows (86%) postoperatively, sustained in 4 (14%), and aggravated in none. Weakness was improved in 20 elbows (71%) postoperatively, sustained in 8 (29%), and aggravated in none. Overall, 2 elbows (7%) were rated as excellent, 18 (64%) good, 7 (25%) fair, and 1 (4%) poor (Table 4). The DASH score was improved from 31.7 ± 11.7 preoperatively to 14.1 ± 9.5 postoperatively (*P*-value < .001). No complications were recorded postoperatively.

## DISCUSSION

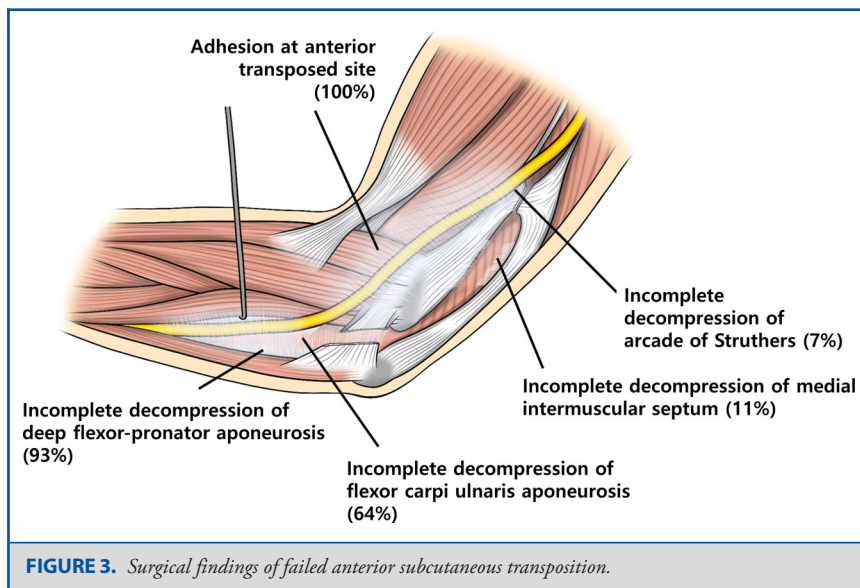
Anterior transposition of the ulnar nerve is inarguably one of the most widely used techniques for cubital tunnel surgery. The



**FIGURE 1.** *A*, At the proximally extended previous incision site, the normal part of the ulnar nerve is identified (arrow). *B*, Subsequent dissection is performed distally. *C*, Perineural adhesion is circumferential around the anteriorly transposed nerve causing tethering and immobilization of the nerve. *D*, Examination along the whole course of the ulnar nerve allows the identification of the completeness of the previous decompression. In this photo, incomplete decompression of the deep flexor-pronator aponeurosis could be assumed by a lack of evidence that any surgical procedure had been performed. *E*, Release of the deep flexor-pronator aponeurosis revealed that the underneath ulnar nerve was flattened, pale, and smaller in diameter than the adjacent part.



**FIGURE 2.** This patient (a 61-yr-old man) previously had anterior subcutaneous transposition of ulnar nerve after failed *in Situ* decompression for CuTS. His symptom, however, was aggravated and revision surgery was performed. **A**, Severe adhesion was identified along the ulnar nerve at the region of transposition anterior to the medial epicondyle (arrows). **B**, Meticulous adhesiolysis was performed, and the nerve is now freed. **C**, Release of the flexor carpi ulnaris aponeurosis revealed that the underneath ulnar nerve was flattened, pale, and smaller in diameter (triangle) than the adjacent part. **D**, Complete release of structures including flexor-pronator aponeurosis was performed. Parts of the ulnar nerve that were incompletely decompressed during previous surgeries are marked by arrows. Symptom relief started immediately after the *in Situ* neurolysis and weakness improved 6 mo after the surgery.



**FIGURE 3.** Surgical findings of failed anterior subcutaneous transposition.

**TABLE 3. Surgical Findings of 28 Cases of Revision Cubital Tunnel Surgery**

Case number	Severe adhesion	Structures compressing the ulnar nerve	Additional procedures
1	Yes	AS, FCUA, FPA	
2		FCUA, FPA	
3	Yes		
4	Yes	FCUA, FPA	
5		FCUA, FPA	
6	Yes	FCUA, FPA	
7	Yes		
8	Yes	FCUA, FPA	
9		FPA	
10	Yes	FCUA, FPA	
11		FPA	Excision of neuroma
12		FPA	
13		AS, FCUA, FPA	
14		FCUA, FPA	
15	Yes	FPA	
16	Yes	FCUA, FPA	Excision of neuroma
17		FCUA, FPA	
18	Yes	FPA	
19	Yes	FPA	
20		FPA	
21		FCUA, FPA	
22		FCUA, FPA	
23		FCUA, FPA	
24	Yes	FCUA, FPA	
25		FCUA, FPA	
26	Yes	FCUA, FPA	
27		FPA	
28	Yes	FCUA, FPA	Excision of neuroma

AS = Arcade of Struthers, FCUA = flexor carpi ulnaris aponeurosis, FPA = deep flexor-pronator aponeurosis.

**TABLE 4. Outcome of in Situ Decompression for Patients With Failed Anterior Subcutaneous Transposition of Ulnar Nerve**

	Preoperative	Postoperative	Improvement	P value
Pain	1.2 ± 0.6	2.4 ± 0.6	+1.2	<.001
Sensory	1.1 ± 0.4	2.2 ± 0.6	+1.1	<.001
Motor	1.0 ± 0.7	1.9 ± 0.8	+0.9	<.001
Total score	3.4 ± 1.0	6.4 ± 1.3	+3.0	<.001

technique has preference over in Situ decompression technique when the neuropathy is severe or when the nerve becomes unstable after simple decompression.<sup>9</sup> However, failure rate up to 25% after anterior transposition for CuTS were reported.<sup>14</sup> The unfavorable outcomes were related to incorrect diagnosis, adhesion after anterior transposition, and incomplete decompression.<sup>15</sup>

One of the main causes of the failed anterior subcutaneous transposition was severe perineural adhesion, which was found in all study patients. The adhesion might be related to the location of the transposed ulnar nerve, which is not physiologic. Considering that the nerve is prone to sublunate to its former location when transposed, creation of structures that prevents this migration is needed. Fascial sling or subcutaneous stitches that were created to prevent medial migration of the transposed nerve was considered a cause of the adhesion because we observed that these adhesions were mainly located around the medial condylar area where the nerve was transposed (Figure 2). Furthermore, decrease in blood flow to the ulnar nerve is inevitable after anterior subcutaneous transposition.<sup>24</sup> The resultant hypoxic status might stimulate the development of perineural fibrosis.<sup>25</sup>

In 26 elbows (93%), we found incomplete decompression of the nerve at more than one site. It mostly occurred at the distal part of the elbow, especially at the deep flexor-pronator aponeurosis. The incomplete decompression might result in kinking of the nerve during anterior transposition. This finding is consistent with a recent cadaveric study that simulated the anterior transposition of the ulnar nerve and showed the inevitable kinking of the nerve unless distal decompression is performed.<sup>26</sup> Complete decompression of these sites improved patients' complaints significantly. Moreover, injury of the cutaneous nerve such as medial antebrachial cutaneous nerve may result in severe pain after cubital tunnel surgery. This nerve has two branches with consistent course around the medial epicondyle: the anterior branch at a site 1.5 cm proximal to the medial epicondyle and the posterior branch at a site 3.0 cm distal to it.<sup>14</sup> Despite the consistency in the course, Mackinnon and Novak<sup>27</sup> reported that injury occurred in 73% of 100 revision cases during cubital tunnel surgery. Extensive dissection and exposure during the anterior transposition procedure might put the nerves at risk despite their consistent location around the surgical field. This possibility of medial antebrachial cutaneous nerve injury may be reduced if the distal part of the ulnar nerve is not open. These worries of the surgeon might cause incomplete release at the distal part like deep flexor-pronator aponeurosis and flexor carpi ulnaris aponeurosis.

Several surgical techniques have been attempted for patients with failed cubital tunnel surgeries. Gabel and Amadio,<sup>17</sup> Rogers et al,<sup>28</sup> and Aleem et al<sup>16</sup> reported the outcomes of anterior submuscular transposition, and improvement was observed in 60%, 100%, and 25% of the patients, respectively. Caputo and Watson<sup>18</sup> attempted anterior subcutaneous transposition, and 90% of their patients showed improvement. However, subjects of these studies were heterogeneous in the type of primary surgeries. Most of them had undergone anterior transposition, but others had failed in Situ decompression or medial epicondylectomy, which limits the comparison of the outcomes between the techniques. Types of the anterior transposition as primary surgeries also varied (Table 5), which might have been inevitable considering the low incidence of the failure. On the contrary, our reports are based on selected 28 elbows in which anterior subcutaneous transposition had been

**TABLE 5. Comparison of Outcomes of Surgical Techniques Performed for Patients With Failed Cubital Tunnel Surgeries**

References	n	Primary surgery	Follow-up (mo)	Revision surgery	Improvement
Gabel and Amadio <sup>16</sup>	30	SC (60%), IM (17%), SM (10%), ISD (10%), ME (3%)	46	SM (80%), SC (17%), IM (3%)	24 (60%)
Rogers et al <sup>25</sup>	14	ME (44%), SC (38%), IM (13%), ISD (6%)	19	SM	14 (100%)
Caputo and Watson <sup>17</sup>	20	SC (60%), SM (20%), ISD (20%)	32.4	SC	18 (90%)
Aleem et al <sup>15</sup>	28	ISD (93%), SC (7%)	40.8	SM	7 (25%)
Current study	28	SC (100%)	69.9	In Situ neurolysis	27 (96%)

IM, anterior intramuscular transposition; ISD, in Situ decompression; ME, medial epicondylectomy SC, anterior subcutaneous transposition; SM, anterior submuscular transposition.

previously performed but failed. In this study, we performed in Situ neurolysis, and the symptoms were improved after the surgery in 27 elbows (96%). The remaining one patient complained of persistent symptom that, however, did not affect his daily activity. Functional outcomes according to DASH score were also favorable.

### Limitations

There are some limitations of this study. First, this is a retrospective study without comparative group. Thus, we compared our data with previously reported data by using the same measurement method and added DASH scores as validated method for measurement of postoperative status. Second, all patients had anterior subcutaneous transposition at other hospital. Therefore, we could not identify or analyze the state of ulnar neuropathy before the surgery.

### CONCLUSION

From our literature review, we could not find a report on surgical outcomes of in Situ neurolysis for patients with failed anterior subcutaneous transposition. This study showed that severe perineural adhesion at the transposed site and incomplete decompression of the ulnar nerve are two main causes of the failure of anterior subcutaneous transposition. In Situ neurolysis of the ulnar nerve concerning these two main causes resulted in favorable outcome.

### Funding

This study did not receive any funding or financial support.

### Disclosures

The authors have no personal, financial, or institutional interest in any of the drugs, materials, or devices described in this article.

### REFERENCES

- Chung KC. Treatment of ulnar nerve compression at the elbow. *J Hand Surg Am.* 2008;33(9):1625-1627.
- Osei DA, Groves AP, Bommarito K, Ray WZ. Cubital tunnel syndrome: incidence and demographics in a national administrative database. *Neurosurgery.* 2017;80(3):417-420.
- Dellon AL. Review of treatment results for ulnar nerve entrapment at the elbow. *J Hand Surg Am.* 1989;14(4):688-700.
- Palmer BA, Hughes TB. Cubital tunnel syndrome. *J Hand Surg Am.* 2010;35(1):153-163.
- Bartels RH, Menovsky T, Van Overbeeke JJ, Verhagen WI. Surgical management of ulnar nerve compression at the elbow: an analysis of the literature. *J Neurosurg.* 1998;89(5):722-727.
- Kim KW, Lee HJ, Rhee SH, Baek GH. Minimal epicondylectomy improves neurologic deficits in moderate to severe cubital tunnel syndrome. *Clin Orthop Relat Res.* 2012;470(5):1405-1413.
- Boone S, Gelberman RH, Calfee RP. The management of cubital tunnel syndrome. *J Hand Surg Am.* 2015;40(9):1897-1904.
- Novak CB, Mackinnon SE. Selection of operative procedures for cubital tunnel syndrome. *Hand (New York, N.Y.).* 2009;4(1):50-54.
- DeGeorge Jr BR, Kakar S. Decision-making factors for ulnar nerve transposition in cubital tunnel surgery. *J Wrist Surg.* 2019;8(2):168174.
- Baek GH, Kwon BC, Chung MS. Comparative study between minimal medial epicondylectomy and anterior subcutaneous transposition of the ulnar nerve for cubital tunnel syndrome. *J Shoulder Elbow Surg.* 2006;15(5):609-613.
- Gervasio O, Gambardella G, Zaccone C, Branca D. Simple decompression versus anterior submuscular transposition of the ulnar nerve in severe cubital tunnel syndrome: a prospective randomized study. *Neurosurgery.* 2005;56(1):108-117.
- Bartels RH, Verhagen WI, van der Wilt GJ, Meulstee J, van Rossum LG, Grotenhuis JA. Prospective randomized controlled study comparing simple decompression versus anterior subcutaneous transposition for idiopathic neuropathy of the ulnar nerve at the elbow: Part 1. *Neurosurgery.* 2005;56(3):522-530.
- Biggs M, Curtis JA. Randomized, prospective study comparing ulnar neurolysis in situ with submuscular transposition. *Neurosurgery.* 2006;58(2):296-304.
- Lowe JB, Maggi SP, Mackinnon SE. The position of crossing branches of the medial antebrachial cutaneous nerve during cubital tunnel surgery in humans. *Plast Reconstr Surg.* 2004;114(3):692-696.
- Tang P, Hoellwarth SJ, Chauhan SA. Recurrent cubital tunnel syndrome. *JBJS Rev.* 2016;4(3):17.
- Aleem AW, Korgue JD, Calfee RP. Outcomes of revision surgery for cubital tunnel syndrome. *J Hand Surg Am.* 2014;39(11):2141-2149.
- Gabel GT, Amadio PC. Reoperation for failed decompression of the ulnar nerve in the region of the elbow. *J Bone Joint Surg Am.* 1990;72(2):213-219.
- Caputo AE, Watson HK. Subcutaneous anterior transposition of the ulnar nerve for failed decompression of cubital tunnel syndrome. *J Hand Surg Am.* 2000;25(3):544-551.
- Varitimidis SE, Riano F, Sotereanos DG. Recalcitrant post-surgical neuropathy of the ulnar nerve at the elbow: treatment with autogenous saphenous vein wrapping. *J Reconstr Microsurg.* 2000;16(Number 4):273-278.
- Puckett BN, Gaston RG, Lourie GM. A novel technique for the treatment of recurrent cubital tunnel syndrome: ulnar nerve wrapping with a tissue engineered bioscaffold. *J Hand Surg Eur Vol.* 2011;36(2):130-134.
- Ehsan A, Hanel DP. Recurrent or persistent cubital tunnel syndrome. *J Hand Surg Am.* 2012;37(9):1910-1912.
- Roh YH, Kim S, Gong HS, Baek GH. Clinical features affecting the patient-based outcome after minimal medial epicondylectomy for cubital tunnel syndrome. *J Plast Reconstr Aesthet Surg.* 2018;71(10):1446-1452.

23. Stutz N, Gohritz A, van Schoonhoven J, Lanz U. Revision surgery after carpal tunnel release – analysis of the pathology in 200 cases during a 2 year period. *J Hand Surg.* 2006;31(1):68-71.
24. Nakamura K, Uchiyama S, Ido Y, et al. The effect of vascular pedicle preservation on blood flow and clinical outcome following ulnar nerve transposition. *J Hand Surg Am.* 2014;39(2):291-302.
25. Jayson MI. The role vascular damage and fibrosis in the pathogenesis of nerve root damage. *Clin Orthop Relat Res.* 1992;(279):4048.
26. Mahan MA, Gasco J, Mokhtee DB, Brown JM. Anatomical considerations of fascial release in ulnar nerve transposition: a concept revisited. *J Neurosurg.* 2015;123(5):1216-1222.
27. Mackinnon SE, Novak CB. Operative findings in reoperation of patients with cubital tunnel syndrome. *Hand (New York, N.Y).* 2007;2(3):137-143.
28. Rogers MR, Bergfield TG, Aulicino PL. The failed ulnar nerve transposition. Etiology and treatment. *Clin Orthop Relat Res.* 1991;(269):193200.

## COMMENT

**T**his study examines the use of in situ decompression to treat prior failed subcutaneous ulnar nerve transposition. Not surprisingly, the authors noted significant scarring around all of the nerves and failure of the prior surgeon(s) to divide some of the usual sites of ulnar nerve

entrapment in most. Given the high success rate of revision surgery in this series, in situ decompression would seem to be a reasonable treatment option in these cases. I personally use this technique in my practice as well.

Given the prodigious amount of scar noted by the authors in these revision procedures, one wonders whether there is a role for the application of a nerve wrap to limit the regrowth of this perineural scar. There are commercially available wraps designed for this purpose, although given the success rates of revision surgery in this study, perhaps this additional procedural step is unnecessary.

It is also important to note that we now have the advantage of using preoperative high-resolution ultrasound to examine the anatomy prior to performing revision surgery. With ultrasound, I have periodically found hourglass constrictions that contribute to failed prior subcutaneous transposition (and other) ulnar nerve procedures as well. In these cases, I perform an internal neurolysis to release the intraneural compression if external neurolysis is insufficient.

**Christopher J. Winfree**  
New York, New York, USA