

Available online at [www.sciencedirect.com](http://www.sciencedirect.com)

ScienceDirect

journal homepage: [www.elsevier.com/locate/radcr](http://www.elsevier.com/locate/radcr)

## Case Report

# Prerupture diagnosis of a pregnant rudimentary uterine horn <sup>☆</sup>

Lida Anwari, Consultant Obstetrician and Gynecologist

Department of Obstetrics and Gynecology, Darent Valley Hospital, Dartford, Kent, UK

## ARTICLE INFO

## Article history:

Received 23 November 2020

Revised 11 January 2021

Accepted 11 January 2021

## Keywords:

Prerupture diagnosis

Rudimentary horn pregnancy

Abdominal pain

Maternal ultrasound

## ABSTRACT

This clinical case reports prerupture diagnosis of a rudimentary horn pregnancy in a 27-year-old formerly healthy woman presented with moderate to severe suprapubic abdominal pain at the gestational age of 12 + 0 weeks. The suspected diagnosis of this pregnant rudimentary horn via transvaginal ultrasound was acknowledged during an emergency exploratory laparotomy. The simple transvaginal ultrasound criteria suggested by the present study would help clinicians avoid time-consuming inefficient investigative procedure and rule out this rare life-threatening condition by taking into account the rudimentary horn pregnancy as a differential diagnosis in patients presenting with abdominal pain.

Crown Copyright © 2021 Published by Elsevier Inc. on behalf of University of Washington.

This is an open access article under the CC BY-NC-ND license (<http://creativecommons.org/licenses/by-nc-nd/4.0/>)

## Introduction

Rudimentary horn is an uncommon gynecological entity caused by the anomalies during the fusion of the Müllerian ducts. Pregnancy in rudimentary horn is extremely rare with an estimated incidence of 1 in 76,000 pregnancies [1,2]. The rudimentary horn pregnancy (RHP) often terminates in rupture of horn during the first (or rarely second) trimester, which can lead to a life-threatening condition for the mother because of heavy intraperitoneal bleeding. The high amount of bleeding may cause hypovolemia and hemorrhagic shock and possible maternal mortality [3,4]. A review by Kehrer [5] estimated that the worldwide maternal mortality rate of RHP before 1900 was approximately 48% [5]. Though rupture

of the gravid horn is still a common incident, no case of maternal death has been published since 1960 [6].

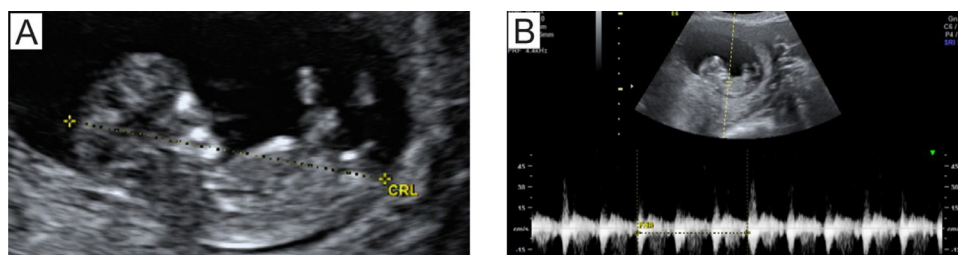
Due to the rarity of the RHP and the nonspecific nature of its symptoms, including abdominal pain that may sometimes be accompanied by nausea and vomiting, a correct prerupture diagnosis is commonly missing. The prerupture recognition of all the symptoms and initiation of management is crucial to reduce the risk of maternal morbidity and/or mortality. Given the significance of this diagnosis, the present study reports on a case of pregnancy in rudimentary horn diagnosed in the first trimester before the horn rupture. The outcome of this work is to emphasize a timely and appropriate diagnostic and management approach to the RHP which helps recognize and manage this clinical condition in new patients before rupture.

<sup>☆</sup> Competing interest: The author has no competing interest to report.


E-mail address: [lidaanwari@gmail.com](mailto:lidaanwari@gmail.com)

<https://doi.org/10.1016/j.radcr.2021.01.029>

1930-0433/Crown Copyright © 2021 Published by Elsevier Inc. on behalf of University of Washington. This is an open access article under the CC BY-NC-ND license (<http://creativecommons.org/licenses/by-nc-nd/4.0/>)



**Fig. 1 – Fetal ultrasound imaging of the studied case. (A) Intact fetus with a crown-rump length of 5 cm (the dotted line). (B) Regular fetal heart beats, indicating a viable pregnancy.**



**Fig. 2 – Maternal ultrasound imaging of the investigated case. (A) An oval-shaped, well-demarcated gestational sac containing the fetus. (B) A non-pregnant empty uterus.**

## Case presentation

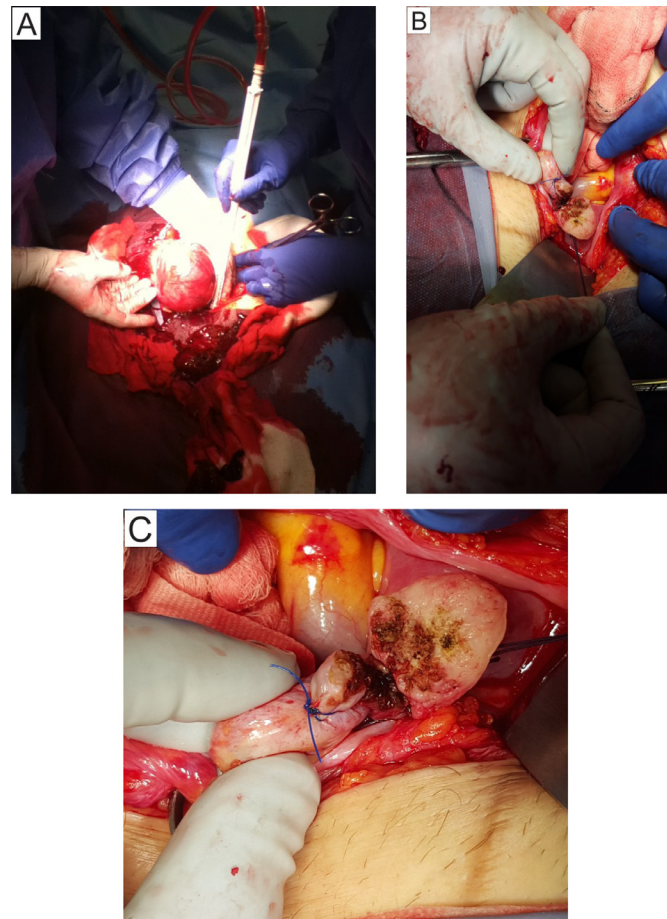
A 27-year-old formerly healthy white woman (I gravida/0 para) initially presented to the Accident and Emergency Department (A&E), Royal Free Hospital London at the gestational age of 12 + 0 weeks with moderate to severe suprapubic abdominal pain. Following abdominal ultrasound, her pregnancy was reported by the A&E to be in normal progression with intact intrauterine gravidity. She was then referred to the Department of Obstetrics and Gynecology, where the author of this manuscript was based at, 2 hours later for ruling out the gynecological-related cause of the pain.

At presentation to the Department of Obstetrics and Gynecology, she was hemodynamically stable with normal vital signs, including 110/70 mm Hg blood pressure, respiratory rate of 16, 90 beats per minute, and 36.6°C temperature. The patient had no history of trauma and former surgical procedures. Physical examinations showed a moderate tenderness diffused over the lower part of the abdomen with a gradual increase when moving. Fetal ultrasound performed transabdominally displayed a viable pregnancy with a crown-rump length of 50 mm, regular fetal heart beats and movement, and the placenta located anteriorly without signs of placental pathology (Fig. 1). Maternal ultrasound assessment performed transvaginally revealed a round- to oval-shaped, well-confined, 18.1 × 17.2 cm gestational sac with a fetus also a normal morphology of adnexal structures. However, a 7.2 × 5.3 cm homogenous structure attached to the inferior and posterior sides of the gestational sac

appeared to be a non-pregnant empty uterus was noticed (Fig. 2). This extrauterine gravidity led to the suspected diagnosis of a RHP, and thus the patient was admitted and an emergency exploratory laparotomy procedure was decided.

The results of preoperational full blood count tests, including 124 g/L hemoglobin (Hb) level, 0.37 hematocrit level, C-reactive protein level of 10, and  $180 \times 10^9$  per liter platelets counts appeared to be normal. Further, liver and kidney function tests and coagulation parameters tests indicated values within normal ranges. In the meantime during transfer to the theater, analgesic therapy with paracetamol 1000 mg, followed by intravenous infusion of the balanced sodium chloride solution, was admitted as a pain management procedure. The entire investigation and diagnosis procedure from presentation to the Department of Obstetrics and Gynecology to the start of operation was fulfilled within 2.5 hours.

After entering the abdomen through the Pfannenstiel incision, no evidence of intra-abdominal bleeding was found. During exploration of the uterus and adnexes, however, the suspected diagnosis of the pregnant rudimentary horn roughly measuring 20 × 18 cm with the gestational sac contained in was discovered intraoperatively. This almost round-shaped structure was attached to the upper right part of the uterus. Following the classification of congenital uterine anomalies by the American Society for Reproductive Medicine [7], this uterine anomaly appeared to be a unilateral formed corpus with a communicating rudimentary horn. After incision of the rudimentary horn, the gestational sac containing



**Fig. 3 – Rudimentary horn in the studied pregnant case. (A) The horn with the gestational sac. (B) Status after excision of the horn. (C) Close-up view of B.**

the fetus was removed (Fig. 3). The results of postoperative laboratory analyses, including the full blood count (were all normal. The patient was discharged on day 3 postoperation.

## Discussion

### Clinical features

#### Symptoms

Clinical symptoms of a pregnant rudimentary horn are often unspecific and may include sudden or gradually increasing suprapubic (sometimes unilateral) abdominal pain and in some occasions vaginal bleeding (for the studied RHP case only moderate-severe abdominal pain was reported). In situations where rupture occurs, there may be general conditions of a hemorrhagic shock state, including tachycardia and hypotension which in acute cases can result in dizziness, faintness, and collapse [8]. Further, clinical examinations indicate the presence of Carnett's sign (acute abdominal pain remains unchanged or increases when the muscles of the abdominal wall are tensed [9,10] and Turner's sign (ecchymosis on the abdominal flank) in some of the ruptured pregnant horns [11].

#### Risk factors

Clinically, risk factors for the RHP are similar to other types of ectopic pregnancy [12]. Adenomyosis, in vitro fertilization, and former surgical intervention modalities may contribute to the development of a RHP [13]. The possible risk factors that may cause rupture of the horn include conditions that elevate intra-abdominal pressure, such as coughing, severe vomiting, or straining during passing stool, but also a prior uterine trauma, hereditary or iatrogenous coagulation abnormalities, vascular malformation, and female sex [14,15].

#### Diagnostic ultrasound

Transvaginal ultrasound method poses a viable diagnostic feature in RHP as in most of the cases intraoperatively discovered to be pregnant in rudimentary horn, the method could lead to the suspected diagnosis of this anomaly. It can be used as a first-line test and is well secure in pregnant patients [15]. The significance of maternal sonography is further proven where the employment of other diagnostic confirmation methods, including computed tomography (CT) scan and magnetic resonance imaging (MRI) is vital, but could not be readily used because of their limited availability. In the case of the patient pregnant in the rudimentary horn investigated here, despite their availability, CT scan and MRI

were not necessary simply because the imaging information obtained from the suspected RHP in week 12 using these complementary methods are not more than that of the maternal sonographic assessment; hence the diagnostic ultrasound would suffice. So far, 4 criteria for ultrasound recognition of the RHP have been suggested by some researchers [1,16–18]:

1. Pseudopattern of an asymmetrical bicornuate uterus.
2. Presence of myometrial tissue surrounding the gestational sac.
3. Absence of visual continuity between the cervix and the wall of the pregnant horn.
4. Hypervascularization typical to placenta accreta.

Owing to several years of experience in advanced maternal ultrasound and clinical assessment, the author challenges Criteria 1, 2, and 4. It is technically very difficult to recognize a bicornuate uterus, as due to much larger size of the gestational sac in the pregnant horn compared to the non-pregnant uterus the link between the horn and the uterus cannot be visualized sonographically. Also, the myometrial tissue can only be observed around the gestational sac in a normal intrauterine pregnancy. In addition, hypervascularization typical to placenta accreta is not specific to the RHP and can be well seen in normal intrauterine pregnancy. Above all, these 3 criteria are time-consuming, whereas quick and efficient suspected diagnosis of the RHP is a very critical matter.

Instead, this study strongly agrees to the suggested criterion 3 that could technically help timely diagnosis of the RHP in the studied case. The absence of continuity between the cervix and the horn supports a suspected diagnosis of RHP because the rudimentary horn has no cervix, and this phenomenon can be readily traced under maternal ultrasound. Additionally, the author introduces here identification of the heterogeneous structure of an empty uterus as a simple and quick technical clue which was useful in prerupture diagnosis of the RHP in the investigated case. Importantly, it is less challenging to identify an empty uterus due to its topographical position in the pelvis.

Given the rarity of the RHP and relatively similar visual features of this anomaly under ultrasound examinations, the Criterion 3 suggested by former works and the technical clue introduced in this study have the potential to be applied for the diagnosis of the RHP in other cases.

#### *Surgical procedure*

In the reported case, a life-saving emergency exploratory laparotomy was executed as the patient was with acute abdominal pain, suggestive for a prerupture status. In addition, the size of the RHP was corresponding to weeks 13 to 14 of the gestation age, which denies the possibility of performing a laparoscopic procedure due to the risk of massive bleeding and technical difficulty of resecting the RHP. The attachment of the rudimentary horn to the uterus varies from a fibromuscular band to an extensive fusion between the two horns where there is no external separation between them [18]. The first was the type of attachment found in the studied case. In the investigated case here, excision of the rudimentary horn from the main uterus with the help of 2 straight hemostatic clamps prevented any significant blood loss from the well-perfused horns during the operation.

## Conclusions

This paper presents a case of a woman with rudimentary horn pregnancy, which prerupture suspected diagnosis was confirmed during emergency exploratory laparotomy. The study suggests simple technical clues to reach timely diagnosis of the rudimentary horn pregnancy and highlights the need for exclusion of time-consuming criteria for recognition of this clinical anomaly. Although pregnancy in rudimentary horn is a relatively rare entity, the risk of serious maternal morbidity and mortality is high. Therefore, prerupture diagnosis is vital in order to manage this life-threatening condition quickly and efficiently.

## Patient consent

Patient consent is already obtained and can be provided to you if you need it.

## Acknowledgments

The author would like to thank the patient and the authorities of Royal Free Hospital London for permission to publish this work. The manuscript was not funded by any organization or by educational grants.

## REFERENCES

- [1] Kanagal DV, Hanumanalu L. Ruptured rudimentary horn pregnancy at 25 weeks with previous vaginal delivery: a case report. *Case Rep Obstet Gynaecol* 2012;2012:985076.
- [2] Lai YJ, Lin CH, Hou WC, Hwang KS, Yu MH, Su HY. Pregnancy in a noncommunicating rudimentary horn of a unicornuate uterus: prerupture diagnosis and management. *Tai J Obstet Gynecol* 2016;55:604–6.
- [3] AbouZahr C. Global burden of maternal death and disability. *Br Med Bull* 2009;67:1–11.
- [4] Say L, Chou D, Gemmill A, Tunçalp Ö, Moller AB, Daniels J, et al. Global causes of maternal death: a WHO systematic analysis. *Lancet Global Health* 2014;2:e323–33.
- [5] Kehrler E. Das Nebenhorn des doppelten Uterus: Dargestellt im Anschlusse an 82 fälle von Graviditat und 12 fäle von Hamatometra, Inaugural dissertation, Heidelberg, 1900.
- [6] Nahum GG. Rudimentary uterine horn pregnancy. The 20th-century worldwide experience of 588 cases. *J Reprod Med* 2002;47:151–63.
- [7] Ludwin A, Ludwin I. Comparison of the ESHRE-ESGE and ASRM classifications of Müllerian duct anomalies in everyday practice. *Hum Reprod* 2015;30:569–80.
- [8] Iyoke C, Okafor C, Ugwu G, Oforbuike C. Live birth following a term pregnancy in a non-communicating rudimentary horn of a unicornuate uterus. *Ann Med Health Sci Res* 2014;4:126–8.



- [9] Suleiman S, DE Johnston. The abdominal wall: an overlooked source of pain. *Am Fam Physician* 2001;64:431–8.
- [10] Cartwright SL, Knudson MP. Evaluation of acute abdominal pain in adults. *Am Fam Physician* 2008;77:971–8.
- [11] Chauhan S, Gupta M, Sachdev A, D’cruz S, Kaur I. Cullen’s and Turner’s sign associated with portal hypertension. *Lancet North Am Ed* 2008;372 *n. pag.*.
- [12] Radwan F, Martin S. Can we reduce the recurrence of cornual pregnancy? A case report. *Gynecol Surg* 2009;6:57–9.
- [13] Wu PJ, Han CM, Wang CJ, CL Lee. Early detection and minimally invasive management of intramural pregnancy. *J Minimally Invasive Gynecol* 2013;20:123–6.
- [14] Sheth HS, Kumar R, DiNella J, Janov C, Kaldas H, RE Smith. Evaluation of risk factors for rectus sheath hematoma. *Clin Appl Thromb Hemost* 2014;22:292–6.
- [15] Eckhoff K, Wedel T, Both M, Bas K, Maass N, Alkatout I. Spontaneous rectus sheath hematoma in pregnancy and a systematic anatomical workup of rectus sheath hematoma: a case report. *J Med Case Rep* 2016;10:292.
- [16] Tsafirir A, Rojansky N, Sela HY, Gomori JM, Nadjari M. Rudimentary horn pregnancy: First-trimester prerupture sonographic diagnosis and confirmation by magnetic resonance imaging. *J Ultrasound Med* 2005;24:219–23.
- [17] Patra S, Puri M, Trivedi SS, Yadav R, Bali J. Unruptured term pregnancy with a live fetus with placenta percreta in a non-communicating rudimentary horn. *Congenit Anom (Kyoto)* 2007;47:156–7.
- [18] Buntugu K, Ntummy M, Ameh E, Obed S. Rudimentary horn pregnancy: pre-rupture diagnosis and management. *Ghana Med J* 2008;42:92–4.