

Gastric heterotopia in rectum: A literature review and its diagnostic pitfall

SAGE Open Medical Case Reports

Volume 5: 1–5

© The Author(s) 2017

Reprints and permissions:

<https://uk.sagepub.com/en-gb/journals-permissions>

DOI: 10.1177/2050313X17693968

journals.sagepub.com/home/sco

Peyman Dinarvand¹, Ashley A. Vareedayah², Nancy J Phillips¹,
Christine Hachem² and Jinping Lai¹

Abstract

Objectives: The term heterotopia, in pathology, refers to the presence of normal tissues at foreign sites. Gastric heterotopia has been reported anywhere in the gastrointestinal tract. However, the presence of gastric heterotopia in the rectum is very rare.

Methods: We, here, report a rare case of a localized 2-cm area of cratered mucosa with heaped-up borders in the rectum of a 51-year-old, asymptomatic woman who underwent screening colonoscopy.

Results: Histologic examination of the biopsy from the lesional tissue in rectum demonstrated fragments of rectal mucosa co-mingling with oxyntic- and antral-type gastric mucosa. No intestinal metaplasia or *Helicobacter pylori* is identified.

Conclusion: Patients with gastric heterotopia in rectum usually present with bleeding and/or abdominal pain. Definite treatment of choice is surgical or endoscopic resection, although the lesions also respond to histamine-2 receptor blockers. In this article, most recent literature about gastric heterotopia in rectum is reviewed, following a case presentation about it.

Keywords

Gastric heterotopia, rectum

Date received: 27 September 2016; accepted: 23 January 2017

Introduction

It is not rare to see gastric heterotopia (GHT) in the esophagus or small intestine. However, the presence of gastric mucosa in the rectum is a very uncommon entity.¹ Since the first report by Ewell and Jackson² in 1939, approximately 50 cases of GHT in the rectum have been reported, to the best of our knowledge.³ Heterotopia is defined as the presence of a particular tissue type at a non-physiological site, but usually co-existing with original tissue in its correct anatomical location.¹ GHT refers to the presence of normal gastric mucosal tissue located in a non-physiological site with demarcation from the surrounding mucosa and entirely separated from the stomach.⁴ GHT is a commonly reported epithelial heterotopia and has been described as heteroplasia (congenital) during organogenesis or metaplasia (acquired) during process of damaged epithelial repair.⁵ Although the histopathologic finding is very accurate for correct diagnosis, GHT is typically identified endoscopically as a polyp, diverticula or ulcer, and it can be seen anywhere in the gastrointestinal (GI) tract, from the mouth to anorectal area, and also in the hepatobiliary system.^{6–9} Most cases are observed in the esophagus, duodenum and Meckel's diverticulum.¹ GHT is variable in size and shape in different anatomical sites,¹⁰ and definite

diagnosis is based on pathologic examination.¹ In this report, we present a case of a woman with a 2-cm polypoid (cratered) GHT in rectum, followed by review of most recent literature about this entity.

Report of a case

We present a case of a 51-year-old woman who presented for average-risk screening colonoscopy. Other comorbidities included morbid obesity, asthma and hypertension. She was otherwise asymptomatic and specifically denied melena, hematochezia, change in bowel habits and family history of colorectal cancer or inflammatory bowel disease. The quality

¹Department of Pathology, School of Medicine, Saint Louis University, St. Louis, MO, USA

²Division of Gastroenterology, Department of Internal Medicine, School of Medicine, Saint Louis University, St. Louis, MO, USA

Corresponding Author:

Jinping Lai, Department of Pathology, School of Medicine, Saint Louis University, St. Louis, MO 63104, USA.

Email: jinpinglei@slu.edu



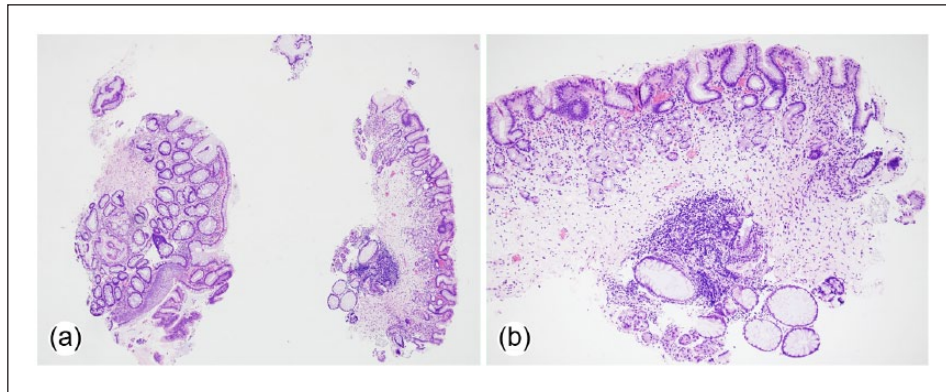


Figure 1. Histologic features of the initial presentation of the rectal biopsy. Presence of gastric mucosa with some attached rectal crypts ((a) original magnification $\times 40$ and (b) original magnification $\times 100$).

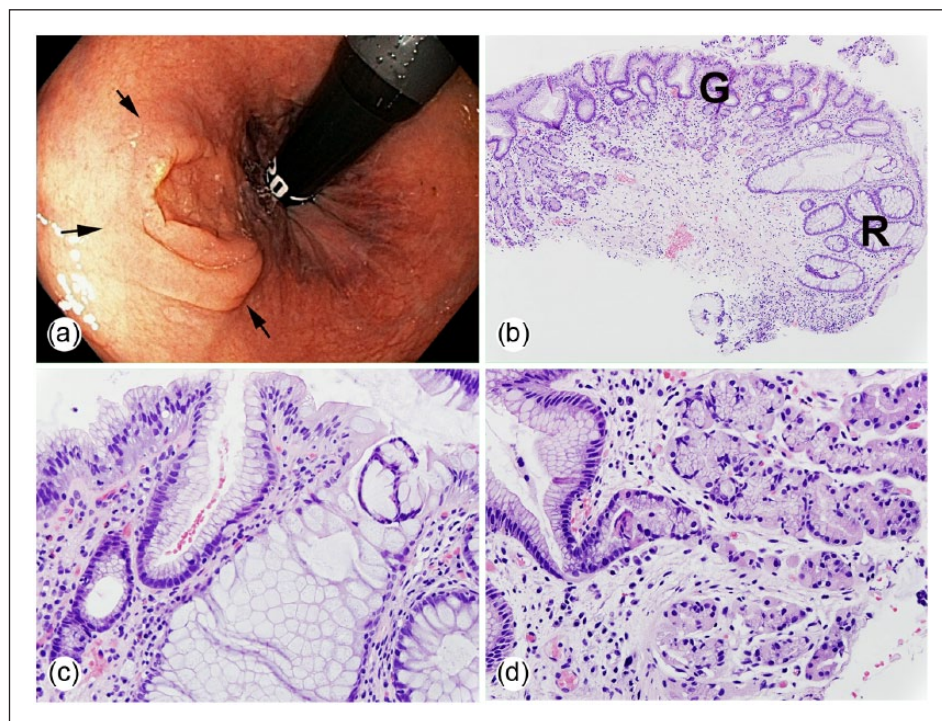


Figure 2. Endoscopic and histological features of gastric heterotopia in the rectum: (a) endoscopic picture of the cratered lesion in the rectum; (b) characteristic features of gastric heterotopia on low magnification, with having both gastric (G) and rectal (R) mucosa co-mingling together (original magnification $\times 100$); (c) specialized foveolar mucosa with very-close rectal crypts (original magnification $\times 400$); and (d) oxyntic and antral glands along with foveolar epithelium in the rectal biopsy (original magnification $\times 400$).

of the preparation was excellent, and she tolerated the colonoscopy without complication. Notable findings included a 3-mm transverse colon polyp, diverticulosis and a localized 2-cm area of cratered mucosa with heaped-up borders in the rectum, noted on retroflexion.

Results

When we initially evaluated our slides to make a diagnosis on a rectal biopsy, we observed multiple fragments of gastric

mucosa, with some minimally attached rectal crypts (Figure 1(a) and (b)). The lesion is endoscopically identified as a localized 2-cm area of cratered mucosa with heaped-up borders in the rectum (Figure 2(a)). The definite diagnosis of this entity is entirely based on histology with hematoxylin and eosin staining (Figure 2(b)–(d)), although using immunostains to demonstrate the transition area between rectal and gastric mucosa could be helpful (Figure 3). The histologic features of GHT in the rectum are simple and have been shown in many cases (Figure 2(b) and (c)).^{1,11,12} Our

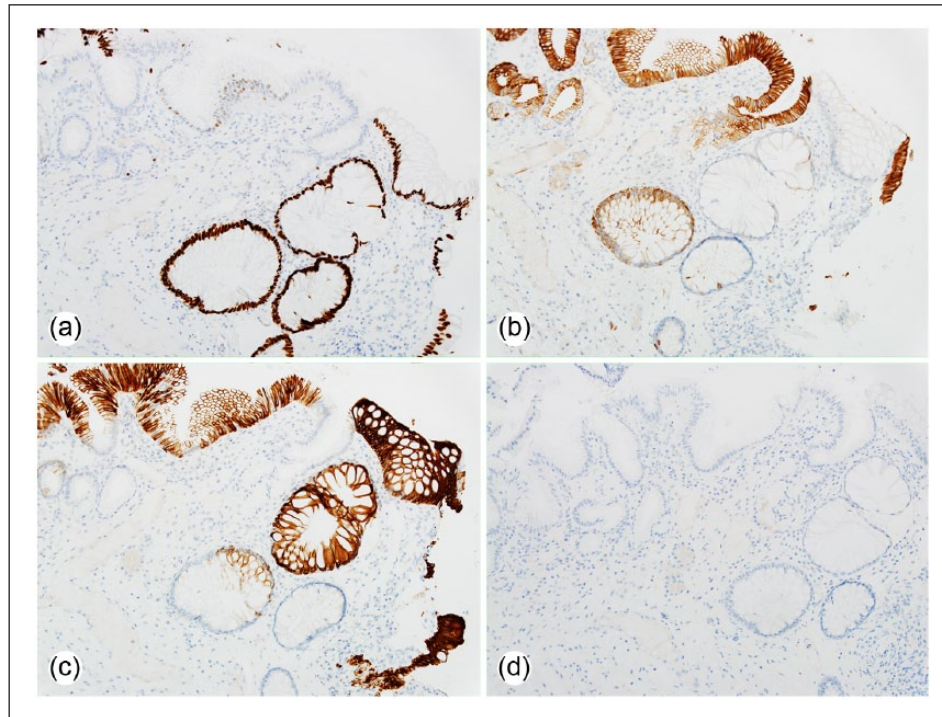


Figure 3. Applying immunostains to the rectal biopsy: (a) presence of positive CDX2 stain indicates the presence of colon-type crypt in this biopsy, (b) showing diffuse positive CK7 stain on foveolar epithelium, (c) CK20 stain is positive in both types of mucosa and (d) immunostain for *Helicobacter pylori* is negative in our case (original magnification $\times 100$).

case showed mixed oxyntic and antral mucosa co-mingling with rectal-type mucosa. It is very uncommon to see other rare heterotopic components like enterochromaffin-like (ECL) cells, intestinal metaplasia or pyloric gland hyperplasia.^{10,13,14} Immunostains for this biopsy can be done to consolidate the diagnosis. CXD2 (Figure 3(a)), CK7 (Figure 3(b)) and CK20 (Figure 3(c)) are very good candidates to show the difference between these two specialized epithelium in GI tract, with CDX2 being positive in rectal, and CK7 in gastric, mucosa. CK20, in our case, is positive in both types of epithelium.

Discussion

GHT has been reported in almost every anatomical site in the GI tract and even in other unusual areas like the scrotum or mediastinum.^{4,15} GHT in the foregut is explained congenitally, as the failure of developmental descent of the stomach.¹⁶ This type of change is considered heteroplasia. However, GHT distal to the foregut is explained by the capability of the pluripotent cells in the GI tract, which can change to any type of cell, including gastric mucosa.^{16,17} Gastric metaplasia, which is defined as an acquired type of GHT, is caused by local injury or inflammation in anatomical sites other than stomach and will appear as gastric mucosa on histological examination. This is an adaptive response of the original anatomic site's cells to the injury and/or inflammation.¹ The difference between metaplasia and heteroplasia

is the presence of full mucosal thicknesses of gastric epithelium and glands in the latter; however, metaplasia usually consists of only foveolar-type epithelium mixed with the original site's tissue.¹⁸ There are no recent, relevant confirmational investigations in the literature regarding the basic pathological pathways which are involved in GHT. Per our knowledge and based on the literature review, these theories are still valid and can explain the pathophysiology of this entity.

GHT has a potential to progress to malignancy; however, the rate of malignancy is not known.^{19,20} Treatment of patients with rectal bleeding may be done using histamine-2 receptor blockers,¹⁸ although surgical/endoscopic excision is generally considered the treatment of choice and usually results in complete cure in almost all cases.³

The presence of *Helicobacter pylori* organism in GHT in rectum is a surprising feature, which may be very rarely seen in pathologic examination.¹ Dye et al.²¹ reported a successful eradication of a *Helicobacter pylori* infection in GHT in the rectum, which led to resolution of the patient's abdominal pain. No *Helicobacter pylori* was identified in our case using special immunostain for this organism (Figure 3(d)).

Despite advances in surgical pathology practice, floaters are seen on a daily basis; there is no definite way to prevent this type of artifact. The College of American Pathologists (CAP) conducted Q-Probes study in 275 laboratories on extraneous tissues in surgical pathology, which showed that

there was an extraneous tissue rate of 0.6% of slides in the prospective study and 2.9% of slides in the retrospective study.²² Since GHT in rectum is very rare, our first impression was possible artifact (floater) in our sample, and we began investigation for any possible error and also to observe all other cases on the same day to find any possible missing gastric biopsy. Once we could not find any donor for this unwanted guest in our rectal biopsy sample, we considered the possibility of GHT and ordered multiple deeper levels. Definite diagnosis was made on recut by observing mixture of both types of mucosa.

The common presentations of GHT are abdominal pain and rectal bleeding.¹ The reports suggest that men are predominantly affected (male:female = 20:7) with a median age of 18 years (range: 6 months to 51 years).¹ GHT in rectum is usually found between 5 and 8 cm from the anal verge in the posterolateral wall of this area.²³ The GHT in our case was 2 cm from the anal verge.

In a very recent systematic review by Iacopini et al., they evaluated 72 reports of GHT in rectum and anus revealing the presence of congenital malformations in 17 (24%) patients, rectal duplication responsible for most of the cases. GHT was mostly located in the anus and perianal rectum in 25 cases (41%). The lesions were mostly non-polypoid in 37 cases (51%), polypoid in 26 cases (36%) and ulcerated in 9 cases (13%). Complications were observed in 23 cases (32%). Surgical excision was the treatment of choice in 50 cases (83%); however, endoscopic resection was performed in 17 cases (34%).³

Conclusion

The heterotopic tissue refers to the presence of normal tissues at abnormal sites. Although GHT has been reported almost everywhere in the GI tract, the GHT in the rectum is very rare. Histologic examination of the biopsy from the interest area in rectum showed fragments of rectal mucosa co-mingling with oxyntic- and antral-type gastric mucosa. Important pitfall in this entity is to erroneously diagnose it as floater or contamination. Due to high frequency of having floater in some histology laboratories, we recommend ordering multiple deeper recuts on cases when pathologist sees closeness or attachment of gastric tissue to the rectal tissue. That being said, it is important for pathologists, although it is a very rare entity, to consider GHT once they observe a scenario such as ours.

Declaration of conflicting interests

The author(s) declared no potential conflicts of interest with respect to the research, authorship and/or publication of this article.

Funding

The author(s) received no financial support for the research, authorship and/or publication of this article.

Informed consent

Appropriate informed patient consent was obtained from a legally authorized representative(s) to be published in this article.

References

1. Srinivasan R, Loewenstine H and Mayle JE. Sessile polypoid gastric heterotopia of rectum: a report of 2 cases and review of the literature. *Arch Pathol Lab Med* 1999; 123(3): 222–224.
2. Ewell GH and Jackson RH. Aberrant gastric mucosa in the rectum with ulceration and hemorrhage. *Wis Med J* 1939; 38: 641–643.
3. Iacopini F, Gotoda T, Elisei W, et al. Heterotopic gastric mucosa in the anus and rectum: first case report of endoscopic submucosal dissection and systematic review. *Gastroenterol Rep* 2016; 4: 196–205.
4. Willis R. Some unusual developmental heterotopias. *Br Med J* 1968; 3(5613): 267–272.
5. Yu L, Yang Y, Cui L, et al. Heterotopic gastric mucosa of the gastrointestinal tract: prevalence, histological features, and clinical characteristics. *Scand J Gastroenterol* 2014; 49(2): 138–144.
6. Wacrenier A, Fayoux P, Augusto D, et al. Gastric heterotopia in the nasopharynx. *Int J Pediatr Otorhinolaryngol* 2002; 64(1): 65–67.
7. Picard EJ, Picard JJ, Jorissen J, et al. Heterotopic gastric mucosa in the epiglottis and rectum. *Am J Dig Dis* 1978; 23(3): 217–221.
8. Rodríguez-Martínez A, Salazar-Quero JC, Tutau-Gómez C, et al. Heterotopic gastric mucosa of the proximal oesophagus (inlet patch): endoscopic prevalence, histological and clinical characteristics in paediatric patients. *Eur J Gastroenterol Hepatol* 2014; 26(10): 1139–1145.
9. Steele SR, Mullenix PS, Martin MJ, et al. Heterotopic gastric mucosa of the anus: a case report and review of the literature. *Am Surg* 2004; 70(8): 715–719.
10. Vieth M, Kushima R, de Jonge J, et al. Adenoma with gastric differentiation (so-called pyloric gland adenoma) in a heterotopic gastric corpus mucosa in the rectum. *Virchows Arch* 2005; 446(5): 542–545.
11. Sauer CG, Bickston SJ and Borowitz SM. Gastric heterotopia of the rectum. *J Pediatr Gastroenterol Nutr* 2010; 50(3): 329–333.
12. Wiersma R, Hadley G, Govender D, et al. Rectal gastric heterotopia in infancy. *J Pediatr Surg* 2002; 37(10): 1481–1482.
13. Seitz G and Schüder G. Heterotopic gastric mucosa of the rectum. *Pathologie* 1987; 8(1): 52–55.
14. Kim HS, Kim JH and Yoon SO. Heterotopic gastric mucosa with focal intestinal metaplasia and squamous epithelium in the rectum. *Dig Endosc* 2012; 24(1): 46–48.
15. Khan MM and Fitzgerald R. Heterotopic gastric tissue in the scrotum. *J Urol* 1996; 155(6): 2061.
16. Wolff M. Heterotopic gastric epithelium in the rectum: a report of three new cases with a review of 87 cases of gastric heterotopia in the alimentary canal. *Am J Clin Pathol* 1971; 55(5): 604–616.
17. Morison JE. *Fetal and neonatal pathology*. Washington, DC: Butterworths, 1963, pp. 297–298.

18. Ok CY and Akalin A. Gastric heterotopia in the rectum. *J Med Cases* 2012; 3(2): 113–115.
19. Ko H, Park SY, Cha EJ, et al. Colonic adenocarcinoma arising from gastric heterotopia: a case study. *Korean J Pathol* 2013; 47(3): 289–292.
20. Christensen WN and Sternberg SS. Adenocarcinoma of the upper esophagus arising in ectopic gastric mucosa: two case reports and review of the literature. *Am J Surg Pathol* 1987; 11(5): 397–402.
21. Dye KR, Marshall BJ, Frierson HF, et al. Campylobacter pylori colonizing heterotopic gastric tissue in the rectum. *Am J Clin Pathol* 1990; 93(1): 144–147.
22. Gephardt GN and Zarbo RJ. Extraneous tissue in surgical pathology: a College of American Pathologists Q-Probes study of 275 laboratories. *Arch Pathol Lab Med* 1996; 120(11): 1009–1014.
23. Nakanishi Y and Merenda G. Heterotopic fundic and pyloric-type gastric mucosa in the rectum presented as a foveolar hyperplastic polyp. *Case Rep Clin Pathol* 2014; 2(2): 47–50.