



## Optical coherence tomography findings of cyanoacrylate glue patch in corneal perforations

Eduardo J. Polania-Baron, Eduardo Gonzalez-Lubcke, Enrique O. Graue-Hernandez, Arturo Ramirez-Miranda, Alejandro Navas\*

Department of Cornea, External Diseases and Refractive Surgery, Institute of Ophthalmology "Conde de Valenciana", Mexico City, Mexico

### ARTICLE INFO

#### Keywords:

Corneal perforation  
Cyanoacrylate glue patch  
Optical coherence tomography

### ABSTRACT

**Purpose:** To report a cases series of corneal perforations treated with cyanoacrylate glue patch (CGP) assessed with optical coherence tomography for monitoring corneal status in long-term follow-up examinations.

**Observations:** CPG was successfully used as primary treatment in three cases of corneal perforations. Spontaneous loosening or dislodging of the CPG did not occur in the follow-up. Anterior segment optical coherence tomography (AS-OCT) was performed to monitor wound healing at the site of perforation before considering the CPG removal. The presence of normal epithelium layer beneath the glue patch and stromal regeneration tissue were confirmed by AS-OCT, and glue patch was safely removed.

**Conclusions and importance:** The area of healing tissue beneath the CGP may not be easy to evaluate using the slit-lamp microscopy alone. AS-OCT is a useful tool in the assessment of corneal healing tissue in the presence of cyanoacrylate glue patch.

### 1. Introduction

Corneal perforation is an ophthalmic emergency that requires urgent management. The goal of treatment of corneal perforations is to restore globe integrity and allow healing of the defect to make the cornea amenable for future visual rehabilitation. Corneal glueing with cyanoacrylate glue patch (CPG) is the most commonly described technique to manage small perforations.<sup>1</sup>

Since cyanoacrylate material is non-biodegradable, potentially toxic and pro-inflammatory, is considered a temporary measure and should be removed at some point. The timing of CPG removal is still a controversial subject. Moreover, the area of healing tissue beneath the CPG may not be easy to evaluate using the slit-lamp microscopy.<sup>2</sup>

Anterior segment optical coherence tomography (AS-OCT) is extremely valuable in studying anterior segment pathology involving cornea. Particularly, AS-OCT is useful for assessment of the area of the actual stromal thickness and healing tissue in cases of corneal injury.<sup>3</sup>

The purpose of this study is to describe AS-OCT findings in corneal perforations treated with CPG application.

### 2. Findings

Three patients were diagnosed with corneal perforation using slit-lamp examination, which revealed Seidel's positive sign at the outset. The cause of corneal perforation was ocular trauma in 1 eye, and stromal herpetic keratitis in 2 eyes. In all patients, informed consent was obtained and a cyanoacrylate glue patch procedure was achieved.

The procedures were performed under topical anesthesia using 0.5% tetracaine eye drops. First, a single 3 mm diameter disc was cut from a sterile surgical plastic drape using a 3 mm skin trephine. The epithelium surrounding the corneal perforation was removed manually with scalpel blade or a microsponge. After the healthy corneal stroma was exposed and the ocular surface was dry, a small amount of N-butyl-cyanoacrylate was applied to the center of the disc, followed by the application of the glue patch (plastic disc + cyanoacrylate) directly in the area of corneal perforation. Finally, a therapeutic contact lens was placed. This successfully sealed the corneal perforation, resulting in cessation of aqueous leakage and adequate anterior chamber depth after 30 minutes. Patients were followed-up daily with slit-lamp examinations after the CPG procedure for the first week and thereafter as needed.

High resolution AS-OCT using the Triton Swept-source OCT (Topcon) was performed to monitor wound healing at the site of perforation

\* Corresponding author. Chimalpopoca 14, Colonia Obrera, Mexico City, 06800, Mexico.

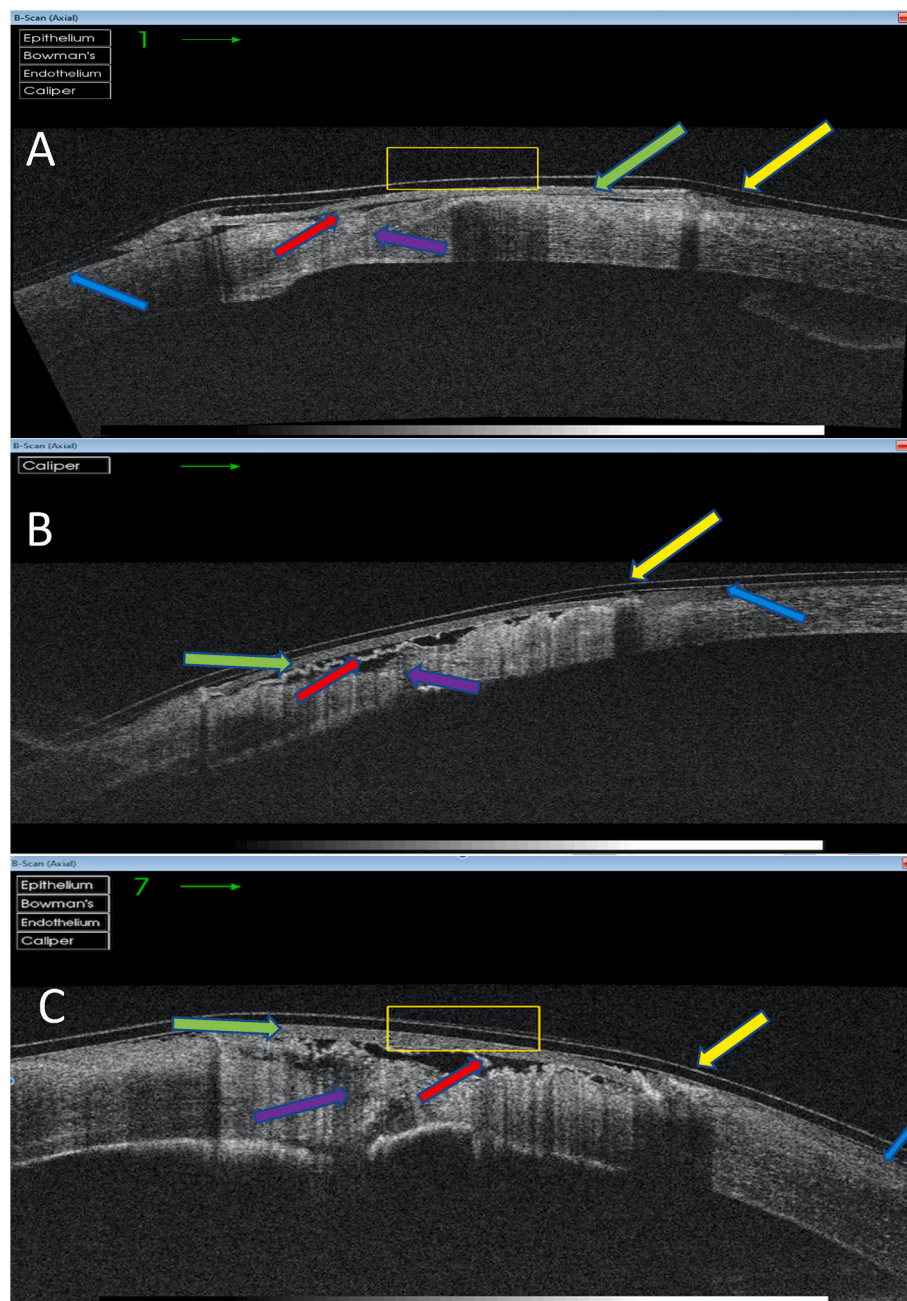
E-mail address: [dr.alejandronavas@gmail.com](mailto:dr.alejandronavas@gmail.com) (A. Navas).

<https://doi.org/10.1016/j.ajoc.2022.101576>

Received 5 November 2020; Received in revised form 18 April 2022; Accepted 4 May 2022

Available online 13 May 2022

2451-9936/© 2022 Published by Elsevier Inc. This is an open access article under the CC BY-NC-ND license (<http://creativecommons.org/licenses/by-nc-nd/4.0/>).



**Fig. 1.** Imaging of corneal healing tissue and cyanoacrylate glue patch with anterior segment optical coherence tomography. Cross-sectional image in patients with corneal perforation due to wire trauma (A) and stromal herpetic keratitis (B, C) reveals a bandage contact lens in situ (yellow arrow). Plastic disc and cyanoacrylate material are visible under de bandage contact lens (arrowhead). Similarly, normal epithelium layer (asterisk) and stromal regeneration tissue (cross mark) are also visible below the glue patch. Time of OCT acquisition were 8, 4 and 9 months after GCP placement, respectively. (For interpretation of the references to colour in this figure legend, the reader is referred to the Web version of this article.)

before considering the CGP removal. Cross-sectional OCT scans were carried out through the area of the corneal perforation, with the scanning beam running through the meridian that crossed the center of the perforation.

**Case 1.** A 40-year-old male with a history of wire trauma in his left eye presented with a 2 mm central corneal perforation. A CGP was used as initial management, followed by topical medication. After 8 months, the patch remained in its place. The AS-OCT showed bandage contact lens, plastic disc and cyanoacrylate material, normal epithelium layer underneath the patch and stromal regeneration tissue (Fig. 1-A).

**Case 2.** A 64-year-old female with a history of stromal herpetic keratitis presented with a 1 mm temporal corneal perforation in the right eye. The patient was treated with a CGP and oral valacyclovir. After 4 months, the AS-OCT displayed the bandage contact lens, plastic disc and cyanoacrylate material, epithelium and corneal healing tissue underneath the patch (Fig. 1-B).

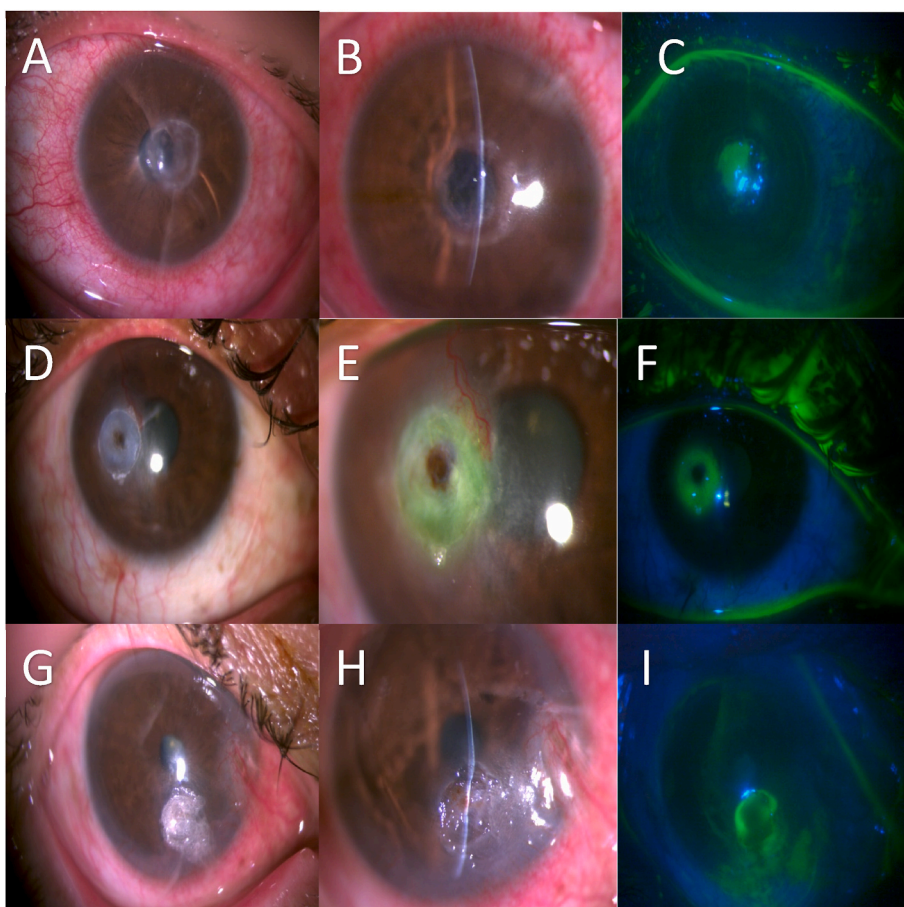
**Case 3.** A 38-year-old male with a history of stromal herpetic keratitis in the right eye presented with a 2 mm inferior corneal perforation. He was treated with CGP and oral valacyclovir. At 9 months follow-up, the patch remained in place. AS-OCT imaging confirmed bandage contact lens, plastic disc with cyanoacrylate material, epithelium and stromal regeneration tissue (Fig. 1-C).

All patients underwent a single CGP application. Spontaneous loosening or dislodging of the glue patch did not occur. In all cases the patch was successfully removed after AS-OCT assessment (Fig. 2). None of the eyes required re-application or additional surgical procedures for tectonic purposes.

### 3. Discussion

In the event of severe stromal thinning or corneal perforation, urgent intervention is needed to maintain anatomical integrity. The use of





**Fig. 2.** Slit-lamp biomicroscopy of all three patients. Postglueing clinical appearance of the cornea of **case 1** (A), **case 2** (D) and **case 3** (G) at 8, 4 and 9 months, respectively.

After patch extraction, corneal regeneration tissue is observed in all cases (B, E, H) with a negative Seidel test assessed with fluorescein dye and cobalt blue light (C, F, I). (For interpretation of the references to colour in this figure legend, the reader is referred to the Web version of this article.)

cyanoacrylate glue is the most common method described.<sup>4</sup> This procedure has become the initial treatment of choice for small corneal perforation because it is easily available and cost effective compared with procedures like amniotic membrane or corneal transplantation.<sup>5</sup>

The CGP normally is allowed to dislodge spontaneously, although, cyanoacrylate is known to adhere to a wound site for a long period given its nonbiodegradability.<sup>6</sup> Complications associated with CGP have been reported, including increased ocular surface inflammation, corneal neovascularization and giant papillary conjunctivitis.<sup>7</sup> Therefore, CGP should be considered a transitory measure and removal is required.

Controversy still surrounds the issue of selecting proper timing for CGP removal. Some authors have recommended the removal of glue patch if still present at 3–5 weeks, however, there is no clear consensus on optimal timing for patch withdrawal.<sup>8</sup>

Because cyanoacrylate is not biocompatible and does not allow cells to grow on it, consequently, all healing and re-epithelialization occur beneath the glue. The area of healing tissue under the patch may not be easy to properly evaluate using the slit-lamp alone.<sup>9</sup>

To determine morphological changes of the cornea, AS-OCT has been found to be useful. AS-OCT can provide noninvasive evaluation, allowing for real-time imaging of all corneal structures, including the epithelium, stromal thickness and even wound healing process.<sup>9,10</sup>

Utsunomiya and colleagues observed that after corneal stromal thinning, AS-OCT showed epithelial hypertrophy and hyperplasia in the affected area; subsequently, scar tissue formed with an improvement in the thickness of the corneal stroma. The scar tissue gradually appeared clear on slit-lamp examination; however, the high signal on AS-OCT remained.<sup>11</sup> In a recent study with corneal perforations, postglueing AS-OCT showed a dense hyperreflective band corresponding to the glue and the plastic disc; in all cases stroma and epithelial healing occurred beneath the glue and were replaced by scar tissue.<sup>12</sup> In our case series,

both the CGP material and the regeneration tissue were properly acknowledged with OCT imaging.

Potential limitations resulting from image artefacts due to factors such as scarring, oedema and the CGP itself can potentially impair the OCT signal quality in more posteriorly located tissue layers, with shadowing posterior to the glue. Nevertheless, our observations using high resolution AS-OCT provided appropriate assessment of cornea status beneath the CGP, showing re-epithelialization, stromal thickness and healing tissue.

**Conclusions:** The area of healing tissue beneath the CGP may not be easy to evaluate using traditional methods. AS-OCT allows the visualization of corneal healing tissue in the presence of cyanoacrylate glue patch, allowing for a more precise follow up, supporting to decide the proper timing for glue patch removal. Additionally, OCT might be used to consider another surgical procedure in the absence of corneal healing.

#### Patient consent statement

Written informed consent to publish these cases were not obtained, although all three patients provided oral consent for publication. This report does not contain any personal information that could lead to identification of the patients.

#### Funding

No funding or grant support.

#### Authorship

All authors attest that they meet the current ICMJE criteria for Authorship.

### CRedit authorship contribution statement

**Eduardo J. Polania-Baron:** Conceptualization, Methodology, Writing – original draft. **Eduardo Gonzalez-Lubcke:** Data curation, Software, Writing – review & editing. **Enrique O. Graue-Hernandez:** Resources, Visualization. **Arturo Ramirez-Miranda:** Investigation, Supervision. **Alejandro Navas:** Formal analysis, Validation, Project administration.

### Declaration of competing interest

The authors have no financial disclosures (EP, EGH, ARM, EG, AN).

### Acknowledgments

None.

### References

- Khalifa YM, Bailony MR, Bloomer MM, et al. Management of nontraumatic corneal perforation with tectonic drape patch and cyanoacrylate glue. *Cornea*. 2010;29:1173–1175.
- Singh RB, Zhu S, Yung A, Dohlman TH, Dana R, Yin J. Efficacy of cyanoacrylate tissue adhesive in the management of corneal thinning and perforation due to microbial keratitis. *Ocul Surf*. 2020;18(4):795–800.
- Ang M, Baskarana M, Werkmeister RM, et al. Anterior segment optical coherence tomography. *Prog Retin Eye Res*. 2018;66:132–156.
- Anchouche S, Harissi-Dagher M, Segal L, Racine L, Darvish-Zargar M, Robert MC. Cyanoacrylate tissue adhesive for the treatment of corneal thinning and perforations: a multicenter study. *Cornea*. 2020;39(11):1371–1376.
- Yin J, Singh RB, Al Karmi R, Yung A, Yu M, Dana R. Outcomes of cyanoacrylate tissue adhesive application in corneal thinning and perforation. *Cornea*. 2019;39(6):668–673.
- Setlik DE, Seldomridge DL, Adelman RA, et al. The effectiveness of isobutyl cyanoacrylate tissue adhesive for the treatment of corneal perforations. *Am J Ophthalmol*. 2005;140:920–921.
- Sharma A, Kaur R, Kumar S, et al. Fibrin glue versus N-butyl-2-cyanoacrylate in corneal perforations. *Ophthalmology*. 2003;110(2):291–298. Feb.
- Leahey AB, Gottsch JD, Stark WJ. Clinical experience with N-butyl cyanoacrylate (nexacryl) tissue adhesive. *Ophthalmology*. 1993;100:173–180.
- Konstantopoulos A, Kuo J, Anderson D, Hossain P. Assessment of the use of anterior segment optical coherence tomography in microbial keratitis. *Am J Ophthalmol*. 2008;146(4):534–542. Oct.
- Siebelmann S, Scholz P, Sonnenschein S, et al. Anterior segment optical coherence tomography for the diagnosis of corneal dystrophies according to the IC3D classification. *Surv Ophthalmol*. 2018;63(3):365–380.
- Utsunomiya T, Hanada K, Muramatsu O, Ishibazawa A, Nishikawa N, Yoshida A. Wound healing process after corneal stromal thinning observed with anterior segment optical coherence tomography. *Cornea*. 2014;33(10):1056–1060.
- AlMaazmi A, Said DG, Messina M, AlSaadi A, Dua HS. Mechanism of fluid leak in non-traumatic corneal perforations: an anterior segment optical coherence tomography study. *Br J Ophthalmol*. 2020;104(9):1304–1309. Sep.