

CASE REPORT

A rare case of acquired factor V inhibitor, during treatment with dabigatran for chronic atrial fibrillation, successfully treated with bypassing agents

Gaetano Giuffrida^{1,2}  | Uros Markovic^{1,2}  | Daniela Nicolosi^{1,2} | Valeria Calafiore^{1,2}

¹Division of Hematology, AOU “Policlinico - Vittorio Emanuele”, Catania, Italy

²Department of General Surgery and Medical-Surgical Specialties, Hematology Section, University of Catania, Catania, Italy

Correspondence

Gaetano Giuffrida, UOC di Ematologia con Trapianto di Midollo Osseo, AOU “Policlinico – Vittorio Emanuele”, Via Santa Sofia 78, Catania, Italy.
Email: gaegiuffrida@gmail.com

Funding information

The editorial assistance was provided by Ethos SRL through an unconditional grant. The authors of the publication are fully responsible for the contents and conclusions. Ethos SRL did not influence and has not been involved in the data interpretation presented in the manuscript.

Abstract

Acquired factor V inhibitor represents a rare condition, described only in case reports. The use of activated bypassing agents in bleeding control could be of aid and improve the survival in symptomatic patients with acquired factor V inhibitor.

KEYWORDS

acquired coagulation inhibitor, bypassing agents, dabigatran, factor V, immunosuppressive therapy

1 | INTRODUCTION

A 68-year-old woman treated with dabigatran for chronic atrial fibrillation presented with hematomas and hematuria. Given the alteration of coagulation tests, not corrected by plasma-mixing study, decreased activity of factor V confirmed acquired factor V inhibitor. She was successfully treated with activated prothrombin complex concentrate, steroids, and cyclophosphamide.

Acquired coagulation factor V (FV) inhibitors represent a rare form of coagulation factor inhibitors, with an estimated incidence of 0.09–0.29 for 1 million persons per year.^{1,2} However, given the extremely variable clinical presentation, ranging from asymptomatic coagulation abnormalities to

potentially life-threatening bleeding, a substantial proportion of asymptomatic patients are likely to remain undiagnosed.²

FV is a part of the common coagulation pathway. It acts as a cofactor, binding the activated factor X (FXa) to the platelet surface, and subsequently accelerating the prothrombin conversion. Factor V inhibitors are polyclonal IgG antibodies that interfere with the binding of activated platelets, through its light chain C2 domain. By blocking the C2 domain the inhibitors interfere with the common pathway, leading to prolongation of both prothrombin time (PT) and activated partial thromboplastin time (aPTT).^{3,4} The possible causes of acquired factor V inhibitors (AFVI) are as follows: (a) exposure to bovine proteins, (b) infections, (c) medications (especially antibiotics), (d) association to other medical conditions

This is an open access article under the terms of the Creative Commons Attribution-NonCommercial-NoDerivs License, which permits use and distribution in any medium, provided the original work is properly cited, the use is non-commercial and no modifications or adaptations are made.

© 2020 The Authors. *Clinical Case Reports* published by John Wiley & Sons Ltd.

(autoimmune disorders, cancer), and (e) surgical procedures. In up to 30% of cases, AFVI is idiopathic.^{1,3,5,6} Spontaneous autoantibodies, alloantibodies, and cross-reacting anti-bovine factor V antibodies have been hypothesized as possible mechanisms of inhibitor development. However, the actual mechanisms remains unknown.⁵

Dabigatran etexilate methanesulfonate (DEM) is a novel oral anticoagulant that suppresses fibrin formation through direct and selective inhibition of thrombin activity, with anticoagulant and antithrombotic effects. It is generally used in primary prevention of venous thromboembolic events and to reduce the risk of stroke and systemic embolism in patients with nonvalvular atrial fibrillation.

Here, we describe a case of a patient that developed AFVI with diffuse hematomas, hematuria, and severe anemia following treatment with dabigatran. The patient was successfully treated with activated coagulant complex bypassing agents, steroids, and cyclophosphamide therapy. To the best of our knowledge, this is the second case report describing AFVI after DEM therapy.

2 | CASE REPORT

A 68-year-old woman presented in October 2018 to the emergency department with a one-month history of diffuse hematomas and two-week history of intense hematuria. Her medical history included type 2 diabetes mellitus, hypertension treated with oral pharmacological therapy, and chronic atrial fibrillation. The patient has been treated with novel oral anticoagulant (NOAC) DEM at 220 mg/day, in prophylaxis. Two months prior to emergency department admission the first signs of subcutaneous hematomas appeared. Six weeks later, after hematuria onset, dabigatran was switched to low molecular weight heparin (LMWH), without major clinical improvement.

The patient presented with diffuse hematomas, especially in the lower extremities (Figure 1), and intense hematuria. She was conscious and oriented with normal vital signs, except for rhythmic tachycardia (pulse of 115/min), with no abnormal neurological or other findings. The results of emergency laboratory tests revealed the presence of severe anemia (Hb 4.1 g/dL, reference value (r.v.) 11.7–16 g/dL), together with important prolongation of both international normalized ratio (INR; 6.48, r.v. 0.8–1.2) and aPTT (>180 s, r.v. 24–36 s), while the platelet count, LDH, and D-dimer levels were all in normal range (Table 1). The patient was hospitalized, and supportive therapy with red blood cell transfusion and fresh-frozen plasma (FFP), together with intravenous (iv) vitamin K administration, was immediately started.

Due to a lack of clinical response and coagulopathy correction with supportive therapy, a plasma-mixing study for both PT and aPTT was performed, demonstrating the absence

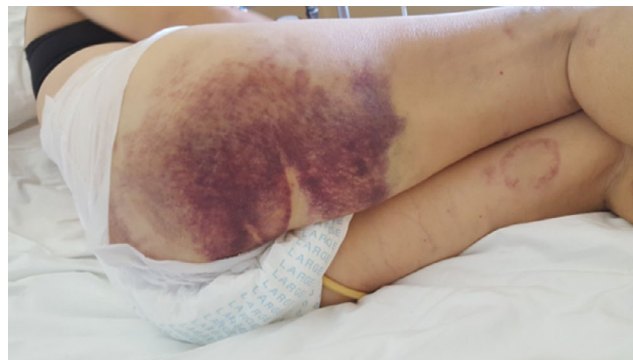

FIGURE 1 Clinical manifestation of bleeding symptoms (lower extremity subcutaneous hematoma) in a patient with acquired factor V inhibitors

of correction after 2 hours of incubation. The screening for autoimmune disorders, tumor markers, and antiphospholipid syndrome tested all negative (Table 1). On the other hand, the measurement of the coagulation factor profile revealed severely decreased factor V activity (0.1%, r.v. 60%–140%), with the remaining coagulation factors within normal range (Table 2). The modified Bethesda method revealed the presence of factor V inhibitors (1.94 Bethesda U/ml).

Acquired factor V inhibitor (AFVI) was diagnosed and likely caused by dabigatran therapy. The patient's clinical course after admission is shown in Figure 2. Considering the clinical presentation, the patient was treated for both bleeding control and inhibitor eradication. Regardless of supportive therapy, the patient remained anemic and transfusion-dependent, with persistent alteration of both PT and aPTT, while the platelet count remained within normal range. Therefore, treatment with activated prothrombin complex concentrates (APCC) bypassing agent was started (70 UI/kg, twice a day), in order to overlap the FV deficit in the common coagulation pathway. As for the inhibitor eradication, corticosteroid therapy with methylprednisolone 1 mg/kg daily and immunosuppressive therapy with cyclophosphamide 2 mg/kg daily were initiated. Approximately two days later, the bleeding symptoms and the results of coagulation tests started improving, and the patient was no longer transfusion-dependent. Following the resolution of bleeding symptoms and anemia, associated with a relevant increase in FV activity (16.6%) and the disappearance of FV inhibitors, APCC was first reduced and eventually stopped. In November 2018, the patient was discharged, on steroid therapy with the same dosage, while cyclophosphamide was reduced to 1 mg/kg daily.

Unfortunately, approximately two weeks later, the patient presented once again to the emergency department, accusing malaise, asthenia, and skin pallor, with no signs of bleeding. The results of emergency laboratory tests revealed high N-terminal pro-brain natriuretic peptide (NT-proBNP) levels, while coagulation tests and complete blood count (CBC) were within range. Anti-factor V inhibitors were negative.

TABLE 1 Laboratory findings of the emergency laboratory tests

Complete Blood Count	
WBC	9320/ μ L
RBC	1.49 x 10⁶/μL \downarrow (3.7-5.1) ^a
Hb	4.1 g/dL \downarrow (11.7-16) ^a
Ht	13.2% \downarrow (36-48)
MCV	89 fL
MCH	27.8 pg
Plt	237 x 10 ³
Coagulation	
PT	71.3 sec \uparrow (11-13) ^a
PT activity	11% \downarrow (70-130) ^a
PT-INR	6.48 \uparrow (0.8-1.2) ^a
aPTT	>180 sec \uparrow (28-40) ^a
Fbg	589 mg/dL \uparrow (170-450)
AT III	145% \uparrow (75-125)
D-dimer	405 μ g/mL \uparrow (0-250)
Biochemistry	
AST	32 U/L
ALT	20 U/L
LDH	185 U/L
γ -GTP	18 U/L
T-Bil	0.54 mg/dL
Cr	0.94 mg/dL
Immuno-serological findings	
Antinuclear Ab	negative
Anticardiolipin Ab	negative
Anti-CL β 2GP1 Ab	negative
Lupus AC	negative
Tumor markers	
CEA	0.3 ng/mL
CA 15-3	5 U/mL
CA 125	6 U/mL

Note: Altered parameters are in bold; \uparrow and \downarrow indicate values higher and lower than normal ranges, respectively. Normal ranges are shown in parentheses.

^aAltered values.

Electrocardiogram revealed an episode of atrial fibrillation. Therefore, the patient was successfully treated with digoxin and received prophylaxis with clopidogrel and acetylsalicylic acid. Given the high risk of ischemic stroke and possible recurrence of factor V inhibitor during continuative use of other NOACs (apixaban, rivaroxaban, edoxaban), after a cardiologic consult as part of conclusive stroke prevention, the patient underwent percutaneous left atrial appendage closure. The patient was subsequently monitored until the beginning

of December 2018, when she was finally discharged. During this period, the patient continued steroid and immunosuppressive therapy. The follow-up visits confirmed complete normalization of both the results of coagulation tests and factor V levels, with negative FV inhibitors. Therefore, prior to dose tapering, first the steroid therapy and later the cyclophosphamide were stopped, with no inhibitor recurrence. The patient is currently doing well, without other hemorrhagic manifestations.

TABLE 2 Dosage of coagulation factors

Coagulation factor assay	
Factor II	70.5%
Factor V	0.1% (60-140)^a
Factor VII	61.5%
Factor VIII	138.1%
Factor IX	153.8%
Factor X	76.4%
Factor XI	91.1%
Factor XII	76.3%

Note: Altered parameter is in bold; ↓ indicates values lower than normal range; normal range is shown in parentheses.

^aAltered value.

3 | DISCUSSION

AFVI represents an extremely rare bleeding disorder. The etiopathogenesis of the disease remains unknown. The main historical cause of AFVI was the development of iatrogenic alloantibody after exposure to bovine thrombin, used during surgical procedures.⁷ Retrospective data were collected from several reviews on AFVI cases described in literature without the history of bovine thrombin exposure. The most common associated factors were drugs, especially antibiotics (β -lactams, aminoglycosides, quinolones, etc), but there were

also anecdotal cases in course of warfarin and amiodarone therapy. Other described causes were surgical procedures, infections, malignancies, and autoimmune disease, with around 20%-30% of cases remaining idiopathic.^{1,5,6} However, given the common presence of the above-mentioned conditions and medications in the general population, alone or in association, it is difficult to prove the relationship with the inhibitor onset. One other AFVI case during DEM therapy was previously described, with the presentation of only mild bleeding manifestation (subcutaneous ecchymoses) and the patient was treated with steroids.⁸ In our case, the patient developed diffuse hematomas, hematuria, and consequential severe anemia, successfully treated with bypassing agents.

Unlike with other coagulation inhibitors, the level of FV does not correlate with the degree of hemorrhagic manifestation, ranging from asymptomatic carriers to fatal outcomes, in 14%-31% of cases.⁶ Therefore, a substantial number of patients without bleeding symptoms are unaware of the condition, thus the actual incidence of the coagulopathy is probably much higher.² In symptomatic patients, simultaneous multiple bleeding sites were involved in about one-third of patients. The most common bleeding presentation included mucous membranes (ie, gastrointestinal, genitourinary, and upper airway tracts), with hematuria being one of the most frequent clinical manifestations. Other sites like subcutaneous hematomas, bleeding after surgical procedures, retroperitoneal, and intracranial hemorrhages were present less frequently, with cerebral hemorrhage

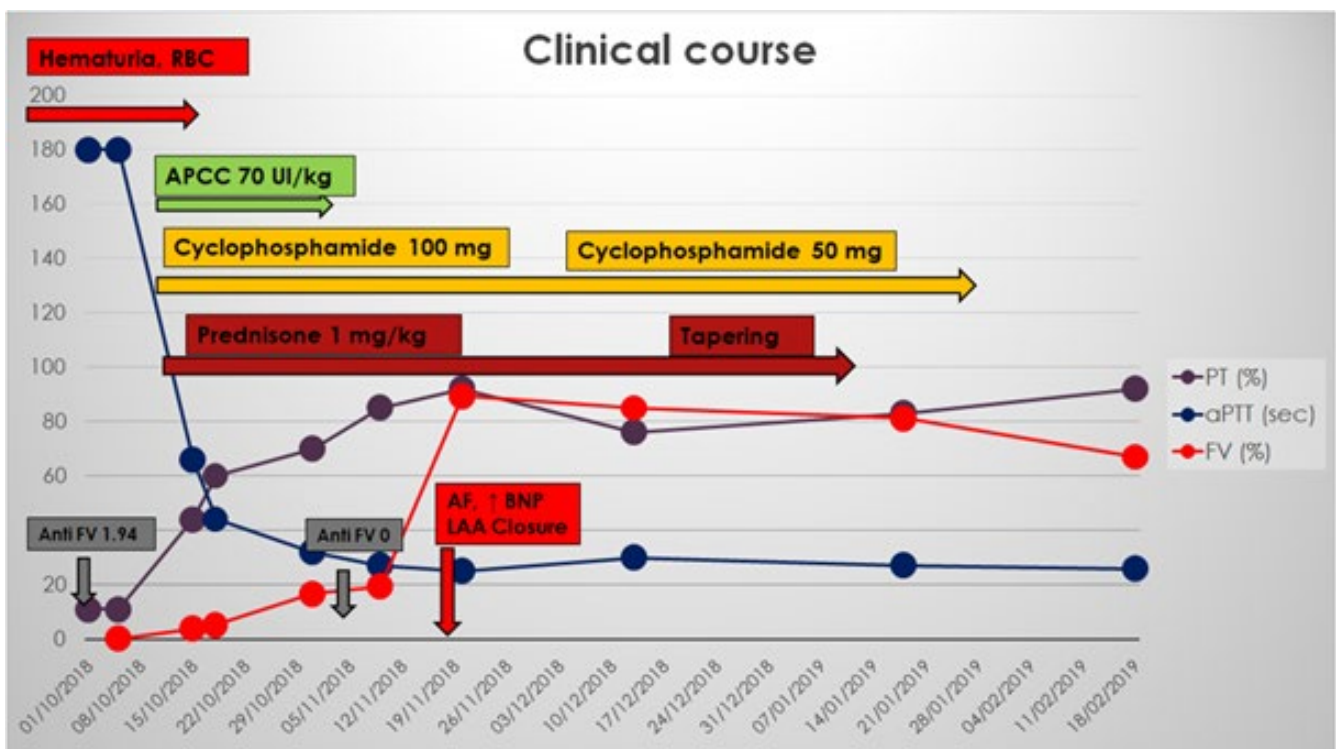


FIGURE 2 Clinical course and laboratory features of the patient with acquired factor V inhibitor. (PT—prothrombin time; aPTT—activated partial thromboplastin time; FV—factor V; RBC—red blood cell transfusion; APCC—activated prothrombin complex concentrates; AF—atrial fibrillation; BNP—N-terminal pro-brain natriuretic peptide; LAA—left atrial appendage)

having the highest mortality rate.^{1,5,6} In our case, the subcutaneous hematomas appeared first and were later accompanied by hematuria, without improvement of clinical and coagulation status, even after dabigatran suspension.

Given the rarity of AFVI and extremely limited evidence, supported only by case reports, symptomatic patients pose a remarkable challenge for prompt diagnosis and treatment. A diagnostic algorithm was proposed for patients with bleeding and prolonged PT/aPTT by Cadamuro et al, after performing a plasma-mixing test. In the absence of PT/aPTT correction, with fibrinogen and thrombin time (TT) in the normal range, the differential diagnosis excludes all coagulation inhibitors except for FX and FV inhibitor. The diagnosis is confirmed with coagulation factor measurement and modified Bethesda method, but the appropriate treatment can be initiated even before.⁹

The treatment of AFVI is indicated only for patients with hemorrhagic manifestations and consists of two phases: bleeding control and eradication of FV inhibitors. Bleeding control and its timing in symptomatic patients is of extreme importance, given the high risk of fatal outcome. A number of treatment options (ie, fresh-frozen plasma, platelet transfusions, bypassing agents like activated prothrombin complex concentrates, and recombinant activated factor VII (rFVIIa)) have been used to achieve hemostasis with inconsistent success.^{1,5,6} In this case, after the diagnostic follow-up, during which the patient was treated with FFP and vitamin K without major success, the patient was started on bypassing agent, given the normal platelet count and blockage of prothrombin complex by the FV inhibitor. The choice between APCC and rFVIIa was based on current hospital availability.

Different treatment approaches for inhibitor eradication have been reported. Immunosuppression with steroids has high success rates, alone or in combination with cyclophosphamide, cyclosporine, or azathioprine. Anti-CD20 monoclonal antibody rituximab is also an option as second-line treatment. Intravenous immunoglobulin and therapeutic plasma exchange may also be used as adjunct or alternative treatments.^{1,5,6} Given the patient's conditions and severe bleeding associated with anemia, a multimodality approach was started. The patient was started on combination therapy with steroids and cyclophosphamide, together with APCC for bleeding control. After a couple of days, both the clinical and the coagulation status improved significantly.

Atrial fibrillation represents the most common arrhythmia and accounts for approximately 20% of stroke cases, with a 5-fold increased risk of stroke.¹⁰ Prevention of thromboembolic complications represents the cornerstone of atrial fibrillation treatment and is based on oral anticoagulation therapy. With the development of NOACs, like dabigatran, rivaroxaban, apixaban, and edoxaban, direct thrombin, or factor X inhibitors, the use of vitamin K antagonists is in decline.^{11,12} However, over the last decade, percutaneous closure of left

atrial appendage closure (LAAC) proved effective in reducing thromboembolic complications in patients with oral treatment contraindications.^{13,14} The 5-year outcome of both the PREVAIL and PROTECT prospective randomized trials demonstrated that LAAC provided comparable stroke reduction compared to warfarin, with an additional reduction in major bleeding, in particularly hemorrhagic stroke.¹⁵ There is an ongoing prospective randomized trial comparing LAAC vs NOACs [NCT02426944].

Although no cases describing AFVI development following direct FX inhibitor oral therapy were published so far, the possibility of inhibitor recurrence could not be excluded. Our patient after suspending dabigatran was off-therapy for one month, until November 2018, when she had the latest episode of atrial fibrillation. Given the prospect of lifelong therapy with other NOACs as stroke prevention, after cardiologic consultation, percutaneous LAAC was performed, due to a comparably low risk of future thromboembolic complications.

4 | CONCLUSIONS

Acquired factor V inhibitor represents a rare condition, described only as case reports and in retrospective reviews. There is limited knowledge in the diagnosis, management, and treatment, with conflicting experiences. To the best of our knowledge, this is the second case report of AFVI caused by dabigatran treatment. However, unlike the first case, it was characterized by important bleeding manifestation and successfully treated with bypassing agents. We believe that the diagnosis can be achieved relatively quickly, using the appropriate algorithm. Furthermore, based on our experience, the use of activated bypassing agents in bleeding control could be of aid and improve the survival in symptomatic patients. Lastly, the choice of prophylaxis in patients with atrial fibrillation can be made among other NOACs or percutaneous LAAC, given their high efficacy in preventing thromboembolism, although inhibitor recurrence cannot be excluded without further data.

ACKNOWLEDGMENTS

The authors acknowledge Alessandro Lico (Ethos SRL, Rome, Italy) for his support in medical writing and editorial assistance. Published with written consent of the patient.

CONFLICT OF INTEREST

The authors stated that they had no interests which might be perceived as posing a conflict or bias.

AUTHOR CONTRIBUTIONS

All authors have made substantial contributions to all of the following: VC: obtained patient consent, collected initial

data, and critically revised the manuscript. UM: interpreted data and wrote the first and final draft of the manuscript. DN: involved in the acquisition of data, analysis, and interpretation of data. GG: critically revised the article for important intellectual content and approved the final version for submission.

ETHICAL STATEMENT

Informed consent was obtained from the patient regarding the report of her clinical scenario data in an anonymous way.

DATA AVAILABILITY STATEMENT

Data sharing not applicable to this article as no datasets were generated or analyzed during the current study.

ORCID

Gaetano Giuffrida  <https://orcid.org/0000-0003-4947-3338>

Uros Markovic  <https://orcid.org/0000-0003-0868-5676>

REFERENCES

1. Ang AL, Kuperan P, Ng CH, Ng HJ. Acquired factor V inhibitor. A problem-based systematic review. *Thromb Haemost.* 2009;101(5):852-859.
2. Favaloro EJ, Posen J, Ramakrishna R, et al. Factor V inhibitors: rare or not so uncommon? A multi-laboratory investigation. *Blood Coagul Fibrinolysis.* 2004;15(8):637-647.
3. Olson NJ, Ornstein DL. Factor V Inhibitors: A Diagnostic and Therapeutic Challenge. *Arch Pathol Lab Med.* 2017;141(12):1728-1731.
4. Ortel TL, Moore KD, Quinn-Allen MA, et al. Inhibitory anti-factor V antibodies bind to the factor V C2 domain and are associated with hemorrhagic manifestations. *Blood.* 1998;91(11):4188-4196.
5. Boland F, Shreenivas AV. Acquired Factor V Inhibitors: A Review of Literature. *Ann Hematol Oncol.* 2017;4(9):1168.
6. Franchini M, Lippi G. Acquired factor V inhibitors: a systematic review. *J Thromb Thrombolysis.* 2011;31(4):449-457.
7. Streiff MB, Ness PM. Acquired FV inhibitors: a needless iatrogenic complication of bovine thrombin exposure. *Transfusion.* 2002;42(1):18-26.
8. Sekiguchi Y, Yoshikawa H, Shimada A, et al. Acquired factor v inhibitor developing after treatment with dabigatran etexilate methanesulfonate: a case report and review of the literature. *Indian J Hematol Blood Transfus.* 2014;30(suppl 1):275-279.
9. Cadamuro J, Skocic M, Meisl B, et al. A diagnostic algorithm for the detection of inhibitors against coagulation Factor V. *Clin Chem Lab Med.* 2016;54(7):e203-206.
10. Zoni-Berisso M, Filippi A, Landolina M, et al. Frequency, patient characteristics, treatment strategies, and resource usage of atrial fibrillation (from the Italian Survey of Atrial Fibrillation Management [ISAF] study). *Am J Cardiol.* 2013;111(5):705-711.
11. January CT, Wann LS, Calkins H, et al. 2019 AHA/ACC/HRS Focused Update of the 2014 AHA/ACC/HRS Guideline for the Management of Patients With Atrial Fibrillation: A Report of the American College of Cardiology/American Heart Association Task Force on Clinical Practice Guidelines and the Heart Rhythm Society. *J Am Coll Cardiol.* 2019;74(1):104-132.
12. Lip GYH. The safety of NOACs in atrial fibrillation patient subgroups: A narrative review. *Int J Clin Pract.* 2019;73(2):e13285.
13. Boersma LV, Ince H, Kische S, et al. Efficacy and safety of left atrial appendage closure with WATCHMAN in patients with or without contraindication to oral anticoagulation: 1-Year follow-up outcome data of the EWOLUTION trial. *Heart Rhythm.* 2017;14(9):1302-1308.
14. Glikson M, Wolff R, Hindricks G, et al. EHRA/EAPCI expert consensus statement on catheter-based left atrial appendage occlusion - an update. *Europace.* 2019;15(13):1133-1180.
15. Reddy VY, Doshi SK, Kar S, et al. 5-Year Outcomes After Left Atrial Appendage Closure: From the PREVAIL and PROTECT AF Trials. *J Am Coll Cardiol.* 2017;70(24):2964-2975.

How to cite this article: Giuffrida G, Markovic U, Nicolosi D, Calafiore V. A rare case of acquired factor V inhibitor, during treatment with dabigatran for chronic atrial fibrillation, successfully treated with bypassing agents. *Clin Case Rep.* 2021;9:623–628. <https://doi.org/10.1002/ccr3.3586>