



## An instance of excellent response of subcutaneous zygomycosis to itraconazole monotherapy

Priyadarshini Patro<sup>a</sup>, Padma Das<sup>a,\*</sup>, Divya Sachdev<sup>b</sup>, Nitinkumar Borkar<sup>c</sup>, Satyaki Ganguly<sup>b</sup>, Nighat Hussain<sup>d</sup>

<sup>a</sup> Department of Microbiology, All India Institute of Medical Sciences, Raipur, 492099, India

<sup>b</sup> Department of Dermatology and Venerology, All India Institute of Medical Sciences, Raipur, 492099, India

<sup>c</sup> Department of Paediatric Surgery, All India Institute of Medical Sciences, Raipur, 492099, India

<sup>d</sup> Department of Pathology, All India Institute of Medical Sciences, Raipur, 492099, India



### ARTICLE INFO

#### Keywords:

Basidiobolus ranarum  
Subcutaneous zygomycosis  
Fungal infection  
Spindle cell tumor  
Itraconazole therapy

### ABSTRACT

Subcutaneous zygomycosis is a rare fungal infection caused by *Basidiobolus ranarum*. This entity is usually endemic in South India and only limited numbers of cases have been reported from central India. We report a case of 4-year-old male child from Chhattisgarh, who presented with a painless, non-tender, large, subcutaneous swelling of 4 months duration on the right upper arm, which was initially misdiagnosed as benign spindle cell tumor and advised surgical resection. But the fungal culture of the affected tissue grown *Basidiobolus ranarum* and the child responded very well to itraconazole therapy only.

### 1. Introduction

The class zygomycetes includes two fungal orders: Mucorales and Entomophthorales, with extremely different pathogenic potential [1]. Mucorales are responsible for mucormycosis, more severe form of the disease, seen mainly in immunocompromised host [2]. On the other hand, Entomophthorales, which include *Basidiobolus* & *Conidiobolus* genera, usually affect the immunocompetent individuals, principally causing chronic infection of the subcutaneous tissue [1].

In the past, clinical isolates of *Basidiobolus* were classified as *B. ranarum*, *B. meristosporus* and *B. haptosporus*. But recent taxonomic studies based on antigenic analysis, isoenzyme banding and restriction enzyme analysis of rDNA prove that all human pathogens belong to *B. ranarum* [3].

*Basidiobolus ranarum* is a saprophytic fungus present in soil, decaying fruit & vegetable matter as well as in the gut of amphibians & reptiles. It can cause a variety of clinical manifestations including subcutaneous zygomycosis, gastrointestinal zygomycosis & occasionally an acute systemic illness similar to that caused by mucorales [4].

Subcutaneous zygomycosis, is the commonest clinical form of Basidiobolomycosis with cases reported from many tropical and subtropical countries including India [4]. It is characterized by the formation of firm and nontender swellings, generally on the extremities, trunk, and rarely other parts of the body [5].

Here, we report a case of subcutaneous zygomycosis caused by *Basidiobolus ranarum* in a 4 year old male child with a large subcutaneous lesion on the right distal arm, which was initially misdiagnosed as a soft tissue tumor and it responded very well to only itraconazole therapy.

### 2. Case

A 4-year-old boy attended the paediatric surgery department of AIIMS, Raipur on 10th April 2018 (day 0), with a gradually increasing, painless swelling over the right distal arm since 4 months. It was associated with occasional itching. The lesion started as a small painless nodule which gradually increased in size to attain the present size. The child was a resident of Chhattisgarh with low socioeconomic background. Preceding history of any trauma could not be elicited.

The child was previously treated at a local private clinic with a course of antibiotics & later on as the lesion did not subside, both Fine needle aspiration cytology (FNAC) and sonography of the swelling was done. He was being diagnosed with benign spindle cell tumor and was advised for surgical excision & referred to our hospital.

On local examination, the lesion was approximately 6 × 5 cm in size, subcutaneous, non-tender, indurated with smooth & round edges over the right distal arm & cubital fossa (Fig. 1). The swelling was freely movable over the underlying structures. The skin over the lesion was

\* Corresponding author.

E-mail address: [drdaspadma@gmail.com](mailto:drdaspadma@gmail.com) (P. Das).

<https://doi.org/10.1016/j.mmcr.2019.02.002>

Received 6 December 2018; Received in revised form 4 January 2019; Accepted 8 February 2019

Available online 14 February 2019

2211-7539/ © 2019 Published by Elsevier B.V. on behalf of International Society for Human and Animal Mycology. This is an open access article under the CC BY-NC-ND license (<http://creativecommons.org/licenses/by-nc-nd/4.0/>).

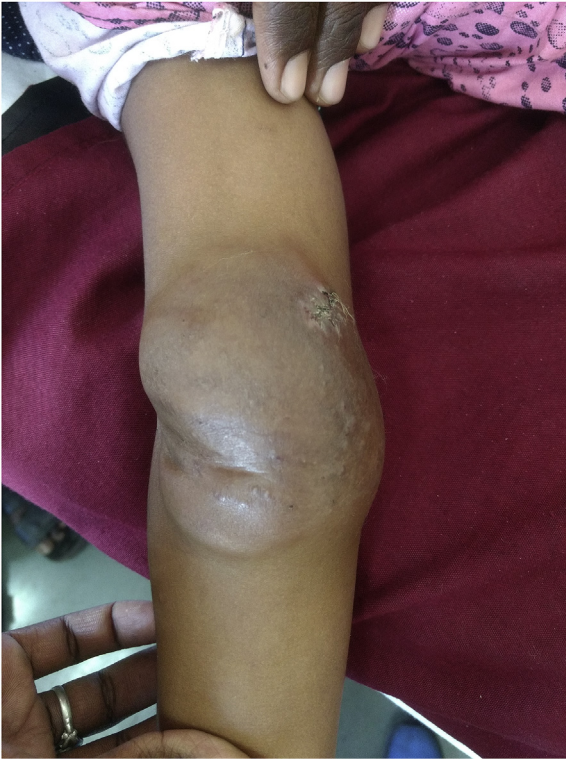

Fig. 1. Photograph of the lesion.

normal and there was no limitation of movement of the right upper limb. The child was afebrile; but the right axillary lymph nodes were enlarged. The rest of the general and systemic examination was normal.

Routine hemogram (day 0) showed features of microcytic hypochromic anaemia only and other routine hematologic & biochemical parameters including erythrocyte sedimentation rate, fasting and postprandial blood glucose levels, serum proteins, liver & kidney function tests were in normal range. His HIV status was also negative.

X-ray of right arm (day 0) showed soft tissue shadow without any bony involvement (Fig. 2). Contrast enhanced MRI of right distal arm with elbow joint (day 0) showed irregular, marginated soft tissue lesion ( $5.3 \times 4.7 \times 2.3\text{cm}$ ) localised in skin and subcutaneous fat plane with deeper infiltration at underlying superficial fascia (Fig. 3). Enlarged lymph nodes were present along the medial aspect of distal arm along the ulnar nerve with few other sub centric lymph nodes along the brachial vessels. A provisional diagnosis of subcutaneous fungal infection was made & Incisional biopsy was sent for histopathology as well as mycological examination (day 0).

Direct examination of the tissue material (day +1) in 40% potassium hydroxide wet mount preparation showed few broad, hyaline, sparsely septate, branched hyphae (Fig. 4). Growth was observed after 5 days (day +5) on Sabouraud's dextrose agar (SDA) without cycloheximide at both  $25^\circ\text{C}$  &  $37^\circ\text{C}$ . The colonies were expanding, creamy white, waxy, without aerial mycelium, with cerebriform centre and deep radial fissures in the outer zone (Figs. 5 and 6). On further incubation, satellite colonies were observed within next one week (day +11). Lactophenol cotton blue mount (day +5) showed sparsely septate, broad hyphae, fragmented into short hyphal bodies and conidia of various sizes, globose to pyriform shaped and smooth walled (Fig. 7). There was presence of many zygosporangia which were typically smooth, thick-walled and with characteristics lateral conjugation beaks, which confirmed the isolate to be *Basidiobolus ranarum* (Fig. 8). Hematoxylin & Eosin stain of the tissue biopsy showed foci of granuloma and multinucleated giant cells (Fig. 9).

Following the diagnosis, the child was treated with oral itraconazole syrup 9ml ( $\approx 90\text{mg}$ ) daily in two divided doses (day +6). The child responded very well to itraconazole therapy & the lesion started to resolve within first one month (day +20) of follow-up. He was advised to continue the treatment & for follow-up till the lesion completely subsides. The future treatment plan was to go for surgical excision in case of any residual lesion followed by confirmation of microbiological cure by fungal culture of the excised tissue. But unfortunately the child was lost to follow-up after two months of starting the treatment.

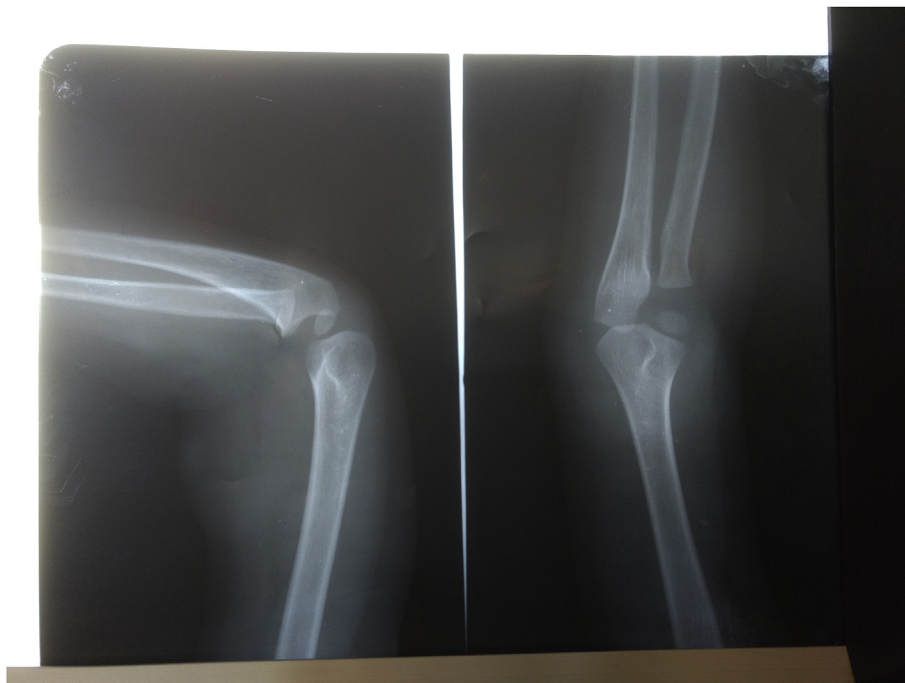

Fig. 2. X-ray of right arm.

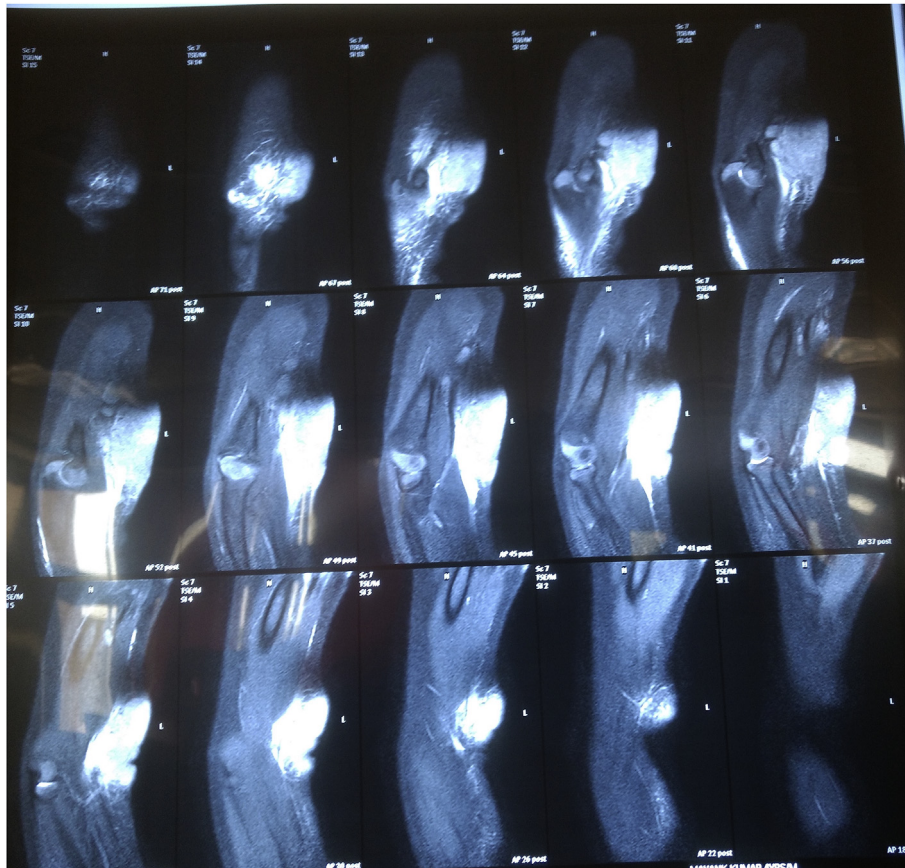


Fig. 3. Contrast enhanced MRI of the right distal arm.

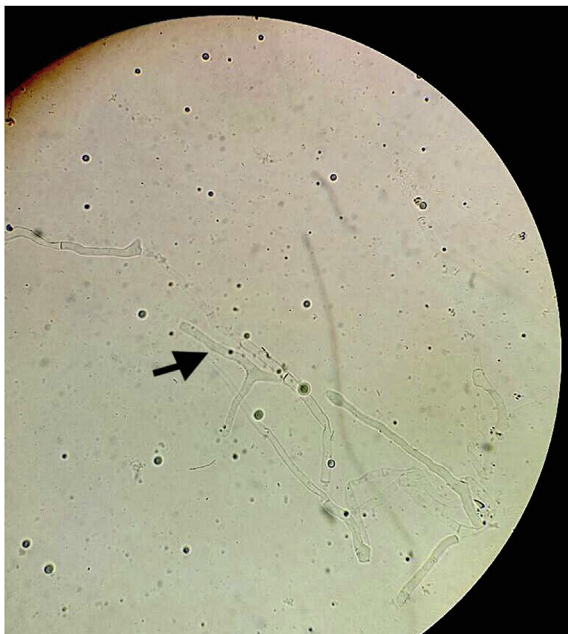


Fig. 4. Direct microscopy in 40% KOH wet mount.

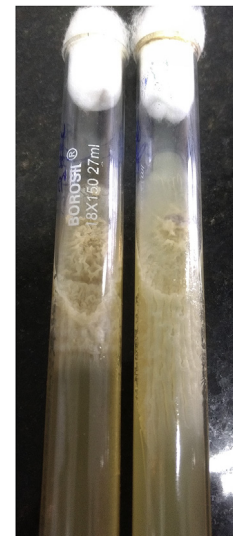

Fig. 5. Growth on Sabouraud's dextrose agar.

### 3. Discussion

The first case of Subcutaneous zygomycosis caused by *Basidiobolus ranarum* had been reported from Indonesia by Kian JL et al. (5). In India, the first case was reported by Mukerji et al., 1962 in Bombay (Mumbai) [6]. But as far as Indian scenario is concerned, the disease is

more concentrated in south India [1,4,7]. In contrast the present case was from central part of India. Seven cases of chronic subcutaneous phycomycosis caused by *B. ranarum* were detected by Maiti PK et al., during a span of 9 years from 1991 to 1999, from 9 districts in and around Kolkata [8]. There are scarce case reports from other parts of India, including north-eastern India, Chhattisgarh and Bhopal [3,9,10].

The disease usually occurs in children, less often in adolescents, and rarely in adults. Males are much more frequently affected than females [5]. *B. ranarum* typically causes a chronic infection of the peripheral or subcutaneous tissue, usually on the arms, trunk, and buttocks. The most



Fig. 6. Growth on Sabouraud's dextrose agar.

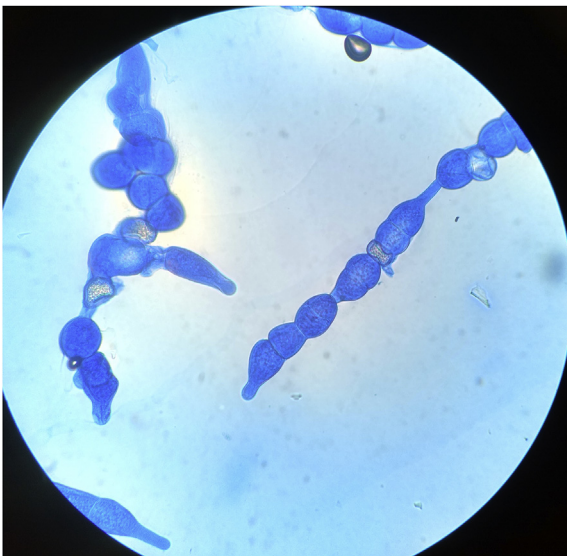


Fig. 7. Lactophenol cotton blue preparation of fungal growth.

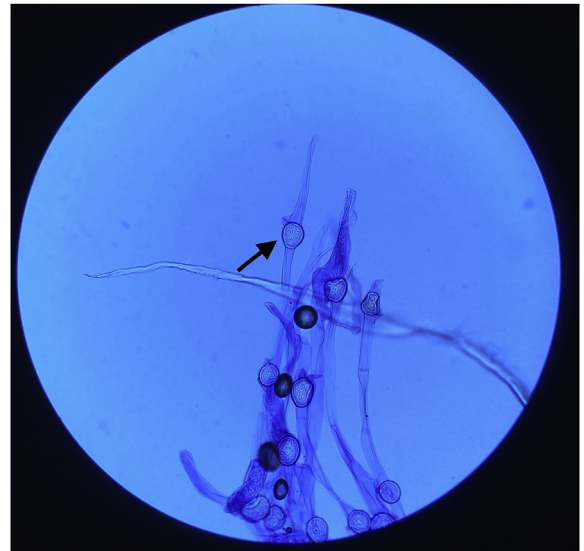


Fig. 8. Lactophenol cotton blue preparation of fungal growth.

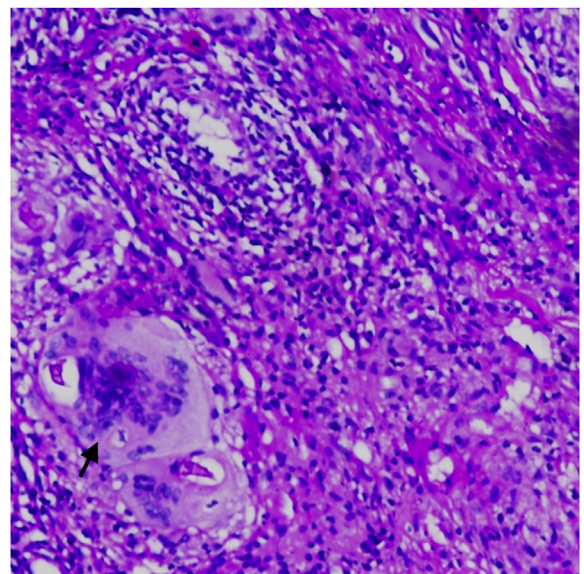


Fig. 9. Haematoxylin and eosin stain of the tissue biopsy.

common presentation for Basidiobolomycosis is on the thighs and buttocks in a bathing suit distribution [1].

Subcutaneous zygomycosis results from inoculation of fungal spore into the dermis or subcutis [2]. Possible mode of transmission is minor trauma which may be through insect bite, intravenous catheter, or even intramuscular injection [2,11]. No predisposing factor could be identified in our case, but we suspect trivial traumatic implantation may be the most probable mode of entry.

Clinically the disease starts as nodule on extremities or trunk which if untreated may spread and expand locally to form hard, painless, nontender swelling. Although ulceration of the nodule may be a possible fate, dissemination is extremely rare. *B. ranarum* has been reported to cause gastrointestinal infections, lymph node and muscle involvement apart from chronic granulomatous subcutaneous infection, but with a much lesser frequency [1].

Histopathologically, Basidiobolomycosis is typically associated with

presence of thin walled, broad, often aseptate hyphae or hyphal fragments with an eosinophilic sheath (Splendore-Hoeppli phenomenon), frequently phagocytised within giant cells [3] But this feature may not be present in all cases [4].

Basidiobolus can be grown on standard mycology medium such as sabouraud dextrose agar (SDA), potato dextrose agar, or cornmeal agar. The colonies are typically flat and furrowed, with a waxy texture, a yellow-grey surface with pale reverse, and a musty odour. Satellite colonies are formed after few days from the germination of ejected sporangioles. Presence of globose to subglobose (20-50µ.) zygospores (sexual spores) with thick often undulating walls and two closely appressed beak-like appendages, which is the remnants of conjugation tube, is the characteristic feature of *Basidiobolus ranarum* [11].

Though direct examination of the biopsy sample may suggest a diagnosis of this entity, culture is gold standard for confirmation [1]. An immunodiffusion test has also been developed for specific diagnosis of the disease, but it is not routinely available [3].

Various pharmaceutical agents have been used to successfully treat Basidiobolomycosis including potassium iodide (KI), trimethoprim-sulfamethoxazole, amphotericin B, oral azoles. Treatment of

Basidiobolomycosis is not always successful, and no single drug has proved effective in the treatment of all cases of Basidiobolomycosis [12]. The usual treatment of choice has been saturated solution of potassium iodide (KI), the dose being 30 mg/kg daily given as a single daily dose or divided into three daily doses. Treatment is continued for 6–12 months. Some patients do not respond to KI treatment [11] and some patients don't comply due to the adverse effects of KI [12]. Most patients with Basidiobolomycosis also respond very well to azoles, particularly itraconazole. Treatment with amphotericin-B has given unsatisfactory results, with some strains even showing in vitro resistance to this drug. There was an excellent response to only itraconazole therapy within one month in our case.

Basidiobolomycosis is a potentially curable disease, but the possibility of misdiagnosing this entity as neoplasm should be kept in mind as it is a great mimicker of soft tissue tumor, synovial sarcoma and burkitt's lymphoma [2]. It may also resemble other tropical infections, e. g fungal infections (Pythiosis & Sporotrichosis), parasitic infections (Filariasis elephantiasis and Onchocerciasis) and bacterial infections (*Mycobacterium tuberculosis* & *Mycobacterium ulcerans*).

In our case also, the clinical presentation and FNAC report led the clinician to diagnose it as a soft tissue tumor; but timely microbiological diagnosis & good response to itraconazole therapy helped to avoid the unnecessary surgical intervention.

It has been reported that surgery may hasten the spread of infection. So there should be a caution regarding its prevention, since the organism has been introduced iatrogenically and may spread during diagnosis & treatment [1].

Subcutaneous zygomycosis is a rare cause of soft tissue infection and should be suspected in atypical swelling, chronic non-healing sinuses and abscesses which are refractory to treatment. In a nutshell, Early diagnosis and awareness of this entity even in non-endemic part of the country is very important to prevent disfigurement, misdiagnosis, and avoidance of unnecessary investigations and surgical interventions.

## Conflict of interest

Authors have no conflict of interest to declare.

## Funding

There is no funding to disclose.

## References

- [1] U.R. Anaparthi, G. Deepika, A case of subcutaneous zygomycosis, *Indian Dermatol. Online J.* 5 (2014) 51–54, <https://doi.org/10.4103/2229-5178.126033>.
- [2] A.K. Mondal, A. Saha, J. Seth, S. Mukherjee, Subcutaneous zygomycosis: a report of one case responding excellently to potassium iodide, *Indian J. Dermatol.* 60 (2015) 500–502, <https://doi.org/10.4103/0019-5154.164376>.
- [3] R. Singh, I. Xess, A.S. Ramavat, R. Arora, Basidiobolomycosis: a rare case report, *Indian J. Med. Microbiol.* 26 (2008) 265, <https://doi.org/10.4103/0255-0857.42044>.
- [4] S. Sujatha, C. Sheeladevi, A. Khyriem, D. Thappa, reportSubcutaneous Zygomycosis Caused by Basidiobolus Ranarum - A Case Report, (n.d.) 2.
- [5] M. Anand, S.D. Deshmukh, D.P. Pande, S. Naik, D.P. Ghadage, Subcutaneous zygomycosis due to Basidiobolus ranarum: a case report from Maharashtra, India, *J. Trop. Med.* (2010), <https://doi.org/10.1155/2010/950390>.
- [6] S. Mukerji, S.B. Gore, S.N. Mansukhani, V.M. Kini, Subcutaneous phycomycosis, *Indian J. Child Health* 11 (1962), <https://www.cabdirect.org/cabdirect/abstract/19631301838>, Accessed date: 6 September 2018.
- [7] P. PVS, Subcutaneous phycomycosis in a child, *Indian J. Dermatol. Venereol. Leprol.* 68 (2002) 303.
- [8] P.K. Maiti, R. Bose, S. Bandyopadhyay, S. Bhattacharya, J.B. Dey, A. Ray, Entomophthoromycosis in south Bengal (eastern India): a 9 years study, *Indian J. Pathol. Microbiol.* 47 (2004) 295–297.
- [9] S.T. Jayanth, P. Gaikwad, M. Promila, J.C. Muthusami, The sinus that breeds fungus: subcutaneous zygomycosis caused by Basidiobolus ranarum at the injection site, *Case Rep. Infect. Dis.* (2013), <https://doi.org/10.1155/2013/534192>.
- [10] T. Karuna, D.P. Asati, D. Biswas, S. Purwar, Subcutaneous entomophthoromycoses, *Indian Dermatol. Online J.* 6 (2015) 410–412, <https://doi.org/10.4103/2229-5178.169730>.
- [11] H.C. Gugnani, A review of zygomycosis due to Basidiobolus ranarum, *Eur. J. Epidemiol.* 15 (1999) 923–929.
- [12] J. Guarro, C. Aguilar, I. Pujol, In-vitro antifungal susceptibilities of Basidiobolus and Conidiobolus spp. strains, *J. Antimicrob. Chemother.* 44 (1999) 557–560.