

Original Article



Cyst Size in Fetuses with Biliary Cystic Malformation: An Exploration of the Etiology of Congenital Biliary Dilatation

Kengo Hattori ^{1,2}, Yoshinori Hamada ², and Masahito Sato ³

¹Department of Pediatric Surgery, Takatsuki General Hospital, Osaka, Japan

²Division of Pediatric Surgery, Kansai Medical University, Osaka, Japan

³Department of Pediatric Surgery, Kitano Hospital, Osaka, Japan



Received: Mar 7, 2020

Revised: May 6, 2020

Accepted: Jun 16, 2020

Correspondence to

Kengo Hattori

Department of Pediatric Surgery, Takatsuki General Hospital, 1-3-13 Kosobe-cho, Takatsuki, Osaka 569-1192, Japan.
E-mail: ken5hattori@gmail.com

Copyright © 2020 by The Korean Society of Pediatric Gastroenterology, Hepatology and Nutrition

This is an open-access article distributed under the terms of the Creative Commons Attribution Non-Commercial License (<https://creativecommons.org/licenses/by-nc/4.0/>) which permits unrestricted non-commercial use, distribution, and reproduction in any medium, provided the original work is properly cited.

ORCID iDs

Kengo Hattori

<https://orcid.org/0000-0003-2650-3370>

Yoshinori Hamada

<https://orcid.org/0000-0003-2214-7399>

Masahito Sato

<https://orcid.org/0000-0002-2848-0275>

Conflict of Interest

The authors have no financial conflicts of interest.

ABSTRACT

Purpose: Our aim was the longitudinal assessment of cyst size in fetuses with biliary cystic malformation (BCM) to explore its etiology and the possibility of antenatal differentiation between biliary atresia (BA) and congenital biliary dilatation (CBD).

Methods: We conducted a retrospective review of all patients diagnosed antenatally with BCM from 1994 to 2014 at our institutions.

Results: The study cohort comprised of three patients with BA and six with CBD. There were no significant differences in the gestational age and cyst size at the first detection of BCM between the two groups. In fetuses with CBD, the cyst size steadily increased as the gestational age advanced, while it fluctuated around 1.5 cm and remained below 2.1 cm in those with BA. However, the ratio of cystic area to fetal trunk area was approximately constant due to linear fetal growth in fetuses with CBD.

Conclusion: Fetuses with BCM <2.1 cm in the late gestation period were more likely to have BA than CBD. Our observation of cyst enlargement with advancing gestational age in the CBD group was attributed solely to fetal growth. Biliary dilatation in fetuses with CBD and BA might be completed at the onset of BCM.

Keywords: Prenatal diagnosis; Biliary atresia; Biliary cystic malformations; Choledochal cyst; Diagnostic imaging

INTRODUCTION

Congenital biliary dilatation (CBD) is now the preferred name for choledochal cysts [1]. Its etiology remains unclear; however, it may be closely associated with the development of pancreaticobiliary maljunction (PBM), which is observed in the majority of CBD cases [2].

Biliary atresia (BA) is a progressive fibro-obliterative cholangiopathy of unknown etiology and is one of the most common indications for pediatric liver transplantation. BA represents the final outcome of intra-uterine or perinatal injury to the bile ducts, leading to fibrous obliteration of these structures and severe cholestatic liver disease in the neonatal period [3].

Recent advances in fetal ultrasonography (US) have enabled the prenatal identification of biliary cystic malformations (BCMs) including BA and CBD. Previous studies have suggested the potential for differentiating BA from CBD on the basis of cyst size [4] and chronological changes in the cyst size [5,6]. However, distinguishing between BA and CBD in fetuses with BCM remains difficult, and no unequivocal US criteria have been established despite the necessity of early parental counseling and early corrective surgery after birth. The aim of this study was to assess the cyst size in fetuses with BCM so as to explore the etiology of BCM and the possibility of antenatal differentiation between BA and CBD.

MATERIALS AND METHODS

We conducted a retrospective review of all patients diagnosed antenatally with BCM from 1994 to 2014 at our institutions. Data collected included the cyst size measured during serial antenatal US examinations, perinatal characteristics, postnatal serum chemistry values, and operative diagnosis. In addition to the cyst size, which was defined as the maximum cystic diameter, the cyst and fetal trunk areas were measured directly by the US machine or were calculated as the area of the approximate ellipse.

The statistical significance of differences was assessed by the Mann–Whitney U-test. Significance was set at $p < 0.05$.

This study was approved by the Institutional Review Board of Kansai Medical University (H160519). Formal consent was not required for this type of study.

RESULTS

The study cohort comprised of three patients with BA (two with Type I cysts and one with Type IIIc cyst) and six patients with CBD (three with Todani type Ia cysts and three with Todani type IV-A cysts) who were diagnosed antenatally with BCM during the study period at our institutions. All patients were born at full term. **Table 1** summarizes the statistical data on the perinatal characteristics, gestational age, cyst size at the first detection by fetal US, postnatal serum chemistry values, and operative findings in patients diagnosed antenatally with BCM. None of the differences in the perinatal characteristics between the BA and CBD

Table 1. Perinatal characteristics, gestational age, cyst size at first detection by fetal ultrasonography, postnatal serum chemistry values, and operative findings in patients diagnosed antenatally with biliary cystic malformations

Variable	BA (3 cases)	CBD (6 cases)	<i>p</i> -value (Mann-Whitney U-test)
GA at birth (wk)	39.3 (39–40)	39.7 (37–41)	0.42
Body weight at birth (g)	2,745 (2,680–2,805)	3,100 (2,360–3,444)	0.17
GA at detection of BCM (wk)	27.7 (21–33)	24.8 (20–31)	0.43
Cyst size at detection (cm)	0.73 (0.14–1.05)	1.04 (0.35–2.4)	0.91
AST (U/L)	157 (32–281)	46.7 (16–157)	0.09
ALT (U/L)	96.7 (7–178)	18.8 (6–54)	0.20
GGTP (U/L)	341 (181–526)	654 (101–1,679)	0.71
T-Bil (mg/dL)	7.37 (6.7–8.1)	9.68 (0.5–15.3)	0.55
D-Bil (mg/dL)	4.47 (2.9–6)	0.63 (0–2.1)	0.02
Type (operative findings)	Two Type I cysts and one Type IIIc cyst	Three Todani type Ia cysts and three Todani type IVa cysts	

Values are presented as mean (range).

BA: biliary atresia, CBD: congenital biliary dilatation, GA: gestational age, BCM: biliary cystic malformation, AST: aspartate aminotransferase, ALT: alanine aminotransferase, GGTP: gamma-glutamyl transpeptidase, T-Bil: total bilirubin, D-Bil: direct bilirubin.

groups were statistically significant. Among postnatal serum chemistry parameters, there was a significant intergroup difference only in the direct bilirubin level.

Fig. 1 shows the changes in the cyst size in the BA and CBD groups from 22 to 38 weeks of gestation. In the CBD group, the mean cyst size steadily increased from 1.9 cm at the 22nd week to 3.1 cm at the 38th week. Conversely, in the BA group, the mean cyst size fluctuated around 1.5 cm and remained smaller than 2.1 cm throughout the period of measurement. The gap in the mean cyst size between the CBD and BA groups widened over time, ranging from 0.4 cm at the 22nd week to 1.8 cm at the 38th week.

Fig. 2 shows the mean cyst areas in the BA and CBD groups assessed fortnightly from 22 to 38 weeks of gestation. In the CBD group, the mean cyst area increased almost steadily from 3.1

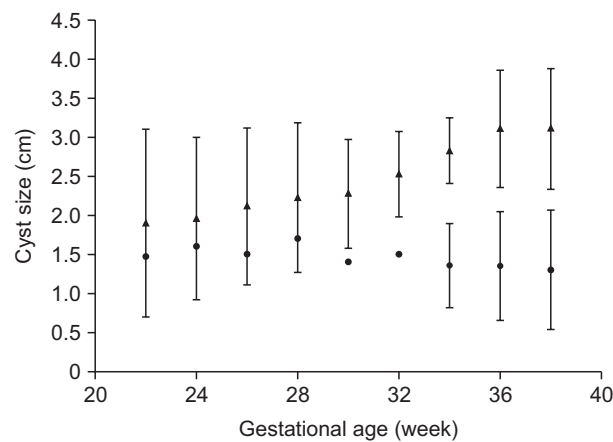


Fig. 1. Antenatal cyst size from 22 to 38 weeks of gestation in patients with biliary cystic malformation. Mean cyst sizes were calculated fortnightly from the measured and estimated cyst sizes in the CBD (black triangles) and BA (black circles) groups. Data are shown as mean with standard deviation. CBD: congenital biliary dilatation, BA: biliary atresia. The difference between the CBD and BA groups at each gestational age was not statistically significant. Statistical analyses were performed using the Mann-Whitney U-test.

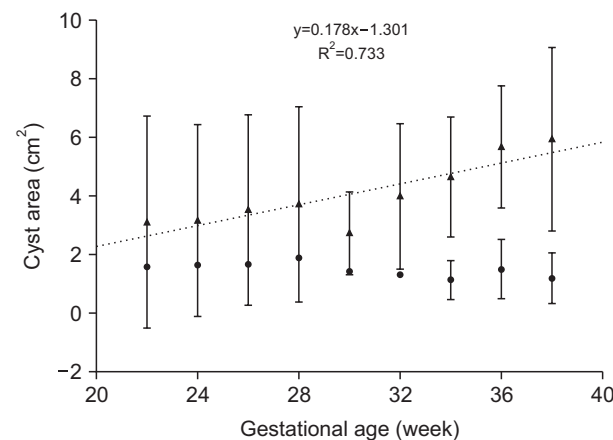


Fig. 2. Antenatal cyst area from 22 to 38 weeks of gestation in patients with biliary cystic malformation. Mean cyst areas were calculated fortnightly from the measured and estimated cyst areas in the CBD (black triangles) and BA (black circles) groups. CBD: congenital biliary dilatation, BA: biliary atresia. Data are shown as mean with standard deviation. The difference between the CBD and BA groups at each gestational age was not statistically significant. Statistical analyses were performed using the Mann-Whitney U-test. The dotted line represents the linear regression line between the mean cyst area and gestational age in CBD patients. The equation of the line $y=0.178x-1.301$ ($R^2=0.733$).

cm² at the 22nd week to 5.9 cm² at the 38th week, while in the BA group, it fluctuated between 1 cm² and 2 cm² (similar to the mean cyst size in Fig. 1). Fig. 2 shows the linear trend of an increase in cyst area with gestational age (dotted line) in the CBD patients.

Fig. 3 illustrates a scatterplot between the fetal trunk area and the gestational age in the CBD group that indicates a linearly increasing trend in the fetal trunk area ($y=3.538x-54.64$; $R^2=0.885$). To neutralize this fetal growth and to estimate the true enlargement of the cyst in the fetuses, the ratio of the cystic area to the fetal trunk area was calculated; Fig. 4 shows the fortnightly-assessed means of these ratios in the BA and CBD groups from 22 to 38 weeks of gestation. The ratios in both the BA and CBD groups were approximately constant and exhibited a slightly declining trend, indicating that the cysts in fetuses with CBD and BA might not enlarge independently and that the biliary dilatation in fetuses might be completed at the onset of BCM.

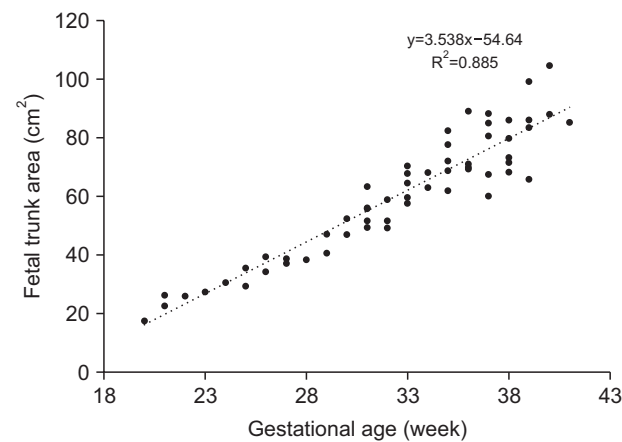


Fig. 3. Scatterplot between fetal trunk area in ultrasonography scans and gestational age in the congenital biliary dilatation (CBD) group. The dotted line represents the linear regression line whose equation is $y=3.538x-54.64$ ($R^2=0.885$).

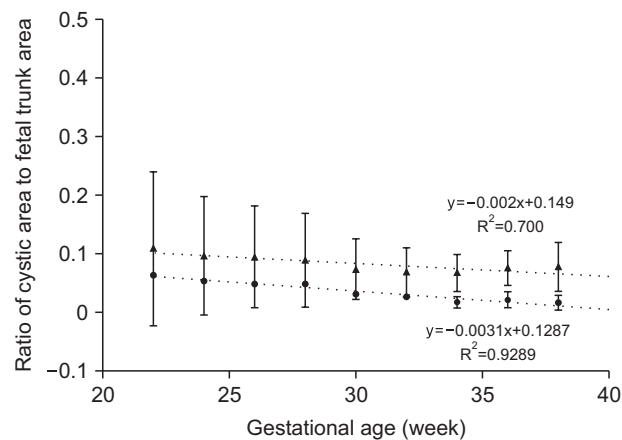


Fig. 4. Fortnightly-assessed means of the calculated cystic area-to-fetal trunk area ratios in the CBD (black triangles) and BA (black circles) groups from 22 to 38 weeks of gestation. CBD: congenital biliary dilatation, BA: biliary atresia. The dotted lines represent linear regressions lines whose equations are: $y=-0.002x+0.149$ ($R^2=0.700$) for CBD and $y=-0.003x+0.129$ ($R^2=0.929$) for BA.

DISCUSSION

Inspired by recent advances in antenatal US, some researchers have suggested the potential for differentiating between BA and CBD antenatally. In the first such paper in 1997, Matsubara et al. [6] reported that while cyst enlargement may lead to a diagnosis of CBD, according to a review of previously published case reports and their own experience with two cases, enlargement does not occur in some patients with CBD or BA. Cassacia et al. [5] suggested the US scan pattern, cyst size, and increase in cyst size as possible criteria for differentiating between BA and CBD. They reported that anechoic small cysts are highly suggestive of BA, echoic large or enlarging cysts are highly suggestive of “obstructed” CBD, and echoic small and stable cysts are highly suggestive of “unobstructed” CBD. However, they did not identify any particular size or rate of increase in size as diagnostic. In our experience, we found no difference in echogenicity between the BA and CBD groups. The sonographic features of “obstructed” CBD could be applicable for our six CBD cases (three with Todani type Ia cysts and three with Todani type IV-A cysts).

In a study on ten patients with antenatally diagnosed BA and CBD (five each), Tanaka et al. [4] reported that the cyst size was significantly larger in the CBD group as compared to in the BA group after 35 gestational weeks, which is very similar to our findings. They also reported that all patients with BCM smaller than 2.1 cm were diagnosed with BA, which is again identical to our findings. Accordingly, a “cyst size of equal to or less than 2.1 cm” could be a promising criterion for BA in a fetus with BCM after the 35th gestational week. This report also suggested that after bile excretion was initiated in the 12th week of gestation, the cyst size in the CBD group gradually increased, although the cyst size in the BA group remained virtually the same throughout the prenatal period.

Chronological changes in the cyst size could be one of the most promising diagnostic criteria for differentiating between BA and CBD, although some reports failed to demonstrate statistically significant differences due to a small number of cases [7]. The idea on which these studies were predicated was that changes in cyst size throughout gestation reflect the amount of bile excreted by the liver and the patency of the bile duct [8]. Thus, poor bile flow due to BA should be associated with a decrease in the cyst size, especially in the later gestational period during which extrahepatic bile ducts are being obliterated by inflammation and subsequent fibrosis. The timing of the decrease in cyst size may depend on the onset and progression of BA. In contrast, because patients with CBD usually have a good bile flow, their cysts are likely to enlarge. This “enlarging cyst” concept was convincing enough to be widely accepted; however, our hypothesis might impugn its accuracy. In the present study, we calculated the ratio of the cystic area to the fetal trunk area to neutralize fetal growth, and estimated the true enlargement of the cyst in fetuses. We found that the ratio tended to decline slightly over time in fetuses with CBD and BA, suggesting that biliary dilatation in these fetuses is completed at the onset of BCM and would not progress much subsequently. The difference in the cyst size between BA and CBD fetuses in later pregnancy, as shown in this study, might be mainly due to a progressive fibro-obliterative process in the extrahepatic bile ducts of fetuses with BA.

The reason and mechanism of biliary dilatation in CBD are still far from being fully elucidated, although the pathogenesis of CBD is thought to be closely associated with the development of PBM, an anomalous union of the pancreatic and biliary ducts located outside the duodenal wall [2]. This association led to the well-known “Babbitt hypothesis”, which

states that a continuous reflux of pancreatic juice into the common bile duct allowed by PBM causes inflammation, and thus, weakens the ductal wall, resulting in biliary dilatation [9]. However, our finding that biliary dilatation in fetuses with CBD is completed at the onset of BCM in early fetal life casts considerable doubt on the Babbitt hypothesis. The reason is that the level of proteolytic enzyme activity in the fetal pancreatic tissue at around 22 weeks of gestation is not sufficient for causing biliary dilatation during fetal maturation [10]. An increase in pancreatic proteases appears after approximately one month of extrauterine life [11]. Many studies on biliary dilatation without PBM also suggested that reflux of pancreatic juice alone could not cause biliary dilatation [12]. Furthermore, some interesting studies have demonstrated a fundamental inverse relationship between the resting bile duct pressure and the level of biliary amylase, which in CBD, is substituted for other enzymes causing tissue damage [13,14]. They also demonstrated that a high intraluminal pressure was associated with more severe histopathological changes and morphology in CBD. These results suggest that it is the intraluminal pressure rather than the refluxed pancreatic juice that induces biliary dilatation.

There is another convincing theory based on fragile ductal wall with immature elastic fibers (a congenital abnormality). The combined effect of this abnormality and an elevated intraductal pressure might elicit biliary dilatation [15]. However a strong counterargument against this theory is that the elastic fibers are also immature in normal children and there is little possibility that abnormality of elastic fibers is involved in biliary dilatation [12].

Another possible explanation for biliary dilatation in CBD patients is the narrowing of the distal bile duct and the subsequent increase in the intraluminal pressure in the dilating bile duct. In our CBD cases, operative findings indicated that biliary dilatation was associated with the presence of a narrow segment. The present study suggests that the extent of biliary dilatation is determined during the early fetal period. Ando and colleagues [16,17] evaluated the role of stenosis in biliary dilatation and derived an equation that indicated a strong relationship between the maximum diameter of the common bile duct and the length of the narrow segment, irrespective of the age. They postulated that obstruction in the narrow segment distal to the dilated common bile duct during fetal life is responsible for biliary dilatation. This equation and etiologic consideration strongly support the findings of our study. Regrettably, we did not measure the length of the narrow segment during surgery.

In this study, we examined only the prenatal cyst size, and concluded that enlargement of the cyst with advancing gestational age in the CBD group was attributed solely to fetal growth. We consequently speculated that dilatation of the common bile duct, which was established in the early fetal life, would not progress much further after birth. In reality, the ratio of cystic area to fetal trunk area in fetuses with CBD was 0.08 at 38 weeks of gestation in our study and increased to 0.15 by the first sonographic follow-up after birth. Among our six cases, the cyst grew in size in three cases (two with a Todani type Ia cyst and one with a Todani type IV-A cyst), and contrariwise, it decreased in size in the other three cases (one with a Todani type Ia cyst and two with a Todani type IV-A cyst) between the 38th gestational week and the first sonographic follow-up after birth. We inferred that the inflammatory reaction secondary to a pancreatic juice reflux may have exacerbated the stenosis of the narrow segment in terms of the diameter and/or length; hence, further dilatation occurred. To verify this hypothesis, laboratory test values including inflammatory marker levels and liver function test results after birth were reviewed, but no associations between the progression of biliary dilatation and abnormal laboratory test values were found.

Limitations of the present study include the small number of cases and its retrospective nature. Single institutions, especially in Japan, have very few cases of antenatally diagnosed BA and CBD. The Japanese Study Group on PBM recently published the “Diagnostic Criteria for Congenital Biliary Dilatation 2015”, which we believe are the world’s first published criteria [1]. These criteria were established by employing a multicenter approach to overcome the reality that single institutions in Japan experience very few cases. We anticipate that our promising hypothesis will be further refined as additional data on antenatally diagnosed BA and CBD accumulate through a nationwide multicenter study like that of the JSGPM.

In conclusion, our observation of increasing cyst size with advancing gestational age in the CBD group might be attributed solely to fetal growth. Biliary dilatation in fetuses with CBD and BA might be completed at the onset of BCM and not progress much further subsequently.

REFERENCES

1. Hamada Y, Ando H, Kamisawa T, Itoi T, Urushihara N, Koshinaga T, et al. Diagnostic criteria for congenital biliary dilatation 2015. *J Hepatobiliary Pancreat Sci* 2016;23:342-6.
[PUBMED](#) | [CROSSREF](#)
2. Ishibashi H, Shimada M, Kamisawa T, Fujii H, Hamada Y, Kubota M, et al. Japanese clinical practice guidelines for congenital biliary dilatation. *J Hepatobiliary Pancreat Sci* 2017;24:1-16.
[PUBMED](#) | [CROSSREF](#)
3. Moreira RK, Cabral R, Cowles RA, Lobritto SJ. Biliary atresia: a multidisciplinary approach to diagnosis and management. *Arch Pathol Lab Med* 2012;136:746-60.
[PUBMED](#) | [CROSSREF](#)
4. Tanaka N, Ueno T, Takama Y, Fukuzawa M. Diagnosis and management of biliary cystic malformations in neonates. *J Pediatr Surg* 2010;45:2119-23.
[PUBMED](#) | [CROSSREF](#)
5. Casaccia G, Bilancioni E, Nahom A, Trucchi A, Aite L, Marcellini M, et al. Cystic anomalies of biliary tree in the fetus: is it possible to make a more specific prenatal diagnosis? *J Pediatr Surg* 2002;37:1191-4.
[PUBMED](#) | [CROSSREF](#)
6. Matsubara H, Oya N, Suzuki Y, Kajiura S, Suzumori K, Matsuo Y, et al. Is it possible to differentiate between choledochal cyst and congenital biliary atresia (type I cyst) by antenatal ultrasonography? *Fetal Diagn Ther* 1997;12:306-8.
[PUBMED](#) | [CROSSREF](#)
7. Tanaka H, Sasaki H, Wada M, Sato T, Kazama T, Nishi K, et al. Postnatal management of prenatally diagnosed biliary cystic malformation. *J Pediatr Surg* 2015;50:507-10.
[PUBMED](#) | [CROSSREF](#)
8. Saito T, Horie H, Yoshida H, Matsunaga T, Kouchi K, Kuroda H, et al. The perinatal transition of the hepatobiliary cyst size provides information about the condition of bile flow in biliary cystic malformation cases. *J Pediatr Surg* 2006;41:1397-402.
[PUBMED](#) | [CROSSREF](#)
9. Babbitt DP, Starshak RJ, Clemett AR. Choledochal cyst: a concept of etiology. *Am J Roentgenol Radium Ther Nucl Med* 1973;119:57-62.
[PUBMED](#) | [CROSSREF](#)
10. McClean P, Weaver LT. Ontogeny of human pancreatic exocrine function. *Arch Dis Child* 1993;68(1 Spec No):62-5.
[CROSSREF](#)
11. Lieberman J. Proteolytic enzyme activity in fetal pancreas and meconium: demonstration of plasminogen and trypsinogen activators in pancreatic tissue. *Gastroenterology* 1966;50:183-90.
[CROSSREF](#)
12. Ando H. [Mechanism of the bile duct dilatation in congenital biliary dilatation]. *Jpn J Pediatr Surg* 2009;41:1353-6. Japanese.
13. Davenport M, Basu R. Under pressure: choledochal malformation manometry. *J Pediatr Surg* 2005;40:331-5.
[PUBMED](#) | [CROSSREF](#)

14. Turowski C, Knisely AS, Davenport M. Role of pressure and pancreatic reflux in the aetiology of choledochal malformation. *Br J Surg* 2011;98:1319-26.
[PUBMED](#) | [CROSSREF](#)
15. Spitz L. Experimental production of cystic dilatation of the common bile duct in neonatal lambs. *J Pediatr Surg* 1977;12:39-42.
[PUBMED](#) | [CROSSREF](#)
16. Ando H. [Mechanism of the bile duct dilatation in congenital dilatation of the common bile duct]. *Nihon Geka Gakkai Zasshi* 1983;84:1174-85. Japanese.
[PUBMED](#)
17. Ito T, Ando H, Nagaya M, Sugito T. Congenital dilatation of the common bile duct in children.-The etiologic significance of the narrow segment distal to the dilated common bile duct. *Z Kinderchir* 1984;39:40-5.
[PUBMED](#) | [CROSSREF](#)