

Combined C1–2 transarticular screw fixation and C1 laminoplasty with interlaminar bone transplant for retro-odontoid pseudotumor: illustrative case

Takanori Fukunaga, MD, PhD,¹ Kazuo Yonenobu, MD, PhD,² Manabu Sasaki, MD, PhD,¹ and Haruhiko Kishima, MD, PhD³

¹Department of Neurosurgery, Iseikai Hospital, Osaka, Japan; ²Osaka Yukioka College of Health Science, Osaka, Japan; and ³Department of Neurosurgery, Osaka University Graduate School of Medicine, Suita, Osaka, Japan

BACKGROUND The surgical treatment for retro-odontoid pseudotumor (ROP) remains controversial. Posterior C1 laminectomy without fixation occasionally leads to postoperative enlargement of ROP. Because its pathogenesis is associated with atlantoaxial instability, atlantoaxial fixation with C1 laminectomy is commonly performed. Atlantoaxial fixation usually includes transarticular fixation and screw-rod fixation. However, these methods have some issues. That is, in transarticular fixation with C1 laminectomy, the bone grafting area is challenging to obtain. In screw-rod fixation with C1 laminectomy, extensive bleeding occurs at times if the lateral atlantoaxial joint is exposed to the transplant bone grafts.

OBSERVATIONS Herein, the authors report a case of ROP treated with combined C1–2 transarticular screw fixation and C1 laminoplasty with interlaminar bone transplant, which can help achieve adequate spinal cord decompression and can simultaneously secure the bone grafting area between the laminae. In addition, the volume of intraoperative blood loss decreased. Postoperative magnetic resonance imaging showed sufficient decompression of the spinal cord at the C1 level, and computed tomography performed after 6 months revealed bone union between the C1 and C2 laminae.

LESSONS Combined C1–2 transarticular screw fixation and C1 laminoplasty with interlaminar bone transplant is a useful method for ROP.

<https://thejns.org/doi/abs/10.3171/CASE2289>

KEYWORDS retro-odontoid pseudotumor; C1 laminoplasty; posterior transarticular fixation

Retro-odontoid pseudotumor (ROP) is a nontumoristic lesion that is frequently associated with some inflammatory pathologies, such as rheumatoid arthritis, long-term hemodialysis, and calcium pyrophosphate dehydrate deposition. However, noninflammatory conditions, including cervical degenerative and mechanical alterations, are occasionally correlated with ROP formation.¹ In these cases, ROP develops due to chronic mechanical stress caused by atlantoaxial instability or subluxation. Mechanical stress gradually produces reactive fibrocartilaginous mass proliferation, resulting in ROP. Atlantoaxial instability is not always detected via dynamic plain radiography.² However, atlantoaxial joint microinstability or overload is considered a cause of ROP. This notion is supported by the fact that ROP often develops if there is ossification of the anterior longitudinal ligament and ankylosis at the adjacent spinal segments (O–C1, C2–3 levels).^{3,4}

In cases of atlantoaxial instability based on radiological studies, posterior fixation is the most popular surgical method. Posterior fixation, even without ROP resection, can diminish the volume of ROP immediately after surgery.^{3–7} However, in cases of severe spinal cord compression, C1 laminectomy, which involves atlas posterior arch resection, is required for immediate neural decompression. On the one hand, because C1 laminectomy is correlated with the loss of area for atlantoaxial interlaminar bone transplant, it is not easy to prepare the bone graft area in atlantoaxial (C1–2) fixation. On the other hand, occipitoaxial (O–C2) fixation can secure the bed for bone transplant. However, it can possibly cause complications due to significant limitations in head movements⁸ and is associated with a higher risk of reoperation than C1–2 fixation.⁹

ABBREVIATIONS CT = computed tomography; MRI = magnetic resonance imaging; ROP = retro-odontoid pseudotumor; SR = screw-rod fixation; TA = transarticular screw fixation.

INCLUDE WHEN CITING Published April 11, 2022; DOI: 10.3171/CASE2289.

SUBMITTED February 22, 2022. **ACCEPTED** March 3, 2022.

© 2022 The authors, CC BY-NC-ND 4.0 (<http://creativecommons.org/licenses/by-nc-nd/4.0/>).

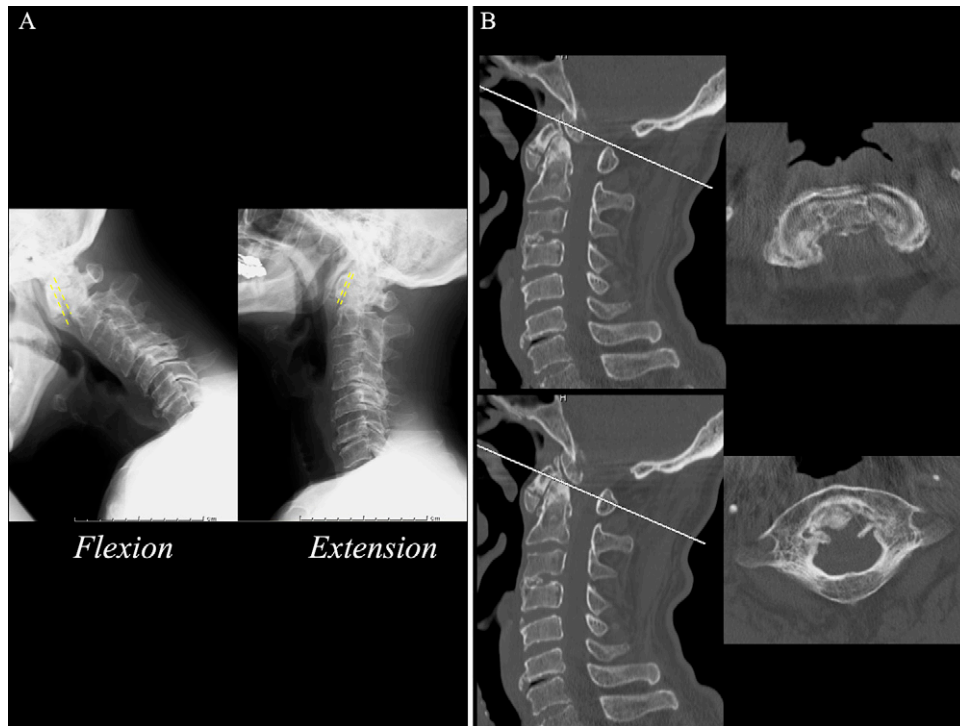


FIG. 1. Preoperative radiographs and CT scans. **A:** The atlantodental interval widened, and the posterior arch of the atlas moved forward in the neck flexion position. **B:** Ectopic ossification around the C1 anterior arch, C2 process, and anterior longitudinal ligament in the lower cervical spine. These findings implicated mechanical stress caused by atlantoaxial instability.

Herein, we report a case of ROP managed with combined C1–2 transarticular screw fixation (TA) and C1 laminoplasty with interlaminar bone transplant.

Illustrative Case

Presentation and Preoperative Course

A 67-year-old man presented with numbness that progressed from the left hand to the left lateral chest and the left leg. The symptom worsened if the neck was bent forward. The patient had no history of collagen disease, including rheumatic arthritis, or hemodialysis. Plain radiography revealed widening of the atlantodental interval, with a length of 4 mm, and anterior dislocation of the posterior arch of atlas with neck flexion. Dislocation was corrected with neck extension (Fig. 1A). Computed tomography (CT) showed ectopic ossification in front of the odontoid process and anterior arch of atlas as well as the anterior longitudinal ligament in the lower cervical spine (Fig. 1B). In addition, magnetic resonance imaging (MRI) revealed that the spinal cord was compressed by a solid mass behind the odontoid process with isosignal intensity on both T1- and T2-weighted images. Intramedullary high signal intensity was observed at the C1 level (Fig. 2A). Thus, the patient was diagnosed with cervical myelopathy caused by ROP after atlantoaxial instability. Then, combined C1–2 TA and C1 double-door laminoplasty, which simultaneously facilitate spinal cord decompression and interlaminar bone transplant, was performed.

Surgical Method

The patient was placed in the prone position under general anesthesia. Next, a midline posterior skin incision was established

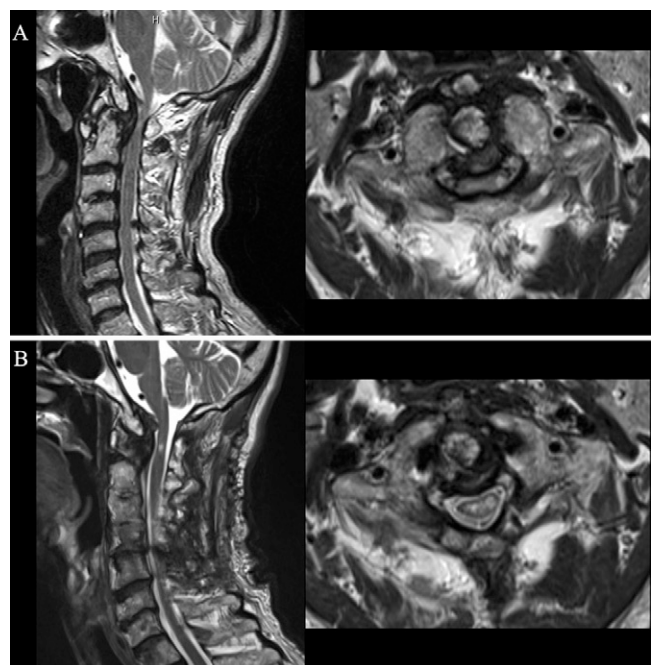


FIG. 2. Preoperative and postoperative MRI. **A:** Preoperative MRI showed that the retro-odontoid pseudotumor compressed the cervical spinal canal and a high-intensity area within the cervical spinal cord on the T1-weighted image. **B:** Postoperative MRI revealed that the cervical spinal cord was adequately decompressed at the C1 level.

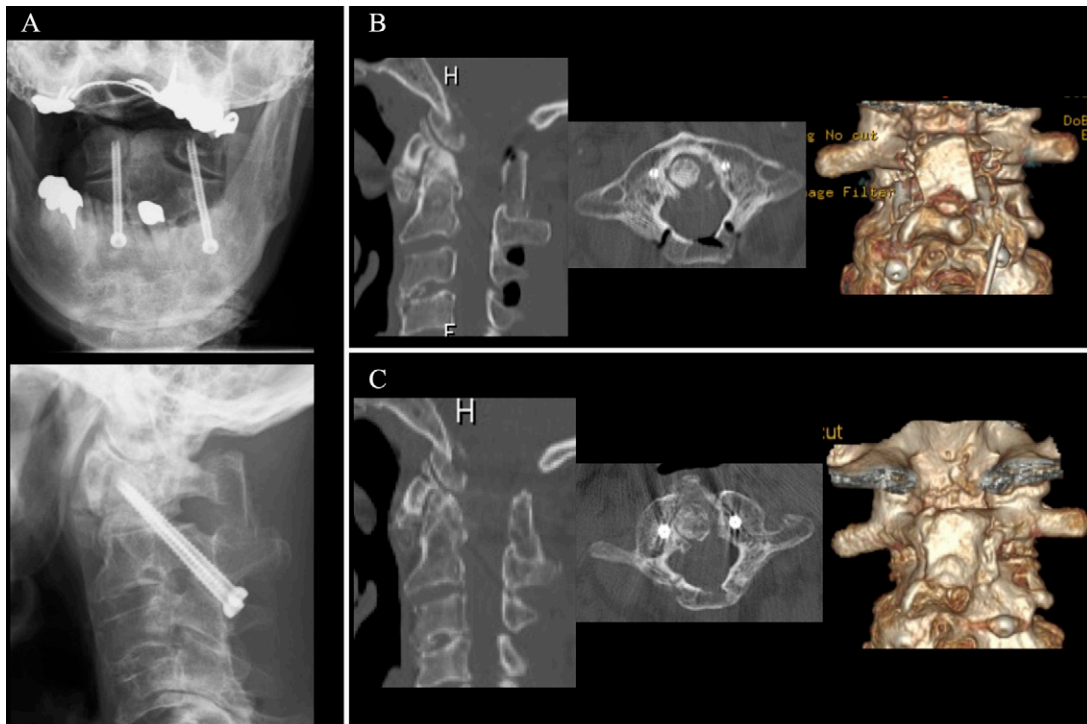


FIG. 3. Postoperative radiographs and CT scans. **A:** Radiographs revealed appropriate bilateral screw implantation using the Magerl technique. **B:** CT showed C1 double-door laminoplasty and interlaminar autogenous iliac bone implantation immediately after surgery. **C:** CT revealed satisfactory posterior bone union between the C1 and C2 levels 6 months after surgery.

to expose the posterior bony elements at the C1–2 levels. The posterior arch of atlas was cautiously exposed to the lateral side of the cervical canal and C2 isthmus. C1–2 TA using a lag screw (UCSS, Medtronic Sofamor Danek) was applied bilaterally by directly visualizing the pedicle under three-dimensional navigation guidance. Next, the middle part of the posterior arch of the C1 lamina was cut with a high-speed drill, and gutters were constructed on the bilateral groove of the posterior arch. Then, the bilateral laminae were lifted similarly to the method used in double-door laminoplasty. After decortication of the C2 laminae and spinous process, the autogenous bone strut harvested from the iliac bone was shaved between the bilateral edges of the opened C1 posterior arches and the C2 lamina and was then inserted. However, fixation was not performed. The volume of intraoperative blood loss was 60 mL.

Postoperative Course

His symptoms improved immediately after the surgery. There were no surgery-related complications. Postoperative MRI showed adequate spinal cord decompression at the C1 level (Fig. 2B). CT performed after 6 months revealed solid bone union of the bone graft in contact with the C1 and C2 laminae (Fig. 3).

Discussion

Observations

Pseudotumor resection using the transoral approach, which was introduced in 1980, is initially performed for the management of ROP.^{1,2,10} Although this method enables the direct removal of the

pseudotumor, it can possibly cause severe surgical complications, such as cerebrospinal fluid leakage and postoperative infections.¹¹ Therefore, the use of this strategy declined recently. On the contrary, posterior surgeries may be favorable. In cases without severe atlantoaxial instability, C1 laminectomy is often performed. Previous studies have reported that ROP regression can be achieved with C1 laminectomy alone.^{12,13} However, in some cases, C1 laminectomy caused recurrent myelopathy due to deterioration of instability and enlargement of ROP.^{5,11,14} Patients with this condition required a second surgery for posterior fixation. Accordingly, in C1 laminectomy, we need to acknowledge the risk of postoperative deterioration. Thus, even if the presence of atlantoaxial instability is not confirmed, posterior fixation is performed. With consideration of fixation range, some options, including O–C2 fixation and C1–2 fixation, are available. In cases in which the particular pathology is associated with ROP, including destruction of the O–C1 joint, occipitocervical malformation (i.e., C1 assimilation and tight posterior fossa), and ROP progression into the cranial base, O–C2 fixation and C1 laminectomy are performed.^{7,15} Although this method can secure a satisfactory bed for the graft bone, it has some disadvantages, including postoperative respiratory and swallowing difficulties because of moderate range of neck motion.^{16,17} Thus, the potential complications should be considered cautiously. For these reasons, C1–2 fixation and C1 laminectomy are selected in most cases.^{18,19}

Posterior atlantoaxial TA or screw-rod fixation (SR) using C1 lateral mass and a C2 pedicle screw have commonly been used for C1–2 stabilization. The fusion rates of the two methods are similar.²⁰ If C1 laminectomy is required, interlaminar bone transplant is

not performed. In TA, it is challenging to transplant bone grafts into the C1–2 facet joints because these joints must be preserved. By contrast, in SR, bone grafts are usually transplanted to the lateral atlantoaxial joint. Although this method has a high postoperative bone union rate,²¹ packing morselized bone grafts into the C1–2 facet joints is challenging based on our previous experience. That is, adequate bone grafting requires full exposure to the outside of the atlantoaxial joint. Copious bleeding occasionally occurs from the lateral venous plexus during exposure of the C1–2 articular joints. A previous study reported that the SR group had a higher volume of intraoperative blood loss than the TA group.²² Moreover, postoperative neuropathic pain is at times caused by C2 nerve root manipulation during graft area exposure in the lateral atlantoaxial joint.²³ In addition, the incidence of posterior scalp numbness is approximately 11.6%.^{24,25} In the present case, we selected TA with C1 laminoplasty. This method can help apply the C1 lamina for interlaminar bone grafting, thereby resulting in solid bony fusion between the C1 double-door laminae and the C2 laminae 6 months after surgery. In this case, the volume of intraoperative blood loss in TA was only 60 mL, and this value was less than that in SR (213–930 mL) in previous studies.^{26–29} Adequate spinal cord decompression was achieved between the opened C1 laminae. To the best of our knowledge, this is the first study about combined C1–2 TA and C1 laminoplasty with interlaminar bone transplant for ROP.

The TA technique requires preliminary reduction of C1 on C2 before screw placement, and it is associated with a risk for vertebral artery injury from an anatomical standpoint.^{30,31} However, this technique is reasonable for both cervical spinal cord decompression and securing the bone graft area, and it is correlated with a lower volume of blood loss than SR. The present study had some limitations. It is a single case report; therefore, more consecutive data are required, and future prospective clinical studies must be conducted to obtain a more definite conclusion.

Lessons

To date, there is no consensus regarding the appropriate surgical method for ROP. However, the treatment strategy should be determined according to the patient's status. Combined C1–2 TA and C1 laminoplasty with interlaminar autogenous iliac bone transplant can facilitate cervical spinal cord decompression and secure the bone graft area, which facilitates postoperative bone union and is associated with a lower volume of intraoperative blood loss. Thus, it is recommended for ROP.

Acknowledgments

We thank Enago for the English-language review.

References

- Sze G, Brant-Zawadzki MN, Wilson CR, Norman D, Newton TH. Pseudotumor of the craniocervical junction associated with chronic subluxation: MR imaging studies. *Radiology*. 1986;161(2):391–394.
- Crockard HA, Sett P, Geddes JF, Stevens JM, Kendall BE, Pringle JA. Damaged ligaments at the craniocervical junction presenting as an extradural tumour: a differential diagnosis in the elderly. *J Neurol Neurosurg Psychiatry*. 1991;54(9):817–821.
- Chikuda H, Seichi A, Takeshita K, et al. Radiographic analysis of the cervical spine in patients with retro-odontoid pseudotumors. *Spine (Phila Pa 1976)*. 2009;34(3):E110–E114.
- Young WF, Boyko O. Magnetic resonance imaging confirmation of resolution of odontoid pannus formation following C1/C2 posterior transarticular screw fixation. *J Clin Neurosci*. 2002;9(4):434–436.
- Kobayashi K, Imagama S, Ando K, Nishida Y, Ishiguro N. Postoperative regression of retro-odontoid pseudotumors treated with and without fusion. *Eur Spine J*. 2018;27(12):3105–3112.
- Sono T, Onishi E, Matsushita M. Radiographic risk factors and surgical outcomes for retroodontoid pseudotumors. *J Spinal Disord Tech*. 2014;27(6):E193–E198.
- Yamaguchi I, Shibuya S, Arima N, Oka S, Kanda Y, Yamamoto T. Remarkable reduction or disappearance of retroodontoid pseudotumors after occipitocervical fusion. Report of three cases. *J Neurosurg Spine*. 2006;5(2):156–160.
- Zileli M, Aköntürk N. Complications of occipitocervical fixation: retrospective review of 128 patients with 5-year mean follow-up. *Eur Spine J*. 2022;31(2):311–326.
- Bhimani AD, Chiu RG, Esfahani DR, et al. C1-C2 fusion versus occipito-cervical fusion for high cervical fractures: a multi-institutional database analysis and review of the literature. *World Neurosurg*. 2018;119:e459–e466.
- Pettersson H, Larsson EM, Holtås S, et al. MR imaging of the cervical spine in rheumatoid arthritis. *AJNR Am J Neuroradiol*. 1988;9(3):573–577.
- Yu SH, Choi HJ, Cho WH, Cha SH, Han IH. Retro-odontoid pseudotumor without atlantoaxial subluxation or rheumatic arthritis. *Korean J Neurotrauma*. 2016;12(2):180–184.
- Suetsuna F, Narita H, Ono A, Ohishi H. Regression of retroodontoid pseudotumors following C-1 laminoplasty. Report of three cases. *J Neurosurg Spine*. 2006;5(5):455–460.
- Kakutani K, Doita M, Yoshikawa M, et al. C1 laminectomy for retro-odontoid pseudotumor without atlantoaxial subluxation: review of seven consecutive cases. *Eur Spine J*. 2013;22(5):1119–1126.
- Notani N, Miyazaki M, Yoshiwa T, Ishihara T, Kanezaki S, Tsumura H. Dynamic paraspinous muscle impingement causing acute hemiplegia after C1 posterior arch laminectomy: a case report. *Medicine (Baltimore)*. 2017;96(50):e9264.
- Lagares A, Arrese I, Pascual B, Gómez PA, Ramos A, Lobato RD. Pannus resolution after occipitocervical fusion in a non-rheumatoid atlanto-axial instability. *Eur Spine J*. 2006;15(3):366–369.
- Miyata M, Neo M, Fujibayashi S, Ito H, Takemoto M, Nakamura T. O-C2 angle as a predictor of dyspnea and/or dysphagia after occipitocervical fusion. *Spine (Phila Pa 1976)*. 2009;34(2):184–188.
- Maulucci CM, Ghobrial GM, Sharan AD, et al. Correlation of posterior occipitocervical angle and surgical outcomes for occipitocervical fusion. *Evid Based Spine Care J*. 2014;5(2):163–165.
- Jun BY. Complete reduction of retro-odontoid soft tissue mass in os odontoideum following the posterior C1-C2 transarticular screw fixation. *Spine (Phila Pa 1976)*. 1999;24(18):1961–1964.
- Park JH, Lee E, Lee JW, et al. Postoperative regression of retro-odontoid pseudotumor after atlantoaxial posterior fixation: 11 years of experience in patients with atlantoaxial instability. *Spine (Phila Pa 1976)*. 2017;42(23):1763–1771.
- Kim JY, Oh CH, Yoon SH, Park HC, Seo HS. Comparison of outcomes after atlantoaxial fusion with transarticular screws and screw-rod constructs. *J Korean Neurosurg Soc*. 2014;55(5):255–260.
- Ishida W, Ramhmdani S, Xia Y, et al. Use of recombinant human bone morphogenetic protein-2 at the C1-C2 lateral articulation without posterior structural bone graft in posterior atlantoaxial fusion in adult patients. *World Neurosurg*. 2019;123:e69–e76.
- Lee SH, Kim ES, Sung JK, Park YM, Eoh W. Clinical and radiological comparison of treatment of atlantoaxial instability by posterior C1-C2 transarticular screw fixation or C1 lateral mass-C2 pedicle screw fixation. *J Clin Neurosci*. 2010;17(7):886–892.
- Conroy E, Laing A, Kenneally R, Poynton AR. C1 lateral mass screw-induced occipital neuralgia: a report of two cases. *Eur Spine J*. 2010;19(3):474–476.

24. Salunke P, Karthigeyan M, Futane S. Pros and cons of C2 nerve sectioning/preservation in posterior fusion for congenital atlantoaxial dislocation. *World Neurosurg.* 2018;118:e925–e932.
25. Kang MM, Anderer EG, Elliott RE, Kalthorn SP, Frempong-Boadu A. C2 nerve root sectioning in posterior C1-2 instrumented fusions. *World Neurosurg.* 2012;78(1-2):170–177.
26. Elliott RE, Kang MM, Smith ML, Frempong-Boadu A. C2 nerve root sectioning in posterior atlantoaxial instrumented fusions: a structured review of literature. *World Neurosurg.* 2012;78(6):697–708.
27. Xi YM, Zhang GQ, Chen BH, et al. Outcomes of posterior C(1-2) fusion for atlantoaxial instability or dislocation using pedicle screws of atlas and axis. Article in Chinese. *Zhonghua Wai Ke Za Zhi.* 2009;47(22):1722–1724.
28. Stulik J, Vyskocil T, Sebesta P, Kryl J. Atlantoaxial fixation using the polyaxial screw-rod system. *Eur Spine J.* 2007;16(4):479–484.
29. Schmidt R, Richter M, Gleichsner F, Geiger P, Puhl W, Cakir B. Posterior atlantoaxial three-point fixation: comparison of intraoperative performance between open and percutaneous techniques. *Arch Orthop Trauma Surg.* 2006;126(3):150–156.
30. Jain VK. Atlantoaxial dislocation. *Neurol India.* 2012;60(1):9–17.
31. Elliott RE, Tanweer O, Boah A, et al. Outcome comparison of atlantoaxial fusion with transarticular screws and screw-rod constructs: meta-analysis and review of literature. *J Spinal Disord Tech.* 2014;27(1):11–28.

Disclosures

The authors report no conflict of interest concerning the materials or methods used in this study or the findings specified in this paper.

Author Contributions

Conception and design: Fukunaga. Acquisition of data: Fukunaga. Analysis and interpretation of data: Fukunaga. Drafting the article: Fukunaga. Reviewed submitted version of manuscript: Fukunaga, Sasaki, Kishima. Approved the final version of the manuscript on behalf of all authors: Fukunaga. Study supervision: Yonenobu, Sasaki, Kishima.

Correspondence

Takanori Fukunaga: Iseikai Hospital, Osaka, Japan. tfukunaga_nsu@aol.com.