



Degenerative cervical myelopathy: Neuroradiological, neurophysiological and clinical correlations in 27 consecutive cases



C. Soda^a, G. Squintani^d, M. Teli^{c,*}, N. Marchesini^b, U.M. Ricci^a, A. D'Amico^b, F. Basaldella^d, E. Concon^d, V. Tramontano^d, S. Romito^d, N. Tommasi^e, G. Pinna^a, F. Sala^b

^a Department of Neurosurgery, AOUI Borgo Trento Hospital, Verona, Italy

^b Department of Neurosurgery, University of Verona, Italy

^c Department of Spinal Surgery, Rizzola Academy, San Donà di Piave, Italy

^d Neurology Unit, AOUI Borgo Trento Hospital, Verona, Italy

^e Department of Economics, University of Verona, Italy

ARTICLE INFO

Keywords:

Myelopathy
Cervical spine
Intraoperative neuromonitoring
Laminotomy
Outcome

1. Introduction

Degenerative cervical compressive myelopathy (DCCM) is a progressive degenerative spinal cord disease and the leading cause of spinal cord dysfunction in the elderly population worldwide (Akter et al., 2020; Chen et al., 2001; Fehlings et al., 2017a; Nouri et al., 2015). Pathologically, DCCM is characterized by spinal cord compression due to progressive narrowing of the diameters of the spinal canal secondary to degenerative changes in the cervical spine (New et al., 2014). Clinically, DCCM may present with numbness, weakness, neck pain, loss of dexterity and gait problems (Fehlings et al., 2017b; Lubelski et al., 2016). Signal alterations in T1 and T2 magnetic resonance imaging (MRI) sequences can reflect pathological changes in the spinal cord and become reliable predictors of surgical outcomes (Wang et al., 2016; Nouri et al., 2017a). Intraoperative neurophysiological monitoring (IONM) is at present widely applied in spinal surgery for deformity and cancer, with the aim of predicting and possibly preventing postoperative neurological worsening (Devlin, 2007; Di Martino et al., 2019; Tamaki and Kubota, 2007). Within IONM, the direct wave (D-wave) has been proven to be the strongest predictor of long-term motor outcome in spinal cord tumor surgery, but its role in spinal decompression for DCCM remains undetermined (Deletis and Sala, 2008; Sala et al., 2006, 2007, 2019). Overall, the value of IONM in DCCM surgery has been explored in a few studies (Park et al., 2018;

Resnick et al., 2009; Takeda et al., 2018; Sutter et al., 2015). Anecdotally, Wang and coworkers have recently reported that patients with intraoperative improvements of motor evoked potentials (MEPs) during cervical cord decompression may enjoy better early and long-term neurologic recovery (Wang et al., 2016). Therefore, our primary aim was to explore both radiological and neurophysiological changes and any correlation between MRI features and neurological outcome in patients submitted to laminotomy for DCCM.

2. Methods

The present prospective study was carried out on a sample of patients with multilevel cervical myelopathy who were treated with posterior decompression and who agreed to voluntarily undergo a clinical and neurophysiological evaluation before, during and 6 months after surgery. Informed consent from all patients and approval from the Institutional board were obtained to collect the data presented in this study.

Clinical evaluation. On admission and at follow-up, all patients underwent a detailed neurological examination. The modified Japanese Orthopedic Association score (mJOA) was administered pre-operatively, at discharge and 6 months after surgery (Kopjar et al., 2015). The neurological improvement rate was calculated by the following equation: [(6-months-postoperative JOA score-preoperative JOA score)/(18 (full score) - preoperative JOA score) *100%] (Nouri et al., 2015). Patients

* Corresponding author. Department of Spinal Surgery, Rizzola Academy, Via Gorizia 1, 30027, San Donà di Piave, Italy.
E-mail address: teli@rizzola.it (M. Teli).

<https://doi.org/10.1016/j.bas.2022.100909>

Received 10 April 2022; Received in revised form 4 June 2022; Accepted 24 June 2022

Available online xxx

2772-5294/© 2022 The Authors. Published by Elsevier B.V. on behalf of EUROSPINE, the Spine Society of Europe, EANS, the European Association of Neurosurgical Societies. This is an open access article under the CC BY-NC-ND license (<http://creativecommons.org/licenses/by-nc-nd/4.0/>).

Abbreviation and acronyms

DCCM:	Degenerative compressive cervical myelopathy
IONM:	Intraoperative neuromonitoring
MEP:	Motor Evoked Potential
i-MEP:	intra-operative MEP
i-AMEP:	intra-operative MEP Amplitude
pr-AMEP:	pre-operative MEP Amplitude
pr-LMEP:	pre-operative MEP latency
p-MEP-6m:	post-operative MEP at 6 months
p-AMEP-6m:	post-operative MEP amplitude at 6 months
p-LMEP-6m:	post-operative MEP latency at 6 months
SEP:	Sensory evoked potential
i-SEP:	intra-operative SEP
pr-SEP:	pre-operative SEP
i-ASEP:	intra-operative DSEP amplitude
p-SEP 6 m:	post-operative SEP at 6 months
p-ASEP-6m:	post-operative SEP amplitude at 6 months
D-wave:	direct wave
i-AD-wave:	intraoperative D wave amplitude
i-LD-wave:	intraoperative D wave latency

were categorised into mild ($mJOA \geq 15$), moderate ($mJOA = 12-14$) and severe ($mJOA \leq 11$) disability groups. A difference in one point detected on post-operative mJOA score was considered as significant minimum clinically important difference (MCID), as per accepted estimates (1–2 points) for cervical myelopathy patients (Tetreault et al., 2015a).

MRI Analysis. Based on sagittal spinal cord MRI features and with the help of an expert neuroradiologist we considered 2 main groups based on the presence of signal changes only on T2WI (*T2WI-only*) or either on T2WI + T1WI (*T2WI + T1WI*) (Mizuno et al., 2003; You et al., 2015) and 2 subgroups, taking into account the border of the lesion: *diffuse-T2WI* i.e. poorly delineated hyperintense areas in T2 weighted images, and *distinct T2WI* i.e. well demarcated wedge or nodular shaped areas also in T2 weighted images (Fig. 1 and Table 2), both sagittal and axial. For each

MRI pattern, clinical and neurophysiological outcomes were analyzed.

IONM setting for intraoperative neurophysiological assessment. Intra-operative neurophysiological monitoring was performed using a dedicated equipment (ISIS Neurostimulator, INOMED, Germany). MEPs and somatosensory evoked potentials (SEPs) baseline values were saved immediately after prone positioning of the patient. At laminar exposure all potentials were re-tested and compared with the baseline values; an electrode for D-wave recording was positioned in the epidural space through an interlaminar bone window distal to the level of cord compression. After lifting the laminae, IOMN signals were re-checked to detect any changes from the previous recordings. A final run of IOMN signals was achieved at the end of the surgical procedure. MEPs were obtained performing transcranial electrical stimulation using cork-screw electrodes placed on C1, C2, C3 and C4 according to the *International 10–20 System (SI)*²⁵. Trains of five pulses were delivered at intensities ranging from 50 mA to 200 mA; pulse width was set to 500 msec and inter-stimulus interval to 4 msec. MEPs were recorded using subdermal needle electrodes placed bilaterally in the extensor digitorum communis (EDC) and the abductor pollicis brevis (APB) for the upper limbs and in the tibialis anterior (TA) and the abductor hallucis brevis (AHB) for the lower ones. D-waves were elicited performing transcranial electrical stimulation using cork-screw electrodes placed on C1 and C2 according to the SI. Single pulse stimulation was delivered at intensity of 200 mA; the pulse width was set to 500 msec. The recording electrode was placed in the epidural space distal to the level of cord decompression. SEPs were obtained with electrical stimulation of the median nerve at the wrist for the upper limbs and posterior tibial nerve at the ankle for the lower limbs (rate was 3.7 Hz, intensity between 20 mA and 30 mA, pulse width 500 msec). Cortical responses were recorded from cork-screw electrodes placed on C3', C4' and Cz' referred to Fz according to SI. MEPs, SEPs and D wave amplitude and latency were collected before and after decompression.

An increase in amplitude higher than 50% of either intra-operative MEP amplitude (*i-AMEP*), intra-operative SEP amplitude (*i-ASEP*) or intraoperative D wave amplitude (*i-AD-wave*) at closing after decompression versus the opening baseline record was considered a 'positive change', while a reduction in amplitude to lower than 50% of the baseline record was considered as a 'negative change'.

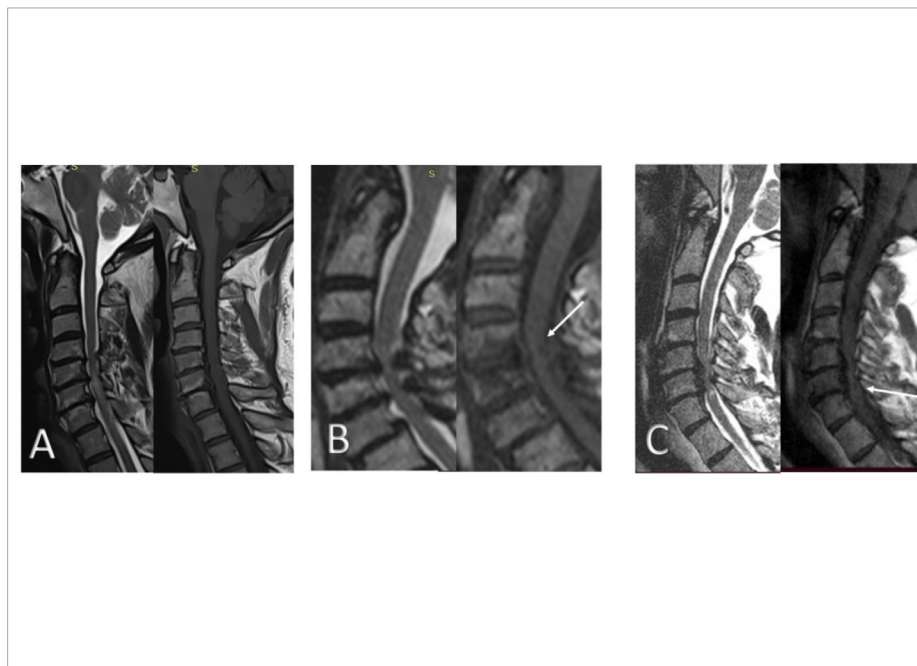


Fig. 1. Different MRI pattern based on sagittal signal changes on T2 Weighted and T1 Weighted Images (A) T2WI-only type with diffuse border and no signal change on T1WI (B) T2WI + T1WI (see arrow) with diffuse border on T2WI (C) T2WI + T1WI (see arrow) with distinct border on T2WI.

Pre- and post-operative neurophysiological assessment. All patients were submitted to upper and lower limbs MEPs and SEPs. Neurophysiological tests were performed preoperatively and six months after surgery. MEPs were recorded from the Abductor Pollicis Brevis (APB) muscle (or Abductor Digiti Minimi - ADM if signs of tunnel carpal syndrome were present) in the upper limbs, and from the Abductor Hallucis (AH) muscle in the lower limbs. Stimulation was performed with a circular coil at 150% of motor threshold. SEPs from the upper limbs were obtained by stimulating the median nerve (or ulnar nerve if electrophysiological signs of tunnel carpal syndrome were present). Recording electrodes were positioned at the Erb's point ipsilateral to the stimulation (referred to contralateral Erb), CV7 (referred to jugular site) and from C3'/C4' contralateral to stimulation (referred to C4'/C3' ipsilateral to stimulation and Fz), according to SI. SEPs from the lower limbs were obtained by stimulating the tibial nerve at the ankle; recording electrodes were positioned at the popliteal fossa (bipolar recording), T10 (referred to hip contralateral to stimulation), Cz, C ipsilateral to stimulation (referred to Fpz) and FPZ referred to lobe ipsilateral to stimulation. Bipolar stimulation (0.1 msec duration, 3.3 Hz frequency) was performed at motor threshold. A band pass filter was fixed at 10 Hz-3KHz for the upper limbs and at 10 Hz-2KHz for the lower limbs. MEPs' and SEPs' cortical amplitude, latency, and central conduction time (CCT) were analyzed before and after surgery. An increase in amplitude higher than 50% in either post-operative MEPs at 6 months (*p*-AMEP 6m), and or post-operative SEP amplitude at 6 months (*p*-ASEP 6m) compared to the pre-operative values, were considered as 'positive change'.

Surgical technique. Anaesthesia was maintained using Propofol, Remifentanyl and Fentanyl (intermittent infusion), based on haemodynamic response. No muscle relaxant or inhalation agents (sevoflurane or nitrous oxide) were administered during IONM recording. An open door laminoplasty as described by Hirabayashi (Hirabayashi et al., 1983) and modified by our group as reported in the past by Faccioli and co-workers, was used in all patients to decompress the cervical spinal cord (Faccioli et al., 1987). The laminae were exposed through a midline incision followed by sub-periosteal bilateral dissection of the splenius and semispinalis capitis, lower semispinalis cervicis, and multifidus muscles. Unlike in the original Hirabayashi's technique, the spinal process and interspinous ligament were both removed. Before any decompression of the spinal cord, a D-wave probe was inserted in the epidural space through an interlaminar window immediately distal to the more caudal laminotomy. A high-speed drill with a 2 and 4 -mm diamond burr was used to make a hinge medial to the lamino-articular junction, within the outer cortical margins of the lamina. Each lamina was bent to the hinge side, then gently lifted to increase space in the spinal canal and stabilised with a 3/0 Mersilene stitch to the paravertebral muscle (Fig. 2). Haemostasis was obtained with a combination of bipolar cautery and absorbable haemostatic products. An extradural drain was routinely placed and then removed 24 h after surgery. Perioperative antibiotic prophylaxis with Cefazolin was administered 15–60 min before incision and continued for 24 h. A combination of mechanical compression with stockings and low molecular weight heparin was used for prevention of

venous thromboembolism. All patients were offered a soft collar for better postoperative comfort.

Statistical Analysis. With the aim of facilitating correlation with clinical outcome and preoperative MRI pattern, we extracted the average sum of the overall percent changes for amplitude and latency of the evoked potentials recorded at upper (ABP or ADM muscles) and lower limbs (AHB muscle).

Statistical analysis was performed using both Stata and Microsoft Excel 365 MSO, 2018. The Chi-square test was used for dichotomous data to compare pre-operative characteristics on MRI and improvement of at least 1 point on the mJOA scale at 6 months; the same statistical evaluation was used to compare MRI features and intra and post-operative neurophysiological improvement over >50% of the baseline. Student's *t*-test was used to compare changes in mJOA scores pre- and post-operatively, as well as neurophysiological data before and after surgery. A linear regression was used to investigate correlation among MRI features, neurophysiological variation, and clinical outcome, with the threshold of a change of 1 point in the score of the mJOA scale. A regression test was also used to assess the effect of independent variables (e.g., sex, age, duration of symptoms, preoperative mJOA score) on the dichotomised long term neurophysiological and clinical outcome (improved or not improved). For all tests, a *p* value of <0.05 was considered significant.

3. Results

Twenty-seven patients affected by DCCM were enrolled between March 2017 and October 2018. The average age of the cohort was 63.1 years (range, 42–84). Males accounted for 55.5% (15) and females for 44.4% (12) of the enrolled patients. The most common symptom at presentation was gait instability (10 patients, 37%). On admission, 15 patients (55.5%) had a mild disability, 10 patients (37%) had a moderate and 2 (7.4%) a severe disability according to the mJOA classification. General demographics are reported in Table 1. No association at regression analysis was found between pre-operative MRI patterns and pre-operative mJOA score. The average duration of symptoms was 26.7 months before admission, and patients with *T2WI-only* MRI patterns had shorter clinical histories (15.07 months on average) than those with *T2WI + T1WI* patterns (38.3 months on average).

At the 6 months follow-up, 17 patients (62.9%) improved their mJOA score of almost 1 point, with a mean recovery ratio (RR) of 69%. No patient showed deterioration of their mJOA score at 6 months, while 10 (37%) had a mJOA score at follow-up that was like the one obtained preoperatively. A significant difference was found between the mean preoperative mJOA score and the score detected at discharge (14.7 vs 15.77; *p* = 0.047) and at 6 months (14.7 vs 15.8; *p* = 0.0309) respectively (Table 3). On logistic regression, no relationship was found between independent variables (e.g., sex, age, duration of symptoms, preoperative mJOA score) and mJOA recovery at the last follow up. Similarly, no relationship was found between the same independent variables and *p*-AMEP-6m positive change.

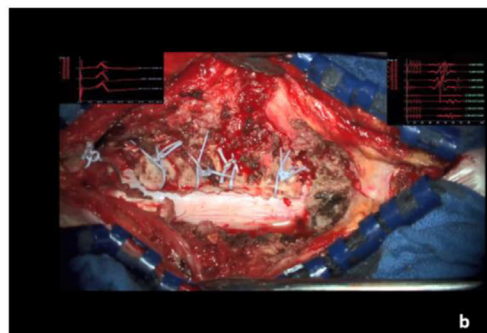
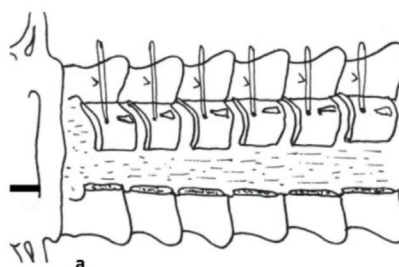


Fig. 2. Open door laminoplasty as described originally by Hirabayashi and modified by our group as described by Faccioli et al. (You et al., 2015): spinous processes are drilled away and laminae are bent to the hinge side. In order to keep the flap in this position, sutures are passed through drill holes in the laminae and corresponding paravertebral muscles. (a) schematic drawing with gentle permission of Faccioli et al. (You et al., 2015); (b) intraoperative photo showing an adequate spinal cord decompression with improvement of i-D-wave and i-AMEP.

Table 1
Baseline patient characteristics (n = 27): age, gender, mJOA score, clinical examination.

		Mean value	n	%
Age (years)		63 (42–84)		
Male:Female			15:12	55.5–44.5
Duration of symptoms (months)		26.7 (3–212)		
			n	%
Onset Symptom	Gait impairment		10	37
	Cervico-brachial pain		6	22.2
	Pain lower limbs		1	3.7
	Clumsyness		2	7.4
	Motor impairment		3	11
	Sensory changes		4	14.8
	Paraesthesiae		1	3.7
		Mean value	n	%
Pre-op mJOA		14,7 (11–18)		
	Mild disability mJOA ≥ 15		15	55.5
	Moderate disability mJOA 12–14		10	37.03
	Severe disability mJOA ≤11		2	7,4
			n	%
Motor impairment	Clumsy hands		17	62.9
	Pyramidal signs (<i>Babinski, impaired gait, hyperreflexia, spasticity</i>)		19	70.3
	Limb weakness		17	62.9
Sensory symptoms			19	70.3

Table 2
MRI Sagittal signal changes alterations: signal pattern changes on T2WI, T2WI + T1WI and the border of the lesion (Diffuse type and Distinct Type).

MAIN GROUP	n	Diffuse	distinct
T2WI only	13	11	2
T2WI + T1WI	14	6	8
Tot	27	17	10

Table 3
Clinical improvement (mJOA score) after cervical decompression at discharge and at last follow up (6 months).

Table 3 A	Pre-op score	Score at discharge	p-value	6-mo follow-up	p-value
Mean mJOA score	14.71	15.77	0.047^a	15.8	0.0309^a

^a Bold values refer to statistical significance.

Neurophysiological data and clinical outcome. Recordable *i*-MEPs were obtained in 25 patients (92.6%). A significant increase in *i*-AMEPs amplitude at upper and lower limbs after decompression was recorded (from 0.024 to 0.419 μV, p = 0.00002 for upper limbs and from 0.0882 to 0.168 μV, p = 0.004 for lower limbs). An increase in MEP amplitude (*i*-AMEP) over 50% was recorded in 21 patients (84%).

A stable *D*-wave could be recorded in 19 patients (70%). An increase in intraoperative *D* wave Amplitude (*i*-AD-wave) was observed in 9 patients (47.3%), although an improvement over 50% after laminotomy was recorded in only 1 patient. No significant reduction of *i*-LD-Wave or improvement of *i*-AD-Wave was recorded after spinal cord decompression except in one case.

Post-operative neurophysiological assessment. Outpatients' neurophysiological data was obtained in 26 patients (96.2%). A significant reduction

in post-operative MEP latency (from 24.47msec to 23.43; p = 0.01) and central conduction time (from 9.17 msec to 8.53; p = 0,03), associated to a significant increase of MEPs amplitude (from 1.91 μV to 2.29; p = 0.001) was recorded in the upper limbs. With regards to the lower limbs, there was a significant reduction of CCT (from 16.88 to 15.61; p = 0.02) and an increase in MEPs amplitude (from 0.98 to 1.46; p = 0.002). In 4 patients, cortical MEPs recorded from upper and lower limbs reappeared after surgery. In 2 patients transcranial MEPs from the lower limbs re-emerged after decompression. No significant change was obtained from SEPs data after surgery. For details, please see [Table 4](#).

MRI features, IONM, post-operative neurophysiological and clinical outcome. A *T2WI-only* pattern was described in 13 patients (48%) while a *T1WI + T2WI* one in 14 (52%). A diffuse-border signal change on T2WI (*diffuse-T2WI*) was present in 17 patients (62.9%) and its distribution in the 2 main groups was 11 for *T2WI-only* and 6 for *T1WI + T2WI* groups, respectively.

([Table 2](#)). A significantly higher proportion of patients in the *T2WI-only* pattern group improved their mJOA score at follow-up, compared with the *T1WI + T2WI* pattern group (84.6% vs 42.9%; p = 0.0284) ([Table 5](#)).

All patients with diffuse border of the two main groups (either *T2WI-only* and *T1WI + T2WI*) and concomitant increase of *i*-AMEP over 50% (n = 14) improved their clinical outcome at the last follow-up, while patients with a distinct border (belonging to either the *T2WI-only* or the *T1WI + T2WI* group) and concomitant increase of *i*-AMEP over 50% (n = 7) did not show any clinical improvement ([Table 6](#), [Figs. 3 and 4](#)).

Remarkably, the rate of patients with *i*-AMEP increase (>50%) after cervical decompression was higher in patients with pre-operative *T2WI-only* signal pattern than *T2WI + T1WI* group (100% vs 69%; p = 0.036) ([Table 5](#)). Patients with *T2WI + T1WI* pattern showed instead only a mild significant neurophysiological improvement on *p*-AMEP 6m compared to those with *T2WI-only* alteration on MRI (85.7%, n = 12/14 vs 50%, n = 6/12; p = 0.049) ([Table 5](#)).

No clinical differences were seen at the last follow-up between

Table 4

Neurophysiological SEP and MEP parameters before and 6 months after surgery SEP: somatosensory evoked potentials; MEP motor evoked potentials; PRE: before surgery; POST: six months after surgery; lat: latency; ampl: amplitude; CCT: central conduction time; SD: standard deviation.

	SEP (upper limb)							MEP (upper limb)					
	N20 lat		N20 ampl		CCT (N20-N13)			MEP lat		MEP ampl		CCT	
	PRE	POST	PRE	POST	PRE	POST		PRE	POST	PRE	POST	PRE	POST
Mean	21.06	20.87	3.30	3.69	6.84	6.73	mean	24.47	23.43	1.91	2.29	9.17	8.53
SD	1.49	1.10	1.78	1.83	1.18	0.84	SD	4.43	3.74	1.54	1.57	3.50	3.13
t-test	0,10		0.07		0.48		t-test	0.01^a		0.01^a		0.03^a	

	SEP (lower limb)							MEP (lower limb)					
	P40 lat		P40 ampl		CCT (N22-NP40)			MEP lat		MEP ampl		CCT	
	PRE	POST	PRE	POST	PRE	POST		PRE	POST	PRE	POST	PRE	POST
Mean	44.64	44.67	1.93	1.83	19.14	19.61	mean	43.08	42.51	0.98	1.46	16.88	15.61
SD	3.70	3.41	1.17	0.97	2.32	2.70	SD	5.72	5.72	0.81	1.15	4.81	4.37
t-test	0.91		0.41		0.13		t-test	0.21		0.002^a		0.02^a	

^a Bold values refer to statistical significance.

Table 5

Relationship between pre-operative MRI Pattern and, i-AMEP, p-AMEP and mJOA score improvement at last follow-up.

MRI PATTERN	mJOA 6mo Improved	mJOA 6mo not improved	tot	P	i-AMEP >50%	i-AMEP <50%	Tot	P	p-AMEP 6 m >50%	p-AMEP 6 m <50%	tot	P
T2WI + T1WI	6 42.9%	8 57.1%	14	0.0284	9 69%	4 30%	12	0.036	12 85%	2 14%	14	0.049
T2WI only	11 84.6%	2 15.4%	13		12 100%	0	13		6 50%	6 50%	13	
	17	10	27		12	13	25		18	8	26	

*Bold values refer to statistical significance.

Table 6

Relationship between diffuse Vs distinct MRI patterns and clinical outcome.

	mJOA Improved (n)		mJOA not improved (n)		P-Val
	n	%	n	%	
	Diffuse border + i-AMEP improved (n = 14)	14	100	0	
The Distinct border + i-AMEP improved (n = 7)	0	0	7	100	

*Bold values refer to statistical significance.

patients with pre-operative T2 WI-only signal changes who presented an i-AMEP increase and those with the same radiological pattern who did not show any change of i-AMEP.

In order to investigate not only the total number of patients improving, but the range of improvement we evaluated the mean pre-operative, post-operative and 6 months mJOA score in the following subgroups: T2WI-only, T2WI + T1WI, diffuse/distinct border on MRI, i-AMEP change lower or higher than 50%, p-AMEP change lower or higher than 50%.

Patients with T2WI -only pattern showed a mean preoperative and post-operative mJOA score of 14.6 and 16.15 respectively (p=0.034), that became 16.3 at 6 months after surgery (p=0.02).

Patients with T2WI + T1WI pattern showed a non-significant range of improvement between mJOA score before surgery (14.7), after surgery (15.4) (p=0.39) and at 6 months (15.6) (p=0.2).

A significant range of improvement was seen in the diffuse T2WI subgroup (preoperative mJOA score: 14.58; post-operative: 16.9; p=0.004; 6 months f-up: 16.52, p=0.0018) while no variation was seen for the distinct-T2WI subgroup of patients (mean pre-operative mJOA: 14.9; mean post-operative mJOA: 14.9; mean f-up mJOA: 14.9).

Patients with i-AMEP >50% showed a significant mean score improvement at 6 months (14.76 vs 16.14; p=0.03) but not at 6 months f-up (14.76 vs 15.8; p=0.1). No important variation was seen for i-AMEP <

50% patients (15.2 vs 15.7 vs 16).

Similarly, the subgroup with p-AMEP > 50% showed a significant change both in the post-operative (14.83 vs 15.83; p = 0.08) and 6 months f-up mJOA scores (14.83 vs 16.16; p=0.03), while the improvement of the scores in the subgroup p-AMEP <50% was not relevant (14.6 vs 16 vs 15.5 respectively).

4. Discussion

The definition of reliable and affordable prognostic factors in the decision-making process of surgical treatment for DCCM can be challenging. Many variables have been tested to date. Namely, duration of symptoms, preoperative neurological condition, age and smoking habit are most frequently cited predictors of neurological outcome (Tetreault et al., 2015b; Uchida and Nakajima, 2014). This study focused on evaluating the relationship between positive changes during IONM, preoperative MRI characteristics on sagittal and axial view and functional improvement in patients with DCCM using mJOA score before and at 6 months after surgery.

To the best of our knowledge, no studies published so far have focused on the evaluation of potential relationships between pre-operative MRI patterns, IONM including D-wave, outpatient neurophysiological data before and after surgery and clinical outcome in DCCM. According to previous studies, IONM can verify the functional integrity of the corticospinal tracts with a high sensitivity and specificity (Hilibrand et al., 2004). Current clinical guidelines for spinal surgery recommend multimodal IONM including SEPs and MEPs, as a reliable and valid diagnostic instrument to assess spinal cord integrity (Sala et al., 2007, 2019; Hilibrand et al., 2004; Hadley et al., 2017). Some authors have provided an electrophysiological method useful to reach a prognostic evaluation of cervical cord recovery for DCCM patients. Wang and Park observed that DCCM patients have a favorable prognosis in terms of neurological recovery when they demonstrate an increase in i-AMEP (>50%) during cervical spinal cord decompression (Wang et al., 2016; Park et al., 2018). The D-wave has proven to be the strongest predictor of long-term motor outcome: its preservation above 50% of the baseline


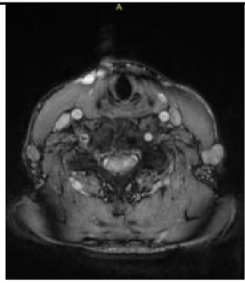




Pre-operative MRI			Pre-op mJOA	Recovery rate
			16	100%
Post-operative MRI			Post-op mJOA	
			18	

Fig. 3. This is a 51-year-old woman with MRI Diffuse-T2WI pattern and mild preoperative disability (16 mJOA). Amplitude D wave (i-AD-wave) and intraoperative MEP (i-AMEP) improvement could be seen after surgical decompression. There was also an amplitude MEP increase 6 months later (p-AMEP-6m) with a complete functional recovery at the last follow-up.







Preoperative MRI			Pre-op mJOA	Recovery rate
			14	50%
Post-operative 6 months MRI			Post-op mJOA	
			16	

Fig. 4. A case with MRI T2WI + T1WI pattern: 63 years old male with pre-operative moderate disability (mJOA: 14). No intraoperative neurophysiological improvement (i-AD-wave and i-AMEP increase) after decompression was detected. An improvement of MEP amplitude (p-MEP-6m) and clinical scores could be seen at last follow-up (6 months even with pre-operative T1 hypo-intensity on MRI).

amplitude typically correlates with either no deficit, if muscle MEPs are preserved, or only a transient deficit when muscle MEPs are lost (Deletis and Sala, 2008; Sala et al., 2007; Resnick et al., 2009; Hadley et al., 2017).

i-MEPs can detect the functional integrity of the corticospinal tracts with high sensitivity and specificity. Most studies mainly focused on amplitude decrement of *i*-MEP alone or in combination with latency increase to predict post-operatively paralysis (Sala et al., 2006; Quiñones-Hinojosa et al., 2005; Witiw et al., 2018; Zileli et al., 2019). Others demonstrated that an increase in MEP amplitude was related to post-operative functional improvement (Wang et al., 2016; Park et al., 2018; Nouri et al., 2017b; Kobayashi and Ando, 2018). Park and coworkers reported functional improvement one month after surgery in patients with an increase of *i*-AMEP >50% and a decrease in latency >10% (Park et al., 2018). However, no significant differences were recorded at 6 months between patients with or without positive intraoperative changes. Wang and coworkers pointed out that MEP amplitude is probably more accurate in predicting the surgical outcome than MEP latency during intraoperative spinal cord monitoring (Wang et al., 2016). Both authors agree that SEPs are not related to significant clinical improvement and that the main limit of SEPs recording is that they reflect function primarily located in the posterior columns of the spinal cord (Wang et al., 2016; Park et al., 2018).

This study has several limitations including the enrolment of a small number of patients with DCCM and a limited percentage of patients with severe disability (mJOA <12). Furthermore, the adoption of a 1-point improvement in mJOA score as MCID for cervical myelopathy could overestimate the treatment effect. Nevertheless, in the present analysis, a significantly higher proportion of patients in the *T2WI-only* pattern group improved their mJOA score at follow-up, while patients with the *T1WI + T2WI* pattern group did not. In addition, all patients with diffuse border of the two main groups (either *T2WI-only* and *T1WI + T2WI*) and concomitant increase of *i*-AMEP over 50% improved their clinical outcome at the last follow-up, while patients with a distinct border (either belonging to *T2WI-only* or *T1WI + T2WI* groups) and concomitant increase of *i*-AMEP over 50% did not show any clinical improvement. This result might suggest that inflammatory changes within the compressed spinal cord may be reversible after decompression, and that clinical improvement could be due to a reduction of intramedullary oedema, with micro-reperfusion and reductions in activation of microglia and astrogliosis (Tamaki and Kubota, 2007; Park et al., 2018; Kopjar et al., 2015; Mizuno et al., 2003; Pratheesh et al., 2014; Holly et al., 2009). Moreover, the rate of patients with *i*-AMEP increase (>50%) after cervical decompression was higher in patients with pre-operative *T2WI-only* signal pattern than *T2WI + T1WI* group. A significant range of improvement in the mean value at the mJOA score between pre-operative, post-operative and last follow-up was seen in the *T2WI-only*, *diffuse T2-WI*, *i*-AMEP>50 and *p*-AMEP >50 subgroups.

We confirm that MEP amplitude is probably more effective in predicting the surgical outcome than MEP latency or SEPs during intraoperative spinal cord monitoring. We have also demonstrated that *i*-SEPs do not change after spinal decompression, do not correlate with clinical outcomes, and reflect a low sensitivity (Wang et al., 2016; Deletis and Sala, 2008; Park et al., 2018; Hilibrand et al., 2004).

Patients with *T2WI + T1WI* pattern showed instead only a mild significant neurophysiological improvement on *p*-AMEP 6m compared to those with *T2WI-only* alteration on MRI. Different pre-operative MRI signal patterns can reflect different pathological grades of spinal cord degeneration and, as already suggested, are reliable prognostic factors of surgical outcomes (Chen et al., 2001; Nouri et al., 2017a; Park et al., 2018; Kopjar et al., 2015; Witiw et al., 2018; Kobayashi and Ando, 2018; Tetreault et al., 2016). A stepwise trend toward increasing impairment from no signal change to *T2WI-only* and *T2WI + T1WI* has been observed, with the last pattern apparently associated with permanent injury and decreased functional recovery after surgery^{9,31}.

Further neurophysiological improvements in patients with chronic

parenchymal injury, as in the *T2WI + T1WI* radiological pattern, could be explained, in our opinion, by an increased arterial supply and a consequent restoration of blood flow and recovery of neural transmission in local areas that are not yet infarcted (Nouri et al., 2015, 2017a; Wang et al., 2016; Kopjar et al., 2015; Uchida and Nakajima, 2014).

Diffusion Tensor Imaging (DTI) MR and spinal cord fiber tracking might prove useful tools for DCCM imaging, as recently demonstrated by high fractional anisotropy at the site of compression being related to better functional outcomes (Tetreault et al., 2015a; Witiw et al., 2018; Vidal et al., 2017). In the future, correlation with clinical and neurophysiological data with DTI could provide a more precise characterization of DCCM (Jones et al., 2013). Furthermore, a more precise analysis of the radiological patterns, including the borders of the areas of signal alteration, could offer more insights (Xu et al., 2020).

In previous studies the most common predictors of surgical outcome for patients with DCCM were age, duration of symptoms and severity of myelopathy (Fehlings et al., 2017a; Faccioli et al., 1987; Holly et al., 2009; Tetreault et al., 2016; Vidal et al., 2017). Nevertheless, in our sample size, the duration of symptoms did not correlate with clinical outcome, as we observed similar clinical and neurophysiological improvements 6 months after decompression in patients with chronic intramedullary signal alteration (*T2WI + T1WI*) who had the highest average duration of symptoms.

5. Conclusion

Cervical spinal cord decompression for DCCM with a modified Hirabajashi's open door laminoplasty as described above may not only offer stabilisation of clinical parameters but also a significant recovery of neurological function in a high proportion of patients, as shown in this series. Patients with an intraoperative increase of *i*-AMEP higher than 50% seem to have a better overall clinical outcome. A *T2WI-Only* pattern on preoperative MRI may be considered a positive prognostic factor for clinical and neurophysiological improvement 6 months after surgery. A post-operative clinical improvement can be expected in about half of patients with *T2WI + T1WI* pattern who also show diffuse border on sagittal *T2WI* pattern.

In conclusion, IONM can not only prevent neural injury, but in conjunction with MRI predict neural recovery after posterior decompression for DCCM.

Declaration of competing interest

The authors declare the following financial interests/personal relationships which may be considered as potential competing interests: Marco Teli reports a relationship with Medtronic Inc that includes consulting or advisory and travel reimbursement.

References

- Akter, F., Yu, X., Qin, X., Yao, S., Nikrouz, P., Syed, Y., et al., 2020. The pathophysiology of degenerative cervical myelopathy and the physiology of recovery following decompression. *Front. Neurosci.* 138. <https://doi.org/10.3389/fnins.2020.00138>, 2020 Apr 30;14:138.
- Chen, C.J., Lyu, R.K., Lee, S.T., Wong, Y.C., Wang, L.J., 2001. Intramedullary high signal intensity on T2-weighted MR images in cervical spondylotic myelopathy: prediction of prognosis with type of intensity. *Radiology* 221, 789–794. <https://doi.org/10.1148/radiol.2213010365>.
- Deletis, V., Sala, F., 2008. Intraoperative neurophysiological monitoring of the spinal cord during spinal cord and spine surgery: a review focus on the corticospinal tracts. *Clin. Neurophysiol.* 119, 248–264. <https://doi.org/10.1016/j.clinph.2007.09.135>.
- Devlin, V.J.S.D., 2007. Intraoperative neurophysiologic monitoring during spinal surgery. *J. Am. Acad. Orthop. Surg.* 15, 549–560. <https://doi.org/10.5435/00124635-200709000-00005>.
- Di Martino, A., Papalia, R., Caldaria, A., Torre, G., Denaro, L., Denaro, V., 2019 Apr 2. Should evoked potential monitoring be used in degenerative cervical spine surgery? A systematic review. *J. Orthop. Traumatol.* 20 (1), 19. <https://doi.org/10.1186/s10195-019-0524-4>.
- Faccioli, F., Buffatti, P., Grosslercher, J.C., Bricolo, A., Dalle Ore, G., 1987. [Open-door decompressive cervical laminotomy. Technique and initial experiences]. *Neurochirurgia* 33, 38–43. PMID: 3561645.

- Fehlings, M.G., Tetreault, L.A., Riew, K.D., Middleton, J.W., Wang, J.C., 2017a. A clinical practice guideline for the management of degenerative cervical myelopathy: introduction, rationale, and scope. *Global Spine J.* 7, 21S–27S. <https://doi.org/10.1177/2192568217703088>.
- Fehlings, M.G., Tetreault, L.A., Wilson, J.R., Kwon, B.K., Burns, A.S., Martin, A.R., et al., 2017b. A clinical practice guideline for the management of acute spinal cord injury: introduction, rationale, and scope. *Global Spine J.* 7, 84S–94S. <https://doi.org/10.1177/2192568217703387>.
- Hadley, M.N., Shank, C.D., Rozzelle, C.J.W.B., 2017. Guidelines for the use of electrophysiological monitoring for surgery of the human spinal column and spinal cord. *Neurosurgery* 81, 713–732. <https://doi.org/10.1093/neuros/nyx466>.
- Hilibrand, A., Schwartz, D., Sethuraman, V., Vaccaro, A., Albert, T., 2004 Jun. Comparison of transcranial electric motor and somatosensory evoked potential monitoring during cervical spine surgery. *J. Bone Joint Surg.* 86 (6), 1248–1253. <https://doi.org/10.2106/00004623-200406000-00018>.
- Hirabayashi, K., Watanabe, K., Wakano, K., Suzuki, N., Satomi, K., Ishii, Y., 1983 Oct. Expansive open-door laminoplasty for cervical spinal stenotic myelopathy. *Spine* 8, 693–699. <https://doi.org/10.1097/00007632-198310000-00003>.
- Holly, L.T., Matz, P.G., Anderson, P.A., Groff, M.W., Heary, R.F., Kaiser, M.G., et al., 2009. Clinical prognostic indicators of surgical outcome in cervical spondylotic myelopathy. *J. Neurosurg. Spine* 11, 112–118. <https://doi.org/10.3171/2009.5.SPINE09210>.
- Jones, J.G.A., Cen, S.Y., Lebel, R.M., Hsieh, P.C., Law, M., 2013. Diffusion tensor imaging correlates with the clinical assessment of disease severity in cervical spondylotic myelopathy and predicts outcome following surgery. *Am. J. Neuroradiol.* 34, 471–478. <https://doi.org/10.3174/ajnr.A319>.
- Kobayashi, K., Ando, K.S.R., 2018. Evaluation of waveform amplitude and peak latency in intraoperative spinal cord monitoring. *Spine* 43, 1231–1237. <https://doi.org/10.1097/BRS.0000000000002579>.
- Kopjar, B., Tetreault, L., Kalsi-Ryan, S., Fehlings, M., 2015 Jan 1. Psychometric properties of the modified Japanese Orthopaedic association scale in patients with cervical spondylotic myelopathy. *Spine* 40 (1), E23–E28. <https://doi.org/10.1097/BRS.0000000000000648>.
- Lubelski, D., Alvin, M.D., Nesterenko, S., Sundar, S.J., Thompson, N.R., Benzel, E.C., et al., 2016. Correlation of quality of life and functional outcome measures for cervical spondylotic myelopathy. *J. Neurosurg. Spine* 24, 483–489. <https://doi.org/10.3171/2015.6.SPINE159>.
- Mizuno, J., Nakagawa, H., Inoue, T.H.Y., 2003. Clinicopathological study of 'snake-eye appearance' in compressive myelopathy of the cervical spinal cord. *J. Neurosurg.* 99, 162–168. <https://doi.org/10.3171/spi.2003.99.2.0162>.
- New, P.W., Cripps, R.A., Bonne Lee, B., 2014 Feb. Global maps of non-traumatic spinal cord injury epidemiology: towards a living data repository. *Spinal Cord* 52 (2), 97–109. <https://doi.org/10.1038/sc.2012.165>.
- Nouri, A., Tetreault, L., Singh, A., Karadimas, S.K., Fehlings, M.G., 2015 Jun 15. Degenerative cervical myelopathy: epidemiology, genetics, and pathogenesis. *Spine* 40 (12), E675–E693. <https://doi.org/10.1097/BRS.0000000000000913>.
- Nouri, A., Martin, A.R., Kato, S., Reihani-Kermani, H., Riehm, L.E.F.M., 2017a. The relationship between MRI signal intensity changes, clinical presentation, and surgical outcome in degenerative cervical myelopathy: analysis of a global cohort. *Spine* 42, 1851–1858. <https://doi.org/10.1097/BRS.0000000000002234>.
- Nouri, A., Martin, A.R., Kato, S., Reihani-Kermani, H., Riehm, L.E., Fehlings, M.G., 2017b. The relationship between MRI signal intensity changes, clinical presentation, and surgical outcome in degenerative cervical myelopathy. *Spine* 42, 1851–1858. <https://doi.org/10.1097/BRS.0000000000002234>.
- Park, M.K., Lee, S.J., Kim, S.B., Lee, K.W., Lee, J.H., 2018 Jul 5. The effect of positive changes during intraoperative monitoring on the functional improvement in patients with cervical compressive myelopathy. *Clin. Interv. Aging* 13, 1211–1218. <https://doi.org/10.2147/CIA.S163467>.
- Pratheesh, R., Babu, K.S., Rajshekhar, V., 2014. Improvement in intraoperative transcranial electrical motor-evoked potentials in tethered cord surgery: an analysis of 45 cases. *Acta Neurochir.* 156, 723–731. <https://doi.org/10.1007/s00701-014-1999-7>.
- Quiñones-Hinojosa, A., Lyon, R., Zada, G., Lamborn, K.R., Gupta, N., Parsa, A.T., et al., 2005. Changes in transcranial motor evoked potentials during intramedullary spinal cord tumor resection correlate with postoperative motor function. *Neurosurgery* 56, 982–992. PMID: 15854246.
- Resnick, D.K., Anderson, P.A., Kaiser, M.G., Groff, M.W., Heary, R.F., Holly, L.T., et al., 2009. Electrophysiological monitoring during surgery for cervical degenerative myelopathy and radiculopathy. *J. Neurosurg. Spine* 11, 245–252. <https://doi.org/10.3171/2009.2.SPINE08730>.
- Sala, F., Palandri, G., Basso, E., Lanteri, P., Deletis, V., Faccioli, F., et al., 2006. Motor evoked potential monitoring improves outcome after surgery for intramedullary spinal cord tumors: a historical control study. *Neurosurgery* 58, 1129–1141. <https://doi.org/10.1227/01.NEU.0000215948.97195.58>.
- Sala, F., Bricolo, A., Faccioli, F., Lanteri, P., Gerosa, M., 2007 Nov. Surgery for intramedullary spinal cord tumors: the role of intraoperative (neurophysiological) monitoring. *Eur. Spine J.* 16 (Suppl. 2), S130–S139. <https://doi.org/10.1007/s00586-007-0423-x>. Suppl 2.
- Sala, F., Meneghelli, P., Conti, A., Somma, T., Angileri, F., Cappabianca, P., 2019. Intraoperative neurophysiological monitoring for craniocervical junction surgery. *Acta Neurochir. Suppl.* 125, 369–380. https://doi.org/10.1007/978-3-319-62515-7_53, 2019;125:369-380.
- Sutter, M., Eggspuehler, A., Jeszenszky, D., et al., 2015. The impact and value of uni- and multimodal intraoperative neurophysiological monitoring (IONM) on neurological complications during spine surgery: a prospective study of 2728 patients. *Eur. Spine J.* 24 (Suppl. 2), S236–S251. <https://doi.org/10.1007/s00586-013-2658-z>.
- Takeda, M., Yamaguchi, S., Mitsuhashi, T., Abiko, M., Kurisu, K., 2018. Intraoperative neurophysiological monitoring for degenerative cervical myelopathy. *Neurosurg. Clin.* 29, 159–167. <https://doi.org/10.1016/j.nec.2017.09.012>.
- Tamaki, T., Kubota, S., 2007 Nov. History of the development of intraoperative spinal cord monitoring. *Eur. Spine J.* 16 (Suppl. 2), S140–S146. <https://doi.org/10.1007/s00586-007-0416-9>. Suppl 2.
- Tetreault, L., Nouri, A., Kopjar, B., et al., 2015 Nov. The minimum clinically important difference of the modified Japanese orthopaedic association scale in patients with degenerative cervical myelopathy. *Spine* 40 (21), 1653–1659. <https://doi.org/10.1097/BRS.0000000000001127>.
- Tetreault, L.A., Karpova, A., Fehlings, M.G., 2015b. Predictors of outcome in patients with degenerative cervical spondylotic myelopathy undergoing surgical treatment: results of a systematic review. *Eur. Spine J.* 24, 236–251. <https://doi.org/10.1007/s00586-013-2658-z>.
- Tetreault, L., Ibrahim, A., Côté, P., Singh, A., Fehlings, M.G., 2016 Jan. A systematic review of clinical and surgical predictors of complications following surgery for degenerative cervical myelopathy. *J. Neurosurg. Spine* 24, 77–99. <https://doi.org/10.14245/ns.1938220.110>.
- Uchida, K., Nakajima, H.T.N., 2014. Prognostic value of changes in spinal cord signal intensity on magnetic resonance imaging in patients with cervical compressive myelopathy. *Spine J.* 14, 1601–1610. <https://doi.org/10.1016/j.spinee.2013.09.038>.
- Vidal, P.M., Karadimas, S.K., Uldreaj, A., Laliberte, A.M., Tetreault, L., Forner, S., et al., 2017 Jun. Delayed decompression exacerbates ischemia-reperfusion injury in cervical compressive myelopathy. *JCI insight* 2 (11), e92512. <https://doi.org/10.1172/jci.insight.92512>.
- Wang, S., Tian, Y., Wang, C., Lu, X., Zhuang, Q., Peng, H., et al., 2016. Prognostic value of intraoperative MEP signal improvement during surgical treatment of cervical compressive myelopathy. *Eur. Spine J.* 25, 1875–1880. <https://doi.org/10.1007/s00586-016-4477-5>.
- Witiw, C.D., Mathieu, F., Nouri, A., Fehlings, M.G., 2018. Clinico-radiographic discordance: an evidence-based commentary on the management of degenerative cervical spinal cord compression in the absence of symptoms or with only mild symptoms of myelopathy. *Global Spine J.* 8, 527–534. <https://doi.org/10.1177/2192568217745519>.
- Xu, X., Zhang, B., Sun, K., Sun, J., Wang, Y., Ji, C., et al., 2020 Jun. Reliability and validity of multi-shot DWI in diagnosis of cervical spondylotic myelopathy: a study based on 3-T MRI. *Eur. Spine J.* 29, 1219–1226. <https://doi.org/10.1007/s00586-020-06381-z>.
- You, J.Y., Lee, J.W., Lee, E., Lee, G.Y., Yeom, J.S., Kang, H.S., 2015. MR classification system based on axial images for cervical compressive myelopathy. *Radiology* 276, 553–561. <https://doi.org/10.1148/radiol.2015142384>.
- Zileli, M., Borkar, S.A., Sinha, S., Reinas, R., Alves, Ó.L., Kim, S.H., et al., 2019. Cervical spondylotic myelopathy: natural course and the value of diagnostic techniques-wfns spine committee recommendations. *Neurospine* 16, 386–402. <https://doi.org/10.14245/ns.1938240.120>.