

# Utility of F-18 FDG-PET in Detecting Primary Aldosteronism in Patients with Bilateral Adrenal Incidentalomas

Myung Kwan Ko,<sup>1</sup> Chan Sung Park,<sup>1</sup>  
Sung Soo Byun,<sup>1</sup> Jung Min Hong,<sup>1</sup>  
Mu Yeol Lee,<sup>1</sup> Kyung Hoon Kim,<sup>1</sup>  
Yang Won Na,<sup>2</sup> Hye Jeong Choi,<sup>3</sup>  
Il Sung Nam-Goong,<sup>1</sup> Young Il Kim,<sup>1</sup>  
and Eun Sook Kim<sup>1</sup>

Departments of <sup>1</sup>Internal Medicine, <sup>2</sup>General Surgery, <sup>3</sup>Pathology, Ulsan University Hospital, University of Ulsan College of Medicine, Ulsan, Korea

Received: 6 July 2012  
Accepted: 30 January 2013

Address for Correspondence:

Eun Sook Kim, MD

Department of Internal Medicine, Ulsan University Hospital,  
877 Bangeojinsunhwan-doro, Dong-gu, Ulsan 682-714, Korea  
Tel: +82.52-250-8837, Fax: +82.52-250-7048  
E-mail: es10@unitel.co.kr

In patients with primary aldosteronism who have bilateral adrenal incidentalomas, it is important to identify which adrenal gland is secreting excess aldosterone. Traditionally, adrenal vein sampling (AVS) has been performed for lateralization despite its invasiveness. Here we report a case of bilateral adrenal incidentaloma in which 18-Fluorodeoxyglucose (FDG)-positron emission tomography (PET) was used to identify the functional adrenal mass. A 53-yr-old man was referred to our clinic due to bilateral adrenal incidentalomas (right: 1 cm, left: 2.5 cm) on computed tomography (CT). Given his history of colon cancer, FDG-PET/CT scanning was used to rule out metastasis. Although there was focal hot uptake lesion in the right adrenal gland, the patient was suspected primary aldosteronism clinically more than metastasis because of the patient's underlying hypertension with hypokalemia. It was consistent with the results of AVS. Based on these findings, we propose that FDG-PET/CT can be used instead of AVS to identify the source of primary aldosteronism between two bilateral adrenal incidentalomas.

**Key Words:** Bilateral Adrenal Incidentaloma; FDG-PET/CT; Primary Aldosteronism

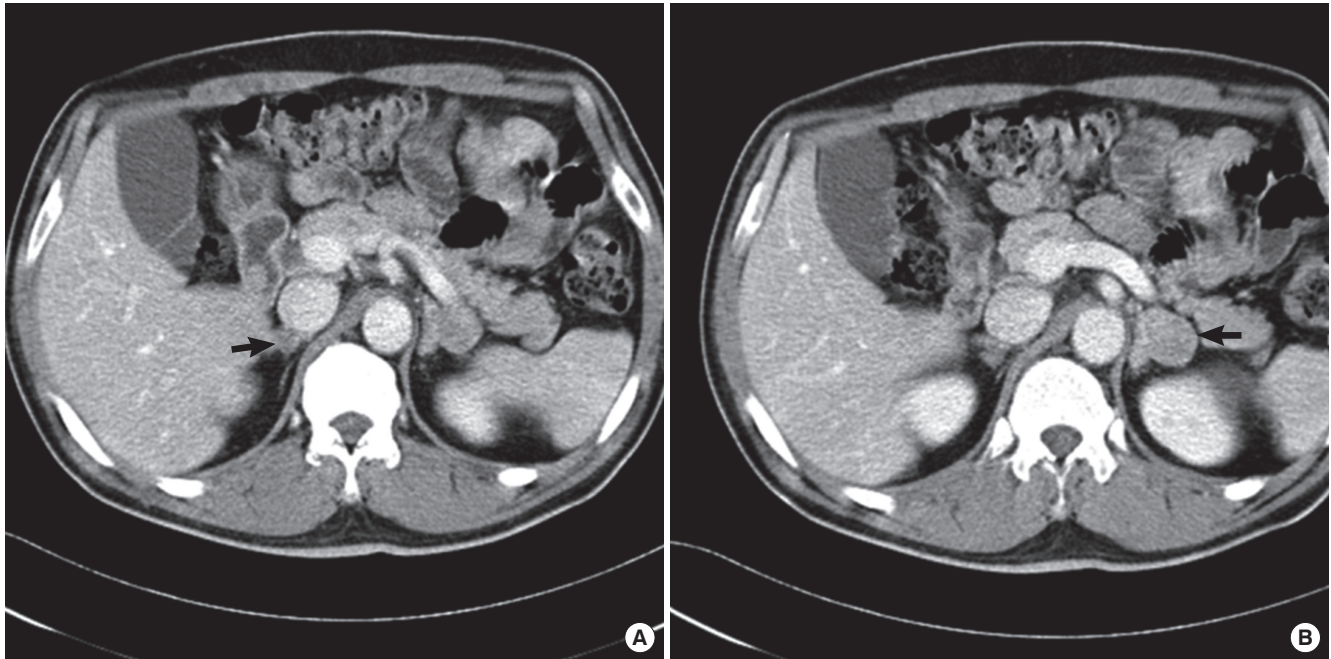
## INTRODUCTION

Since the early 1980s, the number of incidentally discovered adrenal masses has increased as a result of the widespread use of imaging studies, such as computed tomography (CT) and magnetic resonance imaging (MRI) (1). The prevalence of adrenal incidentalomas is known to be as high as 3% in middle-aged people and 10% in the elderly (2). The prevalence of primary aldosteronism (PA) increases with the severity of hypertension and varies depending on the population under investigation. In a recent meta-analysis, Jansen et al. (3) determined a mean PA prevalence of 4.3% in hypertensive primary care patients and 9.0% in referred hypertensive patients. Currently, only a minority of PA requires surgery, in part because it is difficult to prove that the adenoma is the sole cause of PA (4). The assessment of eligibility for surgery requires differentiation of unilateral Conn's adenoma from cases of bilateral adrenal hyperplasia and non-functioning adrenal nodules (incidentalomas) (5). Adrenal vein sampling (AVS) is the most accurate standard test to distinguish these entities; however, it is commonly ineffective because the adenoma only intermittently secretes aldosterone or because of technical difficulties in cannulating the right adrenal vein (6). The purpose of this report is to describe the findings of non-invasive imaging methods that can be used to lateralize aldoste-

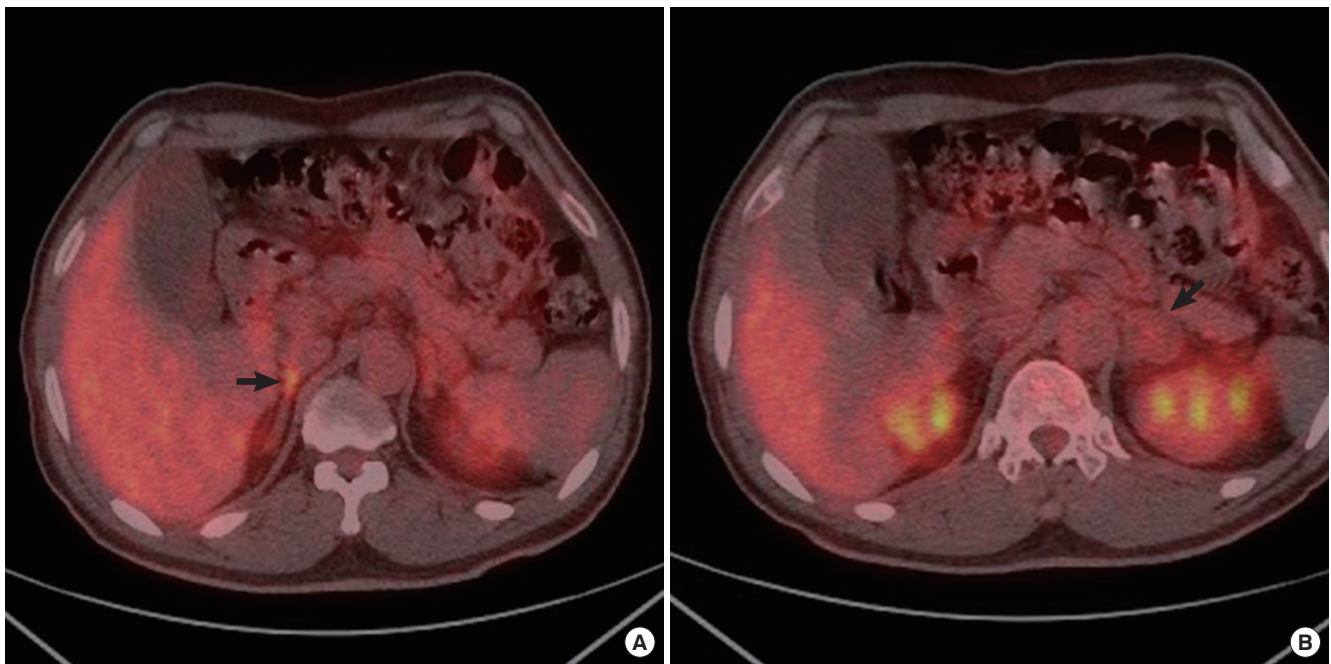
rone secretion to one of the bilateral incidentally-detected adrenal masses. Here we report a case where unilateral PA was detected on 18F-fluorodeoxyglucose (FDG)-positron emission tomography (PET/CT) and confirmed by adrenal venous sampling of both adrenal incidentalomas.

## CASE DESCRIPTION

A 53-yr-old man was referred to our clinic on September 5, 2011 after bilateral adrenal masses (right: 1 cm, left: 2.5 cm) were discovered on an abdominal CT (Fig. 1). Two years prior, the patient underwent low anterior resection for sigmoid colon cancer and had received adjuvant chemotherapy. The patient had been prescribed antihypertensive medications (almodipine 10 mg, olmesartan 20 mg) for 12 yr, but his blood pressure could not be controlled well and was found to be 160/90 mmHg on presentation. He was generally well-appearing, but complained of a persistent mild headache. He demonstrated an increased deep tendon reflex in both knees and had no weight gain or edema. Blood analysis revealed persistent hypokalemia (serum potassium of 2.6 mM), but his medications did not include a potassium-wasting diuretic (e.g., thiazide, loop). Laboratory tests showed plasma renin activity (PRA) of 0.12 ng/mL/h and plasma aldosterone concentration (PAC) of 10.4 ng/dL with a PAC/PRA ratio



**Fig. 1.** Abdominal CT of the patient with both adrenal incidentaloma. Both adrenal incidentalomas were noted on abdominal CT. (A) The one was noted 1-cm sized mass at right side (arrow). (B) Another was noted 2.5-cm sized mass at left side (arrow).



**Fig. 2.** FDG-PET/CT of the patient with both adrenal incidentaloma. (A) FDG-PET/CT of the torso showing a focal hypermetabolic lesion (maxSUV = 2.7) in the right adrenal mass (arrow). (B) There was no hypermetabolic foci in the left adrenal mass (arrow).

of 86.6. And we confirmed diagnosis of primary aldosteronism with captopril challenge test (post-captopril aldosterone level was 18.5 ng/dL).

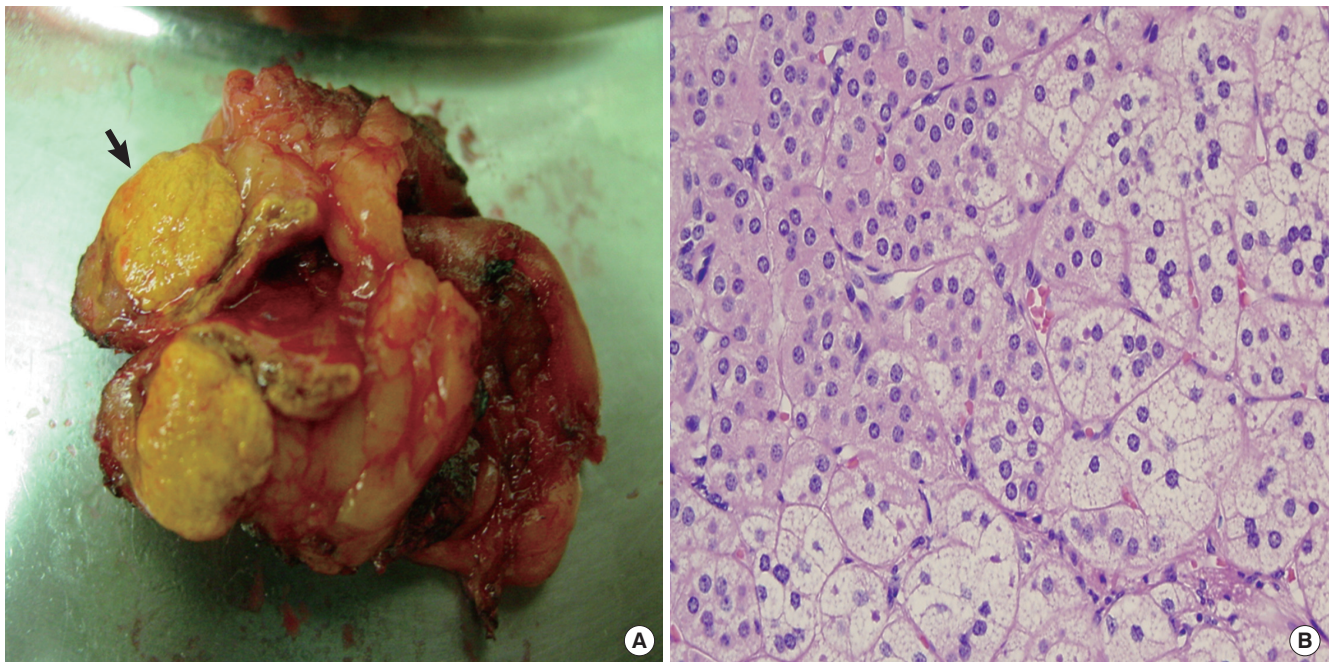
Given his history of colon cancer, we had to rule out metastatic disease before continuing to adrenal venous sampling. FDG-PET/CT of his torso incidentally revealed a focal hyper-

metabolic lesion in the right adrenal gland (Fig. 2). Generally, the larger tumor has more focal hypermetabolic uptake lesion. But in this case, although right adrenal incidentaloma was smaller than left that, only right adrenal gland had focal hypermetabolic uptake. There was no hypermetabolic uptake except adrenal gland in FDG-PET/CT, the patient was suspected primary

**Table 1.** Bilateral selective adrenal vein catheterization and sampling test

| Vein               | Aldosterone (ng/dL) |           | Cortisol ( $\mu$ g/dL) |           | A/C ratio ((pg/mL)/[ $\mu$ g/dL]) |         |
|--------------------|---------------------|-----------|------------------------|-----------|-----------------------------------|---------|
|                    | Pre-ACTH            | Post-ACTH | Pre-ACTH               | Post-ACTH | 0 min                             | 30 min  |
| Right adrenal vein | 186.9               | 2,108.5   | 15.5                   | > 63.4    | 120.5                             | < 332.5 |
| Left adrenal vein  | 11.2                | 145.1     | 14.0                   | > 63.4    | 8                                 | < 22.8  |
| IVC (Post-ACTH)    | 11.3                | 21.9      | 12.7                   | 21.1      | 8.8                               | 10.3    |

Adrenal venous sampling was performed at both adrenal glands and revealed an aldosterone/cortisol ratio 15 times higher on the right side than on the left. The result of adrenal venous sampling showed right lateralization. A/C ratio, aldosterone/cortisol ratio; ACTH, adrenocorticotropic hormone; min., minute; IVC, inferior vena cava.



**Fig. 3.** The pathologic findings of right adrenal gland after laparoscopic adrenalectomy. (A) On gross examination, a well-demarcated, golden yellow nodule is noted in the right adrenal gland (black arrow). (B) On microscopic examination, tumor cells of right adrenal gland showed lipid-laden clear cells.

aldosteronism clinically. So we thought that right adrenal incidentaloma was not metastatic lesion but benign functioning tumor. Adrenal venous sampling was performed at both adrenal glands, and the aldosterone/cortisol ratio was found to be 15 times higher on the right side than on the left (Table 1). This finding was consistent with the results of FDG-PET/CT.

Surgical resection of the right adrenal gland was performed. Pathological examination showed a well-demarcated, golden yellow nodule grossly (Fig. 3A) with tumor cells that resembled cortical cells and showed lipid-laden clear cells microscopically (Fig. 3B). Three months after the operation, the patient's blood pressure, serum potassium level, and plasma renin-aldosterone activity were normalized.

## DISCUSSION

The widespread use of CT and MRI has led to an increase in the incidental discovery of adrenal masses, requiring physicians to further evaluate whether the lesions are benign or malignant and lateralize symptoms to one lesion or the other. Many review

articles reported that recent advances in CT, MRI, and PET/CT assist in the distinction between benign adenomas and malignant lesions of the adrenal glands (7). Only a few articles described the use of imaging techniques in distinguishing functional adenomas from nonfunctioning lesions of the adrenal glands (9).

F-18 FDG is widely used in clinical PET imaging. Until now, FDG-PET/CT has been used mainly for distinguishing between benign and malignant adrenal masses (8). The combination of FDG-PET/CT and CT in the evaluation of adrenal incidentalomas in patients without a history of cancer has been reported to have a 93% negative predictive value (NPV) for malignancy and a 97% positive predictive value (PPV) for detecting surgical lesions (9). Surgical lesions are defined as a malignancy or a benign secreting tumor. A high FDG uptake (maximum standardized uptake value  $\geq 10$ ) was highly predictive of malignancy (9). PET/CT performed for the characterization of adrenal masses in patients with cancer yielded a sensitivity of 100% for the detection of malignancy, in addition to a specificity of 99%, a PPV of 93%, a NPV of 100%, and an accuracy of 99% (10). Converse-

ly, for the detection of benign tumor, the sensitivity, specificity, PPV, NPV, and accuracy were 99%, 100%, 100%, 93%, and 99%, respectively (10).

As mentioned above, FDG-PET/CT is a useful tool for differentiating malignancy, benign secreting tumors, and non-functioning benign tumors in adrenal masses. There are, however, some limitations of FDG-PET/CT in distinguishing adrenal masses. First, it is nonspecific for neoplasms, with uptake by macrophages and other immune cells. Second, neoplasms with low glucose metabolism, such as well-differentiated NET (Neuroendocrine tumor), show poor FDG uptake reflecting the degree of tumor differentiation and biological behavior (11). Third, FDG-PET/CT uptake does not show a consistent pattern for endocrine tumors, which is probably due to the variability inherent in FDG uptake (8). Although FDG-PET/CT has some limitations, it is helpful in lateralizing aldosterone secretion in patients with bilateral adrenal incidentalomas. Furthermore, some of its limitations can be overcome using laboratory tests.

Recently, some reports showed that C-11metomidate (MTO)-PET/CT is a sensitive and specific noninvasive alternative to AVS for lateralizing aldosterone secretion by Conn's adenoma (12). C-11 metomidate, a potent inhibitor of 11 $\beta$ -hydroxylase and aldosterone synthase, has been advanced as a positron emission tomography (PET) radiotracer (12).

There was a case report of an adrenocortical adenoma with an increased FDG uptake in patient with subclinical Cushing's syndrome (13). That case suggested that increased FDG uptake may be relevant to hormonal function of an adrenocortical adenoma by glucose metabolism, even in a completely asymptomatic normocortisolism patient. About increased FDG uptake, our case may be related with similar mechanism.

In our case, F-18 FDG-PET/CT was helpful in characterizing adrenal masses and was consistent with the results of AVS, the conventional diagnostic study. Although there are some limitations of F-18 FDG PET/CT in the routine evaluation of adrenal incidentalomas, we propose that F-18 FDG PET/CT can play an additional role for identifying functioning adrenal tumor as an alternative to adrenal venous sampling. Especially in the absence of pre-existing malignancy.

## REFERENCES

1. Barzon L, Boscaro M. *Diagnosis and management of adrenal incidentalomas. J Urol* 2000; 163: 398-407.
2. Kloos RT, Gross MD, Francis IR, Korobkin M, Shapiro B. *Incidentally discovered adrenal masses. Endocr Rev* 1995; 16: 460-84.
3. Jansen PM, Boomsma F, van den Meiracker AH; Dutch ARRAT Investigators. *Aldosterone-to-renin ratio as a screening test for primary aldosteronism: the Dutch ARRAT Study. Neth J Med* 2008; 66: 220-8.
4. Rossi GP; Medscape. *A comprehensive review of the clinical aspects of primary aldosteronism. Nat Rev Endocrinol* 2011; 7: 485-95.
5. Young WF Jr. *Clinical practice: the incidentally discovered adrenal mass. N Engl J Med* 2007; 356: 601-10.
6. Toniato A, Bernante P, Rossi GP, Pelizzo MR. *The role of adrenal venous sampling in the surgical management of primary aldosteronism. World J Surg* 2006; 30: 624-7.
7. Al-Hawary MM, Francis IR, Korobkin M. *Non-invasive evaluation of the incidentally detected indeterminate adrenal mass. Best Pract Res Clin Endocrinol Metab* 2005; 19: 277-92.
8. Han SJ, Kim TS, Jeon SW, Jeong SJ, Yun M, Rhee Y, Kang ES, Cha BS, Lee EJ, Lee HC, et al. *Analysis of adrenal masses by 18F-FDG positron emission tomography scanning. Int J Clin Pract* 2007; 61: 802-9.
9. Ansquer C, Scigliano S, Mirallié E, Taïeb D, Brunaud L, Sebag F, Leux C, Drui D, Dupas B, Renaudin K, et al. *18F-FDG PET/CT in the characterization and surgical decision concerning adrenal masses: a prospective multicentre evaluation. Eur J Nucl Med Mol Imaging* 2010; 37: 1669-78.
10. Boland GW, Blake MA, Holalkere NS, Hahn PF. *PET/CT for the characterization of adrenal masses in patients with cancer: qualitative versus quantitative accuracy in 150 consecutive patients. AJR Am J Roentgenol* 2009; 192: 956-62.
11. Wong KK, Arabi M, Zerizer I, Al-Nahhas A, Rubello D, Gross MD. *Role of positron emission tomography/computed tomography in adrenal and neuroendocrine tumors: fluorodeoxyglucose and nonfluorodeoxyglucose tracers. Nucl Med Commun* 2011; 32: 764-81.
12. Burton TJ, Mackenzie IS, Balan K, Koo B, Bird N, Soloviev DV, Azizan EA, Aigbirhio F, Gurnell M, Brown MJ. *Evaluation of the sensitivity and specificity of (11)C-metomidate positron emission tomography (PET)-CT for lateralizing aldosterone secretion by Conn's adenomas. J Clin Endocrinol Metab* 2012; 97: 100-9.
13. Shimizu A, Oriuchi N, Tsushima Y, Higuchi T, Aoki J, Endo K. *High [18F] 2-fluoro-2-deoxy-D-glucose (FDG) uptake of adrenocortical adenoma showing subclinical Cushing's syndrome. Ann Nucl Med* 2003; 17: 403-6.