



Paroxysmal kinesigenic dyskinesia in a patient with a *PRRT2* mutation and centrotemporal spike discharges on electroencephalogram: case report of a 10-year-old girl

Sun Young Seo, MD, Su Jeong You, MD, PhD

Department of Pediatrics, Inje University Sanggye Paik Hospital, Inje University College of Medicine, Seoul, Korea

Coexistence of paroxysmal kinesigenic dyskinesia (PKD) with benign infantile convulsion (BIC) and centrotemporal spikes (CTS) is very rare. A 10-year-old girl presented with a 3-year history of frequent attacks of staggering while laughing and of suddenly collapsing while walking. Interictal electroencephalogram (EEG) revealed bilateral CTS, but no changes in EEG were observed during movement. The patient's medical history showed afebrile seizures 6 months after birth, while the family history showed that the patient's mother and relatives on the mother's side had similar dyskinesia. Genetic testing demonstrated that the patient had a heterozygous mutation, c.649_650insC, in the *PRRT2* gene. To our knowledge, this constitutes only the second report of a patient with PKD, BIC, CTS, and a *PRRT2* mutation.

Key words: Paroxysmal kinesigenic dyskinesia, Seizure, Proline-rich transmembrane protein-2, Epilepsy

Corresponding author: Su Jeong You, MD, PhD
Department of Pediatrics, Inje University Sanggye Paik Hospital, Inje University College of Medicine, 1342 Dongil-ro, Nowon-gu, Seoul 01757, Korea
Tel: + 82-2-950-1080
Fax: +82-2-951-1246
E-mail: sjyou@paik.ac.kr

Received: 29 September, 2015

Revised: 25 November, 2015

Accepted: 16 December, 2015

Introduction

Paroxysmal kinesigenic dyskinesia (PKD) is an episodic movement disorder characterized by sudden attacks of involuntary movements, such as dystonia, choreoathetosis, and ballism. Most patients with PKD are neurologically normal between the attacks and remain conscious throughout the attacks. The attacks of abnormal movements are triggered by sudden voluntary movements and last less than one minute^{1,2}.

PKD has been associated with mutations in the gene encoding proline-rich transmembrane protein-2 (*PRRT2*), located on chromosome 16 (16p12.1-q12.1), although the precise role of *PRRT2* in PKD remains unclear³. PKD can occur independently of or concurrently with benign infantile convulsions (BIC), a condition characterized by nonfebrile convulsions with onset between 3 and 12 months of age and favorable outcomes, including normal psychomotor development⁴. The diagnosis of PKD is based on clinical features and the correct diagnosis has implications for treatment and prognosis. However, PKD is often misdiagnosed clinically as epilepsy or psychogenic illness. Recent genetic discoveries will increase the likelihood of a correct diagnosis and contribute to elucidating the pathophysiology of this disease.

Centrotemporal spikes (CTS) are diagnostic marker of benign childhood epilepsy with CTS (BECTS) and it is only a diagnostic marker in patients showing characteristic clinical seizure. CTS are not specific to BECTS as they occur in 2%–3% of normal school-aged

Copyright © 2016 by The Korean Pediatric Society

This is an open-access article distributed under the terms of the Creative Commons Attribution Non-Commercial License (<http://creativecommons.org/licenses/by-nc/4.0/>) which permits unrestricted non-commercial use, distribution, and reproduction in any medium, provided the original work is properly cited.

children, of whom <10% develop seizures⁵. Moreover, CTS are also associated with other diseases⁶.

This study describes a 10-year-old girl presenting with PKD, BIC and *PRRT2* mutation, as well as CTS discharges on electroencephalogram (EEG).

Case report

A 10-year-old girl presented with a 3-year history of short duration dyskinesia after sudden movements. She was born via normal vaginal delivery at 38 weeks and 6 days of gestation, with a birth weight of 3,400 g. Her perinatal history was unremarkable, and she developed normally. At age 6 months, she developed a sudden onset of staring, which progressed to generalized hypotonic seizures that lasted for 3 minutes. Her growth and developmental milestones were normal. EEG, neurologic examination and brain magnetic resonance imaging (MRI) were normal. At age 10 months, after experiencing several afebrile seizures, she was

started on treatment with an antiepileptic drug (AED) for about 2 years. Her seizures were well controlled on the AED.

There was no family history of epilepsy or febrile seizures. However, while of school age, her mother and her mother's sister and brother had similar dyskinesia after sudden movements (Fig. 1). Their development was normal with no neurologic problems and no febrile seizures or epilepsy since birth. They no longer have these symptoms.

At 7 years of age, she presented with abnormal paroxysmal movements occurring 5–6 times a day. She staggered while laughing and suddenly collapsed in the street while walking. These symptoms continued to occur. The results of neurologic examinations and brain MRI were normal. EEG revealed bilateral CTS, and there were no changes in EEG during movements (Fig. 2).

After obtaining informed consent from her parents, a blood peripheral sample was obtained from this patient, its DNA was extracted and her *PRRT2* gene was sequenced. A heterozygous frameshift mutation, .649dup, was detected, resulting in p.Arg217Profs*8 (Fig. 3).

Two to 3 days after oxcarbazepine therapy (3 mg/kg/day), her paroxysmal movements were well controlled. She continued oxcarbazepine thereafter and continued to develop normally, with no further seizure and no attacks of PKD.

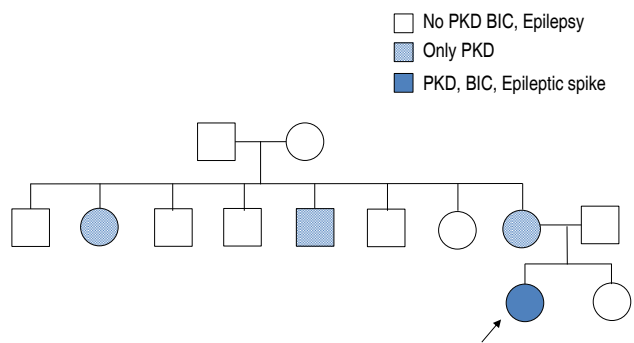


Fig. 1. Family pedigree of the proband. PKD, paroxysmal kinesigenic dyskinesia; BIC, benign infantile convulsion.

Discussion

PKD is a paroxysmal movement disorder characterized by recurrent, brief attacks of abnormal involuntary movements induced by sudden voluntary movements. The episodes usually present with dystonia, chorea, athetosis, ballism, or a combination of these symptoms. The attacks usually last from a few seconds to a few minutes. During these attacks, there is absolutely

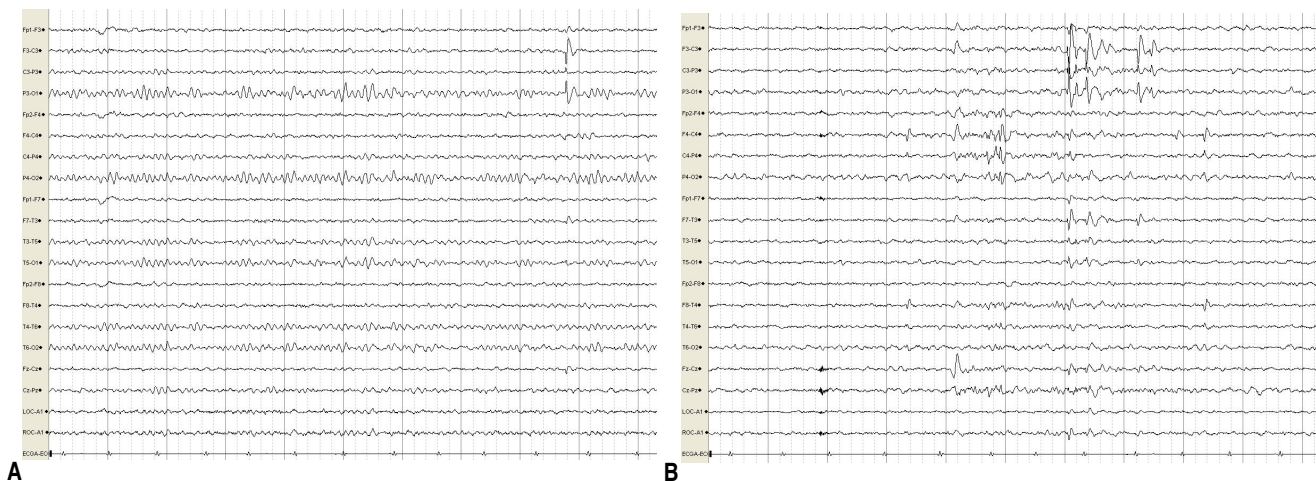


Fig. 2. Interictal electroencephalogram recordings of the patient, showing frequent spike discharges from the left centrotemporoparietal and right centrotemporal areas while awake (A) and asleep (B). Discharges were more aggravated while asleep than when awake.

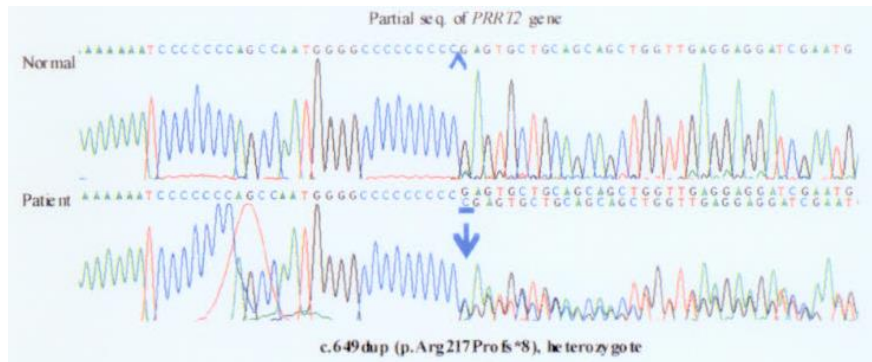


Fig. 3. Genetic analysis showing that the patient had a heterozygous mutation, c.649_650insC, in the proline-rich transmembrane protein-2 (*PRRT2*) gene.

no loss or alteration of consciousness. The prognosis of PKD is favorable and patients usually show excellent response to treatment. PKD can be classified as primary or secondary according to its etiology. Most cases of secondary PKD are caused by multiple sclerosis, head injury, metabolic derangements, or cerebral perfusion insufficiency. Primary PKD can be classified as idiopathic or familial. Familial PKD is more common, with the condition usually inherited in an autosomal dominant manner⁷.

In 2011–2012, mutations in the *PRRT2* gene were found to be responsible for PKD and infantile convulsion with choreoathetosis syndrome⁷. The molecular function of the *PRRT2* protein has not been fully defined. *PRRT2* is likely expressed in the brain and spinal cord during the embryonic and postnatal stages of development^{3,5,7}. *PRRT2* is thought to interact with synaptosomal-associated protein 25 (SNAP25), a member of the family of soluble N-ethylmaleimide-sensitive factor attachment protein receptor proteins, which fuse synaptic vesicles to the presynaptic plasma membrane and release neurotransmitters. Defects in synaptic functions are predicted to be associated with brain disorders. Moreover, SNAP25 is thought to modulate the kinetics of voltage-gated Ca²⁺ channels. In patients with *PRRT2* mutations, the interaction between *PRRT2* and SNAP25 might be affected, resulting in an alteration of Ca_v2.1 properties. These data thus suggest that PKD, benign familial infantile seizures, infantile convulsions with choreoathetosis and hemiplegic migraine could result from dysfunction of a protein involved in synaptic regulation, with ensuing neuronal hyperexcitability⁸.

Previous reports have indicated that mutations in the *PRRT2* gene may cause PKD, infantile convulsions, familial hemiplegic migraine⁹, episodic ataxia¹⁰ and febrile seizures¹¹. Also, recent study showed that a link between BECTS, BIS, PKD or exercise-induced dystonia and *PRRT2* mutations detected by array comparative genomic hybridization and quantitative polymerase chain reaction^{12,13}. A subset of genomic alterations detected in BECTS contains candidate or known epilepsy genes including *PRRT2*, some of which are likely to influence the emergence, the

presentation, or the comorbidity of BECTS¹².

BECTS is considered the most common type of childhood epileptic syndrome, present in 10%–20% of pediatric patients with epilepsy. It is classified among the idiopathic localization-related epilepsies. Characteristic EEGs show high voltage spikes or spike and waves in the centrottemporal region, which may shift from side to side on a normal background. Neuro-imaging is normal. CTS are diagnostic markers of BECTS only in a suggestive clinical presentation. CTS are not specific to BECTS, however, as they occur in 2%–3% of normal school-aged children, of whom <10% develop seizures. They are common among relatives of children with BECTS and may also occur in various organic brain diseases, with or without seizures, such as cerebral tumors, Rett syndrome, fragile X syndrome and focal cortical dysplasia. They may incidentally be found in nonepileptic children with various symptoms, such as headache, speech and behavioral and learning difficulties⁶. *PRRT2* heterozygous mutations cause a wide variety of variably associated paroxysmal cerebral disorders: BIC, PKD, and/or hemiplegic migraine. So we can infer that the mutation in *PRRT2* contributed to the development of BIC, paroxysmal disease, and the diseases showing CTS on EEG or BECTS.

Further functional study of *PRRT2* mutations should assist in elucidating the pathophysiology of various paroxysmal disorders including epilepsy, movement disorders, and disease associated with CTS on EEG, as well as other neurologic disorders.

PKD is often misdiagnosed clinically as psychogenic illness or epilepsy, especially in patients with CTS on EEG, which may cause great distress to patients. A correct diagnosis and subsequent treatment with low doses of anticonvulsants can eliminate the clinical manifestations of PKD and improve patient quality of life in patients.

Conflict of interest

No potential conflict of interest relevant to this article was

reported.

References

1. Mehta SH, Morgan JC, Sethi KD. Paroxysmal dyskinesias. *Curr Treat Options Neurol* 2009;11:170-8.
2. Bhatia KP. Paroxysmal dyskinesias. *Mov Disord* 2011;26:1157-65.
3. Chen WJ, Lin Y, Xiong ZQ, Wei W, Ni W, Tan GH, et al. Exome sequencing identifies truncating mutations in *PRRT2* that cause paroxysmal kinesigenic dyskinesia. *Nat Genet* 2011;43:1252-5.
4. Szepietowski P, Rochette J, Berquin P, Piussan C, Lathrop GM, Monaco AP. Familial infantile convulsions and paroxysmal choreoathetosis: a new neurological syndrome linked to the pericentromeric region of human chromosome 16. *Am J Hum Genet* 1997;61:889-98.
5. Heron SE, Grinton BE, Kivity S, Afawi Z, Zuberi SM, Hughes JN, et al. *PRRT2* mutations cause benign familial infantile epilepsy and infantile convulsions with choreoathetosis syndrome. *Am J Hum Genet* 2012;90:152-60.
6. Panayiotopoulos CP, Michael M, Sanders S, Valeta T, Koutroumanidis M. Benign childhood focal epilepsies: assessment of established and newly recognized syndromes. *Brain* 2008;131(Pt 9):2264-86.
7. Wang JL, Cao L, Li XH, Hu ZM, Li JD, Zhang JG, et al. Identification of *PRRT2* as the causative gene of paroxysmal kinesigenic dyskinesias. *Brain* 2011;134(Pt 12):3493-501.
8. Meneret A, Gaudebout C, Riant F, Vidailhet M, Depienne C, Roze E. *PRRT2* mutations and paroxysmal disorders. *Eur J Neurol* 2013;20:872-8.
9. Marini C, Conti V, Mei D, Battaglia D, Lettori D, Losito E, et al. *PRRT2* mutations in familial infantile seizures, paroxysmal dyskinesia, and hemiplegic migraine. *Neurology* 2012;79:2109-14.
10. Gardiner AR, Bhatia KP, Stamelou M, Dale RC, Kurian MA, Schneider SA, et al. *PRRT2* gene mutations: from paroxysmal dyskinesia to episodic ataxia and hemiplegic migraine. *Neurology* 2012;79:2115-21.
11. Scheffer IE, Grinton BE, Heron SE, Kivity S, Afawi Z, Iona X, et al. *PRRT2* phenotypic spectrum includes sporadic and fever-related infantile seizures. *Neurology* 2012;79:2104-8.
12. Dimassi S, Labalme A, Lesca G, Rudolf G, Bruneau N, Hirsch E, et al. A subset of genomic alterations detected in rolandic epilepsies contains candidate or known epilepsy genes including *GRIN2A* and *PRRT2*. *Epilepsia* 2014;55:370-8.
13. Guerrini R, Bonanni P, Nardocci N, Parmeggiani L, Piccirilli M, De Fusco M, et al. Autosomal recessive rolandic epilepsy with paroxysmal exercise-induced dystonia and writer's cramp: delineation of the syndrome and gene mapping to chromosome 16p12-11.2. *Ann Neurol* 1999;45:344-52.