

Efficiency of Fat Suppression in T1-Weighted Inner Ear Magnetic Resonance Imaging: Multipoint Dixon Method *Versus* Hybrid Techniques

Pinar Cakmak^{1,*}, Duygu Herek^{1,*}, Ahmet Baki Yagci¹, Ergin Sagtas¹, Furkan Ufuk¹ and Vefa Cakmak¹

¹Department of Radiology, Pamukkale University Medical Center, Denizli, Turkey

Abstract: Background : Temporal bone is a region where fat suppression is difficult due to the inhomogeneity of various structures with different molecular properties.

Introduction:: We aimed to determine the most effective fat suppression sequence in order to increase the visibility of the inner ear region.

Materials and Methods: The hybrid techniques and T1-Weighted mDIXON images of 40 patients with Magnetic Resonance (MR) imaging of the inner ear were prospectively compared by two experienced radiologists in terms of fat suppression efficacy. In all fat-suppressed sequences, the Signal to Noise Ratio (SNR), the spinal cord signal intensity / mean fat signal intensity ratio and spinal cord signal to noise ratio were calculated. The suppression efficacy of MR techniques for fat areas in the inner ear was visually graded.

Results: Qualitative assessment of image quality due to fat suppression in the inner ear was made; the Dixon technique performed significantly better than SPAIR and SPIR techniques ($p < 0.0001$). The mean signal intensity of the inner ear fat and SNR for the Dixon technique were significantly lower than that for SPIR and SPAIR techniques ($p < 0.0001$). Inter-observer agreement regarding the assessment of the inner ear fat, mean signal intensity values and mean SNR values for fat suppression techniques was significant.

Conclusion: The Dixon technique exhibited higher image quality and fat suppression efficiency than the hybrid techniques in the MR imaging of the inner ear.

Keywords: Magnetic Resonance Imaging, inner ear, vertigo, signal to noise ratio, spinal cord, CHES.

1. INTRODUCTION

Fat suppression techniques are used to evaluate the lipid content of the tissues and lesion contrast or determine lesion boundaries [1, 2]. Fat suppression is difficult in the temporal bone region because of the inhomogeneity of the various nearby structures and their different molecular characteristics (fat, cerebrospinal fluid, air, membranous labyrinth).

The three types of fat suppression techniques are chemical shift based techniques (chemical shift selective [CHES], water excitation, DIXON), inversion-based techniques (short-TI inversion recovery [STIR]), and hybrid techniques (spectral attenuated inversion recovery [SPAIR], spectral presaturation with inversion recovery [SPIR]). SPIR is a hybrid fat suppression technique that is sensitive to both B0 and B1 inhomogeneities, and it combines the features of

both CHES and STIR. The only difference between SPIR and STIR is that a fat-selective inversion RF pulse is used in SPIR. The other hybrid fat-suppression technique is SPAIR. SPAIR uses adiabatic inversion pulses, and the difference between SPAIR and STIR is that SPAIR is insensitive to B1 inhomogeneities because of the use of adiabatic pulses, although it is sensitive to B0 inhomogeneities [3]. Dixon is a chemical shift-based fat-suppression technique defined by Dixon in 1984. The Dixon technique is based on the resonance difference between fat and water protons [4]. In-phase, out-phase, fat-only and water-only images are obtained, and the water-only images are used for fat suppression. The Dixon method is less sensitive to B0 and B1 heterogeneities than other fat suppression methods. Previous studies available in the English literature have compared fat-suppression techniques in musculoskeletal, spine, chest, head and neck imaging [5-9].

In this study, we aimed to determine the most effective fat-suppression technique in order to increase the visibility of the inner ear region.

*Address correspondence to these authors at the Department of Radiology, Pamukkale University Medical Center, Denizli, Turkey; E-mails: pinarcakmak20@gmail.com, dtherek@yahoo.com

ARTICLE HISTORY

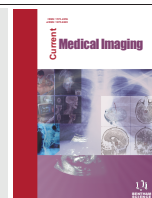
Received: June 05, 2020
Revised: September 30, 2020
Accepted: November 09, 2020

DOI:
[10.2174/1573405617666210114141300](https://doi.org/10.2174/1573405617666210114141300)



CrossMark

This is an Open Access article published under CC BY 4.0
<https://creativecommons.org/licenses/by/4.0/legalcode>



2. MATERIALS AND METHODS

2.1. Study Population

The study was approved by the local ethics committee, and an informed consent was obtained from each patient. Between April 2017 and May 2017, fat-suppressed T1A sequences of 62 patients who underwent inner ear Magnetic Resonance Imaging (MRI) were prospectively evaluated. Various clinical information was available for all patients. The most common clinical indications for MRI were vertigo and tinnitus. Patients without fat in the inner ear and patients under 18 years of age were excluded from the study. All MR images of the remaining 40 patients (20 men, 20 women; mean age 49±14 years; range 18-79 years) were evaluated.

2.2. Magnetic Resonance Imaging

MRI was performed using a 1.5 T superconducting magnet (Ingenia; Philips Medical Systems, Best, the Netherlands, 2016) with an 8-channel neurovascular coil. The T1-weighted turbo spin-echo (TSE) SPIR sequence parameters were as follows: TR/TE 550/10ms, matrix 184x146, number of excitations (NEX) 2.0, field of view 16 cm, slice thickness 3.0 mm, slice spacing 0.3 mm, and scan acquisition times 210 sec. The T1-weighted TSE SPAIR sequence parameters were as follows: TR/TE 550/10ms, matrix 140x111, NEX 2.0, field of view 16 cm, slice thickness 3.0 mm, slice spacing 0.3 mm, and scan acquisition times 254 sec. The S3D T1-weighted mDIXON-all BH SENSE sequence parameters were as follows: TR/TE 5.9/1.8 ms, matrix 156x121, NEX 2.0, field of view 20 cm, slice thickness 3.0mm, slice spacing 1.5 mm, and scan acquisition times 30 sec. All MR images were analysed on a Philips Ingenia 1.5T release 4.1.1 workstation (Eindhoven, the Netherlands).

2.3. Image Analysis

Fat-suppressed T1 images of the inner ear MRI examinations of all patients were evaluated by two radiologists who were blinded to each other's measurements; one (radiologist 1) had 15 years of experience and the other (radiologist 2) had 20 years of experience. The mean signal intensity of fat (SI) was measured by placing a 'region of interest'(ROI) on areas containing inner ear fat which were obtained using the T1-weighted TSE SPIR, T1-weighted TSE SPAIR and T1-weighted mDIXON techniques. The ROI diameter used was 9-20 mm². The standard deviation (SD) of noise was measured in the same slice where the ROI was placed for all fat-suppressed techniques (Figs. 1 and 2). The signal-to-noise ratio (SNR) was calculated according to the formula $SNR = 0.655 \times (SI)/(SD)$ [8-10].

In all fat-suppressed sequences, the spinal cord signal intensity/mean fat signal intensity ratio and spinal cord SNR were calculated (Fig. 3). The suppression efficacy of the MR techniques for fat areas in the inner ear was visually graded as 1 poor, 2 suboptimal, 3 acceptable, 4 good, and 5 excellent.

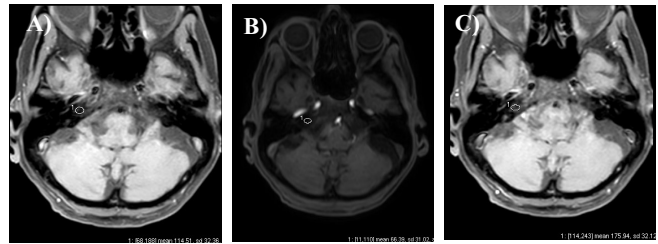


Fig. (1). T1-weighted MR images with SPIR (A), mDixon (B) and SPAIR (C) techniques for fat suppression. ROIs are placed on the fat to obtain signal intensities for SNR. (A higher resolution / colour version of this figure is available in the electronic copy of the article).

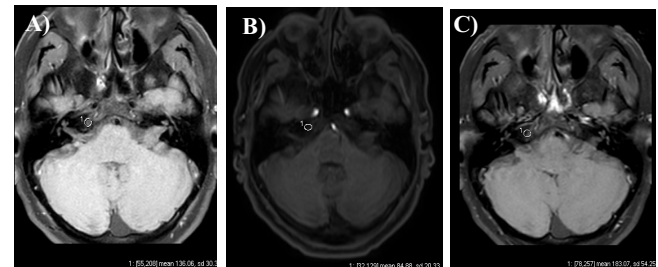


Fig. (2). T1-weighted MR images with SPIR (A), mDixon (B) and SPAIR (C) techniques for fat suppression. (A higher resolution / colour version of this figure is available in the electronic copy of the article).

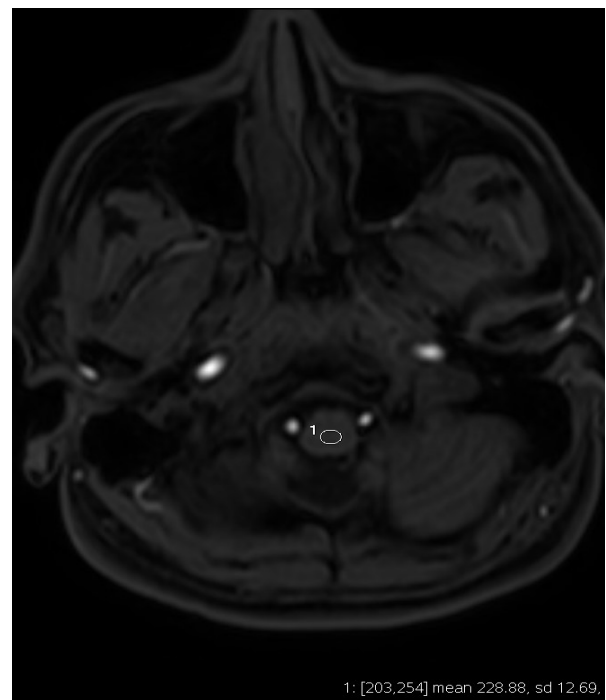


Fig. (3). T1-weighted MR images with mDixon techniques for fat suppression. ROIs are placed on the spinal cord to obtain signal intensities for SNR. (A higher resolution / colour version of this figure is available in the electronic copy of the article).

2.4. Statistical Analysis

Data analysis was performed on a personal computer using statistical software (SPSS 21 for Windows, Chicago, IL). Descriptive statistics are shown as the mean \pm standard deviation for continuous variables and as percentage for categorical variables. Differences between groups were examined with a paired t-test for continuous data or chi-square analysis for categorical data. Intergroup comparisons were performed using the Friedman test and repeated measures ANOVA. A p-value less than 0.05 was considered to indicate statistical significance. Intraclass Correlation Coefficient (ICC) scores with 95% Confidence Interval (CI) were calculated. To evaluate the inter-observer agreement for the visual grading of each sequence, kappa (κ) statistics were also calculated. Interobserver agreement was categorized as follows: 0.01-0.20 slight, 0.21-0.40 fair, 0.41-0.60 moderate, 0.61-0.80 substantial, and ≥ 0.81 excellent [6].

3. RESULTS

The results of qualitative assessment of image quality following fat suppression in the inner ear from both observers indicated that the Dixon technique produced significantly better images than the SPAIR and SPIR techniques ($p < 0.0001$) (Table 1). The mean signal intensity of the inner ear fat for T1-weighted Dixon technique was significantly lower than those for the SPAIR and STIR techniques ($p < 0.0001$).

The SNR for the Dixon technique was significantly lower than those for SPIR and SPAIR techniques ($p < 0.0001$). The spinal cord / fat intensity ratio (SFR) for the Dixon technique was also significantly higher than the SFRs for the SPAIR and STIR techniques ($p < 0.0001$). The spinal cord SNRs for the SPAIR and Dixon techniques were also significantly higher than that for the STIR technique (Table 2). There were no significant differences in the spinal cord SNRs between the Dixon and the SPAIR techniques ($p = 0.06$).

Inter-observer agreements regarding all assessments for each technique were found to be statistically significant ($p < 0.0001$). The inter-observer agreements for the Dixon ($\kappa = 0.55$), SPIR ($\kappa = 0.56$) and SPAIR ($\kappa = 0.47$) techniques used for the assessment of image quality were determined to be moderate. The inter-observer agreement regarding the measurement of the inner ear fat and mean signal intensity values was determined to be excellent for all techniques (Dixon ICC=0.942; SPAIR ICC=0.876; SPIR ICC=0.899). The inter-observer agreement regarding the measurement of the mean SNR values was determined to be excellent for all techniques (Dixon ICC=0.897; SPAIR ICC=0.813; SPIR ICC=0.855).

4. DISCUSSION

Using fat tissue suppression techniques is essential in head and neck MR examinations because without them, it is difficult to distinguish the border of a lesion or lymph node from the surrounding fat tissue in the head and neck regions. Various fat-suppression techniques for MRI have been de-

scribed in previous studies [5-9]. In our study, fat suppression performed using the SPIR, SPAIR and DIXON techniques was compared qualitatively and quantitatively in 40 patients who underwent MRI of the inner ear.

In clinical practice, the most commonly used hybrid fat-suppression techniques are SPIR and SPAIR. Both techniques are insensitive to B0 inhomogeneities. However, due to the use of a full 180° adiabatic pulse, the SPAIR technique is also insensitive to B1 inhomogeneities. The insensitivity of hybrid techniques to B0 inhomogeneities causes heterogeneous fat suppression in FOVs that are larger than the shimmed area. The Dixon technique is insensitive to B0 and B1 field heterogeneities. Accordingly, the Dixon technique provides SNR-efficient fat suppression in abdominal imaging, paediatric imaging, vertebral imaging and imaging in regions with high magnetic susceptibility [3, 9, 11].

In our study, effective fat suppression in the inner ear, which is adjacent to different anatomical structures, was achieved with Dixon technique, and a superior image quality was obtained compared to that obtained with the hybrid techniques. Another advantage of the Dixon technique is that it has a shorter scan acquisition time than hybrid techniques, as observed in our study [3-12].

In our study, the SNR was significantly lower with the Dixon technique than with the hybrid techniques. With the Dixon technique, there was a marked suppression of the fat signal in the inner ear where we performed measurements, and this may explain the reason for low SNR obtained with the Dixon technique in our study. T Kishida *et al.* calculated the SNR in lung tissue and found it to be significantly higher with the STIR technique than with the Dixon and SPAIR techniques [6]. However, Kirchgessner *et al.* while comparing the fat-suppression techniques in the wrist reported that the SNR obtained with the 3D FSPGR T1-weighted Dixon technique was significantly higher than that obtained with 3D FSPGR T1-weighted CHES and 3D FSE T1-weighted CHES [13].

Gaddikeri *et al.* compared the Dixon, SPIR and STIR techniques with T2-weighted MR sequences in the head and neck region [12]. In their study, the spinal cord signal intensity to subcutaneous fat tissue signal intensity ratio was also measured quantitatively with these techniques, and this ratio was found to be significantly higher with the Dixon technique. We also quantitatively assessed the spinal cord to inner ear SFR in addition to assessing the SNR. The SFR was found to be significantly higher with the Dixon technique than with the hybrid techniques. Moreover, in our study, we compared the SNRs of the spinal cord obtained with all the fat suppression techniques, and the SNRs were found to be higher with the DIXON and SPAIR techniques.

Kishida *et al.* qualitatively evaluated the image quality of the thorax and fat suppression efficiency in their study and found that the Dixon technique was superior to the SPAIR and SPIR techniques [6]. In a similar study conducted in the head and neck region, image quality in T2-weighted sequences was found to be superior with the Dixon tech-

Table 1. Qualitative evaluation of image quality for SPIR, SPAIR and mDIXON techniques.

Techniques		SPIR		SPAIR		mDIXON	
Observers		R 1	R 2	R 1	R 2	R 1	R 2
Visual grades	Poor	0	0(%)	6(15%)	0(%)	0(%)	0(%)
	Suboptimal	5(12.5%)	3(7.5%)	9(22.5%)	5(12.5%)	0(%)	0(%)
	Acceptable	11(27.5%)	11(27.5%)	19(47.5%)	12(30%)	1(2.5%)	1(2,5%)
	Good	21(52.5%)	21(52.5%)	5(12.5%)	20(50%)	5(12.5%)	6(15%)
	Excellent	3(7.5%)	5(12.5%)	1(2.5%)	3(7.5%)	34(85%)	33(82.5%)
K values		0.56		0.47		0.55	
Image quality		3,55±0,81		2,65±0,97		4,83 ±0,44	

* R1: Radiologist 1; R2:Radiologist 2.

Table 2. Quantitative evaluation of all techniques.

-	SPIR		95% ICC	SPAIR		95% ICC	mDIXON		95% ICC
	R1	R2		R1	R2		R1	R2	
Fat Signal intensity	115.63±47,43	114,32±43,53	0,899	161,47±64,71	159,92±56,12	0,876	54,74±24,10	57,04±26,45	0,942
Standart deviation	2,65±0,77	2,34±0,55	0,542	2,99±1,01	2,66±0,70	0,529	2,38±0,86	2,23±0,49	0,482
*SNR	29,98±13,42	32,88±12,50	0,855	37,77±17,99	42,07±18,71	0,813	16,22±7,34	17,40±7,99	0,897
*Spinal cord /fat signal intensity	3,28±1,44	3,2±1,12	0,876	2,89±1,09	2,80±1,04	0,895	5,31±1,79	5,09±1,70	0,916
** Spinal Cord SNR	12,09±3,27	12,04±3,28	0,875	11,60±3,45	11,59±3,48	0,893	13,80±3,54	13,77±3,56	0,904

R1: Radiologist 1; R2:Radiologist 2, SNR: Signal to Noise Ratio

* statistical significant difference between techniques(SPIR - SPAIR, SPIR - DIXON, SPAIR - DIXON)(p<0.0001)

** statistical significant difference between techniques (SPIR – SPAIR, p=0.005)(SPIR – DIXON, p=0.006)

nique than with the SPIR technique [12]. In the study of Kirchgessner *et al.*, image quality and fat suppression in soft tissue and bone marrow were found to be significantly better with the T1-weighted Dixon technique than with the T1-weighted CHESSE technique [13]. In our study, the qualitative evaluation of image quality following fat suppression in the inner ear region revealed that the results were significantly better with the Dixon technique than with the hybrid techniques.

In our study, the SNR values of the fatty area obtained from the inner ear region were smaller with the DIXON technique than with the SPIR and SPAIR techniques. We hypothesise that the smaller SNR values achieved with the DIXON technique were because DIXON suppresses fat more effectively than the SPIR and SPAIR techniques, and the lower signal obtained from the fat tissue leads to lower SFR values. When quantitatively comparing fat-suppression techniques, we recommend using the spinal cord/ fat signal intensity ratio or the spinal cord SNR instead of the SNR of the fatty area, which we thought would be more suggestive.

Our study has several limitations. First, our study population was small. However, the number of patients in the study group was similar to that in other studies conducted on the Dixon technique. Second, there were no pathological lesions

in the patients of the study group. Thus, a comparison of fat-suppression techniques was not performed to evaluate the visibility of pathological lesions in the inner ear region. In our study, we tried to minimize false-positive results and partial volume artifacts. To ensure that optimal MR evaluations of the inner ear were performed, the ROI value we used was selected to be within the range recommended by the MR software.

CONCLUSION

In conclusion, among the fat suppression techniques used in MRI of the inner ear, the Dixon technique was found to produce a higher image quality and fat-suppression efficiency than the hybrid techniques.

AUTHOR'S CONTRIBUTIONS

Pinar CAKMAK: Protocol development; Data collection and management; Data analysis; Manuscript writing and editing. Duygu HEREK: Data management; Manuscript writing and editing; Data analysis. Ahmet Baki YAGCI: Manuscript editing. Ergin SAGTAS: Manuscript editing. Furkan UFUK: Manuscript editing. Vefa CAKMAK: Data management, Manuscript writing and editing.

ETHICS APPROVAL AND CONSENT TO PARTICIPATE

Pamukkale University Faculty of Medicine Ethics Committee approved this study (Number:60116787-020/23482).

HUMAN AND ANIMAL RIGHTS

No Animals were used in this study. All the human procedures were in accordance with the ethical standards of the committee responsible for human experimentation (institutional and national), and with the Helsinki Declaration of 1975, as revised in 2013 (<http://ethics.iit.edu/ecodes/node/3931>).

CONSENT FOR PUBLICATION

The study was approved by the local ethics committee, and an informed consent was obtained from each patient.

AVAILABILITY OF DATA AND MATERIAL

Data sharing is not applicable to this article as no datasets were generated or analyzed during the current study.

FUNDING

None.

CONFLICT OF INTEREST

The authors have no conflicts of interest, financial or otherwise.

ACKNOWLEDGEMENTS

Declared none.

REFERENCES

- [1] Delfaut EM, Beltran J, Johnson G, Rousseau J, Marchandise X, Cotten A. Fat suppression in MR imaging: techniques and pitfalls. *Radiographics* 1999; 19(2): 373-82. <http://dx.doi.org/10.1148/radiographics.19.2.g99mr03373> PMID: 10194785
- [2] Bley TA, Wieben O, François CJ, Brittain JH, Reeder SB. Fat and water magnetic resonance imaging. *J Magn Reson Imaging* 2010; 31(1): 4-18. <http://dx.doi.org/10.1002/jmri.21895> PMID: 20027567
- [3] Del Grande F, Santini F, Herzka DA, *et al.* Fat-suppression techniques for 3-T MR imaging of the musculoskeletal system. *Radiographics* 2014; 34(1): 217-33. <http://dx.doi.org/10.1148/rg.341135130> PMID: 24428292
- [4] Dixon WT. Simple proton spectroscopic imaging. *Radiology* 1984; 153(1): 189-94. <http://dx.doi.org/10.1148/radiology.153.1.6089263> PMID: 6089263
- [5] Brandão S, Seixas D, Ayres-Basto M, *et al.* Comparing T1-weighted and T2-weighted three-point Dixon technique with conventional T1-weighted fat-saturation and short-tau inversion recovery (STIR) techniques for the study of the lumbar spine in a short-bore MRI machine. *Clin Radiol* 2013; 68(11): e617-23. <http://dx.doi.org/10.1016/j.crad.2013.06.004> PMID: 23932678
- [6] Kishida Y, Koyama H, Seki S, *et al.* Comparison of fat suppression capability for chest MR imaging with Dixon, SPAIR and STIR techniques at 3 Tesla MR system. *Magn Reson Imaging* 2018; 47: 89-96. <http://dx.doi.org/10.1016/j.mri.2017.11.012> PMID: 29180099
- [7] Ma J, Jackson EF, Kumar AJ, Ginsberg LE. Improving fat-suppressed T2-weighted imaging of the head and neck with 2 fast spin-echo Dixon techniques: initial experiences. *AJNR Am J Neuroradiol* 2009; 30(1): 42-5. <http://dx.doi.org/10.3174/ajnr.A1132> PMID: 18653688
- [8] Kirchgessner T, Perlepe V, Michoux N, Larbi A, Vande Berg B. Fat suppression at 2D MR imaging of the hands: Dixon method versus CHESST technique and STIR sequence. *Eur J Radiol* 2017; 89: 40-6. <http://dx.doi.org/10.1016/j.ejrad.2017.01.011> PMID: 28267547
- [9] Guerini H, Omoumi P, Guichoux F, *et al.* Fat suppression with Dixon techniques in musculoskeletal magnetic resonance imaging: A pictorial review. *Semin Musculoskelet Radiol* 2015; 19(4): 335-47. <http://dx.doi.org/10.1055/s-0035-1565913> PMID: 26583362
- [10] Goerner FL, Clarke GD. Measuring signal-to-noise ratio in partially parallel imaging MRI. *Med Phys* 2011; 38(9): 5049-57. <http://dx.doi.org/10.1118/1.3618730> PMID: 21978049
- [11] Rybicki FJ, Chung T, Reid J, Jaramillo D, Mulkern RV, Ma J. Fast three-point Dixon MR imaging using low-resolution images for phase correction: A comparison with chemical shift selective fat suppression for pediatric musculoskeletal imaging. *AJR Am J Roentgenol* 2001; 177(5): 1019-23. <http://dx.doi.org/10.2214/ajr.177.5.1771019> PMID: 11641161
- [12] Gaddikeri S, Mossa-Basha M, Andre JB, Hippe DS, Anzai Y. Optimal fat suppression in head and neck MRI: Comparison of multi-point Dixon with 2 different fat-suppression techniques, spectral presaturation and inversion recovery, and STIR. *AJNR Am J Neuroradiol* 2018; 39(2): 362-8. <http://dx.doi.org/10.3174/ajnr.A5483> PMID: 29242364
- [13] Kirchgessner T, Perlepe V, Michoux N, Larbi A, Vande Berg B. Fat suppression at three-dimensional T1-weighted MR imaging of the hands: Dixon method versus CHESST technique. *Diagn Interv Imaging* 2018; 99(1): 23-8. <http://dx.doi.org/10.1016/j.diii.2017.09.004> PMID: 29054404