

CASE REPORT

Epididymal papillary cystadenocarcinoma metastasising to the testis in a patient with infertility managed with Onco-microTeSE

Nisha Pindoria^{1,*}, Yurina Miki², Andrea Tay¹, Ashish Chandra², Christopher Anderson³, Evangelos Zacharakis¹, and Majed Shabbir¹

¹Department of Urology, Guy's Hospital, London SE1 9RT, UK, ²Department of Histopathology, Guy's Hospital, London SE1 9RT, UK, and ³Department of Urology, St George's Hospital, London SW17 0QT, UK

*Correspondence address. Department of Urology, Guy's Hospital, Great Maze Pond, London SE1 9RT, UK. Tel: +44-2071887188; Fax: +44-0207 188 6793; E-mail: nishapindoria@hotmail.com

Abstract

Papillary cystadenomas of the epididymis are known to occur in association with Von Hippel–Lindau (VHL) disease. The development of a papillary cystadenocarcinoma, its malignant counterpart, is rare with only a few sporadic cases reported in the literature. Metastatic deposits are exceedingly uncommon; in fact, only a single case report has documented metastases to the paraurethral region, but metastases to the testis have never been reported. A 43-year-old gentleman with VHL disease presented with non-obstructive azoospermia, a right epididymal mass, and an atrophic surgically corrected undescended left testis. The epididymal mass was reported as a papillary cystadenocarcinoma on biopsy. The patient was managed with a radical inguinal orchidectomy and bench microTeSE with successful sperm retrieval. Metastatic papillary cystadenocarcinoma of the epididymis to the testis has never been previously reported. This case was managed by radical orchidectomy and subsequent onco-microTeSE, allowing safe oncological treatment and optimal fertility preservation.

INTRODUCTION

Von Hippel–Lindau (VHL) disease is a rare inherited condition affecting 1 in 36 000 births and is associated with the development of various multi-system tumours, including haemangioblastomas, pheochromocytomas, renal cell carcinomas, endolymphatic sac tumours and papillary cystadenomas of the epididymis (in men) and broad uterine ligament (in women) [1]. Although the association between VHL and primary epididymal papillary cystadenomas is well known, there is extremely limited information about its malignant counterpart (i.e. papillary

cystadenocarcinomas) with only a few cases reported in the literature [2–6]. The few case reports available have not been associated with VHL disease. As a result, there is also limited information regarding their optimal long-term management.

We present the first reported case of a 43-year-old gentleman with VHL disease presenting with azoospermia and subsequently diagnosed with a primary epididymal papillary cystadenocarcinoma, infiltrating the spermatic cord and accompanied by a metastatic deposit in the right testis. The patient was ultimately managed by a combination of radical orchidectomy and onco-microTeSE.

Received: September 13, 2016. Accepted: November 8, 2016

Published by Oxford University Press and JSCR Publishing Ltd. All rights reserved. © The Author 2016.

This is an Open Access article distributed under the terms of the Creative Commons Attribution Non-Commercial License (<http://creativecommons.org/licenses/by-nc/4.0/>), which permits non-commercial re-use, distribution, and reproduction in any medium, provided the original work is properly cited. For commercial re-use, please contact journals.permissions@oup.com

CASE REPORT

A 43-year-old gentleman with known VHL disease and a history of multiple renal carcinomas presented with primary infertility and non-obstructive azoospermia. On examination, he had an atrophic left testis (secondary to a previous orchidopexy for cryptorchidism) and a firm mass in the right epididymis. He was referred for testicular sperm extraction. At the time of surgical sperm retrieval, a biopsy was taken from the epididymal mass, which was reported as a cystadenocarcinoma. A further biopsy was taken of a mass incidentally noted in the upper pole of the right testis, which on histology was suggestive of a metastatic deposit of renal cell carcinoma. No other sites of renal metastasis were seen on subsequent imaging. An orchidectomy was advised, but declined by the patient as he was keen to start a family.

After successfully having a child via *in vitro* fertilisation (IVF) treatment, he re-attended the urology department for definitive management of his epididymal and testicular tumours. He was asymptomatic and clinical examination revealed a palpable mass in the head of the epididymis measuring ~1.5 cm. A separate small mass was also palpable in the upper pole of the right testis. Blood tests revealed normal testicular tumour markers (α -fetoprotein, β -human chorionic gonadotrophin and lactate dehydrogenase). Follicle stimulating hormone and leutenizing hormone levels were 36 and 13 mIU/mL respectively, with a testosterone level of 12.2 nmol/L.

Preoperatively, the optimal management strategy of his testicular and paratesticular lesions was complicated given the rarity of the case coupled with the challenge of multiple issues including:

- (1) Future fertility preservation.
- (2) Atrophic, previously undescended, contralateral testis.
- (3) Borderline testosterone levels.
- (4) Propensity to develop further tumours on a background of VHL disease.

Initially, a partial orchidectomy was considered to preserve future fertility. However, after review at the multidisciplinary team (MDT) meeting, it was felt that a radical orchidectomy was the safest oncological management option and was agreed by the patient. This was performed via an inguinal approach and an onco-microTeSE (microsurgical testicular sperm extraction in azoospermic cancer patients performed once the testicle has been removed) was carried out to allow for future family planning. Isolated areas of dilated tubules were retrieved under $\times 20$ magnification with viable sperm cryopreserved for future IVF. Post-operatively, there were no reported complications.

Subsequent histological review revealed a multinodular tumour in the head and body of the epididymis, which exhibited varying architectural patterns. In some areas, the tumour resembled that of a classical papillary cystadenoma with papillary structures projecting into cystic spaces lined by cuboidal to columnar cells with pale eosinophilic to clear cytoplasm. However, in other areas, the tumour was composed of cystic as well as solid sheets of polygonal cells with clear cytoplasm. Furthermore, there was evidence of tumour infiltration into the spermatic cord. There was also a separate deposit in the upper pole of the testis, which was composed of cystic spaces filled with eosinophilic secretions and lined by polygonal cells with clear cytoplasm. Immunohistochemistry was also performed on both the tumour deposits in the epididymis and testis. Based on the immunohistochemical findings, it was felt that the intratesticular tumour deposit most likely represented

a metastasis from the papillary cystadenocarcinoma of the epididymis (Figs 1 and 2).

Given the unusual nature of the case, the unknown prognosis of papillary cystadenocarcinomas and the lack of established treatment protocols post-orchidectomy, an MDT decision of close clinical surveillance with regular follow-up was made.

DISCUSSION

This case is interesting on a number of levels. Papillary cystadenomas of the epididymis are known to occur in association with VHL disease. However, the development of a papillary cystadenocarcinoma, its malignant counterpart, is incredibly rare. There is a single case report, which has documented metastases from such tumours to the paraureteral region [7]. However, metastasis to the testis has not been previously reported in the available published literature. The presentation on a background of infertility and atrophic undescended contralateral testis raises further dilemmas in management.

Surgical debulking remains as the cornerstone for the treatment of primary malignant epididymal tumours either via partial or radical orchidectomy. A radical orchidectomy was

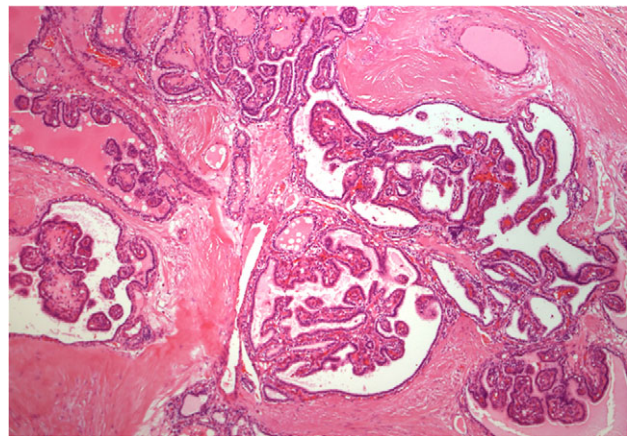


Figure 1: Histology of epididymal tumour showing varying architectural patterns. In some areas, the epididymal tumour resembled that of a classical papillary cystadenoma (4 \times magnification).

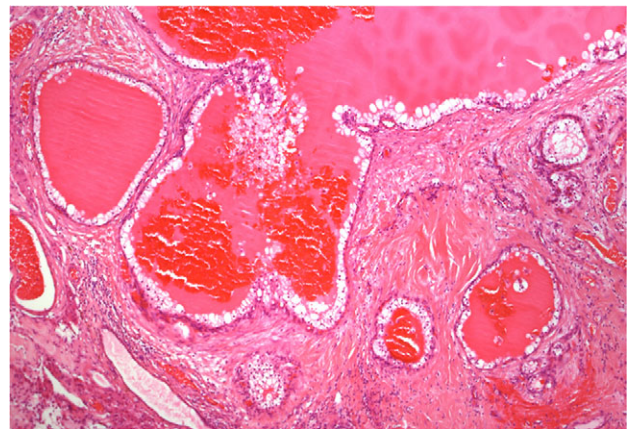


Figure 2: Histology of separate tumour deposit in testis composed of cystic spaces filled with eosinophilic secretions and lined by polygonal cells with clear cytoplasm (4 \times magnification).

considered to be the optimal treatment in view of the nature and location of his tumour, but the limited functional potential of his contralateral atrophic testis made his management more challenging. In this case, fertility preservation was paramount to the patient. Combining his radical orchidectomy with a simultaneous surgical sperm retrieval using an onco-microTESE allowed safe oncological management and optimal fertility preservation. Referral to specialist units with expertise in performing onco-microTESE is important in such difficult cases.

CONSENT

Written consent was obtained from the patient for publication of this case report and the accompanying images.

ACKNOWLEDGEMENTS

None.

CONFLICT OF INTEREST STATEMENT

None declared.

REFERENCES

1. Lonser RR, Glenn GM, Walther M, Chew EY, Libutti SK, Lineham WM, et al. Von Hippel Lindau disease. *Lancet Seminar* 2003;**361**:2059–67.
2. Kurihara K, Oka A, Mannami M, Iwata Y. Papillary adenocarcinoma of the epididymis. *Acta Pathol Jpn* 1993;**43**:440–3.
3. Yu CC, Huang JK, Chiang H, Chen MT, Chang LS. Papillary cystadenocarcinoma of the epididymis: a case report and review of the literature. *J Urol* 1992;**147**:162–5.
4. Nozawa T, Konda R, Ohsawa T, Yoshida M, Komatsu M, Iwama T, et al. Clear cell papillary cystadenocarcinoma of the epididymis: a case report and immunohistochemistry of markers for renal cell carcinoma. *Histol Histopathol* 2013;**28**:321–6.
5. Ganem JP, Jhaveri FM, Marroum MC. Primary adenocarcinoma of the epididymis: case report and review of the literature. *Urology* 1998;**52**:904–8.
6. Jones MA, Young RH, Scully RE. Adenocarcinoma of the epididymis: a report of four cases and review of the literature. *Am J Surg Pathol* 1997;**21**:1474–80.
7. Wang TY, Chiang H, Huang JK, Liu HC. Papillary cystadenocarcinoma of the epididymis—report of a case. *Zhonghua Yi Xue Za Zhi (Taipei)* 1990;**45**:139–42.