

CASE REPORT

Hypersensitivity Reaction as a Harbinger of Acute Myeloid Leukemia: A Case Report and Review of the Literature

Jeffrey M. Cohen, Carol E. Cheng, Aieska DeSouza, Tina R. Nandi, Elizabeth A. Buzney, Allison Larson¹, Winston Y. Lee¹, Arash Mostaghimi

Departments of Dermatology and ¹Pathology, Brigham and Women's Hospital, Harvard Medical School, Boston, MA, USA

Cutaneous paraneoplastic syndromes comprise a broad spectrum of cutaneous reactions to an underlying malignancy. These dermatoses are not the result of metastatic spread to the skin, but rather a reaction to the presence of malignancy. Cutaneous paraneoplastic syndromes often precede the identification of a malignancy. We describe the case of a 79-year-old man with a six-month history of recalcitrant treatment-resistant dermatitis. A complete blood count test performed at the time of initial presentation was normal. The patient ultimately presented with erythroderma and was diagnosed with acute myeloid leukemia (AML). The evolution of the dermatitis to erythroderma coincided with the clinical presentation of AML, and was therefore considered to be a paraneoplastic syndrome. The patient decided against therapy and died seven weeks after diagnosis. Physicians should consider a cutaneous paraneoplastic syndrome when faced with dynamic recalcitrant dermatoses that are difficult to treat and decide on laboratory testing accordingly. Patients should be evaluated regularly for two to three years after initial diagnosis with a physical exam and review of systems to monitor for signs and symptoms of malignancy. (**Ann Dermatol 27(2) 190~193, 2015**)

Received May 26, 2014, Revised July 30, 2014, Accepted for publication August 1, 2014

Corresponding author: Arash Mostaghimi, Department of Dermatology, Brigham and Women's Hospital, Harvard Medical School, Boston, MA 02115, USA. Tel: 1-617-732-5889, Fax: 1-617-525-3177, E-mail: amostaghimi@partners.org

This is an Open Access article distributed under the terms of the Creative Commons Attribution Non-Commercial License (<http://creativecommons.org/licenses/by-nc/3.0>) which permits unrestricted non-commercial use, distribution, and reproduction in any medium, provided the original work is properly cited.

-Keywords-

Paraneoplastic syndromes, Leukemia, Acute myeloid, Dermatitis

INTRODUCTION

Cutaneous paraneoplastic syndromes are dermatoses that result from complex interactions between a malignancy and the skin^{1,2}. Importantly, the cutaneous manifestations in a paraneoplastic syndrome are not the result of metastatic spread to the skin¹. Although the pathophysiology of the majority of cutaneous paraneoplastic syndromes is poorly understood, current evidence suggests that they are related to the production of bioactive substances by the tumor cells or secondary to tumor-induced antigen-antibody interactions¹. We describe the case of a 79-year-old man, with a six-month history of recalcitrant treatment-resistant dermatitis who was ultimately diagnosed with AML and paraneoplastic erythroderma.

CASE REPORT

A 79-year-old man was referred to Brigham and Women's Hospital for evaluation of an erythematous eruption on his bilateral flank areas and right lower back. The rash had been present for approximately 3 months and was associated with intense pruritus. A prior biopsy had revealed mild spongiosis, focal parakeratosis, dermal edema, and a superficial perivascular lymphocytic infiltrate with eosinophils. This was consistent with a hypersensitivity reaction, possibly due to medications. He experienced mild improvement after treatment with oral prednisone and topical clobetasol cream, but the rash returned quickly

when these treatments were tapered.

On initial evaluation at our clinic, the patient had an erythematous, blanching eruption over the trunk and extremities (Fig. 1). His past medical history was significant for mild Alzheimer's disease dementia; stage 3 chronic kidney disease; atrial fibrillation; major depression; and a distant history of prostate cancer that had been treated with a radical prostatectomy. He did not have any history of rash, including either psoriasis or atopic dermatitis. His medications upon presentation included allopurinol, aspirin, venlafaxine, fenofibrate, memantine, nicotinic acid, quetiapine, simvastatin, and sotalol. He was allergic to fluoroquinolones and hydromorphone. The results of a basic metabolic panel were unremarkable, with the exception of chronically elevated creatinine levels (1.52 mg/dl). The complete blood count (CBC) was notable for leukocytosis (13.43 K/ μ l) with a normal cell differential. Even though the patient's medications had not changed in the preceding two years, they were then discontinued over the course of a month due to concern for a possible adverse

drug reaction. The rash did not improve.

One month later, the patient presented with a diffuse urticarial eruption displaying a different morphology from that at the initial presentation. He was given a 21-day prednisone taper and antihistamines. The prednisone was stopped due to increased emotional lability. Following the abrupt cessation of the steroid treatment a few days after starting the tapered dose, the urticaria completely cleared. Forty-eight hours later, the patient developed diffuse pruritic flat-topped violaceous papules over 50% of his body. Rebiopsy identified lichenoid dermatitis with mixed spongiotic and cytotoxic changes. The patient received seven sessions of narrowband ultraviolet B phototherapy without improvement.

Four months after the initial presentation, the patient was hospitalized due to worsening mental status and a progressive cutaneous eruption. He had erythroderma with diffuse erythematous plaques involving the face, trunk, and extremities, with regions of thick hyperkeratotic scale on the forearms and thighs (Fig. 2). On his palms and

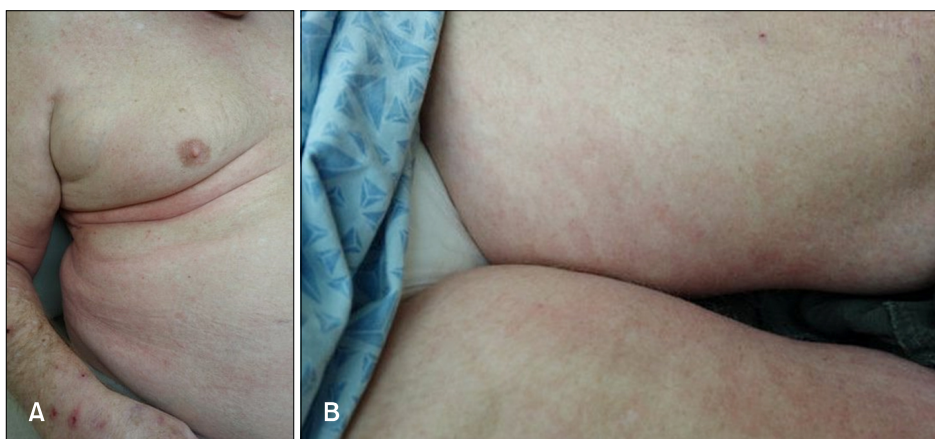


Fig. 1. (A) Erythematous, blanching patches over the right chest and flank. (B) Erythematous, blanching patches over the medial thighs.

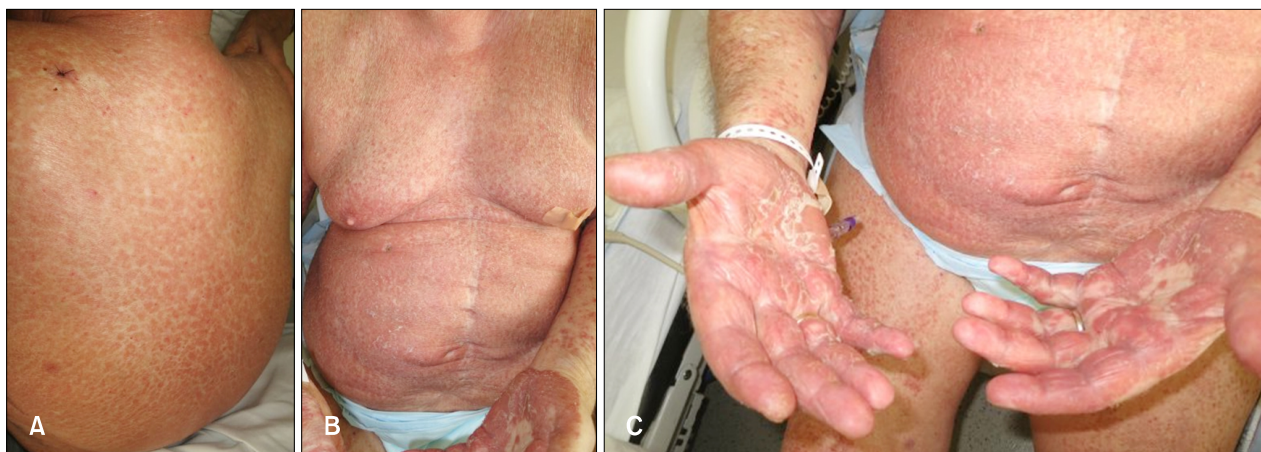

Fig. 2. Erythroderma with diffuse erythematous plaques involving the face, trunk, and extremities with psoriasiform plaques on the forearms and thighs. (A) Back, (B) anterior trunk, (C) palmar surfaces of hands.

soles, he had red plaques with thick scale and prominent desquamation. There was no mucosal involvement or nail changes.

A CBC revealed thrombocytopenia of $49,000/\mu\text{L}$; a white blood cell count of $9.88\text{ K}/\mu\text{L}$; and hematocrit levels of 44.7. The white blood cell differential was as follows: neutrophils, 42%; bands, 4%; lymphocytes, 18%; monocytes, 22%; eosinophils, 5%; and myelocytes, 9%. The patient underwent a bone marrow biopsy, which showed a hypercellular bone marrow with more than 20% blasts (Fig. 3). This biopsy, in conjunction with the flow cytometry results, which showed a population of $\text{CD34}^+ \text{CD13}^+ \text{CD33}^+ \text{CD15}^-$ myeloblasts, was consistent with acute myeloid leukemia (AML). A cytogenetic study of the bone marrow did not reveal any known AML-associated chromosomal translocations.

A skin biopsy of the back showed a superficial and deep atypical CD3+ CD2+ CD5+ lymphoid infiltrate with associated lymphocytic vasculitis and focal interface dermatitis (Fig. 4). Immunostaining of the skin biopsy failed to show evidence of a lymphoproliferative disorder. Ultimately, the clinical presentation and pathologic analysis of the biopsy specimens appeared most consistent with a paraneoplastic erythroderma.

The patient and his family decided not to pursue curative treatment. He was discharged from the hospital and died seven weeks later.

DISCUSSION

Paraneoplastic erythroderma has been previously reported in the literature, and is most commonly associated with lymphomas^{1,3}. It has also been reported in cases of myelodysplasia as well as in solid tumors of various organs including the lungs, colon, and cervix^{3,4}. These skin changes can precede clinical malignancy by several years⁴. Our patient's rash was polymorphic, but it also included hyperkeratotic palmoplantar lesions and facial and ear involvement. This was suggestive of an acrokeratosis paraneoplastica of Bazex-like eruption in the context of developing AML. However, our patient lacked the violaceous color and nail changes that are generally associated with Bazex. Bazex is most commonly associated with solid tumors of the aerodigestive tract, and an association with AML has not been previously reported in the literature⁵. Cutaneous paraneoplastic syndromes represent diagnostic and therapeutic challenges. As in the current case, cutaneous lesions can often present prior to the clinical diag-

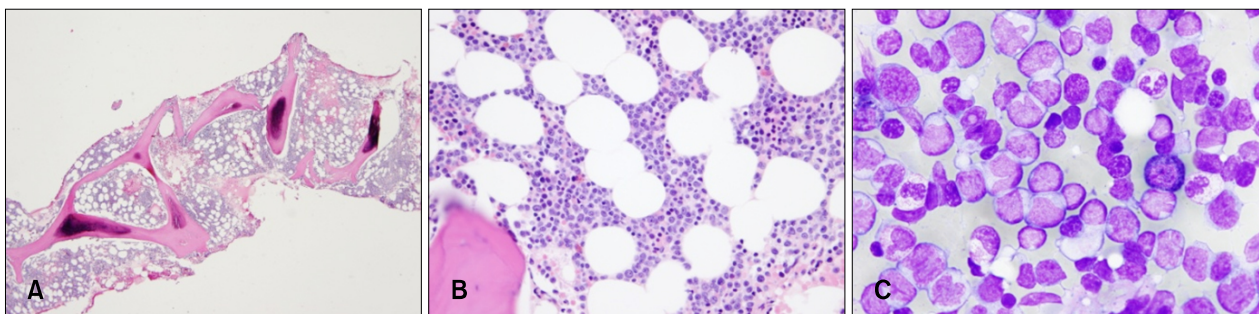


Fig. 3. (A) Bone marrow biopsy showing a hypercellular bone marrow (40% fat), on low power (H&E, $\times 40$). (B, C) Composition of more than 20% blast cells seen on medium power (H&E, $\times 400$) and high power (Wright Giemsa Stain, $\times 1,000$).

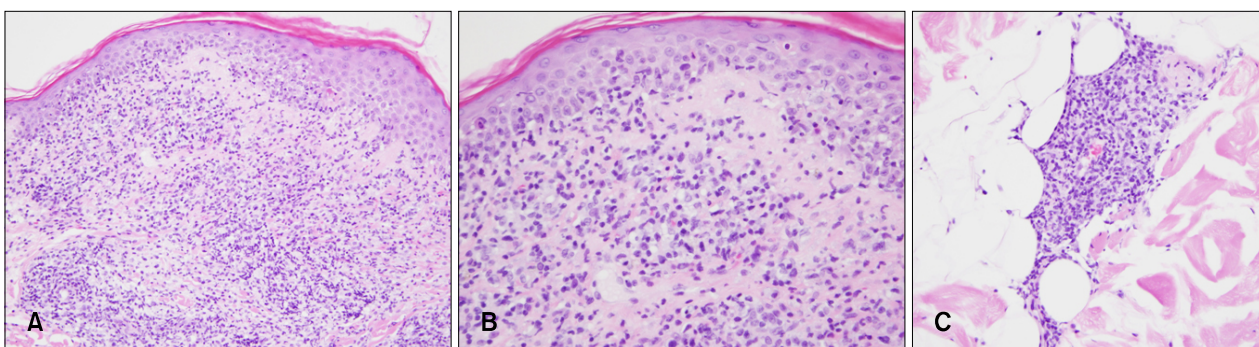


Fig. 4. (A) Skin biopsy of the back showing superficial and deep atypical lymphoid infiltrate (H&E, $\times 20$). (B) Focal interface dermatitis (H&E, $\times 40$). (C) Associated lymphocytic vasculitis (H&E, $\times 20$).

nosis of malignancy, and clinical and histopathological features can evolve over time. The connection between the initial cutaneous findings and the erythroderma remains unclear. While the patient did not have AML at the initial evaluation, as evidenced by his normal CBC with differential, it is possible that the hypersensitivity-like dermatosis was a manifestation of an immune response produced by subclinical disease. The subsequent change in cutaneous findings may then have occurred at the time of onset of clinical AML, which could have elicited a different immune response.

Physicians should consider a cutaneous paraneoplastic syndrome when faced with dynamic recalcitrant dermatoses that are difficult to treat. Patients should be evaluated regularly for two to three years with a physical exam and review of systems, to monitor for signs and symptoms of malignancy. If any evidence of a systemic process is identified, clinicians should apply a low threshold in further laboratory evaluations. Patients should also be prompt-

ly evaluated if there is any abrupt clinical change because, as demonstrated in our case, this may signify the onset of clinical malignancy.

REFERENCES

1. Brenner S, Tamir E, Maharshak N, Shapira J. Cutaneous manifestations of internal malignancies. *Clin Dermatol* 2001; 19:290-297.
2. Thiers BH, Sahn RE, Callen JP. Cutaneous manifestations of internal malignancy. *CA Cancer J Clin* 2009;59:73-98.
3. Hanafusa T, Igawa K, Takagawa S, Yahara H, Harada J, Tani M, et al. Erythroderma as a paraneoplastic cutaneous disorder in systemic anaplastic large cell lymphoma. *J Eur Acad Dermatol Venereol* 2012;26:710-713.
4. Thomas I, Schwartz RA. Cutaneous paraneoplastic syndromes: uncommon presentations. *Clin Dermatol* 2005;23:593-600.
5. Bologna JL, Brewer YP, Cooper DL. Bazex syndrome (acro-keratosis paraneoplastica). An analytic review. *Medicine (Baltimore)* 1991;70:269-280.