

Operative treatments for osteochondral lesions of the talus in adults

A systematic review and meta-analysis

Hongbo Tan, MD^a, Anxu Li, MS^a, Xiong Qiu, MS^a, Yi Cui, MD^a, Wenbao Tang, MS^a, Gang Wang, MS^a, Wei Ding, MD^b, Yongqing Xu, MD^{a,*}

Abstract

Purpose: This systematic review aimed to identify the available evidence regarding the comparative effectiveness and safety of various operative treatments in adult patients with osteochondral lesions of the talus (OLT).

Materials and methods: The PubMed, Embase, ISI Web of Knowledge, and the Cochrane Controlled Trial Register of Controlled Trials were searched from their inception date to September 2019. Two reviewers selected the randomized controlled trials (RCTs) and non-RCTs assessing the comparative effectiveness and safety of various operative treatments for OLT. The meta-analysis was performed using Revman 5.3.

Results: Eight studies (1 RCT and 7 non-RCTs) with 375 patients were included in this review. The difference in the American Orthopaedic Foot and Ankle Society (AOFAS) score between the cartilage repair and replacement was not significant. The cartilage regeneration with or without cartilage repair had significant superiority in improving the AOFAS score compared with the cartilage repair. The difference in the magnetic resonance observation of cartilage repair tissue score between the cartilage repair and replacement and between cartilage repair and cartilage repair plus regeneration was significant.

Conclusions: Cartilage regeneration and cartilage repair plus regeneration had significant superiority in improving the ankle function and radiological evaluation of OLT, although the trials included did not have high-level evidence. Moreover, which treatment between the 2 was safer could not be addressed in this review as most of the trials did not report the safety outcome. Further studies are needed to define the best surgical option for treating OLT.

Abbreviations: ACI = autologous chondrocyte implantation, AOFAS = American Orthopaedic Foot and Ankle Society, BMDC = bone marrow-derived cell, CI = confidence interval, MACI = matrix-induced autologous chondrocyte implantation, MOCART = magnetic resonance observation of cartilage repair tissue, OAT = osteochondral autograft/allograft transplantation, OLT = osteochondral lesions of the talus, PJCAT = particulated juvenile cartilage allograft transplantation, PRP = platelet-rich plasma, RCTs = randomized controlled trials, SMD = standardized mean difference, WMD = weighted mean difference.

Keywords: cartilage regeneration, cartilage repair, meta-analysis, osteochondral lesions, systematic review, talus

Editor: Wen-Wei Sung.

This study was supported by the National Key Research and Development Program of China (2017YFC1103904); the Talent Program of Yunnan Province (2018HB001); China Postdoctoral Science Foundation (2015M572718).

The authors have no conflicts of interest to disclose.

Data Availability: All data generated or analyzed during this study are included in this published article.

All data generated or analyzed during this study are included in this published article [and its supplementary information files].

^a Department of Orthopedic, the 920th Hospital of Joint Logistics Support Force,

^b College of Medicine, Yunnan University of Business Management, Kunming, China.

* Correspondence: Yongqing Xu, Department of Orthopedic, the 920th Hospital of Joint Logistics Support Force, Kunming 650032, China (e-mail: xuyongqingkm@163.net).

Copyright © 2021 the Author(s). Published by Wolters Kluwer Health, Inc. This is an open access article distributed under the terms of the Creative Commons Attribution-Non Commercial License 4.0 (CCBY-NC), where it is permissible to download, share, remix, transform, and buildup the work provided it is properly cited. The work cannot be used commercially without permission from the journal.

How to cite this article: Tan H, Li A, Qiu X, Cui Y, Tang W, Wang G, Ding W, Xu Y. Operative treatments for osteochondral lesions of the talus in adults: a systematic review and meta-analysis. *Medicine* 2021;100:25(e26330).

Received: 20 February 2020 / Received in final form: 2 September 2020 / Accepted: 27 May 2021

<http://dx.doi.org/10.1097/MD.00000000000026330>

1. Introduction

The osteochondral lesions of the talus (OLT) involve both cartilage and subchondral bone lesions.^[1] Patients presenting with OLT are often athletes or have a history of significant ankle trauma within 1 year of symptom onset. The majority of patients are aged 20 to 40 years, and men are more commonly affected than women (1.6:1).^[2] Typically, nonspecific ankle pain that correspond to or not correspond to the location of the lesion often occurs in patients. Additionally, they often complain of recurrent swelling, weakness, stiffness, and catching of the ankle joint.^[3] Available treatment methods may not prevent joint degeneration. In some patients, sequelae of early-stage foot ankle osteoarthritis form, leading to excess pain and movement restriction in the foot ankle in the long term.^[4] Patients with chronic OLT may present with deep, intermittent pain in the ankle joint with weightbearing.^[5] These symptoms place the ability to walk, work, and perform sports at risk, which often has a severe impact on the quality of life of active patients, especially athletes.^[6]

Nonoperative treatment of OLT includes activity modification, protected weight-bearing, physical therapy, bracing, and use of nonsteroidal anti-inflammatory drugs.^[7,8] These treatments are often aimed at treating symptoms, such as pain, rather than providing a cure.^[9] In other words, they may relieve symptoms but cannot repair cartilage injuries. Nonoperative treatment is

appropriate for fresh cartilage injuries that are nondisplaced and have a potential for healing depending on their size and location as well as on patient parameters, such as age, socio-professional context, or smoking.^[10] This approach may be beneficial to the adolescent population, rather than to the adult population.^[10,11] This is mostly due to the biologic properties of hyaline cartilage, namely its avascularity, limiting the healing potential of the articular surface. Clinically, a systematic review of OLT by Verhagen et al^[12] showed that among 201 patients in 14 studies, only 91 (45%) reported successful outcomes with nonoperative treatment.

Many operative treatments have been used to treat OLT, and are usually classified as cartilage repair, cartilage regeneration, and cartilage replacement.^[13] Microfracture, defined as one of the main types of cartilage repair, is the most common procedure for managing OLT. It is described as the first-line operative treatment after an unsuccessful result of nonoperative treatment. It is recommended for smaller talus lesions not exceeding 1.5 cm².^[14,15] Further, the autologous chondrocyte implantation (ACI) is a staged technique attributed to cartilage regeneration.^[16,17] It is a cell-based cartilage regeneration technique using chondrocytes cultivated *ex vivo*. It has been established for treating full cartilage defects of the knee joint in clinical routine, with proven long-term efficacy.^[18] It is often used after unsuccessful nonoperative treatment or microfracture, and is currently offered only through a single vendor in the USA.^[19] The ACI can be used for larger lesions, but its implementation is limited by cost, the need for 2 separate surgical procedures, and the fact that it requires a stable osseous bed.^[11,20,21] Cartilage replacement, such as osteochondral autograft/allograft transplantation (OAT), can replace the talus osteochondral lesions with hyaline cartilage. The main benefit of OAT is that these grafts maintain type-II collagen, to reproduce the mechanical, structural, and biochemical properties of the original hyaline articular cartilage.^[21] OAT shows a trend toward greater longevity and durability as well as improved outcomes in high-demand patients when compared with other options for osteochondral lesion repair.^[22]

The treatment of OLT is challenging, despite the many operative techniques available. The fact that no systematic review concluded which technique was more effective and safer was a concerning issue for the orthopedists. Therefore, this systematic review aimed to identify and analyze the available evidence regarding the comparative effectiveness and safety of different types of operative treatments in adult patients with OLT.

2. Materials and methods

A systematic review was performed according to the Cochrane systematic review guidelines and the Preferred Reporting Items for Systematic Reviews and Meta-Analyses checklist.^[23,24] All analyses were based on previous published studies, thus no ethical approval and patient consent are required.

2.1. Search strategy

The PubMed, Embase, ISI Web of Knowledge, and Cochrane Controlled Trial Register of Controlled Trials were searched from their inception date to September 2019 to identify studies assessing the comparative effectiveness and safety of operative treatments for OLT without language restriction. The following search terms were used: cartilage, osteochondral, osteochon-

dritis, ankle, talus, talar, astragalus, tibia, and talocrural. The references for all identified studies, including related systematic reviews, were searched manually for additional relevant studies.

2.2. Study selection criteria

The inclusion/exclusion criteria for the population, intervention, comparison, outcomes, and study were defined and applied. The studies were selected by 2 reviewers independently. After deleting the duplications, the titles and abstracts were screened for all identified potential studies. All studies with possible relevance were then retrieved in full text for a comprehensive assessment according to the inclusion criteria; disagreement was resolved by discussion or consensus with a third reviewer.

2.3. Inclusion criteria

2.3.1. Participants. Adult (older than 18 years) patients diagnosed with symptomatic OLT. Symptoms included chronic ankle pain, recurrent swelling, weakness, stiffness, and catching of the ankle joint, which were related to symptomatic OLT.

2.3.2. Intervention and comparison. All types of operative treatments were included. Cartilage repair included bone marrow stimulation (microfracture) and retrograde drilling; cartilage regeneration included ACI, matrix-induced autologous chondrocyte implantation (MACI), platelet-rich plasma (PRP), and bone marrow-derived cell (BMDC) transplantation; and cartilage replacement included OAT.

2.3.3. Outcomes. The primary outcomes were the effectiveness outcome, American Orthopaedic Foot and Ankle Society (AOFAS) score for the function of the talus, and revision rates. The AOFAS score is a numerical system emphasizing the patient's perception of function and pain. An AOFAS score of 100 to 90 points was considered as excellent, 89 to 80 as good, 79 to 70 as fair, and <69 as poor results.^[25] The secondary outcomes included radiological outcomes and safety outcomes. The radiological outcome was assessed using the magnetic resonance observation of cartilage repair tissue (MOCART) score.^[26] The safety outcome was assessed using the complication rate.

2.3.4. Study. Any published or unpublished randomized controlled trials (RCTs) or non-RCTs were selected, including conference papers.

2.4. Exclusion criteria

Trials focusing primarily on the treatment of patients with multiple cartilage lesions not limited to the talus were excluded. Trials comparing the same type of operative treatment were excluded, such as the open ACI versus arthroscopic ACI, and OAT compared with allograft transplantation. Studies that did not report the eligible outcome or data were excluded. Letters, reviews, animal experiments, case reports, case series, and studies without control were also excluded.

2.5. Data collection and analysis

Two reviewers independently extracted data using a data extraction form. Potential author discord was resolved through discussion or, when necessary, by involving a third author to establish consensus. All study characteristics and data, such as

study population, sample size, and outcome data, were extracted according to a predefined form.

2.6. Quality assessment

Two reviewers assessed the methodological quality independently. The Cochrane Collaboration Guidelines for the risk of bias was used for the quality assessment of RCTs.^[23] The items for the risk of bias were divided into 7 domains: random sequence generation, allocation concealment, blinding of participants and personnel, blinding of outcome assessment, incomplete outcome data, selective reporting, and other types of bias. The bias was described to indicate a low or high risk of bias; “unclear” indicated that the risk of bias was unclear. For non-RCTs, the methodological index for nonrandomized studies checklist was used.^[26] The items were scored on a 3-point scale: 0 (not reported), 1 (reported, but not adequate), or 2 (reported and adequate). Any disagreement was resolved by the consensus of all authors.

2.7. Statistical analysis

The meta-analysis was performed using Revman 5.3. The results were expressed as risk ratios for dichotomous outcomes. For continuous outcomes with final data, the weighted mean difference (WMD) or the standardized mean difference (SMD) was used, both with 95% confidence interval (CI). The SMD was applied if the studies used different instruments to measure the same construct. The I^2 values were used to assess heterogeneity. A considerable statistical heterogeneity between the studies was assumed if the I^2 value was $>50\%$.^[23] A fixed-effects model was used in the case of no significant heterogeneity; otherwise, a random-effects model was used. Publication bias was tested using the funnel plot.

3. Results

Initially, 1154 potentially relevant studies were identified through electronic and manual searches. Among these, 336 studies due to duplicate publications and 620 studies after screening the titles and abstracts were excluded. Of the remaining 98 studies, 25

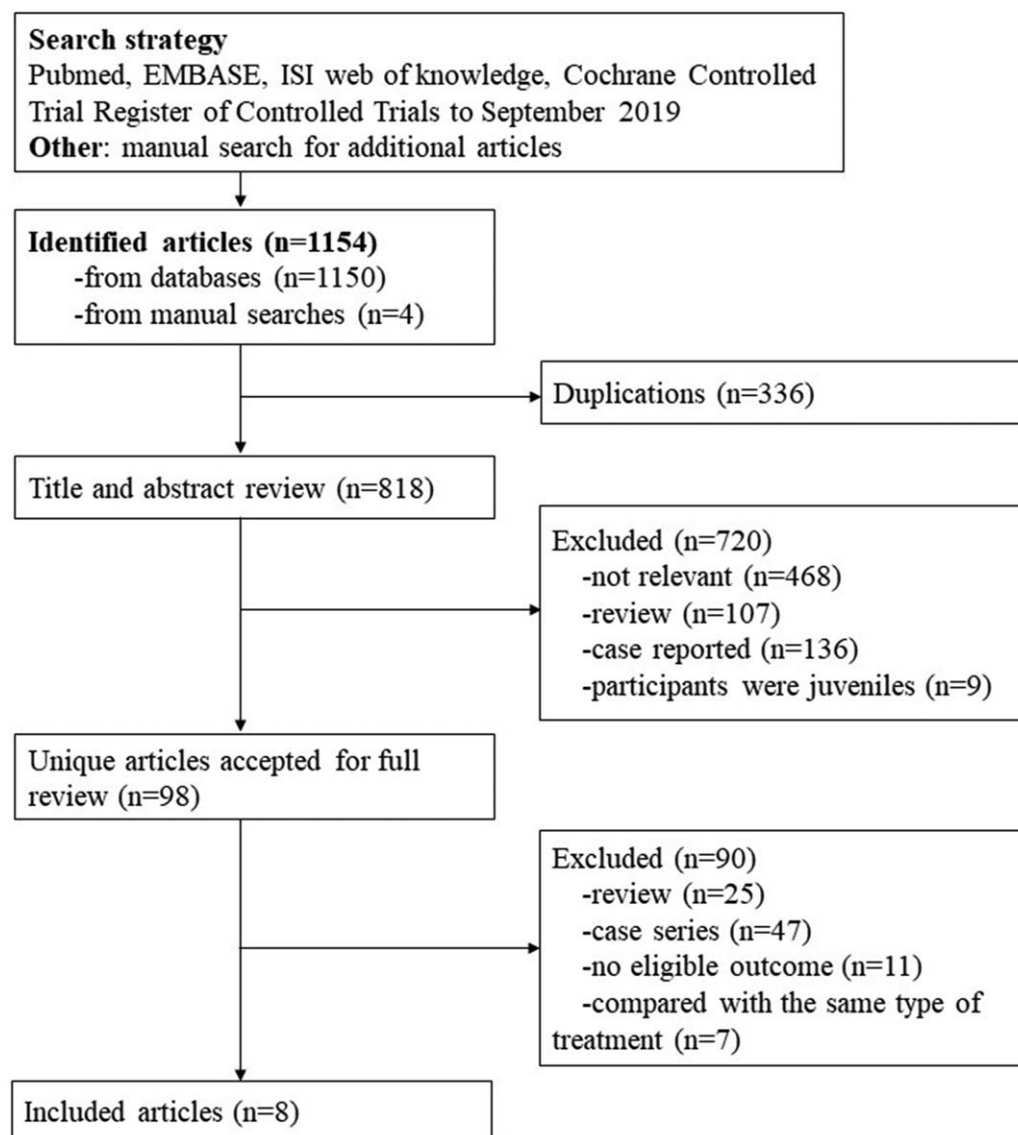


Figure 1. Summary of the literature identification and selection process.

Table 1
Characteristics of trials included in the present meta-analysis.

Study	Design	Patients	Experimental group	Control group	Follow up	Outcomes
Cartilage repair versus cartilage replacement						
Liberati A, 2009 ^[24]	Case controlled	Talar dome lesions	Cartilage repair 17 Patients; curettage and subchondral drilling	Cartilage replacement 14 Patients; bone grafts	71.5±21.1 months	8-Point scale, assessing the range of motion, pain, and crepitus; radiographic assessment
Gobbi A 2006 ^[29]	RCT	Osteochondral lesions of the talus	11 Patients; microfracture	10 Patients; osteochondral autograft transplantation	53 months (range, 24–119 months)	AOFAS, AHS, SAME, NPI, and MRI findings
Domayer SE 2012 ^[30]	Case controlled	Cartilage repair of the ankle	10 Patients; microfracture	10 Patients; matrix-associated autologous cartilage transplantation	113.8 months in group 1 and 65.4 months in group 2	AOFAS, MRI findings, and ROI analysis
Cartilage repair versus cartilage regeneration						
Apprioch S 2012 ^[31]	Case controlled	Stable adjacent cartilage on the talar dome	Cartilage repair 10 patients; microfracture therapy	Cartilage regeneration 10 patients; matrix-associated autologous chondrocyte transplantation	A minimum follow-up of 18 months	AOFAS and MOCART
Tahta M 2017 ^[32]	Case controlled	Osteochondral lesions of the talus	46 patients; nanofracture	52 patients; hyaluronic acid-based cell-free scaffold with concentration of autologous bone marrow aspirate	42.2±9.2 months in group 1 and 40.1±11.6 months in group 2	AOFAS, VAS, and MOCART
Cartilage repair versus cartilage repair + cartilage regeneration						
Kim YS 2014 ^[33]	Case controlled	Osteochondral lesions of the talus	Cartilage repair 26 patients; bone marrow stimulation	Cartilage repair +cartilage regeneration 24 patients; marrow stimulation with an injection of a stromal vascular fraction containing mesenchymal stem cells	27.1 months (range, 22–41 months)	VAS, AOFAS, Tegner scores, and MOCART score
Hammon CP 2016 ^[34]	Case controlled	Osteochondral lesions of the talus	12 patients; arthroscopic bone marrow stimulation	22 patients; arthroscopic bone marrow stimulation and concentrated bone marrow aspirate	77.3 months in group 1 and 48.3 months in group 2	FAOS and SF-12 PCS, and MOCART score
Murphy EP 2019 ^[35]	Case controlled	Osteochondral lesions of the talus	52 patients; microfracture alone	49 patients; microfracture augmented with bone marrow aspirate concentrate and fibrin glue	Minimum follow-up for both groups was 36 months	VAS pain score, FAOS, and revision rate

AHS = Ankle Hindfoot Scale, AOFAS = American Orthopaedic Foot and Ankle Society, HSS = Hannover Scoring System, MOCART = magnetic resonance observation of cartilage repair tissue, MRI = magnetic resonance imaging, NPI = numeric pain intensity, RCT = randomized controlled trial, ROI = region of interest, SAME = single-assessment numeric evaluation, VAS = visual analogue scale.

Table 2
Methodological quality of the RCTs.

Item	Gobbi A 2006 ^[29]
Random sequence generation	Unclear
Allocation concealment	Unclear
Blinding of participants and personnel	Unclear
Blinding of outcome assessment	Low
Incomplete outcome data	Unclear
Selective reporting	Unclear
Other types of bias	Unclear

Low, low risk of bias; High, high risk of bias; and Unclear, the risk of bias was unclear.
RCT = randomized controlled trial.

were reviews, 47 were case series, 11 were without eligible outcome, and 7 had the same type of treatment after reading the full text, and hence were excluded. Finally, 8 trials with 375 patients were included in this systematic review.^[28–35] The selection process of the studies is shown in Fig. 1.

3.1. Study characteristics

All studies included were published between 2000 and 2019. One was RCT,^[24] and the others were non-RCTs.^[28,30–35] Three trials compared cartilage repair with cartilage replacement,^[28–30] 2 trials compared cartilage repair with cartilage regeneration,^[31,32] and 3 trials compared cartilage repair with cartilage repair plus cartilage regeneration.^[33–35] The treatments included in the cartilage repair were curettage and subchondral drilling, microfracture, nano-fracture, and bone marrow stimulation. The cartilage replacement included OAT, matrix-associated autologous cartilage transplantation, and arthroscopic autologous matrix-induced chondrogenesis. Cartilage regeneration included MACI and hyaluronic acid-based cell-free scaffold with a concentration of autologous bone marrow aspirate. The follow-up ranged from 18 to 113.8 months. The sample sizes ranged from 10 to 101. The characteristics of trials included in the present meta-analysis are shown in Table 1.

3.2. Quality assessment

The methodological quality of the trials is shown in Tables 2 and 3. The quality assessment of the RCTs included the following:

Table 3
Methodological quality of the non-RCTs.

	Liberati A, 2009 ^[24]	Domayer SE 2012 ^[30]	Apprich S 2012 ^[31]	Tahta M 2017 ^[32]	Kim YS 2014 ^[33]	Hannon CP 2016 ^[34]	Murphy EP 2019 ^[35]
1. A clearly stated aim	2	2	2	2	2	2	2
2. Inclusion of consecutive patients	0	0	2	0	0	0	0
3. Prospective collection of data	2	2	2	2	2	2	2
4. Endpoints appropriate to the aim of the study	2	2	2	2	2	2	2
5. Unbiased assessment of the study endpoint	2	0	0	0	0	0	0
6. Follow-up period appropriate to the aim of the study	2	2	1	2	2	2	2
7. Loss to follow-up less than 5%	2	2	2	2	2	2	2
8. Prospective calculation of the study size	0	0	0	0	0	0	0
Additional criteria in the case of comparative studies							
9. An adequate control group	2	2	2	2	2	2	2
10. Contemporary groups	2	2	2	2	2	2	2
11. Baseline equivalence of groups	2	0	0	1	1	2	2
12. Adequate statistical analyses	1	1	2	1	1	2	1

0, not reported; 1, reported, but not adequate; and 2, reported and adequate.
RCT = randomized controlled trial.

low, without adequately reported method of randomization, allocation concealment, blinding of participants and personnel, incomplete outcome data, and selective reporting.^[29] The RCTs adequately reported only the blinding of outcome assessment.

The non-RCTs reported a clear aim, prospective collection of data, endpoints appropriate to the aim of the study, loss to follow-up <5%, an adequate control group, and contemporary groups. However, prospective calculation of the study size was not reported in any of the trials. Only the trial of Apprich et al^[31] included patients consecutively. The trial of Apprich et al^[31] reported a minimum follow-up of 18 months, which was conducted because the endpoints were not appropriate to the aim of the study.^[31] Only 3 trials reported that the groups were similar in terms of the criteria other than the studied endpoints.^[28,33,35] All the trials reported statistical analyses, but only 2 of them were adequate.^[31,33]

3.3. Effectiveness outcome

The result of the comparison of the AOFAS score is shown in Fig. 2. Two of 3 trials comparing cartilage repair with cartilage replacement reported that the AOFAS and the difference between the cartilage repair and replacement were not significant (2 trials, 41 participants, WMD = 2.15, 95% CI = -2.90–7.20, $P = .40$).

The 2 trials comparing cartilage repair with regeneration reported that the AOFAS score and the cartilage regeneration had significant superiority in improving the AOFAS score compared with the cartilage repair (2 trials, 118 participants, WMD = -7.39, 95% CI = -11.04 to -3.75, $P < .0001$).

The 3 trials comparing cartilage repair with cartilage repair plus regeneration reported the AOFAS score. Overall, significant differences were observed between cartilage repair and cartilage repair plus regeneration (3 trials, 184 participants, WMD = -4.33, 95% CI = -6.41 to -2.26, $P < .0001$).

Only one trial reported revision rates; 14 of 52 patients in the cartilage repair group and 6 out of 49 in the cartilage repair plus regeneration group required revision.^[27] The trials defined that the difference between the groups was significant.

3.4. Radiological outcome

The result of the comparison of the MOCART score is shown in Fig. 3. Both the trials comparing cartilage repair with regenera-

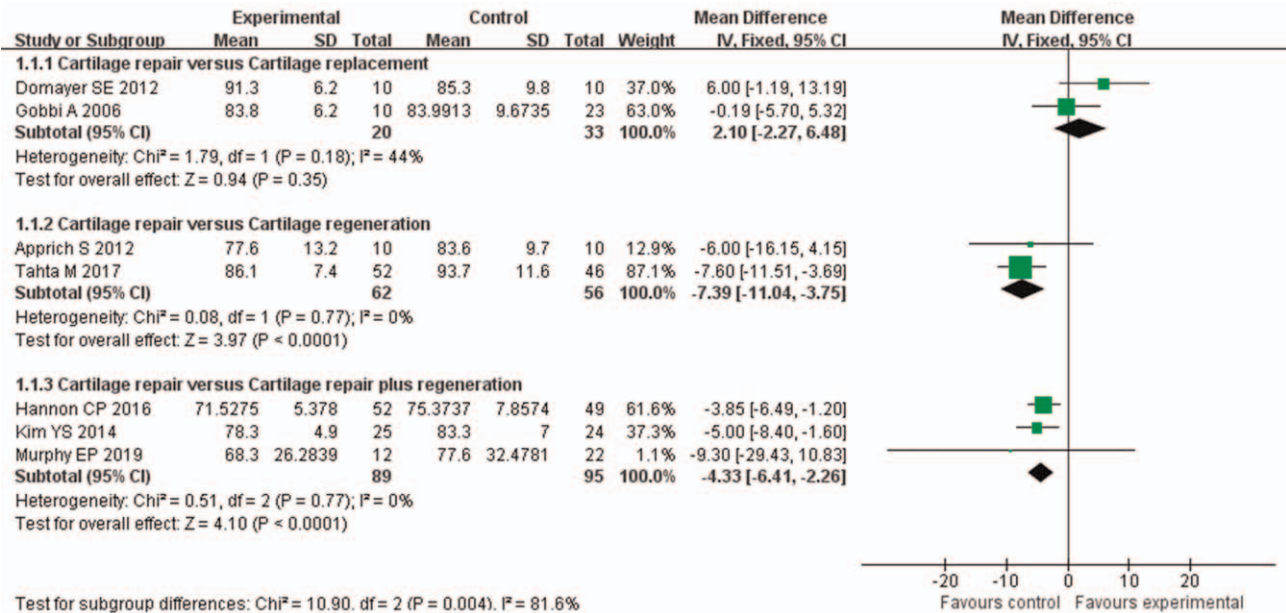


Figure 2. Comparison of the AOFAS score for the function of the talus. AOFAS=American Orthopaedic Foot and Ankle Society.

tion reported the MOCART scores, and the difference between the cartilage repair and the replacement was significant (2 trials, 118 participants, WMD = -8.78, 95% CI = -11.26 to -6.30, P < .00001).

Two of the 3 trials reported the MOCART score, and the cartilage repair plus regeneration group showed significant superiority compared with the cartilage repair group in improving the MOCART score (2 trials, 118 participants, WMD = -7.39, 95% CI = -11.04 to -3.75, P < .0001).

3.5. Safety outcome

The complication rate was reported in 2 trials.^[29,32] Gobbi et al^[29] reported pain of unknown cause at various intervals after surgery in 2 of 10 patients in the cartilage repair group and complications in 3 of 23 patients in the cartilage replacement

group. Tahta et al^[32] reported that no major complication was seen in any patient; however, the superficial infection was observed in 2 patients in the cartilage regeneration group, which was successfully treated with oral antibiotic therapy.

3.6. Publication bias

The roughly symmetrical funnel plot in Fig. 4 indicates no existence of publication bias in this meta-analysis.

4. Discussion

4.1. Summary of evidence

One systematic review reported on treatment strategies for OLT in 2003. In this previous review, 39 studies describing treatment strategies for OLT were summarized, but no RCT was included.

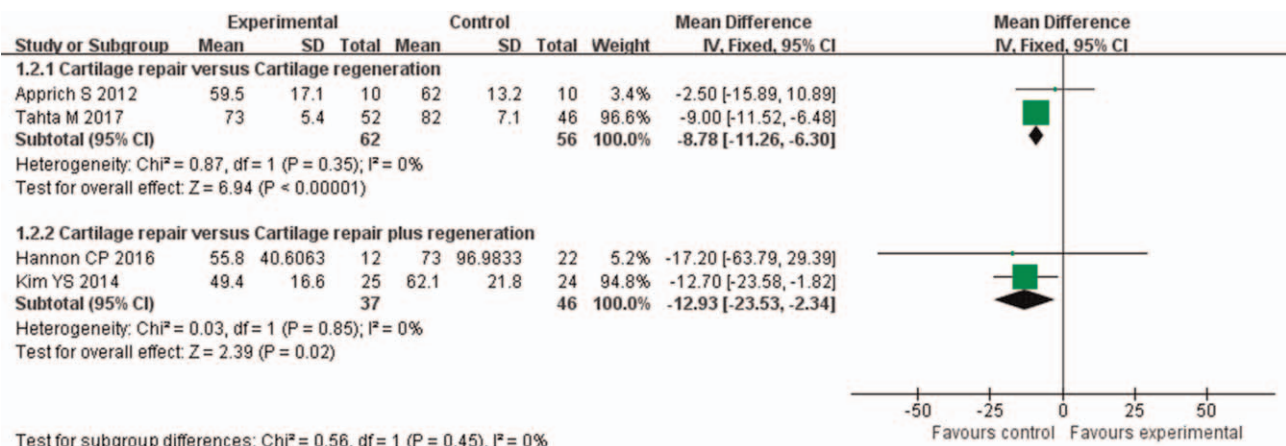


Figure 3. Comparison of the MOCART score for radiological evaluation. MOCART=magnetic resonance observation of cartilage repair tissue.

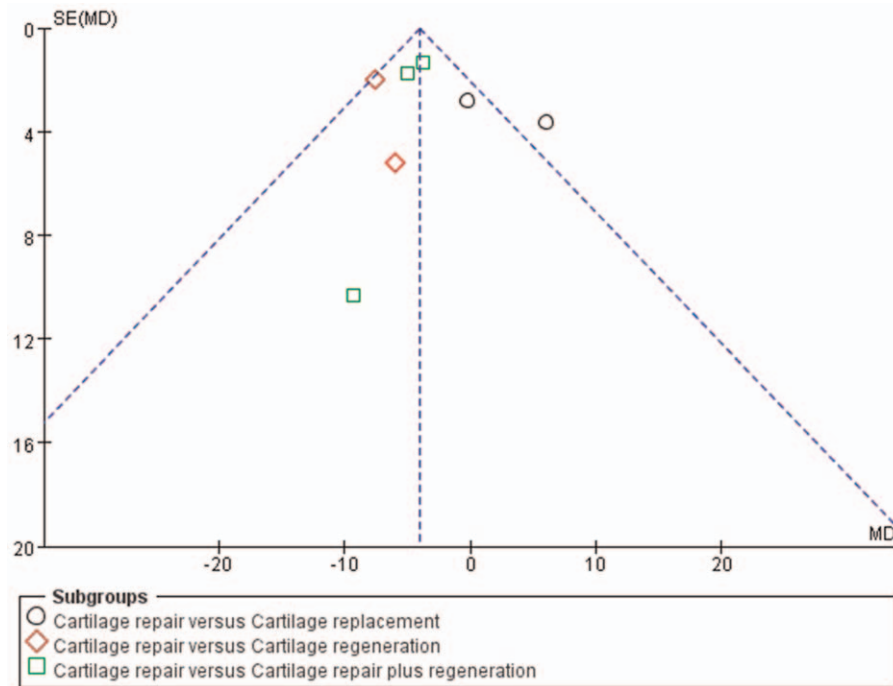


Figure 4. Funnel plot of the trials.

Moreover, as most of the trials were on nonoperative treatments, no definitive evidence was available to compare the effectiveness of these 2 types of surgical interventions.^[12] The effect and safety of microfracture and OAT were reviewed in 2016 and 2017 separately. Gross inconsistencies and an underreporting of data between studies were observed. Consequently, pooling was deemed impossible.^[36,37]

Nine trials with 387 adult patients for OLT were identified in the present study that met the inclusion criteria. The findings of this systematic review indicated that the cartilage regeneration and cartilage repair plus regeneration had significant superiority in improving the function of the ankle and radiological evaluation. The comparative effectiveness between the cartilage repair and replacement could not be confirmed. Moreover, which treatment between the 2 was safer could not be answered in this review as most of the trials did not report the safety outcome.

4.2. Cartilage regeneration

The cartilage regeneration included ACI, MACI, PRP, and BMDC transplantation. The ACI was first developed by Brittberg et al in 1994.^[39] In principle, the primary advantage of ACI was that it involved the transplantation of viable, cultured chondrocytes into the defect, thereby facilitating a presumably hyaline-like repair tissue. However, the ACI required a 2-stage operation. An injection of chondrocyte cell suspension under a sutured periosteal flap harvested from the distal end of the tibia was used in the ACI, which was a technically demanding procedure. The potential for cell dedifferentiation, cell leakage, and uneven distribution of cells limited the application of this technique. Then, the MACI was developed on the basis of the ACI, in which harvested chondrocytes were typically cultured on

a bioabsorbable, porcine type-I/III collagen membrane before implantation into the defect.^[39] Also, various other types of matrices existed, including type-I collagen gel and hyaluronic acid-based membrane.^[40] The MACI was superior to the ACI because of the following reasons: a periosteal graft harvest was avoided, a more even cell distribution was possible, the culturing process prevented the dedifferentiation of chondrocytes, and the procedure could be performed arthroscopically. A meta-analysis concluded that the ACI/MACI was reported to have success rates ranging from 50% to 100% (mean, 89.9%) for the OLT. However, the only 2 trials in this meta-analysis were case series, which did not provide high-level evidence.^[41] The PRP and BMDC transplantation techniques combined microfracture with the addition of autologous iliac crest spongiosa bone, bone marrow aspirate concentrate, and/or PRP to the lesion using a collagen matrix carrier and fibrin glue to secure the carrier. This technique allowed a 1-step arthroscopic procedure involving the use of autologous tissue with minimal donor-site morbidity.^[42]

4.3. Cartilage replacement

Cartilage replacement included OAT and particulated juvenile cartilage allograft transplantation (PJCAT). The OAT was first described by Yamashita et al in 1985 for treating lesions in the knee.^[43] It was primarily reserved for isolated lesions and subchondral cystic lesions of the talus larger than 1 cm². If the primary treatment failed to resolve smaller defects with excision, debridement, and bone marrow stimulation, the OAT procedure was considered.^[44] The OLTs secondary to avascular necrosis have been shown to be at a higher risk of failure because of the decreased vascularity resulting in poor incorporation of the graft.^[45] The PJCAT entailed the transplantation of fresh juvenile cartilage pieces containing live cells within their native

extracellular matrix. The PJCAT is available only through a single vendor at this time (Denovo; Zimmer). A fibrin adhesive was used to secure the tissue firmly inside the prepared lesion. The particulate nature of the graft obviated the need for perpendicular access, thereby eliminating the use of osteotomies of the medial or lateral malleolus and the potential for nonunion or pain at the site of implants. The graft could also be delivered with an all-arthroscopic technique.^[46] Additionally, PJCAT offered the advantages of a shallow learning curve, no graft contouring, no donor-site morbidity, and the performance of a single-stage procedure. The disadvantages of this technique were the absence of long-term data, the limited supply of juvenile donor cartilage, and the risks of disease transmission.

4.4. Limitations of this review

This study was comprehensive with no language restrictions applied, but the small and unpublished trials could not be ruled out. The evidence of this study was limited to the trials with small sample sizes. No subgroup analyses were performed due to the relatively small number of studies. Future studies should include additional trials and sufficient data to perform subgroup analysis so as to explore different estimated effects across different population demographics and patients and injury parameter subgroups. Further, the classification of the different types of treatment might have led to the loss of many unknown information about the trials. Finally, the inherent heterogeneity among included studies due to factors such as surgical centers and instruments, operating experience, and grasp of indications of surgeons might have induced significant variations in outcomes.

5. Conclusions

Cartilage regeneration and cartilage repair plus regeneration had significant superiority in improving the function of the ankle and radiological evaluation. However, the trials included in this study did not provide high-level evidence. Moreover, which treatment between the 2 was safer could not be addressed in this review because most of the trials did not report the safety outcome. Further studies are needed to define the best surgical option for treating OLT.

Author contributions

Conceptualization: Hongbo Tan, Wei Ding, Yongqing Xu.

Data curation: Hongbo Tan, Anxu Li, Xiong Qiu, Yi Cui, Wenbao Tang, Gang Wang.

Formal analysis: Hongbo Tan, Anxu Li, Xiong Qiu, Yi Cui, Wenbao Tang, Gang Wang, Wei Ding, Yongqing Xu.

Project administration: Wei Ding, Yongqing Xu.

Writing – original draft: Hongbo Tan.

Writing – review & editing: Anxu Li, Xiong Qiu, Yi Cui, Wenbao Tang, Gang Wang, Wei Ding, Yongqing Xu.

References

- [1] Seo SG, Kim JS, Seo DK, Kim YK, Lee SH, Lee HS. Osteochondral lesions of the talus. *Acta Orthop* 2018;89:462–7.
- [2] Looze CA, Capo J, Ryan MK, et al. Evaluation and management of osteochondral lesions of the talus. *Cartilage* 2017;8:19–30.
- [3] Amendola A, Panarella L. Osteochondral lesions: medial versus lateral, persistent pain, cartilage restoration options and indications. *Foot Ankle Clin* 2009;14:215–27.
- [4] Elias I, Jung JW, Raikin SM, Schweitzer MW, Carrino JA, Morrison WB. Osteochondral lesions of the talus: Change in MRI findings over time in talar lesions without operative intervention and implications for staging systems. *Foot Ankle Int* 2006;27:157–66.
- [5] Verhagen R, Maas M, Dijkgraaf MG, Tol JL, Krips R, van Dijk CN. Prospective study on diagnostic strategies in osteochondral lesions of the talus: is MRI superior to helical CT? *J Bone Joint Surg Br* 2005;87:41–6.
- [6] Zengerink M, Szerb I, Hangody L, Dopirak RM, Ferkel RD, van Dijk CN. Current concepts: treatment of osteochondral ankle defects. *Foot Ankle Clin* 2006;11:331–59.
- [7] Roach R. Osteochondral lesions of the talus. *J Am Podiatr Med Assoc* 2003;93:307–11.
- [8] Weigelt L, Laux CJ, Urbanschitz L, et al. Long-term prognosis after successful nonoperative treatment of osteochondral lesions of the talus: an observational 14-year follow-up study. *Orthop J Sports Med* 2020;8:2325967120924183.
- [9] Dombrowski ME, Yasui Y, Murawski CD. International Consensus Group on Cartilage Repair of the ankle international consensus group on cartilage repair of the ankle. conservative management and biological treatment strategies: proceedings of the international consensus meeting on cartilage repair of the ankle. *Foot Ankle Int* 2018;39(1_suppl): 9S–15S.
- [10] McGahan PJ, Pinney SJ. Current concept review: osteochondral lesions of the talus. *Foot Ankle Int* 2010;31:90–101.
- [11] Hannon CP, Smyth NA, Murawski CD, et al. Osteochondral lesions of the talus: aspects of current management. *Bone Joint J* 2014;96-B: 164–71.
- [12] Verhagen RA, Struijs PA, Bossuyt PM, van Dijk CN. Systematic review of treatment strategies for osteochondral defects of the talar dome. *Foot Ankle Clin* 2003;8:233–42. viii–ix.
- [13] Dekker TJ, Dekker PK, Tainter DM, Easley ME, Adams SB. Treatment of osteochondral lesions of the talus: a critical analysis review. *JBJS Rev* 2017;5:e4.
- [14] Murawski CD, Kennedy JG. Operative treatment of osteochondral lesions of the talus. *J Bone Joint Surg Am* 2013;95:1045–54.
- [15] Giannini S, Vannini F. Operative treatment of osteochondral lesions of the talar dome: current concepts review. *Foot Ankle Int* 2004;25: 168–75.
- [16] Niemeyer P, Salzmann G, Schmal H, Mayr H, Südkamp NP. Autologous chondrocyte implantation for the treatment of chondral and osteochondral defects of the talus: a meta-analysis of available evidence. *Knee Surg Sports Traumatol Arthrosc* 2012;20:1696–703.
- [17] Dekker TJ, Erickson B, Adams SB, Gross CE. Topical review: MACI as an emerging technology for the treatment of talar osteochondral lesions. *Foot Ankle Int* 2017;38:1045–8.
- [18] Peterson L, Vasiliadis HS, Brittberg M, Lindahl A. Autologous chondrocyte implantation: a long-term follow-up. *Am J Sports Med* 2010;38:1117–24.
- [19] Nam EK, Ferkel RD, Applegate GR. Autologous chondrocyte implantation of the ankle: a 2- to 5-year follow-up. *Am J Sports Med* 2009;37:274–84.
- [20] Baums MH, Schultz W, Kostuj T, Klinger HM. Cartilage repair techniques of the talus: an update. *World J Orthop* 2014;5:171–9.
- [21] Giannini S, Buda R, Grigolo B, Vannini F. Autologous chondrocyte transplantation in osteochondral lesions of the ankle joint. *Foot Ankle Int* 2001;22:513–7.
- [22] Richter DL, Tanksley JA, Miller MD. Osteochondral autograft transplantation: a review of the surgical technique and outcomes. *Sports Med Arthrosc Rev* 2016;24:74–8.
- [23] Chan KW, Ferkel RD, Kern B, Chan SS, Applegate GR. Correlation of MRI appearance of autologous chondrocyte implantation in the ankle with clinical outcome. *Cartilage* 2018;9:21–9.
- [24] Liberati A, Altman DG, Tetzlaff J, et al. The PRISMA statement for reporting systematic reviews and meta-analyses of studies that evaluate healthcare interventions: explanation and elaboration. *BMJ* 2009;339: b2700.
- [25] Kitaoka HB, Alexander IJ, Adelaar RS, Nunley JA, Myerson MS, Sanders M. Clinical rating systems for the ankle-hindfoot, midfoot, hallux, and lesser toes. *Foot Ankle Int* 1994;15: 349–53.
- [26] Marlovits S, Singer P, Zeller P, Mandl I, Haller J, Trattnig S. Magnetic resonance observation of cartilage repair tissue (MOCART) for the evaluation of autologous chondrocyte transplantation: determination of interobserver variability and correlation to clinical outcome after 2 years. *Eur J Radiol* 2006;57:16–23.

- [27] Slim K, Nini E, Forestier D, Kwiatkowski F, Panis Y, Chipponi J. Methodological index for non-randomized studies (minors): development and validation of a new instrument. *ANZ J Surg* 2003;73:712–6.
- [28] Draper SD, Fallat LM. Autogenous bone grafting for the treatment of talar dome lesions. *J Foot Ankle Surg* 2000;39:15–23.
- [29] Gobbi A, Francisco RA, Lubowitz JH, Allegra F, Canata G. Osteochondral lesions of the talus: randomized controlled trial comparing chondroplasty, microfracture, and osteochondral autograft transplantation. *Arthroscopy* 2006;22:1085–92.
- [30] Domayer SE, Apprich S, Stelzener D, et al. Cartilage repair of the ankle: first results of T2 mapping at 7.0 T after microfracture and matrix associated autologous cartilage transplantation. *Osteoarthritis Cartilage* 2012;20:829–36.
- [31] Apprich S, Trattng S, Welsch GH, et al. Assessment of articular cartilage repair tissue after matrix-associated autologous chondrocyte transplantation or the microfracture technique in the ankle joint using diffusion-weighted imaging at 3 Tesla. *Osteoarthritis Cartilage* 2012;20:703–11.
- [32] Tahta M, Akkaya M, Gursoy S, Isik C, Bozkurt M. Arthroscopic treatment of osteochondral lesions of the talus: Nanofracture versus hyaluronic acid-based cell-free scaffold with concentration of autologous bone marrow aspirate. *J Orthop Surg (Hong Kong)* 2017;25:2309499017717870.
- [33] Kim YS, Lee HJ, Choi YJ, Kim YI, Koh YG. Does an injection of a stromal vascular fraction containing adipose-derived mesenchymal stem cells influence the outcomes of marrow stimulation in osteochondral lesions of the talus? A clinical and magnetic resonance imaging study. *Am J Sports Med* 2014;42:2424–34.
- [34] Hannon CP, Ross KA, Murawski CD, et al. Arthroscopic bone marrow stimulation and concentrated bone marrow aspirate for osteochondral lesions of the talus: a case-control study of functional and magnetic resonance observation of cartilage repair tissue outcomes. *Arthroscopy* 2016;32:339–47.
- [35] Murphy EP, McGoldrick NP, Curtin M, Kearns SR. A prospective evaluation of bone marrow aspirate concentrate and microfracture in the treatment of osteochondral lesions of the talus. *Foot Ankle Surg* 2019;25:441–8.
- [36] Hannon CP, Murawski CD, Fansa AM, Smyth NA, Do H, Kennedy JG. Microfracture for osteochondral lesions of the talus: a systematic review of reporting of outcome data. *Am J Sports Med* 2013;41:689–95.
- [37] VanTienderen RJ, Dunn JC, Kusnezov N, Orr JD. Osteochondral allograft transfer for treatment of osteochondral lesions of the talus: a systematic review. *Arthroscopy* 2017;33:217–22.
- [38] Brittberg M, Lindahl A, Nilsson A, Ohlsson C, Isaksson O, Peterson L. Treatment of deep cartilage defects in the knee with autologous chondrocyte transplantation. *N Engl J Med* 1994;331:889–95.
- [39] Jones CW, Willers C, Keogh A, et al. Matrix-induced autologous chondrocyte implantation in sheep: objective assessments including confocal arthroscopy. *J Orthop Res* 2008;26:292–303.
- [40] Haleem AM, Chu CR. Advances in tissue engineering techniques for articular cartilage repair. *Oper Tech Orthop* 2010;20:76–89.
- [41] Erickson B, Fillingham Y, Hellman M, Parekh SG, Gross CE. Surgical management of large talar osteochondral defects using autologous chondrocyte implantation. *Foot Ankle Surg* 2018;24:131–6.
- [42] Giannini S, Buda R, Battaglia M, et al. One-step repair in talar osteochondral lesions: 4-year clinical results and t2-mapping capability in outcome prediction. *Am J Sports Med* 2013;41:511–8.
- [43] Yamashita F, Sakakida K, Suzu F, Takai S. The transplantation of an autogeneic osteochondral fragment for osteochondritis dissecans of the knee. *Clin Orthop Relat Res* 1985;43–50.
- [44] Shimozone Y, Yasui Y, Ross AW, Miyamoto W, Kennedy JG. Scaffolds based therapy for osteochondral lesions of the talus: a systematic review. *World J Orthop* 2017;8:798–808.
- [45] Gautier E, Kolker D, Jakob RP. Treatment of cartilage defects of the talus by autologous osteochondral grafts. *J Bone Joint Surg Br* 2002;84:237–44.
- [46] Adams SB Jr, Demetracopoulos CA, Parekh SG, Easley ME, Robbins J. Arthroscopic particulated juvenile cartilage allograft transplantation for the treatment of osteochondral lesions of the talus. *Arthrosc Tech* 2014;3:e533–7.