

Transvenous lead implantation via the accessory hemiazygos vein in superior vena cava occlusion



Peter H. Waddingham, BSc, MBBS, MRCP,^{*†} Adam S.C. Dennis, BSc, MBBS, MRCP,^{*}
Anu Balan, MBBS, MRCP, FRCR,^{*} Anthony W.C. Chow, MBBS, BSc, MD, FRCP^{*†}

From the ^{*}Barts Heart Centre, St Bartholomew's Hospital, Barts Health NHS Trust, London, United Kingdom, and [†]Queen Mary University of London, Charterhouse Square Barts and the London School of Medicine and Dentistry Queen Mary University of London, London, United Kingdom.

Introduction

Occlusion of the superior vena cava (SVCO) hinders pacemaker and defibrillator lead delivery. Central venous stenosis or occlusion due to pacemaker or defibrillator leads is relatively common at the time of lead revision or device upgrade; however, complete occlusion occurs in less than 10%.^{1,2} Multiple implanted leads is associated with increased risk of developing SVCO.³ The presence of a persistent left superior vena cava (SVC) also complicates lead delivery and impacts lead stability; however, lead delivery is often still feasible.⁴ Persistent left SVC is the commonest thoracic venous anomaly, with a prevalence of 0.3%–0.5%, typically draining into the coronary sinus in more than 90% of cases.⁵ It can also drain anomalously into the left atrium and associate with both heart rhythm disorders and complex congenital heart disease. The right SVC may also be absent in approximately 10% of cases.⁵

This case describes a novel approach for percutaneous transvenous lead delivery via a persistent left SVC and collateralized left accessory hemiazygos vein. This was a technically challenging but feasible route using standard equipment for delivery of left ventricle (LV) leads. Computed tomography (CT) venography and venous angiography were key to the planning of this procedure.

Case report

A 55-year-old male patient with idiopathic non-ischemic cardiomyopathy and prior cardiac resynchronization therapy defibrillator (CRT-D) device implantation required urgent CRT-D reimplantation following whole-system extraction for device-related staphylococcal endocarditis. Bacterial infection necessitated complete removal of all device and

lead hardware, precluding preservation of central venous access for lead reimplantation, which could only be attempted following completion of 4 weeks of intravenous antibiotics and eradication of infection. Past medical history included nonischemic cardiomyopathy, broad left bundle branch block (QRS duration 180 ms), LV ejection fraction of <20%, previous CRT-D implantation 15 years ago (2005), appropriate defibrillator therapies for ventricular fibrillation, obesity (body mass index 36 kg/m²), and obstructive sleep apnea with domiciliary nocturnal noninvasive ventilation. Medications included bisoprolol 10 mg once daily, eplerenone 25 mg once daily, and sacubitril/valsartan.

The patient provided written consent for the publishing of their anonymized medical information for this case report. The case adhered to the CARE case report guidelines.

CT venography (Figure 1A–C) revealed left subclavian vein and proximal right SCVO with the left subclavian vein draining into an incidental persistent left SVC, which joined the accessory hemiazygos reconstituting at the level of the azygos vein and did not drain into the coronary sinus. The left upper limb therefore drained through the persistent left SVC via a dilated left accessory hemiazygos vein to the right atrium (RA).

Management

SVCO presented a significant challenge to CRT-D reimplantation in this case. Management strategies considered included subcutaneous implantable cardioverter-defibrillator implantation, surgical epicardial lead implantation, and transvenous CRT-D reimplantation via percutaneous venoplasty or thoracoscopic SVC puncture. Following a group consensus decision, transvenous device reimplantation was attempted under general anesthetic by a left infraclavicular approach. The extrathoracic axillary vein was cannulated using a 6F safe sheath by Seldinger technique. A Merit vein selector (Merit Medical, South Jordan, UT), Terumo guidewire (Terumo, Shibuya-ku Tokyo, Japan), and Asahi Sion Blue (0.014") wire (Asahi Intecc, Seto-shi, Aichi, Japan) were used to attempt crossing of the venous occlusion, unsuccessfully.

Contrast venous angiography demonstrated the dilated left accessory hemiazygos vein draining into the distal SVC with

KEYWORDS Accessory hemiazygos vein; Cardiac resynchronization therapy; Chronic heart failure; Superior vena cava occlusion (Heart Rhythm 0² 2021;2:721–723)

Address reprint requests and correspondence: Dr Peter H. Waddingham, EP Cardiology Research, St Bartholomew's Hospital, Barts Health NHS Trust, West Smithfield, London, EC1A 7BE, United Kingdom. E-mail address: p.waddingham@doctors.org.uk.

KEY FINDINGS

- Lead delivery via the persistent left superior vena cava (SVC) and collateralized accessory hemiazygos vein was feasible in the context of right SVC occlusion.
- This transvenous approach was challenging owing to venous tortuosity but avoided more invasive approaches, including cardiac surgical lead placement and vascular intervention.
- Computed tomography venography and venous angiography were key to the planning of this procedure.
- Lead delivery via collateralized venous systems may be feasible in selected cases of central venous stenosis or occlusion.

brisk flow (Figure 1D). Three long J wires were passed into the SVC via the left accessory hemiazygos vein followed by a coronary sinus guide catheter (Abbott 135°). An active fixation lead was then delivered to the right ventricle apex

with difficulty owing to tortuous venous anatomy. An active fixation RA lead was delivered via a 23 cm safe sheath to the inferolateral RA. Acute lead parameters were satisfactory. Epicardial LV lead placement via the coronary sinus was not possible owing to corkscrew venous tortuosity significantly limiting torque and control. Leads were connected to an Abbott Quadra Assura CRT-D (Abbott, Sylmar, CA) with the LV port plugged, placed into a subpectoral pocket with a TYRX antibacterial envelope (Medtronic, Minneapolis, MN). Figure 1F displays a posteroanterior chest radiograph showing the final lead positions. The patient recovered postprocedure without complication and was subsequently consented for enrollment into the SOLVE CRT study (NCT02922036) to receive a WiSE CRT (EBR Systems, Sunnyvale, CA) endocardial leadless pacing system; however, the implant procedure was delayed owing to the Covid-19 pandemic. Six months following device reimplantation the lead parameters remain stable.

Discussion

This report describes the first published case of lead delivery via a persistent left SVC and collateralized accessory

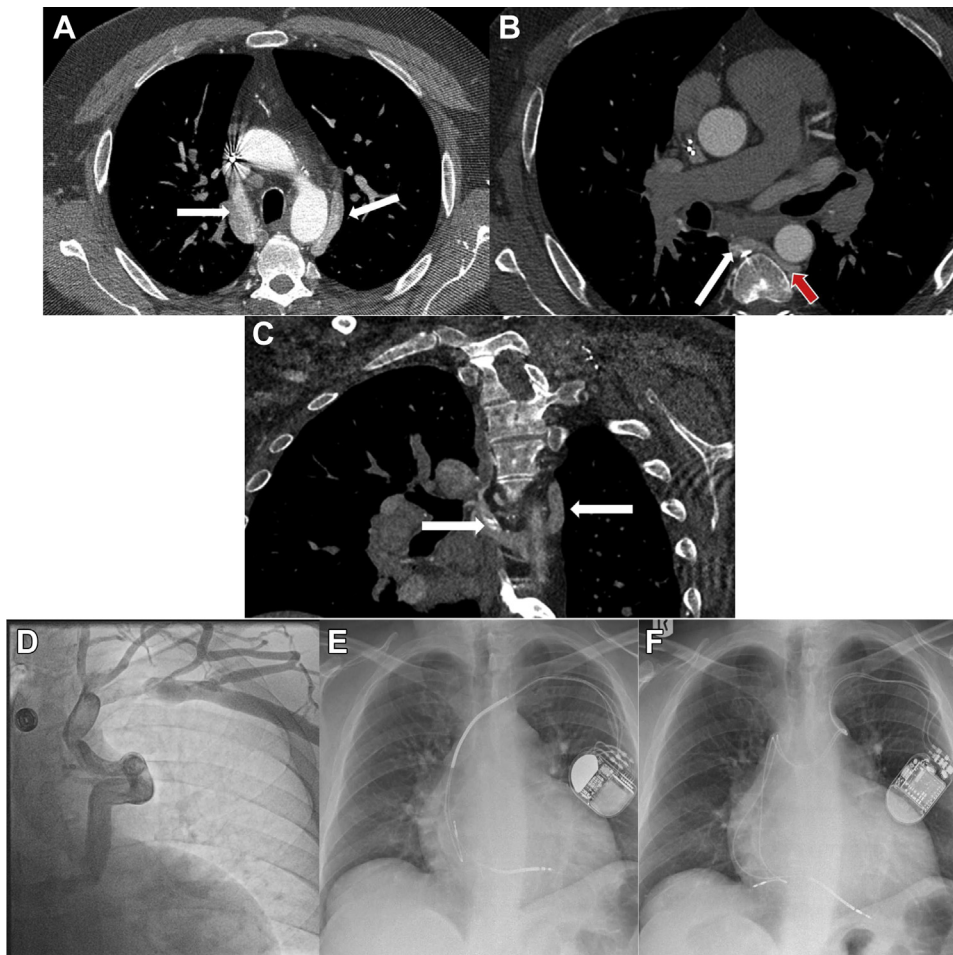


Figure 1 A: Axial contrast-enhanced computed tomography (CT) showing bilateral superior vena cava (SVC) (white arrows). B: Left SVC draining into accessory hemiazygos (red arrow) to azygos vein (white arrow). C: Coronal contrast-enhanced CT with bilateral SVC (white arrows). D: Venous angiography demonstrating collateralization and drainage of the left upper limb via the accessory hemiazygos vein. E: Chest radiograph (posteroanterior projection) showing lead positions prior to whole-system extraction. F: Final lead positions following reimplantation via accessory hemiazygos vein.

hemiazygos vein in a patient with right SVCO. Infection necessitated extraction of all hardware, precluding preservation of central venous access. This lead delivery strategy avoided high-risk vascular or surgical intervention; however, long-term durability and future risks of progressive venous occlusion are unknown. Additional complexity may be associated with this lead delivery strategy, and it was not possible to access the coronary sinus owing to the complex venous tortuosity.

The consequences of progressive venous stenosis or occlusion of the accessory hemiazygos vein are unknown; also, should the patient develop a future indication for further transvenous lead extraction, the procedure would be complex and high risk. These factors should be discussed openly with the patient during procedural planning and consent.

Case reports exist describing the use of azygos and hemiazygos veins to modify shocking vectors at defibrillation threshold testing, typically in right-sided implantable cardioverter-defibrillators.^{6–10} Two published case reports describe the use of mini-thoracotomy and percutaneous approach to access the azygos vein for lead placement in SVCO from the right side.^{11,12} In the context of SVCO, the azygos/hemiazygos route may provide alternate routes of lead delivery, as described in this case.

Conclusion

Lead delivery via the persistent left SVC and collateralized accessory hemiazygos vein was feasible in the context of right SVCO. This avoided the need for more invasive approaches, including cardiac surgery. CT venography and venous angiography were key to the planning of this procedure. Lead delivery via collateralized venous systems may be feasible in selected cases of SVCO.

Funding Sources

This research did not receive any specific grant from funding agencies in the public, commercial, or not-for-profit sectors.

Disclosures

The authors have no conflicts to disclose.

Authorship

All authors attest they meet the current ICMJE criteria for authorship.

Patient Consent

The patient provided written consent for publication of their anonymized medical information for this case report.

Ethics Statement

The case adhered to the CARE case report guidelines.

References

1. Morani G, Bolzan B, Valsecchi S, Morosato M, Ribichini FL. Chronic venous obstruction during cardiac device revision: incidence, predictors, and efficacy of percutaneous techniques to overcome the stenosis. *Heart Rhythm* 2020; 17:258–264.
2. Lickfett L, Bitzen A, Arepally A, et al. Incidence of venous obstruction following insertion of an implantable cardioverter defibrillator. A study of systematic contrast venography on patients presenting for their first elective ICD generator replacement. *Europace* 2004;6:25–31.
3. Abu-El-Haija B, Bhavne PD, Campbell DN, et al. Venous stenosis after transvenous lead placement: a study of outcomes and risk factors in 212 consecutive patients. *J Am Heart Assoc* 2015;4:e001878.
4. Gasparini M, Mantica M, Galimberti P, et al. Biventricular pacing via a persistent left superior vena cava: report of four cases. *Pacing Clin Electrophysiol* 2003; 26:192–196.
5. Biffi M, Boriani G, Frabetti L, Bronzetti G, Branzi A. Left superior vena cava persistence in patients undergoing pacemaker or cardioverter-defibrillator implantation: a 10-year experience. *Chest* 2001;120:139–144.
6. Moran DP, Bhutta U, Yearoo I, Keelan E, O'Neill J, Galvin J. Case report of an anomalous single azygos venous coil insertion to reduce the defibrillation threshold in a patient with a right-sided deltopectoral ICD implant. *Heart Asia* 2013;5:28–29.
7. Dayer MJ, Allen J, Jeavons C. Implantation of an azygos vein coil to facilitate defibrillation. *Heart* 2012;98:519.
8. Cooper JA, Latacha MP, Soto GE, et al. The azygos defibrillator lead for elevated defibrillation thresholds: implant technique, lead stability, and patient series. *Pacing Clin Electrophysiol* 2008;31:1405–1410.
9. Cesario D, Bhargava M, Valderrábano M, Fonarow GC, Wilkoff B, Shivkumar K. Azygos vein lead implantation: a novel adjunctive technique for implantable cardioverter defibrillator placement. *J Cardiovasc Electrophysiol* 2004;15:780–783.
10. Nilsson KR, Jackson KP. Hemiazygos coil placement for high-defibrillation thresholds in a patient with a right-sided implantable cardioverter defibrillator. *Pacing Clin Electrophysiol* 2012;35:e10–e12.
11. Goktekin O, Besoglu Y, Dogan SM, et al. Permanent pacemaker lead implantation via azygos vein in a patient with silent superior vena cava syndrome. *Int J Cardiol* 2007;117:e4–e6.
12. Kamdar RH, Schilling RJ. Percutaneous permanent pacemaker implantation via the azygos vein in a patient with superior vena cava occlusion. *Pacing Clin Electrophysiol* 2008;31:386–388.