

Received: 2017.11.30  
Accepted: 2018.02.20  
Published: 2018.04.23

e-ISSN 1941-5923  
© Am J Case Rep, 2018; 19: 478-481  
DOI: 10.12659/AJCR.908317

## Lipid-Rich Variant of Urothelial Carcinoma Presenting as the Dominant Morphology in a Recurrent Tumor After Local Therapy

Authors' Contribution:  
Study Design A  
Data Collection B  
Statistical Analysis C  
Data Interpretation D  
Manuscript Preparation E  
Literature Search F  
Funds Collection G

ABE 1 **Archi Patel**  
EF 2 **Rowena E. Velilla**  
AF 1 **Muhammad Salah Shurbaji**

1 Department of Pathology, East Tennessee State University, Johnson City, TN, U.S.A.  
2 Department of Pathology, James H. Quillen Veterans Affairs Medical Center, Johnson City, TN, U.S.A.

**Corresponding Author:**  
**Conflict of interest:**

This work was presented in part at the College of American Pathologists 2017 Annual Meeting  
Archi Patel, e-mail: [patela4@etsu.edu](mailto:patela4@etsu.edu)  
None declared

**Patient:** Male, 61  
**Final Diagnosis:** Urothelial carcinoma • lipid-rich variant • metastatic  
**Symptoms:** Hematuria  
**Medication:** —  
**Clinical Procedure:** Transurethral resection of bladder tumour (TURBT)  
**Specialty:** Urology

**Objective:** Rare co-existence of disease or pathology





**Background:** The lipid-rich variant is a rare and aggressive type of urothelial carcinoma (UCA), with less than 40 cases reported in the literature. This variant usually presents as an advanced-stage primary tumor.

**Case Report:** We report the case of a 61-year-old man with previous history of T1 high-grade conventional urothelial carcinoma treated with local therapy. The patient later presented with a new 6.5-cm exophytic bladder mass. Histopathological examination revealed a T2 urothelial carcinoma of the lipid-rich variant. Retrospective review of the previous biopsies confirmed conventional high-grade urothelial carcinoma, but scattered rare individual or small clusters of cells that resemble the lipid-rich variant urothelial carcinoma were also noted.

**Conclusions:** The findings in this case suggest that the differential sensitivity of conventional urothelial carcinoma to local therapy may have allowed the lipid-rich variant to predominate in the recurrence. Pathologists should be aware of the lipid-rich variant of urothelial carcinoma. The prognostic significance of rare lipoblast-like cells among predominantly conventional urothelial carcinoma may requires further study.

**MeSH Keywords:** Carcinoma • Urinary Bladder Diseases • Urothelium

**Full-text PDF:** <https://www.amjcaserep.com/abstract/index/idArt/908317>

 888  —  5  4



## Background

In 2017, it is estimated that there will be 79 030 new cases of bladder cancer diagnosed in the USA that result in an estimated toll of 16 870 patient deaths [1]. The most common type of bladder cancer is urothelial carcinoma (UCa), which accounts for approximately 90% of urinary bladder tumors. Nearly 75% of patients with newly diagnosed bladder cancer present with non-invasive or early invasive (nonmuscularis propria-invasive) disease (stage Ta, Tis, or T1). With these tumors, recurrence is common (occurring in 50–70% of cases), but progression occurs in only 15–25% of cases [2]. Clinical and pathologic prognostic factors that contribute to the risks of recurrence and progression include the number of tumors, tumor size, prior recurrence, T-stage, concurrent flat carcinoma *in-situ* (CIS), and tumor grade [3].

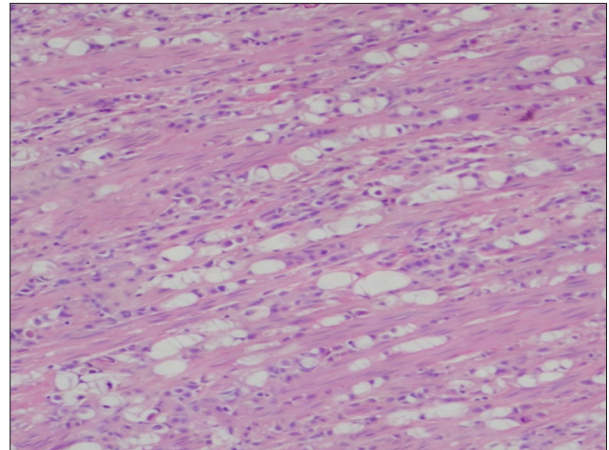
Urothelial carcinoma is known to have a remarkable propensity for divergent differentiation, and there are many described histologic variants of infiltrating urothelial carcinoma, some better characterized than others. Some histologic variants of UCa have been associated with poor outcomes or lack of response to therapy. For example, micropapillary urothelial carcinoma is often muscle-invasive at diagnosis, and the amount of micropapillary morphology present may be correlated with outcomes. Moreover, nested urothelial carcinoma often shows muscle invasion at diagnosis and shows associated aggressive behavior. Plasmacytoid urothelial carcinoma and sarcomatoid urothelial carcinoma are also associated with advanced cancer stage and increased risk of death [2].

Lipid-rich urothelial carcinoma is a rare variant, with fewer than 40 cases reported to date [2]. It is characterized by the presence of large lipoblast-like cells with 1 or more clear cytoplasmic vacuoles that indent the nucleus. The lipid-rich morphology usually constitutes 10–50% of the tumor, admixed with conventional or other variants of urothelial carcinoma [2]. Although not yet well-characterized, lipid-rich morphology appears to be correlated with poor prognosis. A multiinstitutional study of 27 patients showed that 60% died of the disease within 58 months [4].

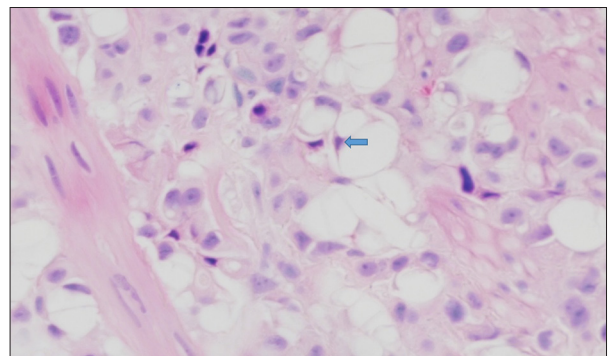
## Case Report

We report the case of a 61-year-old man with previous history of 2 episodes of T1 high-grade conventional urothelial carcinoma that was previously treated with local therapy presented (11 months after the most recent recurrence and 23 months from the original diagnosis), with a new 6.5-cm exophytic bladder mass. A trans-urethral resection was performed.

Histopathological examination revealed a tumor composed predominantly of cords, single cells, and sheets of tumor cells



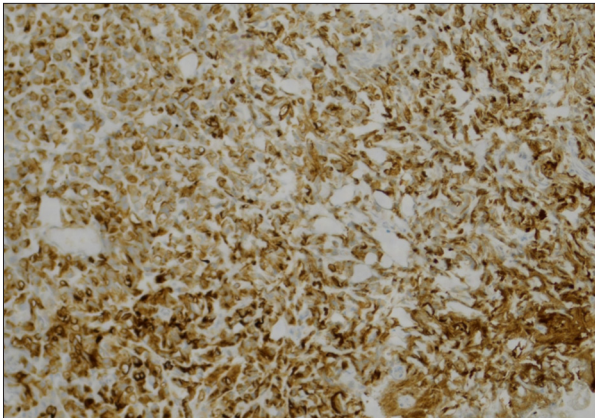
**Figure 1.** Invasive Lipid-Rich Urothelial Carcinoma: Tumor composed predominantly of cords, single cells, and sheets of tumor cells with hyperchromatic and eccentric nuclei invading to muscularis propria (H&E 100).



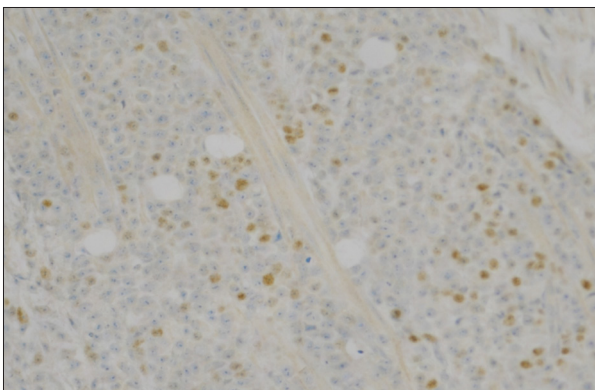
**Figure 2.** Lipid-Rich Urothelial Carcinoma: This figure shows cells with vacuolated cytoplasm and indented nucleus (arrow).

with hyperchromatic and eccentric nuclei invading to the muscularis propria (Figure 1). Many cells had an abundant vacuolated cytoplasm that indented the nucleus (Figure 2), while others were more typical of conventional urothelial carcinoma. The tumor invaded the muscularis propria (T2). On immunohistochemical staining, the tumor cells were strongly and diffusely positive for high molecular weight cytokeratin (34 $\beta$ E12) (Figure 3), and focally positive for p63 (Figure 4). Tumor cells were negative for PSA and mucicarmine. The diagnosis of the lipid-rich variant of urothelial carcinoma was made.

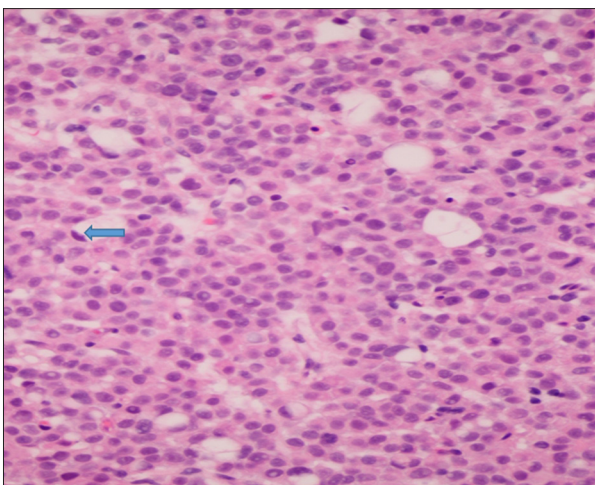
Retrospective review of the original biopsies confirmed conventional high-grade urothelial carcinoma, but on careful examination and with the benefit of hind-sight, we also noted scattered rare individual cells or small clusters of cells that resemble the lipid-rich variant urothelial carcinoma (Figure 5), which are easily overlooked. Similar findings were seen on the first recurrent tumor.



**Figure 3.** Immunohistochemical stain using 34βE12 antibody shows the tumor cells were strongly and diffusely positive for high molecular weight cytokeratin (×100).



**Figure 4.** Tumor cells showing nuclear reactivity with immunohistochemical stain for P63 (×100).



**Figure 5.** Invasive Urothelial Carcinoma: The patient's previous tumor shows few cells with abundant vacuolated cytoplasm and indented nucleus (arrow) among a majority of typical high-grade urothelial carcinoma cells.

After a few months, even with local and systemic chemotherapy treatment, the patient developed metastasis of urothelial carcinoma to bone, which is a course consistent with this aggressive variant.

## Discussion

The limited experience with the lipid cell variant of urothelial carcinoma suggests that it is associated with poor prognosis [2,4]. Since many authors suggest that even T1 high-grade urothelial carcinoma of the aggressive variants may benefit from early cystectomy, because of their tendency for rapid progression, and for resistance to local therapy [3], it becomes even more important to recognize this variant and to report its existence. The lipid cell population in these tumors reportedly varies from 10% to 50% of the tumor cells, with the remainder made up of conventional urothelial carcinoma or another recognized variant. Towards the lower end of this spectrum, these cells may be overlooked.

In this case report, the retrospective review of the previous biopsies confirmed the diagnosis of T1 conventional high-grade urothelial carcinoma, but upon careful examination we also noted scattered, rare (much less than 10%) individual or small clusters of cells that resemble the lipid-rich variant urothelial carcinoma, which are easily overlooked. The significance of finding such scattered cells is unknown, but at least this single patient's presentation leads us to speculate that their presence may be clinically significant. The fact that this patient's T1 disease was not responsive to local therapy and that his tumor eventually recurred as an advanced-stage (T2) tumor with frank lipid cell variant morphology suggests that perhaps local therapy had even selected for this more aggressive clone.

## Conclusions

The diagnosis of the lipid cell variant of urothelial carcinoma can be difficult to establish, especially in a small sample. The differential diagnosis includes signet-ring carcinoma and liposarcoma (primary, secondary, or part of sarcomatoid urothelial carcinoma with heterologous differentiation). Being aware of this rare variant and its histopathologic and immunohistochemical features is essential to making an accurate diagnosis. This case suggests that the presence of rare lipoblast-like cells among predominantly conventional urothelial carcinoma may be a poor prognostic indicator. Additional studies may be needed to establish the significance of this finding.

## Conflicts of interest

None.

## References:

---

1. Siegel RL, Miller KD, Jemal A: Cancer Statistics, 2017. *Cancer J Clin*, 2017; 67(1): 7–30
2. Lopez-Beltran A, Sauter G, Gasser T et al: Infiltrating urothelial carcinoma. In: Eble JN, Sauter G, Epstein JI, Sesterhenn I (eds.), *World Health Organization classification of tumors. Pathology and genetics of tumors of the urinary system and male genital organs*. Lyon: IARC Press; 2004; 93–109
3. Harshman LC, Preston MA, Bellmunt J, Beard C: Diagnosis of bladder carcinoma: A clinician's perspective. *Surg Pathol Clin*, 2015; 8(4): 677–85
4. Lopez-Beltran A, Amin MA, Oliveira PS et al: Urothelial carcinoma of the bladder, lipid cell variant: clinicopathologic findings and LOH analysis. *Am J Surg Pathol*, 2010; 34(3): 371–76