



**Review Article**

## **Lymphoproliferative Syndromes Associated with Human Herpesvirus-6A and Human Herpesvirus-6B**

Eva Eliassen<sup>1\*</sup>, Gerhard Krueger<sup>2</sup>, Mario Luppi<sup>3</sup> and Dharam Ablashi<sup>1</sup>.

<sup>1</sup> HHV-6 Foundation, Santa Barbara, California, USA.

<sup>2</sup> Department of Pathology and Laboratory Medicine, University of Texas, Houston, Texas, USA.

<sup>3</sup> Department of Medical and Surgical Sciences, University of Modena and Reggio Emilia, Modena, Italy.

**Competing interests:** The authors have declared that no competing interests exist.

**Abstract.** Human herpesvirus 6A and 6B (HHV-6A and HHV-6B) have been noted since their discovery for their T-lymphotropism. Although it has proven difficult to determine the extent to which HHV-6A and HHV-6B are involved in the pathogenesis of many diseases, evidence suggests that primary infection and reactivation of both viruses may induce or contribute to the progression of several lymphoproliferative disorders, ranging from benign to malignant and including infectious mononucleosis-like illness, drug induced hypersensitivity syndrome/drug reaction with eosinophilia and systemic symptoms (DIHS/DRESS), and nodular sclerosis Hodgkin's lymphoma. Herein, we discuss the conditions associated with the lymphoproliferative capacity of HHV-6, as well as the potential mechanisms behind them. Continued exploration on this topic may add to our understanding of the interactions between HHV-6 and the immune system and may open the doors to more accurate diagnosis and treatment of certain lymphoproliferative disorders.

**Keywords:** Human herpesvirus; HHV-6A; HHV-6B; Lymphoproliferative Disease.

**Citation:** Eliassen E., Krueger G., Luppi M., Ablashi D. Lymphoproliferative syndromes associated with human herpesvirus-6A and human herpesvirus-6B. *Mediterr J Hematol Infect Dis* 2018, 10(1): e2018035, DOI: <http://dx.doi.org/10.4084/MJHID.2018.035>

**Published:** May 1, 2018

**Received:** April 24, 2018

**Accepted:** April 26, 2018

This is an Open Access article distributed under the terms of the Creative Commons Attribution License (<https://creativecommons.org/licenses/by-nc/4.0>), which permits unrestricted use, distribution, and reproduction in any medium, provided the original work is properly cited.

Correspondence to: Eva Eliassen. HHV-6 Foundation, 1482 East Valley Road, Suite 619, Santa Barbara, CA 93108, USA. Tel: +1-561-926-8564. E-mail: [eva@hhv-6foundation.org](mailto:eva@hhv-6foundation.org)

**Introduction.** Human herpesvirus 6A and 6B (HHV-6A and HHV-6B), collectively known as HHV-6, are a pair of closely related betaherpesviruses of the genus Roseolovirus with lymphocytic tropism and immunomodulatory capabilities.<sup>1,2,3</sup> HHV-6A was discovered in the peripheral blood mononuclear cells (PBMCs) of patients with AIDS-related lymphomas and other lymphoproliferative disorders in the latter part of the 1980s, and its T cell tropism was established in short order.<sup>1,4-6</sup> Early investigations found that the available HHV-6 isolates could be split into two distinct variants, with HHV-6 Type A

preferentially infecting immature T cells and Type B infecting mature T cells.<sup>2,7</sup> These initial findings were followed by detection of HHV-6 antigen and DNA in the lymph nodes of patients with lymphoproliferative disorders and autopsy specimens,<sup>8-12</sup> and a possible role for HHV-6 in lymphomas was examined, with some compelling results but no consensus.<sup>13-15</sup> Although the virus has been implicated in a range of lymphoproliferative disorders, efforts are still underway to elucidate the pathogenic roles of HHV-6 in these conditions. The ubiquitous nature of the virus was recognized early on as a challenge

in identifying its role in the disorders in which it has been implicated, as its DNA can be found in the peripheral blood of healthy donors and low level reactivation may occur without clinical manifestations. Consequently, serological studies serve primarily to screen patients for HHV-6 infection, while the most conclusive results are gained through the use of quantitative PCR, staining techniques applied to tissue samples, and through comparison with carefully selected controls. With the technical advancements and growing understanding of the effects of HHV-6 on the immune response, investigators are continuing to learn about the potential for HHV-6 to trigger lymphoproliferative disorders and the possible mechanisms behind it.

**Interactions between HHV-6 and the Immune System.** HHV-6A and B infect hematopoietic stem cells (CD34+, CD32+), cord blood cells, and several immune cell populations *in vitro* and *in vivo*, including T lymphocytes, NK cells,<sup>16</sup> monocytes and macrophages,<sup>17,18</sup> and dendritic cells,<sup>19</sup> and HHV-6A has also been found to infect EBV-immortalized B cells.<sup>20</sup> However, as the two species utilize different cellular receptors and impact chemokine/cytokine signaling in different ways, their tropism differs. This matter is further complicated as the presence of cellular receptors for HHV-6 does not guarantee infection of such cells in tissues.<sup>21</sup> Viral DNA is found in 9-25% of peripheral blood mononuclear cells (PBMCs) from healthy donors,<sup>13,22</sup> and HHV-6B is found more frequently than HHV-6A, which has been detected in the PBMCs of 3-10% of healthy individuals.<sup>13</sup> In most healthy adults, a T cell response to HHV-6 is present,<sup>23</sup> but fewer than 0.12% of CD4+ T cells in PBMC samples are reactive to HHV-6,<sup>24</sup> and fewer than 1 in 10<sup>5</sup> CD8+ T cells in PBMCs are HHV-6-specific.<sup>25</sup> Reactivation of HHV-6 occurs during T cell activation by various stimuli, including endotoxins, endocrine stimulation, certain cytokines, and food components (e.g. agglutinins, phorbol esters etc.). Immunosuppressive conditions, including those involving stress, transient immunosuppression, and/or stimulation resulting from infection with other viruses such as measles virus, support the persistent activity of HHV-6 once reactivated. Similar to EBV infections, persistent HHV-6 activity can also be found after organ and hematopoietic stem cell transplantation.

As our understanding of HHV-6A and B has grown, their immunomodulatory activities have emerged as key contributors to many of the clinical manifestations linked to HHV-6 infection. HHV-6 infection is most commonly associated with exanthema subitum (roseola infantum),<sup>26</sup> a manifestation of primary infection that occurs during early childhood. Intense reactivation of the virus is frequently observed in the transplantation setting, resulting in a host of complications post-solid organ and hematopoietic stem cell transplantation (HSCT). These conditions, as well as others associated with HHV-6 infection and reactivation, are often mediated to a great extent by the immune response to the virus and by the effects of the virus on various immune cell populations and cytokine/chemokine expression. The influences exerted by HHV-6A/HHV-6B differ by species, but both trigger inflammatory reactions while also employing mechanisms by which they can suppress an immune response and avoid detection.

*In vitro* experimentation has demonstrated that HHV-6B and HHV-6A induce myelosuppression,<sup>27,28</sup> infection of T cells and PBMCs inhibit immune responses against a tuberculin protein derivative or mumps antigen,<sup>29</sup> and infection of PBMCs results in reduced IL-2 mRNA and protein synthesis- 50% less than mock-infected cells- sharply reducing cellular proliferation and indicating that the functions of T cells are suppressed.<sup>30</sup> In the clinical setting, thymic atrophy and severe T lymphocytopenia have been reported,<sup>31-33</sup> and in transplant recipients, delayed engraftment, myelosuppression,<sup>34</sup> and graft failure<sup>35</sup> have been known to occur in response to active HHV-6. An inverse correlation has been identified between reconstitution of CD4+ cells after HSCT and reactivation of HHV-6,<sup>36</sup> as well as CD3+ cells<sup>37</sup> and CD8+ cells,<sup>38</sup> and indeed, proliferation of lymphocytes has been inhibited by persistent HHV-6 infections after allo-HSCT.<sup>39</sup> However, transplantation of cord blood, which is associated with a higher risk of HHV-6 reactivation and higher HHV-6 DNAemia<sup>40</sup> compared to transplantation of other sources of hematopoietic stem cells, have also been found to have faster reconstitution of B lymphocytes with higher B cell counts, a phenomenon that has been hypothesized to arise as a result of an immune response against viral reactivation.<sup>40</sup> As immune suppression

enables HHV-6 to better avoid detection and clearance, this phenomenon is advantageous for the persistence of the virus, but proliferation of infected lymphocytes may also be beneficial for its dissemination. Accordingly, immune suppression and immune activation are but two sides of the same coin during HHV-6 infection. When either suppression or proliferation is unchecked, severe clinical manifestations may result.

Both HHV-6A and HHV-6B are able to affect chemokine/cytokine pathways, which are dysregulated in lymphoproliferative disorders. Infection by either virus impairs production of IL-12 in macrophages<sup>41</sup> and in dendritic cells,<sup>42</sup> which may allow the viruses to suppress activation of cytotoxic effectors. In combination with lower IL-2 expression,<sup>30</sup> TNF-alpha, IL-1beta, IL-8, and IL-15 have been found to be upregulated,<sup>43,44,45</sup> coinciding with a shift from a Th1 to Th2 cytokine profile. HHV-6A infection of astrocytes in patients with glioma has been associated with significantly upregulated TGF-beta, IL-6, and IL-8,<sup>46</sup> and *in vitro*, HHV-6B infection of astrocytes has increased production of the proinflammatory cytokines IL-6 and IL-1beta.<sup>47</sup> Notably, cytokine expression patterns vary temporally and in relation to the infected cell's environment. IL-10, IL-11, and other anti-inflammatory mediators, for example, are expressed at high levels after exposing HHV-6 infected astrocytes to proinflammatory cytokines.<sup>48</sup>

Viral proteins are also integral to HHV-6-mediated immunomodulation. The HHV-6B encoded chemokine U83B induces chemotaxis and activation of leukocytes expressing CCR2, which is expressed under proinflammatory conditions.<sup>49</sup> Similarly, endometrial epithelial cells infected with HHV-6A have shown increased cell surface expression of CCL2, IP-10, and CCL26.<sup>50</sup> On the other hand, the U83A chemokine (HHV-6A-specific), as well as the U51A chemokine receptor, target CCR5/CCL5 (RANTES),<sup>51</sup> another receptor/ligand pair involved in inflammation, resulting in down-modulation of their activity. U51A also binds four other inflammatory modulating chemokines that bind to and stimulate several immune cell populations, including B and T lymphocytes- CCL2, CCL7, CCL11, and CCL13- and the inflammatory cells expressing the U51A receptor exhibit chemotaxis toward, and internalization of, target chemokines.<sup>52</sup> In contrast,

primary HHV-6B infection results in upregulation of CCL2, CXCL11, CXCL10, and CXCL16.<sup>53</sup>

Another mechanism by which the pair of viruses affect their host cells is the alteration of cell membrane fluidity and the dysregulation of cellular receptors.<sup>54,55</sup> Both species downregulate MHC class I<sup>56,57</sup> and CD46, which may result in activation of autologous complement and cellular damage in lymphoid tissue and beyond,<sup>58</sup> and HHV-6A impairs expression of the T cell receptor/CD3 complex at the cell membrane, rendering the affected cells ineffective in responding to antigen-presenting cells.<sup>4,59,60</sup> In addition, HHV-6A triggers expression of CD4 mRNA and protein production in CD4 negative NK<sup>16</sup> and T cells<sup>61</sup> and can reduce the cytotoxicity of CD4+ T cells.<sup>62</sup> Both species interact with toll-like receptors and may exert their effects on cytokine/chemokine expression and the Th1/Th2 balance through them.<sup>63-67</sup>

### **Benign/Reactive Lymphoproliferative**

**Disorders.** Primary HHV-6B infection was identified as a causative agent of exanthema subitum (roseola infantum) in 1988, when the onset of the illness was linked to HHV-6 seroconversion, and the presence of viral antigen was observed in patients' lymphocytes.<sup>26</sup> In some cases observed by Krueger *et al.*, exanthema subitum was also seen during primary HHV-6A infection.<sup>68</sup> In addition to the characteristic rash, fever, and occasionally febrile seizures and encephalitis,<sup>69,70</sup> children with exanthema subitum can experience lymphadenopathy, relative lymphocytosis with increased CD38+ (immature) T cells, and hepatomegaly.<sup>69,71,72</sup>

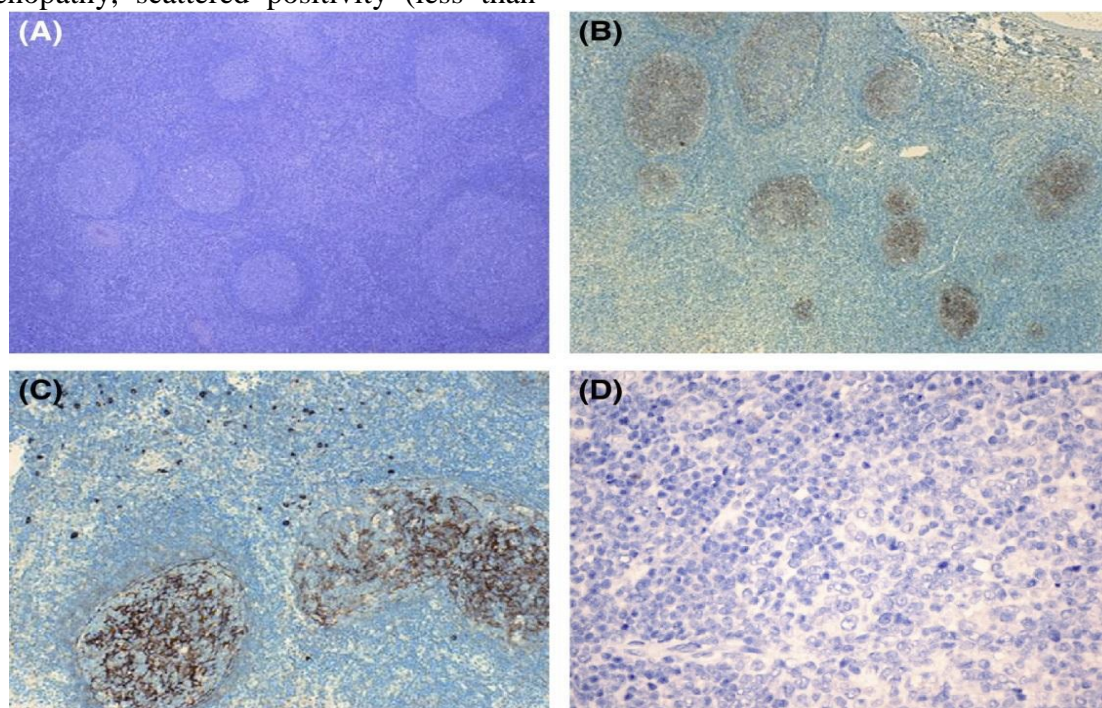
Thrombocytopenia, neutropenia, and leukopenia are commonly found as well.<sup>73</sup> Notably, reactive "atypical" lymphocytes and hemophagocytosis may be observed in bone marrow,<sup>74,75</sup> and a mononucleosis-like illness, with reactive lymphocytosis and liver dysfunction, has been described.<sup>76</sup> Two unique cases documenting HHV-6 infection with unusual lymphoproliferation in very young children have been reported: One infant, 7 months old, died suddenly after developing otitis media, and HHV-6 was found by PCR in tissue samples and in atypical lymphoid infiltrate via ISH.<sup>77</sup> Abnormal, inflammatory lymphocytic infiltration was present in the liver, kidney, heart, spleen, bone marrow, and lymph nodes of the child, and interstitial pneumonitis was



reported. In the other case, a 2-week-old with HHV-6 DNA present in PBMCs, and who perhaps had congenital HHV-6, developed bone marrow cell proliferation, hypersensitivity to granulocyte-macrophage colony-stimulating factor (GM-CSF), hepatosplenomegaly, and was thought to have juvenile myelomonocytic leukemia. However, the symptoms resolved.<sup>78</sup> Generally, lymphoproliferative responses during primary infection are limited in scope and resolve without issue.

After primary infection, HHV-6A and HHV-6B remain latent in many organs, including the heart, lungs, gastrointestinal tract, and the brain, in addition to circulating lymphocytes. In immunocompetent individuals, low level reactivation may occur without major clinical symptoms. In those with immune deficiencies,<sup>79</sup> incomplete clearance and persistent activation cause various clinical diseases (e.g. post-transplant syndromes, autoimmune disorders etc.) During persistent or frequently recurrent reactivation in immune deficient persons (which is usually the case in studying adult patients), the virus has been associated with generalized reactive lymphadenopathy lasting for several days to several weeks.<sup>80-84</sup> Among patients with reactive lymphadenopathy, scattered positivity (less than

1% of total cells) when staining for the HHV-6 antigens p101K, gp106, and gp116, has been observed among cells, namely plasma cells and histiocytes, from lymph node biopsies.<sup>85</sup> The virus has been detected by PCR in PBMCs at a higher prevalence among patients with lymphoproliferative disorders than in healthy volunteers,<sup>86</sup> and in Brazilian patients with lymphadenopathy and fever (but without skin rash), 8.7% had active HHV-6 infection (plasma viremia).<sup>87</sup> While these results indicate that HHV-6 may contribute to reactive lymphadenopathy, they may not implicate HHV-6 as the sole virus involved in its development, as it is difficult to rule out its reactivation in response to a different underlying cause of lymphadenopathy, including infections by other viruses. However, strong evidence of a role for HHV-6 in chronic/recurrent lymphadenopathy, backed by immunohistochemical staining- a more specific technique- has been reported. Of 111 cases of benign/reactive lymphadenopathies with unknown etiology in a recent study, 7 (6.3%) demonstrated recurrent/chronic behavior, and intense staining for HHV-6B was detected in follicular dendritic cells in all cases (**Figure 1**).<sup>88</sup>



**Figure 1. HHV-6B in chronic/recurrent benign lymphadenopathy. (A–D) Histological and immunohistochemical examinations on lymph node tissues.** Retained normal lymph node architecture with follicular hyperplasia and concurrent mild paracortical expansion was documented on haematoxylin/eosin staining. The lymph node follicles were enlarged and numerous. There was considerable variation in the size and shape of the follicles. Most of them retained a round to oval structure, without coalescence and with a conserved mantle zone surrounding the enlarged follicles (A, magnification  $\times 100$ ). An intense immunopositive staining with HHV-6B-specific p101K antibody was demonstrated in follicular dendritic cells (FDCs) of germinal centers in the majority of hyperplastic follicles, concurrently with scattered positivity of interfollicular cells [magnification  $\times 100$  (B),  $\times 200$  (C)]. Immunohistochemical reaction for HHV-6A (early antigen p41/38) was invariably negative on lymph node tissues (D, magnification  $\times 400$ ) (Forghieri et al. 2016).<sup>88</sup>

In contrast, only three non-recurrent/chronic cases showed staining for HHV-6B in germinal centers of follicular dendritic cells, and 7 others showed scattered positivity in cells of interfollicular areas. Control lymph node tissues (n=134), which were obtained from patients with benign lymphadenopathy with known etiology-including other infections, solid cancer without metastasis, sarcoidosis, Kikuchi-Fujimoto disease, Wegener granulomatosis, dermatopathic lymphadenopathy, and unspecified autoimmune disorders- or malignant tumors, were negative for HHV-6. While recurrent or chronic activity is not usually observed in reactive/benign conditions, it is more commonly found in atypical or malignant disorders.<sup>89</sup> Although atypical lymphocytosis was not observed and there were no systemic symptoms, characteristics of abnormal/malignant lymph nodes, including irregular margin and hypoechoic center, were noted among the HHV-6+ patients with chronic/recurrent lymphadenopathy. Taken together, the data suggest that HHV-6 may primarily be involved in prompting benign lymphoproliferative conditions of a certain type, and that the features discussed by Forghieri *et al.* may prove to be useful in differentiating between HHV-6-associated lymphoproliferation and that caused by other agents.<sup>88</sup>

**Rosai-Dorfman Disease.** HHV-6 has been implicated as a trigger for several specific benign/reactive lymphoproliferative disorders, including Rosai-Dorfman (RD) disease. The first report of a possible association between the virus and development of RD described the detection of HHV-6 in involved tissues by ISH in the majority of a small cohort of patients (n=9).<sup>90</sup> HHV-6B DNA was later identified using PCR and Southern blotting in the skin of a patient with RD presenting as giant lesions of granuloma annulare with multiple soft tissue tumors.<sup>91</sup> The patient did not experience spontaneous clearing, which is usually observed for this disease. Notably, the HHV-6 late antigen p101k was detected in the lymph nodes of two RD patients (of two tested) in a pattern similar to that noted in the cases of chronic/recurrent lymphadenopathy described previously.<sup>85,88</sup> In particular, intense staining was noted in follicular dendritic cells of reactive germinal centers in areas of normal lymph node architecture. Moreover,

gp106 staining of many abnormal histiocytes within distended sinuses was observed, with an intense granular positive reaction in the cytoplasm, while weak positivity was observed for both antibodies in few plasma cells. In comparison, the lymph node biopsies from five cases of florid follicular hyperplasia, four cases with a predominantly paracortical lesion, four cases with sinus histiocytosis, and one histiocytic necrotizing lymphadenitis were all HHV-6 positive by PCR, but only isolated plasma cells and histiocytes, most often scattered in interfollicular areas, were positive for late antigens by IHC (<1% of cells in the lymph node).<sup>85</sup> Few granulocytes were positive in the dilated sinuses of 2/4 cases with sinus histiocytosis. HHV-6B late antigen was also found by IHC in the lesion of a young boy with extranodal renal RD, a rare manifestation of the disease.<sup>92</sup> It may be the case that only a subset of RD cases are associated with HHV-6,<sup>93</sup> but the distinctive pattern of late antigen expression, indicating active infection in the follicular dendritic cells of germinal centers argues for the involvement of reactivated HHV-6 in the development of some cases of RD, especially as the pattern was later identified among patients with chronic/recurrent lymphadenopathy.<sup>88</sup>

**Kikuchi-Fujimoto Disease.** Viral etiology has been investigated in Kikuchi-Fujimoto disease (KFD), another self-limited benign disorder. Reactivation of HHV-6 has been determined serologically<sup>94,95</sup> during the course of KFD, and affected lymph nodes have been found to harbor HHV-6 DNA.<sup>94</sup> However, few studies have performed testing for HHV-6, and not all data has supported involvement of the virus. Twenty lymph nodes tested for both EBV and HHV-6, for instance, did not reveal any positivity via PCR.<sup>96</sup> Similarly, only 1/18 lymph node biopsies from another study were HHV-6 positive by PCR- as were 2/18 control lymph nodes from asymptomatic patients with papillary thyroid carcinoma who had not received chemo/radiotherapy, 1 patient with Warthin tumor, and 2 cases of paraganglioma.<sup>97</sup> An earlier study found that the lymph nodes of all but one patient were PCR positive, and all samples tested by ISH were positive as well. On the other hand, the positivity by ISH was not limited to these specimens but was also present in patients with reactive paracortical hyperplasia (60%),

nonspecific lymphadenitis (60%), and tuberculosis lymphadenitis (22.2%).<sup>98</sup> Because it is often difficult to procure tissue samples from healthy persons, it is important to note that HHV-6 could contribute to illnesses affecting controls or may reactivate in response to an illness, which may complicate analysis of the role of HHV-6. This obstacle, as well as variation in assays, carries the potential to skew the interpretation of results.

**Ocular Lymphoproliferation.** Several herpesviruses, including HHV-6, have been isolated from ocular tissue removed from patients with lymphoproliferative disorders. Whereas malignant orbital and conjunctival tissues were infrequently positive for the virus,<sup>99</sup> 23% (mean viral load  $1.7 \times 10^3$  copies/microgram DNA) of samples from IgG4-related ophthalmic disease and 43.9% of samples from reactive lymphoid hyperplasia of the ocular adnexa were HHV-6+. HHV-6A<sup>100</sup> and HHV-6B<sup>101</sup> have been linked to ocular inflammation, perhaps through persistent reactivation and stimulation of immune cells.

#### **Atypical/Unusual Lymphoproliferative Disorders and Lymphocytic Infiltration.**

Atypical lymphoproliferative disorders are characterized by extensive lymphoma-like persistent and/or progressive lymphoproliferation, which, while still polyclonal, may progress to open malignant lymphoma. It may thus be considered a pre-lymphomatous condition.<sup>11</sup> HHV-6 has been cited as a trigger for atypical polyclonal lymphoproliferation,<sup>11,21</sup> although it is more commonly involved in non-neoplastic lymphocytosis with lymphocytes that are often labeled “atypical” but do not show potential for malignant transformation, such as those frequently observed during infectious mononucleosis (IM)-like illnesses. The virus has been detected in reactive CD4+ lymphocytes characteristic of these illnesses,<sup>102</sup> which, though ultimately not malignant, can strongly resemble lymphoma.<sup>103</sup> Specifically, HHV-6 has been localized to CD3+ and CD4+ T cells in the lymph node, characterized by intranuclear eosinophilic viral inclusions and bearing resemblance to lymphocytes present in Hodgkin’s lymphoma and anaplastic large cell lymphoma. Large reactive lymphocytes with a sinusal and paracortical distribution have been found among eosinophils, plasma cells, and scattered immunoblasts.

**Infectious Mononucleosis.** HHV-6 has been implicated in the pathogenesis of a subset of infectious mononucleosis (IM)-like illnesses, as indicated by serologic evidence of active infection and increased HHV-6 specific IgG titers in the absence of active EBV or CMV infection.<sup>10,104-106</sup> Coinfections of HHV-6 and EBV also occur during IM and could exacerbate the symptoms/disease course.<sup>10</sup> While the absolute prevalence is unclear, HHV-6 was specified as the etiological agent in 5% of 40 adults with IM-like illnesses in Japan, after PCR analysis.<sup>107,108</sup> As is often the case during EBV-mediated IM, HHV-6-associated IM-like conditions have been associated with fatigue, lymphocytosis, thrombocytosis, migrating lymphadenopathy, headaches, fever, maculopapular rash, and hepatosplenomegaly with raised liver enzymes, increased immature lymphoid cells, PBMC death,<sup>109-111</sup> and “atypical” T lymphocytosis coinciding with HHV-6 antigen expression.<sup>111</sup> The effects of reactivation may persist even after resolution of active infection; in patients with active HHV-6A and IM, the viral DNA load in blood peaks within 4 weeks and returns to normal by 16 weeks, while prolonged T lymphocytosis decreases to normal levels by 24-28 weeks.<sup>112</sup>

HHV-6B and untyped HHV-6 DNA has been detected in the serum, lymph nodes, and CD4+ T cells of skin tissue characterized by “atypical” infiltrating CD4+ and CD8+ T cells, by PCR, IHC, Southern blot, and ISH.<sup>113-115</sup> Examination of lymph node tissue revealed transformed lymphocytes and immunoblast-like cells, some of which were positive for HHV-6, in addition to some histiocytes and eosinophils. Of interest, instances of HHV-6-associated IM have been significantly associated with Downey type III lymphocytes (i.e. monocytoid blasts with basophilic cytoplasmic granules,<sup>108,116</sup> and it appears that this type of IM may present with certain manifestations relatively unique to HHV-6.

The resulting lymphoproliferation observed during HHV-6-associated IM-like illnesses has been posited to stem from a response by CD8+ T cells against HHV-6-infected CD4+ T cells;<sup>113</sup> analysis of the PBMC composition has identified 35.7% of cells as CD4+ and 52.6% as CD8+. HHV-6-specific T cells consist of CD4+ and CD8+ cells, but in patients with acute HHV-6 infection, CD8+ cells may predominate for several



months after an initial spike in the CD4+/CD8+ ratio.<sup>88,117</sup> Taking into consideration the time-dependent nature of these changes in cellular populations, computer models have illustrated that acute HHV-6 infection can raise the CD4+/CD8+ T cell ratio initially, but there is a subsequent sharp decrease as CD4+ cells are removed and CD8+ cells proliferate.<sup>117</sup> Once HHV-6 has infected lymphocytes, the maturation and function of the cells are altered. During acute infection, this may manifest as an infectious mononucleosis-like illness, while during chronic persistent infection, chronic fatigue-type cellular changes have been observed, as has persistent immature lymphocytosis similar to that seen in Canale-Smith syndrome.<sup>118</sup>

*Hemophagocytic Syndrome/Hemophagocytic Lymphohistiocytosis.* Hemophagocytic syndrome/hemophagocytic lymphohistiocytosis (HLH), a hyperinflammatory disease marked by activation of T lymphocytes and macrophages and driven by overproduction of cytokines, may result from infection by herpesviruses, including EBV, CMV, and HHV-6, and at times, more than one virus.<sup>119,120</sup> Systemic manifestations during HHV-6-induced HLH, including CNS dysfunction, respiratory distress, multiorgan failure, and disseminated intravascular coagulation, are often severe and can be fatal.<sup>119,121-124</sup> While HLH linked to reactivation of HHV-6 has occurred in patients with underlying conditions, it has also occurred in seemingly healthy individuals.<sup>122</sup> Notably, reactivation is not the only avenue for development of hemophagocytosis and HLH, as both localized and systemic hemophagocytosis can also occur during infancy, and in some cases, it is likely a complication of primary infection.<sup>125-127</sup> As in adults, some children who develop HHV-6-associated HLH may be predisposed to the syndrome due to underlying disorders, including Wiedemann-Beckwith syndrome<sup>124</sup> and beta-thalassemia.<sup>128</sup>

*Hepatitis and Liver Dysfunction.* During HHV-6 reactivation post-transplant, hepatitis and liver dysfunction may develop. Randhawa *et al.* reported a case of HHV-6A-associated gastroduodenitis, pancreatitis, and hepatitis in an adult heart transplant recipient<sup>129</sup> with concomitant multinucleate giant cell transformation observed in biopsies, and in another instance, giant cell

hepatitis presumably caused by HHV-6A was observed in a liver transplant recipient.<sup>130</sup> Both species of HHV-6 have shown cell-cell fusion capabilities *in vitro* in lymphocytes and other cells, although the response is more robust for HHV-6A.<sup>21,131,132</sup> Cell fusion events and polyploidy are associated with malignancies and metastasis.<sup>133</sup> HHV-6 infection has also been associated with an increased number of liver allograft infiltrating lymphocytes expressing class II antigens, LFA-1, and VLA-4,<sup>134</sup> and less commonly, the virus is found in liver tissue from immunocompetent patients with hepatitis<sup>135-137</sup> and multiple organ failure.<sup>138</sup> Among patients with HHV-6-associated liver dysfunction, “atypical” activated lymphocytes may be present in both the blood and infiltrating lymphocytes of the liver.<sup>139</sup>

*DIHS/DRESS.* Perhaps the deleterious effects of HHV-6-mediated lymphocytic infiltration are exemplified best by severe DIHS/DRESS, a condition that can mimic malignant lymphoma<sup>140-142</sup> characterized by erythematous rash, organ dysfunction, and occasionally organ failure.<sup>143</sup> High level HHV-6 viremia is often found in these patients, and HHV-6 DNA and antigen has been detected in the CSF of patients with encephalitis and hemophagocytosis,<sup>143,144</sup> the livers of patients with hepatitis and liver failure,<sup>143,145</sup> the kidneys of patients with renal dysfunction and failure,<sup>146,147</sup> and the bone marrow of patients with hemophagocytic syndrome.<sup>148,149</sup> HHV-6 is thought to contribute to the clinical manifestations of DIHS/DRESS, especially the atypical lymphocytosis,<sup>150</sup> lymphadenitis,<sup>141</sup> and multiorgan involvement, and viremia is predictive of a more severe course and flaring of symptoms, including hepatitis and fever,<sup>151</sup> as is hemophagocytosis.<sup>140</sup> Additionally, administration of valganciclovir has improved the condition of patients with severe DIHS/DRESS.<sup>143,147,149</sup> HHV-6 has been found in hepatocytes<sup>143,145,152</sup> and tubular epithelial cells of the kidney,<sup>146,147</sup> as well as in infiltrating lymphocytes, often atypical.<sup>141,148,152</sup> Notably, the detection of HHV-6 in these cells has corresponded to severe necrosis and dysfunction in the related organs.

In addition to triggering lymphocyte infiltration into organs in DIHS/DRESS, HHV-6 appears to disrupt the properties and functions of lymphocytes during and after the reaction. Laboratory findings include lymphopenia or

lymphocytosis, the presence of “atypical” hyperbasophilic lymphocytes, and sometimes hypogammaglobulinemia, leukocytosis and thrombocytopenia.<sup>153</sup> Infiltrating atypical lymphocytes may be detected in tissue samples, and atypical lymphocytosis is present in 27-67% of DIHS/DRESS patients.<sup>154</sup> Strikingly, in one study<sup>142</sup> HHV-6 antigen was found to be exclusively localized to the Reed-Sternberg-like cells of the lymph node, and the cells exhibited loss of CD3 expression. In a similar study, HHV-6 was reportedly present in the majority of large infiltrating atypical lymphocytes with prominent nuclear inclusions in lymph node biopsies by ISH and IHC for p41 early antigen and DR6 and p101k late antigens, and again, there was partial loss of CD3 expression.<sup>141</sup> As in cases of persistent lymphocytosis with plasmablastoid and Downey-type cells in generalized lymphadenopathy and IM, both cytoplasmic<sup>152</sup> and intranuclear (**Figure 2**)<sup>148</sup> viral inclusions with a peripheral halo in CD3+CD4+ atypical T cells in the lymph node have been reported in DIHS/DRESS. In the latter case, the cells displaying positivity to HHV-6 antibodies appeared to be Tregs, which are thought to be important in the pathogenesis of DIHS/DRESS, as well as the development of autoimmunity after resolution of the syndrome, when Treg activity is suppressed and Th17 cells increase in number significantly.<sup>153</sup> *In vitro* testing indicates that HHV-6A<sup>154</sup> and HHV-6B<sup>155</sup> can induce virus-specific Tregs.

*Castleman’s Disease.* Case reports and some larger studies have found HHV-6 in the blood and lymph nodes of patients with Castleman’s disease (CD) by PCR.<sup>156</sup> When the virus identified in lymph node biopsies was typed in two cases, it corresponded to HHV-6B, and viral loads were 5.5 and 53.7 copies/microgram DNA.<sup>157</sup> In a larger cohort, 2/16 (12%) CD patients, both of multicentric mixed-type CD, were HHV-6 positive by PCR in involved tissues, although they were also positive for EBV, with a total of 9 EBV+ samples.<sup>158</sup> As low-level, latent HHV-6 may be found in healthy individuals, both in tissue and in blood, it is unclear whether these results implicate HHV-6 in the development of CD.

## **Malignant Lymphoproliferation.**

*Hodgkin’s Lymphoma.* Interesting data has been reported on the possible involvement of HHV-6 in the nodular sclerosis (NS) subtype of Hodgkin’s lymphoma (HL) (**Figure 3**). Early results finding HHV-6 antigens p41 and gp116/64/54 in Hodgkin’s disease and Reed Sternberg (RS) cells in 37% of biopsies led investigators to hypothesize that the virus might contribute to HL through dysregulation of the cytokine network and through polyclonal stimulations of cellular proliferation.<sup>159</sup> Further investigation revealed the absence of HHV-6 DNA by Southern blot, even when positive by PCR, absence of the virus in neoplastic cells, and no antigen expression by IHC (for gp102, p41, and P11G1-G9C7), with the exception of 2/2 cases of NSHL with interfollicular pattern, which were positive for HHV-6 MAb in residual germinal centers.<sup>160</sup> Along the same lines, HHV-6 early antigen p41 was not observed in viable RS cells from lymph nodes positive by PCR in a later study, but “mummified” RS cells did show positivity in the two cases with the highest copy numbers.<sup>85</sup> Later studies, however, detected HHV-6 in lymph nodes of 41.9% of NSHL lymph nodes at a mean viral load of 6,711.4 copies/microgram DNA, 12/13 of which were typed as HHV-6B, while tissues from 6 patients with other HL subtypes were negative.<sup>161</sup> The detection of HHV-6 DNA in NSHL cases spurred further examination of additional lymph nodes, and in another cohort, the virus was identified in a majority (83.6%) of tumor samples from patients with NSHL, the predominant type of HL in the group.<sup>162</sup> EBV coinfections accounted for 49.3% of total NS cases, and in coinfecting tissues, viral loads of EBV and HHV-6 were higher than in the specimens with a single infection (mean 47,666.5 copies HHV-6/microgram DNA in NS cases vs. 271.4 copies/microgram DNA), suggesting either an immunosuppressive environment favoring viral reactivation, or potentiation of viral replication through simultaneous activity. In the same study, HHV-6 was also found among 5/10 patients with mixed-cellularity HL, one of two lymphocyte-depleted HL, and in the only patient with lymphocyte-predominance HL.



Figure 2A

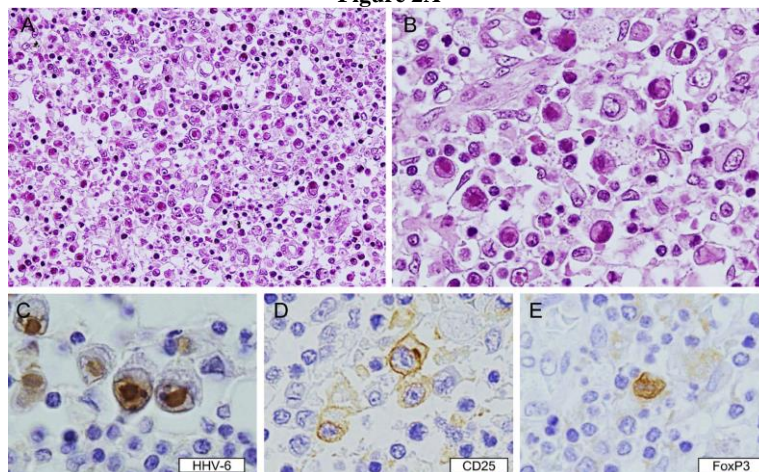
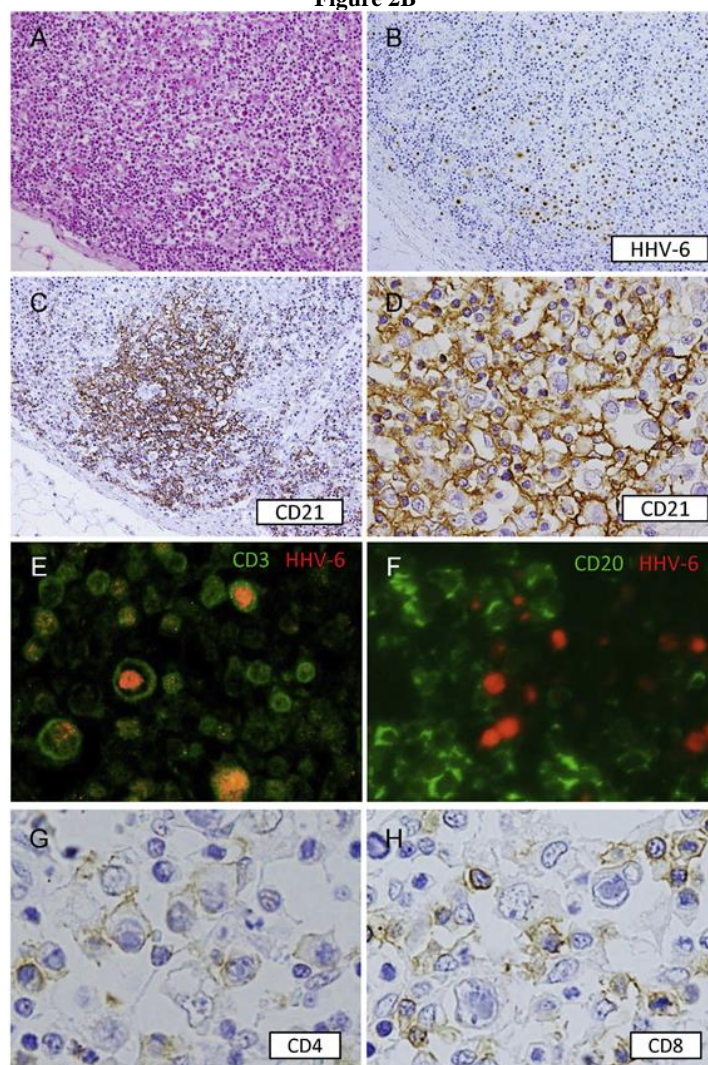


Figure 2B



**Figure 2. HHV-6 in drug induced hypersensitivity syndrome/drug reaction with eosinophilia and systemic symptoms.**

**A. Histopathology and immunohistochemistry of the lymph node.** (A and B) Hematoxylin and eosin staining. Low (A) and high (B) magnification views of the cervical lymph node showed diffuse infiltration of large and blastic lymphoid cells with inclusion bodies. Intranuclear inclusion bodies were eosinophilic and had a halo (B). (C–E) Immunostaining. The large cells with intranuclear inclusion bodies were positive for HHV-6-IE (C). The HHV-6-infected cells were positive for CD25 (D) and FoxP3 (E)(Mine et al. 2014).<sup>148</sup>

**B. Histopathology and immunohistochemistry of the lymph node.** At the cortex of lymph node, large and isolated cells were seen with hematoxylin-eosin staining (A). Many of these isolated cells were positive for HHV-6-IE and were scattered throughout the nodule (B). CD21 immunostaining showed follicular dendritic cells that presented a mesh-work like structure (C and D), in contact with several of the large lymphocytes with inclusion bodies (D). Double immunofluorescence staining showed HHV-6-IE positive cells expressing CD3, but not CD20 (E and F). Immunostaining showed that the large lymphocytes with inclusion bodies were CD4(+) and CD8(-) (G and H)(Mine et al. 2014).<sup>148</sup>

Figure 3A

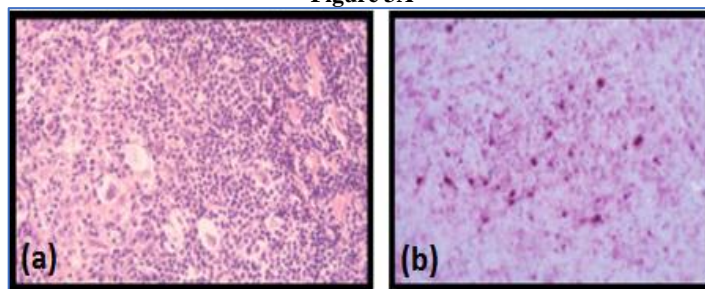


Figure 3B

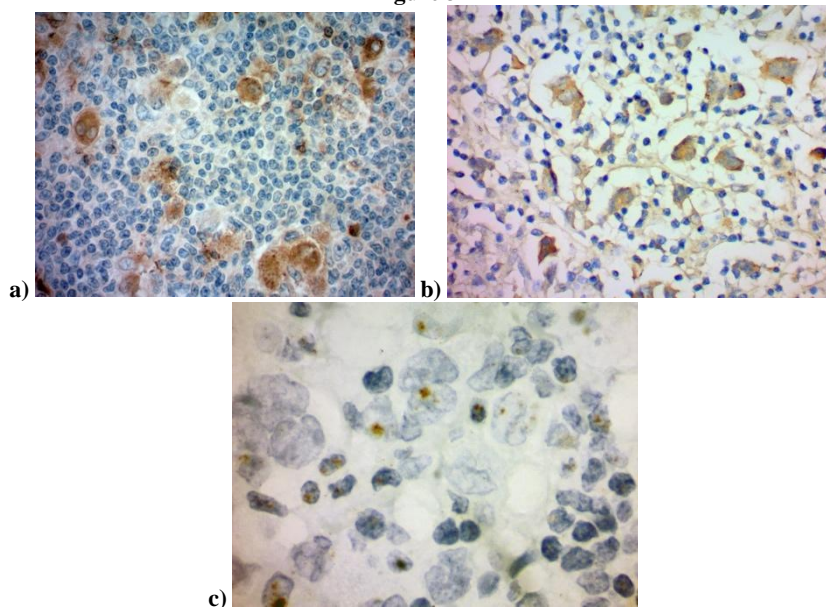
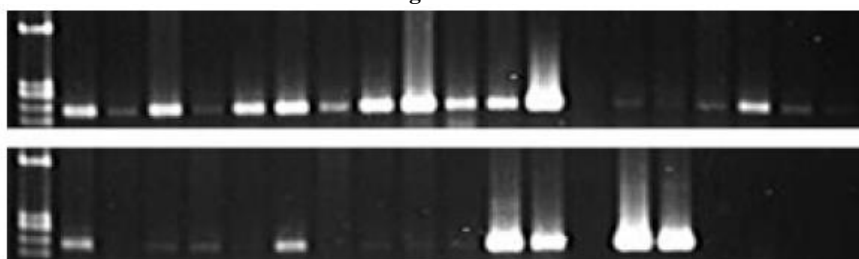


Figure 3C



**Figure 3. HHV-6 in Hodgkin's lymphoma.**

**A. a) HHV-6A in nodular sclerosing Hodgkin's lymphoma.** Hodgkin's lymphoma, nodular sclerosing type: Left, H&E histology. Original magnification x250; b) Right HHV-6 DNA (in situ hybridization pZVH14). Original magnification x250. pZVH14 probe used was designed by and obtained from Dr. Steve Josephs at NCI/NIH. It was obtained from HHV-6A (GS Strain), and was also cross-hybridizes with HHV-6B. Probe was labelled with alkaline phosphatase, and the APAAP reaction was used (APAAP: alkaline phosphatase anti alkaline phosphatase) to visualize its tissues were subjected to in-situ-hybridization. The reaction was sensitive and highly specific as repeatedly proven by isolating HHV-6A in HSB2 cells (isolation in MOLT3 cells for HHV-6B remained negative) (With permission from G. Krueger et al.).

**B. a) Presence of HHV-6 p41 by immunohistochemistry.** Cytoplasmic staining of numerous large cells using a monoclonal antibody to HHV-6 p41 (3E3 clone) among NSHL specimens.

**b). HHV-6 U94 detection by immunohistochemistry.** Staining with monoclonal antibody to HHV-6 U94 reveals positivity in the cytoplasm of numerous large cells.

**c). Presence of HHV-6 by colorimetric in-situ hybridization.** HHV-6 DNA present in the nuclei of both small and large cells. (With permission from Dr. David Hudnall, Yale University, New Haven, CT, USA).

**C. HHV-6 U94 PCR of Hodgkin's lymphoma.** Twenty seven of 31 (87%) HL cases were positive for HHV-6 using primers to the U94 gene. The 19 lanes in the top gel are loaded with PCR product from 19 cases of HL. The 19 lanes in the bottom gel are loaded (from left to right) with PCR product from an additional 12 cases of HL, one empty lane, two positive controls (HHV-6A, HHV-6B), one empty lane, a negative (water) control, and two empty lanes. Viral load appears to vary tremendously from case to case - in 14 cases the viral load is quite high, while in another 13 cases the viral load is very low (Siddon et al. 2012).<sup>165</sup>

Using IHC with antibody that appears to be reactive to both HHV-6 species, the same team later targeted the DR7 oncoprotein, a product of

the ORF-1 gene that is able to bind and inactivate the tumor suppressor p53,<sup>163</sup> which was found in the Reed-Sternberg (RS) cells of 74% of EBV-



negative HL patients whose lymph nodes had previously been found HHV-6 positive by qPCR (n=38; 36 NSHL).<sup>164</sup> The protein was exclusively localized in RS cells, which were CD30+, in 61% of cases. Similarly, exclusive staining for DR7B in RS cells was observed in 6/9 NSHL cases that were both EBV and HHV-6+. The three remaining cases showed positivity in RS and infiltrating cells, and all nine showed positivity for LMP-1, an EBV oncoprotein. A tenth EBV/HHV-6+ patient with mixed-cellularity HL only stained for LMP-1 in RS cells, while DR7B was only identified in infiltrating cells. RS cells were positive for gp116/64/54 in 15 EBV negative patients. Notably, positive staining of gp116/64/54 was observed significantly more frequently (p=0.0154) among patients with stage III and IV HL compared to those at stages I and II.

Via PCR, the prevalence of HHV-6 in 31 additional NSHL lymphoid samples was similar to the rate of detection among tissues from patients with reactive lymphoid hyperplasia (87% vs 83%, respectively).<sup>165</sup> However, IHC analysis revealed HHV-6 whole lysate in numerous RS cells in 48% of cases, and early and late antigen was also found in scattered RS cells. Multiple copies of the virus were present in some RS cells, suggesting that active replication was taking place. Of the samples that were typed, HHV-6B was present singly in 3 cases, HHV-6A was present in 4, and HHV-6A/B coinfection was found in 3. EBV was detected in a total of 5 cases of 21 tested, and EBV/HHV-6 coinfections were detected in RS cells of 3. Of interest, the mean age of patients with HHV-6+ RS cells was 23 years, while those with EBV+ RS cells had a mean age of 47 years (p=0.073). While examination of more cases of mixed cellularity HL is warranted, currently, immunohistochemical findings most strongly suggest that an association may exist between HHV-6 and the NS subtype of HL.

*Non-Hodgkin's Lymphoma.* As HHV-6 was initially isolated from HIV+ patients with malignancies, including non-Hodgkin's lymphoma (NHL), several early studies focused on this population, finding the virus in 4.8-32% of tumor samples.<sup>13,14,84,166</sup> Direct HHV-6-mediated oncogenic activity has not been observed in NHL,<sup>11</sup> and the viral antigen has not been found in the neoplastic cells,<sup>85</sup> but rather, it has been found to be present in infiltrating cells of affected tissues

as well as in blood samples.<sup>167</sup> However, evidence suggests that the virus may act in conjunction with other oncogenic agents, including other viruses, to modulate the lymph node microenvironment and contribute to the characteristic lymphocytic proliferation.<sup>85</sup> Case reports, for instance, have documented a potential interaction between HHV-6 and HHV-8 in diffuse large B-cell lymphoma (DLBCL). Upon analyzing affected tissues of two patients, one with nongerminal B-cell-like DLBCL and the other with primary cutaneous DLBCL, HHV-6 and HHV-8 were simultaneously present in the nucleoli of lymphoma cells. Notably, HHV-6 has shown the capacity to induce expression of HHV-8 lytic phase mRNA and proteins in BCBL-1 cells.<sup>168</sup> Of interest, HHV-6B was also identified among 30.8% of a collection of DLBCL lymph nodes at a mean viral load of 1,140.7 copies/microgram DNA.<sup>161</sup> In comparison, 23.1% of follicular lymphoma samples were positive, but the mean copy number was only 39, and of the other NHL lymphomas tested, only 1 (of 4) peripheral T-cell lymphoma had over 91copies/microgram DNA, with 3,380 copies. In a similar study, 3/5 T-cell lymphoma lymph nodes were HHV-6 (2 HHV-6B, 1 unclassified) positive, with viral loads of 9.1, 60.4, and 810 copies/microgram DNA.<sup>157</sup>

Similarly, EBV coinfections have frequently been observed in HHV-6+ NHL lymphoid biopsies;<sup>169-171</sup> one study, for example, found 57% of HHV-6+ angioimmunoblastic T cell lymphoma/angioimmunoblastic lymphadenopathy (AITL/AILD) lymph nodes to be coinfecting with EBV.<sup>172</sup> In a separate cohort, 79% of HHV-6B+ lymph nodes were EBV+, with the highest HHV-6B viral loads in biopsies with pattern III histology (median 40 copies/1000 cells).<sup>19</sup> Moreover, all of the coinfecting samples showed pattern II or III histology, with the majority falling under pattern III. However, expression of HHV-6 antigens in proliferating T lymphocytes of AILD patients has not been observed.<sup>85</sup>

An inherited, chromosomally integrated form of either HHV-6A or HHV-6B, known as ciHHV-6 or iciHHV-6, is present in about 1% of the population. Two intriguing case reports have documented ciHHV-6+ patients with NHL: One patient, with DLBCL and ciHHV-6 on chromosome 17p, developed marker chromosomes that were also ciHHV-6+,<sup>173</sup> while the other individual, who carried ciHHV-6A on



chromosome 19q, developed a primary effusion-like lymphoma characterized by an absence of any integrated HHV-6.<sup>174</sup> It is possible that ciHHV-6 may have the potential to trigger lymphoma by affecting chromosomal stability.

**Lymphocytic Leukemia.** Although HHV-6 has been detected in the blood<sup>175-176</sup> and bone marrow of patients with lymphocytic leukemia, and heightened titers of HHV-6 antibody have been observed in blood samples,<sup>177-179</sup> a role for the virus in this type of cancer is not well supported. In contrast with a later publication,<sup>180</sup> one study found high rates of HHV-6A in blood and bone marrow samples- 43.8% of B-ALL samples, 52.4% of B-CLL samples, and only less than 10% of MM.<sup>181</sup> HHV-6 p41 antigen has been detected in nearly half of bone marrow samples from patients with myelodysplasia by IHC,<sup>182</sup> but in cases of leukemia, detection of HHV-6A/HHV-6B in the bone marrow only by nested PCR and not via standard PCR, or at low copy numbers by qPCR,<sup>175</sup> has suggested that HHV-6 present in the samples is likely latent.<sup>183</sup> Moreover, when quantified, viral loads both in blood and in bone marrow, have been found to be lower at diagnosis than at remission.<sup>175,180,181</sup> As the virus can infect bone marrow progenitors and reactivate under immunosuppressive conditions, the presence of the virus as it was detected in these instances likely did not impact the course of leukemia.

**Discussion.** The interactions of chronic active HHV-6 infection with the immune system may result in a variety of clinical diseases including aplasia, autoimmune disorders (e.g. Sjögren's syndrome, lupus erythematosus, scleroderma), and lymphoproliferation. These manifestations reflect the disturbed balance between viral persistence and the host's defense status.<sup>184,185</sup> The current overview focuses only on lymphoproliferative disorders in order not to further complicate the report.

HHV-6 may contribute to several benign/reactive lymphoproliferative disorders by spurring a dysfunctional immune response or through dysregulation of cytokines and other

immune mediators. It is probable that HHV-6A and HHV-6B are two of many potential triggers for these disorders, but immunohistochemical analysis may reveal characteristic patterns of viral expression and cellular features in cases associated with either virus. As more instances of HHV-6 associated lymphoproliferation are described, clinical parameters might also be found that are indicative of HHV-6 involvement. Both primary infection and reactivation are able to induce "atypical" lymphocytosis, in which activated cells may appear abnormal and may even resemble transformed, malignant cells. Under some circumstances, HHV-6A/HHV-6B are also capable of inducing organ dysfunction, with lymphocytic infiltration often observed in the affected organs. Because both species of HHV-6 can infect a variety of cells, active infection in tissues may result in an immune response toward the infected tissues, resulting in lymphocytic infiltration, or active infection of lymphocytes may trigger an inflammatory reaction and drive lymphocytic infiltration directly. Although a role for HHV-6 in many lymphomatous malignancies is not strongly supported, evidence points to a potential contribution of the virus in certain Hodgkin's lymphomas of the nodular sclerosis type. The wider use of quantitative PCR and immunohistochemical techniques has enabled more accurate interpretation of viral involvement in lymphoproliferative conditions, and the continued utilization of these techniques will be vital to expanding the knowledge of their association between HHV-6 and these disorders, as well as uncovering the mechanisms behind them. Ultimately, further research is needed to elucidate the immunomodulatory capabilities of HHV-6A and HHV-6B as they relate to the functionality of lymphocytes and to better define their roles in lymphoproliferative diseases, both during acute infection and persistent reactivation.

**Acknowledgements.** We would like to thank Kristin Loomis of the HHV-6 Foundation for her coordination and encouragement.

## References:

1. Salahuddin SZ, Ablashi DV, Markham PD, Josephs SF, Sturzenegger S, Kaplan M, Halligan G, Biberfeld P, Wong-Staal F, Kramarsky B, Gallo RC. Isolation of a new virus, HBLV, in patients with lymphoproliferative disorders. *Science*. 1986;234(4776):596-601. <https://doi.org/10.1126/science.2876520> PMID:2876520
2. Salahuddin SZ, Kelley AS, Krueger GR, Josephs SF, Gupta S, Ablashi DV. Human herpes virus-6 (HHV-6) in diseases. *Clin Diagn Virol*. 1993;1(2):81-100.

- [https://doi.org/10.1016/0928-0197\(93\)90016-X](https://doi.org/10.1016/0928-0197(93)90016-X)
3. Ablashi D, Agut H, Alvarez-Lafuente R, Clark DA, Dewhurst S, DiLuca D, Flamand L, Frenkel N, Gallo R, Gompels UA, Höllsberg P, Jacobson S, Luppi M, Lusso P, Malnati M, Medveczky P, Mori Y, Pellett PE, Pritchett JC, Yamanishi K, Yoshikawa T. Classification of HHV-6A and HHV-6B as distinct viruses. *Arch Virol*. 2014;159(5):863-70. <https://doi.org/10.1007/s00705-013-1902-5> PMID:24193951 PMCID:PMC4750402
  4. Lusso P, Markham PD, Tschachler E, di Marzo Veronese F, Salahuddin SZ, Ablashi DV, Pahwa S, Krohn K, Gallo RC. In vitro cellular tropism of human B-lymphotropic virus (human herpesvirus-6). *J Exp Med*. 1988;167(5):1659-70. <https://doi.org/10.1084/jem.167.5.1659> PMID:3259254
  5. Ablashi DV, Salahuddin SZ, Josephs SF, Imam F, Lusso P, Gallo RC, Hung C, Lemp J, Markham PD. HBLV (or HHV-6) in human cell lines. *Nature*. 1987;329(6136):207. <https://doi.org/10.1038/329207a0> PMID:3627265
  6. Biberfeld P, Kramarsky B, Salahuddin SZ, Gallo RC. Ultrastructural characterization of a new human B lymphotropic DNA virus (human herpesvirus 6) isolated from patients with lymphoproliferative disease. *J Natl Cancer Inst*. 1987;79(5):933-41. PMID:2824914
  7. Ablashi DV, Balachandran N, Josephs SF, Hung CL, Krueger GR, Kramarsky B, Salahuddin SZ, Gallo RC. Genomic polymorphism, growth properties, and immunologic variations in human herpesvirus-6 isolates. *Virology*. 1991;184(2):545-52. [https://doi.org/10.1016/0042-6822\(91\)90424-A](https://doi.org/10.1016/0042-6822(91)90424-A)
  8. Eizuru Y, Minematsu T, Minamishima Y, Kikuchi M, Yamanishi K, Takahashi M, Kurata T, Borisch Chappuis B, Ellinger K, Neipel F, Kirchner T, Kujath P, Fleckenstein B, Müller-Hermelink HK. Human herpesvirus 6 in lymph nodes. *Lancet*. 1989; 333(8628):40-1. [https://doi.org/10.1016/S0140-6736\(89\)91690-5](https://doi.org/10.1016/S0140-6736(89)91690-5)
  9. Dolcetti R, Di Luca D, Mirandola P, De Vita S, De Re V, Carbone A, Tirelli U, Cassai E, Boiocchi M. Frequent detection of human herpesvirus 6 DNA in HIV-associated lymphadenopathy. *Lancet*. 1994;344(8921):543. [https://doi.org/10.1016/S0140-6736\(94\)91931-3](https://doi.org/10.1016/S0140-6736(94)91931-3)
  10. Bertram G, Dreiner N, Krueger GR, Ramon A, Ablashi DV, Salahuddin SZ, Balachandran N. Frequent double infection with Epstein-Barr virus and human herpesvirus-6 in patients with acute infectious mononucleosis. *In Vivo*. 1991;5(3):271-9. PMID:1654150
  11. Krueger GR, Manak M, Bourgeois N, Ablashi DV, Salahuddin SZ, Josephs SS, Buchbinder A, Gallo RC, Berthold F, Tesch H. Persistent active herpes virus infection associated with atypical polyclonal lymphoproliferation (APL) and malignant lymphoma. *Anticancer Res*. 1989;9(6):1457-76. PMID:2560617
  12. Chen T, Hudnall SD. Anatomical mapping of human herpesvirus reservoirs of infection. *Mod Pathol*. 2006;19(5):726-37. <https://doi.org/10.1038/modpathol.3800584> PMID:16528368
  13. Di Luca D, Dolcetti R, Mirandola P, De Re V, Secchiario P, Carbone A, Boiocchi M, Cassai E. Human herpesvirus 6: a survey of presence and variant distribution in normal peripheral lymphocytes and lymphoproliferative disorders. *J Infect Dis*. 1994;170(1):211-5. <https://doi.org/10.1093/infdis/170.1.211> PMID:8014502
  14. Dolcetti R, Di Luca D, Carbone A, Mirandola P, De Vita S, Vaccher E, Sighinolfi L, Ghoghini A, Tirelli U, Cassai E, Boiocchi M. Human herpesvirus 6 in human immunodeficiency virus-infected individuals: association with early histologic phases of lymphadenopathy syndrome but not with malignant lymphoproliferative disorders. *J Med Virol*. 1996;48(4):344-53. [https://doi.org/10.1002/\(SICI\)1096-9071\(199604\)48:4<344::AID-JMV8>3.0.CO;2-7](https://doi.org/10.1002/(SICI)1096-9071(199604)48:4<344::AID-JMV8>3.0.CO;2-7)
  15. Fillet AM, Raphael M, Visse B, Audouin J, Poirer L, Agut H. Controlled study of human herpesvirus 6 detection in acquired immunodeficiency syndrome-associated non-Hodgkin's lymphoma. The French Study Group for HIV-Associated Tumors. *J Med Virol*. 1995;45(1):106-12. <https://doi.org/10.1002/jmv.1890450119> PMID:7714485
  16. Lusso P, Malnati MS, Garzino-Demo A, Crowley RW, Long EO, Gallo RC. Infection of natural killer cells by human herpesvirus 6. *Nature*. 1993;362(6419):458-62. <https://doi.org/10.1038/362458a0> PMID:7681936
  17. Kondo K, Kondo T, Okuno T, Takahashi M, Yamanishi K. Latent human herpesvirus 6 infection of human monocytes/macrophages. *J Gen Virol*. 1991;72 (Pt 6):1401-8. <https://doi.org/10.1099/0022-1317-72-6-1401> PMID:1646280
  18. Kondo K, Kondo T, Shimada K, Amo K, Miyagawa H, Yamanishi K. Strong interaction between human herpesvirus 6 and peripheral blood monocytes/macrophages during acute infection. *J Med Virol*. 2002;67(3):364-9. <https://doi.org/10.1002/jmv.10082> PMID:12116029
  19. Hirata Y, Kondo K, Yamanishi K. Human herpesvirus 6 downregulates major histocompatibility complex class I in dendritic cells. *J Med Virol*. 2001;65(3):576-83. <https://doi.org/10.1002/jmv.2075> PMID:11596096
  20. Ablashi DV, Josephs SF, Buchbinder A, Hellman K, Nakamura S, Llana T, Lusso P, Kaplan M, Dahlberg J, Memon S, Imam F, Ablashi KL, Markham PD, Kramarsky B, Krueger GR, Biberfeld P, Wong-Staal F, Salahuddin SZ, Gallo RC. Human B-lymphotropic virus (human herpesvirus-6). *J Virol Methods*. 1988; 21(1-4):29-48. [https://doi.org/10.1016/0166-0934\(88\)90050-X](https://doi.org/10.1016/0166-0934(88)90050-X)
  21. Krueger GR, Schneider B. Pathologic Features of HHV-6 Disease. In: Krueger GR, Ablashi D, eds. *Perspectives in Medical Virology*. Volume 12, Elsevier. 2006; 133-48. [https://doi.org/10.1016/S0168-7069\(06\)12010-8](https://doi.org/10.1016/S0168-7069(06)12010-8)
  22. Sandhoff T, Kleim JP, Schneeweis KE. Latent human herpesvirus-6 DNA is sparsely distributed in peripheral blood lymphocytes of healthy adults and patients with lymphocytic disorders. *Med Microbiol Immunol*. 1991;180(3):127-34. <https://doi.org/10.1007/BF00206116> PMID:1656178
  23. Yakushijin Y, Yasukawa M, Kobayashi Y. T-cell immune response to human herpesvirus-6 in healthy adults. *Microbiol Immunol*. 1991;35(8):655-60. <https://doi.org/10.1111/j.1348-0421.1991.tb01597.x> PMID:1661364
  24. Nastke MD, Becerra A, Yin L, Dominguez-Amoroch O, Gibson L, Stern LJ, Calvo-Calle JM. Human CD4+ T cell response to human herpesvirus 6. *J Virol*. 2012;86(9):4776-92. <https://doi.org/10.1128/JVI.06573-11> PMID:22357271 PMCID:PMC3347333
  25. Martin LK, Schub A, Dillinger S, Moosmann A. Specific CD8? T cells recognize human herpesvirus 6B. *Eur J Immunol*. 2012;42(11):2901-12. <https://doi.org/10.1002/eji.201242439> PMID:22886850
  26. Yamanishi K, Okuno T, Shiraki K, Takahashi M, Kondo T, Asano Y, Kurata T. Identification of human herpesvirus-6 as a causal agent for exanthem subitum. *Lancet*. 1988;1(8594):1065-7. [https://doi.org/10.1016/S0140-6736\(88\)91893-4](https://doi.org/10.1016/S0140-6736(88)91893-4)
  27. Knox KK, Carrigan DR. In vitro suppression of bone marrow progenitor cell differentiation by human herpesvirus 6 infection. *J Infect Dis*. 1992;165(5):925-9. <https://doi.org/10.1093/infdis/165.5.925>
  28. Carrigan DR, Knox KK. Bone marrow suppression by human herpesvirus-6: comparison of the A and B variants of the virus. *Blood*. 1995;86(2):835-6. PMID:7606018
  29. Horvat RT, Parmely MJ, Chandran B. Human herpesvirus 6 inhibits the proliferative responses of human peripheral blood mononuclear cells. *J Infect Dis*. 1993;167(6):1274-80. <https://doi.org/10.1093/infdis/167.6.1274> PMID:8388898
  30. Flamand L, Gosselin J, Stefanescu I, Ablashi D, Menezes J. Immunosuppressive effect of human herpesvirus 6 on T-cell functions: suppression of interleukin-2 synthesis and cell proliferation. *Blood*. 1995;85(5):1263-71. Erratum in: *Blood* 1995;86(1):418. PMID:7858257
  31. Yoshikawa T, Ihira M, Asano Y, Tomitaka A, Suzuki K, Matsunaga K, Kato Y, Hiramitsu S, Nagai T, Tanaka N, Kimura H, Nishiyama Y. Fatal adult case of severe lymphocytopenia associated with reactivation of human herpesvirus 6. *J Med Virol*. 2002;66(1):82-5. <https://doi.org/10.1002/jmv.2114> PMID:11748662
  32. Knox KK, Pietryga D, Harrington DJ, Franciosi R, Carrigan DR. Progressive immunodeficiency and fatal pneumonitis associated with human herpesvirus 6 infection in an infant. *Clin Infect Dis*. 1995;20(2):406-13. <https://doi.org/10.1093/clinids/20.2.406> PMID:7742449
  33. Comar M, D'Agaro P, Horejsh D, Galvan M, Fiorentini S, Andolina M, Caruso A, Di Luca D, Campello C. Long-lasting CD3+ T-cell deficiency after cord blood stem cell transplantation in a human herpesvirus 6-infected child. *J Clin Microbiol*. 2005;43(4):2002-3. <https://doi.org/10.1128/JCM.43.4.2002-2003.2005> PMID:15815044 PMCID:PMC1081381
  34. Imbert-Marcille BM, Tang XW, Lepelletier D, Besse B, Moreau P, Billaudel S, Milpied N. Human herpesvirus 6 infection after autologous or allogeneic stem cell transplantation: a single-center prospective longitudinal study of 92 patients. *Clin Infect Dis*. 2000;31(4):881-6. <https://doi.org/10.1086/318142> PMID:11049765

35. Rosenfeld CS, Rybka WB, Weinbaum D, Carrigan DR, Knox KK, Andrews DF, Shaddock RK. Late graft failure due to dual bone marrow infection with variants A and B of human herpesvirus-6. *Exp Hematol.* 1995;23(7):626-9. PMID:7601254
36. Admiraal R, de Koning CCH, Lindemans CA, Bierings MB, Wensing AMJ, Versluis AB, Wolfs TFW, Nierkens S, Boelens JJ. Viral reactivations and associated outcomes in the context of immune reconstitution after pediatric hematopoietic cell transplantation. *J Allergy Clin Immunol.* 2017;140(6):1643-1650.e9. Epub 2017 Apr 7. <https://doi.org/10.1016/j.jaci.2016.12.992> PMID:28392330
37. Greco R, Crucitti L, Noviello M, Racca S, Mannina D, Forcina A, Lorentino F, Valtolina V, Rolla S, Dvir R, Morelli M, Giglio F, Barbanti MC, Lupo Stanghellini MT, Oltolini C, Vago L, Scarpellini P, Assanelli A, Carrabba MG, Marktel S, Bernardi M, Corti C, Clementi M, Peccatori J, Bonini C, Ciceri F. Human Herpesvirus 6 Infection Following Haploidentical Transplantation: Immune Recovery and Outcome. *Biol Blood Marrow Transplant.* 2016;22(12):2250-5. <https://doi.org/10.1016/j.bbmt.2016.09.018> PMID:27697585
38. Quintela A, Escuret V, Roux S, Bonnafous P, Gilis L, Barraco F, Labussière-Wallet H, Duscastelle-Leprêtre S, Nicolini FE, Thomas X, Chidiac C, Ferry T, Frobert E, Morisset S, Poitevin-Later F, Monneret G, Michallet M, Ader F; Lyon HEMINF Study Group. HHV-6 infection after allogeneic hematopoietic stem cell transplantation: From chromosomal integration to viral co-infections and T-cell reconstitution patterns. *J Infect.* 2016;72(2):214-22. <https://doi.org/10.1016/j.jinf.2015.09.039> PMID:26518057
39. Wang FZ, Linde A, Dahl H, Ljungman P. Human herpesvirus 6 infection inhibits specific lymphocyte proliferation responses and is related to lymphocytopenia after allogeneic stem cell transplantation. *Bone Marrow Transplant.* 1999;24(11):1201-6. <https://doi.org/10.1038/sj.bmt.1702058> PMID:10642809
40. Illiaquer M, Imbert-Marcille BM, Guillaume T, Planche L, Rimbart M, Bressollette-Bodin C, Le Bourgeois A, Peterlin P, Garnier A, Le Houerou C, Moreau P, Mohty M, Chevallier P. Impact of stem cell graft on early viral infections and immune reconstitution after allogeneic transplantation in adults. *J Clin Virol.* 2017;93:30-6. <https://doi.org/10.1016/j.jcv.2017.05.019> PMID:28601677
41. Smith A, Santoro F, Di Lullo G, Dagna L, Verani A, Lusso P. Selective suppression of IL-12 production by human herpesvirus 6. *Blood.* 2003;102(8):2877-84. <https://doi.org/10.1182/blood-2002-10-3152> PMID:12829600
42. Smith AP, Paolucci C, Di Lullo G, Burastero SE, Santoro F, Lusso P. Viral replication-independent blockade of dendritic cell maturation and interleukin-12 production by human herpesvirus 6. *J Virol.* 2005;79(5):2807-13. <https://doi.org/10.1128/JVI.79.5.2807-2813.2005> PMID:15708999 PMCid:PMC548462
43. Flamand L, Gosselin J, D'Addario M, Hiscott J, Ablashi DV, Gallo RC, Menezes J. Human herpesvirus 6 induces interleukin-1 beta and tumor necrosis factor alpha, but not interleukin-6, in peripheral blood mononuclear cell cultures. *J Virol.* 1991;65(9):5105-10. PMID:1651426 PMCid:PMC248979
44. Arena A, Liberto MC, Iannello D, Capozza AB, Focà A. Altered cytokine production after human herpes virus type 6 infection. *New Microbiol.* 1999;22(4):293-300. PMID:10555198
45. Kikuta H, Nakane A, Lu H, Taguchi Y, Minagawa T, Matsumoto S. Interferon induction by human herpesvirus 6 in human mononuclear cells. *J Infect Dis.* 1990;162(1):35-8. <https://doi.org/10.1093/infdis/162.1.35> PMID:1693942
46. Chi J, Gu B, Zhang C, Peng G, Zhou F, Chen Y, Zhang G, Guo Y, Guo D, Qin J, Wang J, Li L, Wang F, Liu G, Xie F, Feng D, Zhou H, Huang X, Lu S, Liu Y, Hu W, Yao K. Human herpesvirus 6 latent infection in patients with glioma. *J Infect Dis.* 2012;206(9):1394-8. <https://doi.org/10.1093/infdis/jis513> PMID:22962688
47. Yoshikawa T, Asano Y, Akimoto S, Ozaki T, Iwasaki T, Kurata T, Goshima F, Nishiyama Y. Latent infection of human herpesvirus 6 in astrocytoma cell line and alteration of cytokine synthesis. *J Med Virol.* 2002;66(4):497-505. <https://doi.org/10.1002/jmv.2172> PMID:11857528
48. Meeuwssen S, Persoon-Deen C, Bsibsi M, Bajramovic JJ, Ravid R, De Bolle L, van Noort JM. Modulation of the cytokine network in human adult astrocytes by human herpesvirus-6A. *J Neuroimmunol.* 2005;164(1-2):37-47. <https://doi.org/10.1016/j.jneuroim.2005.03.013> PMID:15904975
49. Clark DJ, Catusse J, Stacey A, Borrow P, Gompels UA. Activation of CCR2+ human proinflammatory monocytes by human herpesvirus-6B chemokine N-terminal peptide. *J Gen Virol.* 2013;94(Pt 7):1624-35. <https://doi.org/10.1099/vir.0.050153-0> PMID:23535574
50. Caselli E, Bortolotti D, Marci R, Rotola A, Gentili V, Soffritti I, D'Accolti M, Lo Monte G, Sicolo M, Barao I, Di Luca D, Rizzo R. HHV-6A Infection of Endometrial Epithelial Cells Induces Increased Endometrial NK Cell-Mediated Cytotoxicity. *Front Microbiol.* 2017;8:2525. <https://doi.org/10.3389/fmicb.2017.02525> PMID:29326672 PMCid:PMC5736868
51. Catusse J, Clark DJ, Gompels UA. CCR5 signalling, but not DARC or D6 regulatory, chemokine receptors are targeted by herpesvirus U83A chemokine which delays receptor internalisation via diversion to a caveolin-linked pathway. *J Inflamm (Lond).* 2009;6:22. <https://doi.org/10.1186/1476-9255-6-22> PMID:19643012 PMCid:PMC2744670
52. Catusse J, Spinks J, Mattick C, Dyer A, Laing K, Fitzsimons C, Smit MJ, Gompels UA. Immunomodulation by herpesvirus U51A chemokine receptor via CCL5 and FOG-2 down-regulation plus XCR1 and CCR7 mimicry in human leukocytes. *Eur J Immunol.* 2008;38(3):763-77. <https://doi.org/10.1002/eji.200737618> PMID:18286574
53. Nagasaka M, Morioka I, Kawabata A, Yamagishi Y, Iwatani S, Taniguchi-Ikeda M, Ishida A, Iijima K, Mori Y. Comprehensive analysis of serum cytokines/chemokines in febrile children with primary human herpes virus-6B infection. *J Infect Chemother.* 2016;22(9):593-8. <https://doi.org/10.1016/j.jiac.2016.05.010> PMID:27346377
54. Krueger GRF, Schonnebeck M, Braun M. Enhanced cell membrane receptor expression following infection with human herpesvirus-6. *FASEB J.* 1990;4:A343.
55. Schonnebeck M, Krueger GRF, Braun M, Fischer M, Koch B, Ablashi DV, Balachandran N. Human herpesvirus-6 infection may predispose to superinfection by other viruses. *In Vivo.* 1991;5: 255-64. PMID:1654148
56. Santoro F, Kennedy PE, Locatelli G, Malnati MS, Berger EA, Lusso P. CD46 is a cellular receptor for human herpesvirus 6. *Cell.* 1999;99(7):817-27. [https://doi.org/10.1016/S0092-8674\(00\)81678-5](https://doi.org/10.1016/S0092-8674(00)81678-5)
57. Glosston NL, Hudson AW. Human herpesvirus-6A and -6B encode viral immunoevasins that downregulate class I MHC molecules. *Virology.* 2007;365(1):125-35. <https://doi.org/10.1016/j.virol.2007.03.048> PMID:17467766
58. Grivel JC, Santoro F, Chen S, Fagá G, Malnati MS, Ito Y, Margolis L, Lusso P. Pathogenic effects of human herpesvirus 6 in human lymphoid tissue ex vivo. *J Virol.* 2003;77(15):8280-9. <https://doi.org/10.1128/JVI.77.15.8280-8289.2003> PMID:12857897 PMCid:PMC165251
59. Sullivan BM, Coscoy L. Downregulation of the T-cell receptor complex and impairment of T-cell activation by human herpesvirus 6 u24 protein. *J Virol.* 2008;82(2):602-8. <https://doi.org/10.1128/JVI.01571-07> PMID:17977973 PMCid:PMC2224597
60. Lusso P, Malnati M, De Maria A, Balotta C, DeRocco SE, Markham PD, Gallo RC. Productive infection of CD4+ and CD8+ mature human T cell populations and clones by human herpesvirus 6. Transcriptional down-regulation of CD3. *J Immunol.* 1991; 147(2):685-91. PMID:1677024
61. Lusso P, Garzino-Demo A, Crowley RW, Malnati MS. Infection of gamma/delta T lymphocytes by human herpesvirus 6: transcriptional induction of CD4 and susceptibility to HIV infection. *J Exp Med.* 1995;181(4):1303-10. <https://doi.org/10.1084/jem.181.4.1303> PMID:7699322
62. Furukawa M, Yasukawa M, Yakushijin Y, Fujita S. Distinct effects of human herpesvirus 6 and human herpesvirus 7 on surface molecule expression and function of CD4+ T cells. *J Immunol.* 1994; 152(12):5768-75. PMID:7911490
63. Zheng X, Li S, Zang Z, Hu J, An J, Pei X, Zhu F, Zhang W, Yang H. Evidence for possible role of toll-like receptor 3 mediating virus-induced progression of pituitary adenomas. *Mol Cell Endocrinol.* 2016;426:22-32. <https://doi.org/10.1016/j.mce.2016.02.009> PMID:26891958
64. Reynaud JM, Jégou JF, Welsch JC, Horvat B. Human herpesvirus 6A infection in CD46 transgenic mice: viral persistence in the brain and increased production of proinflammatory chemokines via Toll-like receptor 9. *J Virol.* 2014;88(10):5421-36. <https://doi.org/10.1128/JVI.03763-13>



- PMid:24574405 PMCid:PMC4019085
65. Nordström I, Eriksson K. HHV-6B induces IFN-lambda1 responses in cord plasmacytoid dendritic cells through TLR9. *PLoS One*. 2012;7(6):e38683. Epub 2012 Jun 6. <https://doi.org/10.1371/journal.pone.0038683> PMid:22701693 PMCid:PMC3368904
  66. Chi J, Wang F, Li L, Feng D, Qin J, Xie F, Zhou F, Chen Y, Wang J, Yao K. The role of MAPK in CD4(+) T cells toll-like receptor 9-mediated signaling following HHV-6 infection. *Virology*. 2012;422(1):92-8. <https://doi.org/10.1016/j.virol.2011.09.026> PMid:22055432
  67. Murakami Y, Tanimoto K, Fujiwara H, An J, Suemori K, Ochi T, Hasegawa H, Yasukawa M. Human herpesvirus 6 infection impairs Toll-like receptor signaling. *Virol J*. 2010;7:91. <https://doi.org/10.1186/1743-422X-7-91> PMid:20459723 PMCid:PMC2874541
  68. Krueger GRF, Sander C. What's New in Human Herpesvirus-6? Clinical Immunopathology of the HHV-6 Infection. *Pathol Res Pract*. 1989 Dec;185(6):915-29. [https://doi.org/10.1016/S0344-0338\(89\)80299-7](https://doi.org/10.1016/S0344-0338(89)80299-7)
  69. Mullins TB, Krishnamurthy K. Roseola Infantum (Exanthema Subitum, Sixth Disease). In: StatPearls [Internet]. Treasure Island, StatPearls Publishing. 2018.
  70. Hall CB, Long CE, Schnabel KC, Caserta MT, McIntyre KM, Costanzo MA, Knott A, Dewhurst S, Insel RA, Epstein LG. Human herpesvirus-6 infection in children. A prospective study of complications and reactivation. *N Engl J Med*. 1994;331(7):432-8. <https://doi.org/10.1056/NEJM199408183310703> PMid:8035839
  71. Asano Y, Yoshikawa T, Suga S, Kobayashi I, Nakashima T, Yazaki T, Kajita Y, Ozaki T. Clinical features of infants with primary human herpesvirus 6 infection (exanthem subitum, roseola infantum). *Pediatrics*. 1994;93(1):104-8. PMid:8265302
  72. de Freitas RB, Linhares AC, Oliveira CS, Gusmão RH, Linhares MI. Association of human herpesvirus 6 infection with exanthem subitum in Belem, Brazil. *Rev Inst Med Trop Sao Paulo*. 1995;37(6):489-92. <https://doi.org/10.1590/S0036-46651995000600003> PMid:8731260
  73. Balachandra K, Bowonkiratikachorn P, Poovijit B, Thattiyaphong A, Jayavasu C, Wasi C, Takahashi M, Yamanishi K. Human herpesvirus 6 (HHV-6) infection and exanthem subitum in Thailand. *Acta Paediatr Jpn*. 1991;33(4):434-9. <https://doi.org/10.1111/j.1442-200X.1991.tb02567.x> PMid:1665277
  74. Hashimoto H, Maruyama H, Fujimoto K, Sakakura T, Seishu S, Okuda N. Hematologic findings associated with thrombocytopenia during the acute phase of exanthem subitum confirmed by primary human herpesvirus-6 infection. *J Pediatr Hematol Oncol*. 2002;24(3):211-4. <https://doi.org/10.1097/00043426-200203000-00010> PMid:11990308
  75. Yoshikawa T, Suzuki K, Umemura K, Akimoto S, Miyake F, Usui C, Fujita A, Suga S, Asano Y. Atypical clinical features of a human herpesvirus-6 infection in a neonate. *J Med Virol*. 2004;74(3):463-6. <https://doi.org/10.1002/jmv.20199> PMid:15368515
  76. Kanegane C, Katayama K, Kyoutani S, Kanegane H, Shintani N, Miyawaki T, Taniguchi N. Mononucleosis-like illness in an infant associated with human herpesvirus 6 infection. *Acta Paediatr Jpn*. 1995;37(2):227-9. <https://doi.org/10.1111/j.1442-200X.1995.tb03304.x> PMid:7793262
  77. Hoang MP, Ross KF, Dawson DB, Scheuermann RH, Rogers BB. Human herpesvirus-6 and sudden death in infancy: report of a case and review of the literature. *J Forensic Sci*. 1999;44(2):432-7. <https://doi.org/10.1520/JFS14481J> PMid:10097377
  78. Lorenzana A, Lyons H, Sawaf H, Higgins M, Carrigan D, Emanuel PD. Human herpesvirus 6 infection mimicking juvenile myelomonocytic leukemia in an infant. *J Pediatr Hematol Oncol*. 2002;24(2):136-41. <https://doi.org/10.1097/00043426-200202000-00016> PMid:11990701
  79. Krueger GRF, Ablashi DV, Whitman J, Luka J, Rojo J. Clinical pathology and reactivation of human lymphotropic herpesviruses. *Revista Med Hops Gen Mexico*. 1998;61:226-40.
  80. Irving WL, Cunningham AL. Serological diagnosis of infection with human herpesvirus type 6. *BMJ*. 1990;300(6718):156-9. <https://doi.org/10.1136/bmj.300.6718.156>
  81. Borisch B, Ellinger K, Neipel F, Fleckenstein B, Kirchner T, Ott MM, Müller-Hermelink HK. Lymphadenitis and lymphoproliferative lesions associated with the human herpes virus-6 (HHV-6). *Virchows Arch B Cell Pathol Incl Mol Pathol*. 1991;61(3):179-87. PMid:1685279
  82. Niederman JC, Liu CR, Kaplan MH, Brown NA. Clinical and serological features of human herpesvirus-6 infection in three adults. *Lancet*. 1988;2(8615):817-9. [https://doi.org/10.1016/S0140-6736\(88\)92783-3](https://doi.org/10.1016/S0140-6736(88)92783-3)
  83. Stettner-Gloning R, Jäger G, Gloning H, Pontz BF, Emmrich P. Lymphadenopathy in connection with human herpes virus type 6 (HHV-6) infection. *Clin Invest*. 1992;70(1):59-62. <https://doi.org/10.1007/BF00422942> PMid:1318124
  84. Asou H, Tasaka T, Said JW, Daibata M, Kamada N, Koeffler HP. Co-infection of HHV-6 and HHV-8 is rare in primary effusion lymphoma. *Leuk Res*. 2000;24(1):59-61. [https://doi.org/10.1016/S0145-2126\(99\)00144-7](https://doi.org/10.1016/S0145-2126(99)00144-7)
  85. Luppi M, Barozzi P, Garber R, Maiorana A, Bonacorsi G, Artusi T, Trovato R, Marasca R, Torelli G. Expression of human herpesvirus-6 antigens in benign and malignant lymphoproliferative diseases. *Am J Pathol*. 1998;153(3):815-23. [https://doi.org/10.1016/S0002-9440\(10\)65623-4](https://doi.org/10.1016/S0002-9440(10)65623-4)
  86. Sandhoff T, Kleim JP, Schneweis KE. Latent human herpesvirus-6 DNA is sparsely distributed in peripheral blood lymphocytes of healthy adults and patients with lymphocytic disorders. *Med Microbiol Immunol*. 1991;180(3):127-34. <https://doi.org/10.1007/BF00206116> PMid:1656178
  87. Freitas RB, Freitas MR, Linhares AC. Evidence of active herpesvirus 6 (variant-A) infection in patients with lymphadenopathy in Belém, Pará, Brazil. *Rev Inst Med Trop Sao Paulo*. 2003;45(5):283-8. <https://doi.org/10.1590/S0036-46652003000500008> PMid:14743669
  88. Forghieri F, Luppi M, Barozzi P, Riva G, Morselli M, Bigliardi S, Quadrelli C, Vallerini D, Maccaferri M, Coluccio V, Paolini A, Colaci E, Bonacorsi G, Maiorana A, Tagliazucchi S, Rumpianesi F, Mattioli F, Presutti L, Gelmini R, Cermelli C, Rossi G, Comoli P, Marasca R, Narni F, Potenza L. Chronic and recurrent benign lymphadenopathy without constitutional symptoms associated with human herpesvirus-6B reactivation. *Br J Haematol*. 2016;172(4):561-72. <https://doi.org/10.1111/bjh.13871> PMid:26684692
  89. Weiss LM, O'Malley D. Benign lymphadenopathies. *Mod Pathol*. 2013;26 Suppl 1:S88-96. <https://doi.org/10.1038/modpathol.2012.176> PMid:23281438
  90. Levine PH, Jahan N, Murari P, Manak M, Jaffe ES. Detection of human herpesvirus 6 in tissues involved by sinus histiocytosis with massive lymphadenopathy (Rosai-Dorfman disease). *J Infect Dis*. 1992;166(2):291-5. <https://doi.org/10.1093/infdis/166.2.291> PMid:1321861
  91. Scheel MM, Rady PL, Tying SK, Pandya AG. Sinus histiocytosis with massive lymphadenopathy: presentation as giant granuloma annulare and detection of human herpesvirus 6. *J Am Acad Dermatol*. 1997;37(4):643-6. [https://doi.org/10.1016/S0190-9622\(97\)70186-5](https://doi.org/10.1016/S0190-9622(97)70186-5)
  92. Arakaki N, Gallo G, Majluf R, Diez B, Arias E, Riudavets MA, Sevlever G. Extranodal rosai-dorfman disease presenting as a solitary mass with human herpesvirus 6 detection in a pediatric patient. *Pediatr Dev Pathol*. 2012;15(4):324-8. <https://doi.org/10.2350/11-11-1110-CR.1> PMid:22400904
  93. Ortonne N, Fillet AM, Kosuge H, Bagot M, Frances C, Wechsler J. Cutaneous Destombes-Rosai-Dorfman disease: absence of detection of HHV-6 and HHV-8 in skin. *J Cutan Pathol*. 2002;29(2):113-8. <https://doi.org/10.1034/j.1600-0560.2002.290209.x> PMid:12150132
  94. Hoffmann A, Kim E, Kuerten A, Sander C, Krueger GR, Ablashi DV. Active human herpesvirus-6 (HHV-6) infection associated with Kikuchi-Fujimoto disease and systemic lupus erythematosus (SLE). *In Vivo*. 1991;5(3):265-9. PMid:1654149
  95. Rodríguez JN, Aguayo DM, Elizalde J, Martino ML, Moreno MV, Lara C, Prados D. Kikuchi-Fujimoto disease associated with acute infection by herpesvirus 6. *Sangre (Barc)*. 1996;41(5):387-90.
  96. Hollingsworth HC, Peiper SC, Weiss LM, Raffeld M, Jaffe ES. An investigation of the viral pathogenesis of Kikuchi-Fujimoto disease. Lack of evidence for Epstein-Barr virus or human herpesvirus type 6 as the causative agents. *Arch Pathol Lab Med*. 1994;118(2):134-40. PMid:8311651
  97. Rosado FG, Tang YW, Hasserjian RP, McClain CM, Wang B, Mosse CA. Kikuchi-Fujimoto lymphadenitis: role of parvovirus B-19, Epstein-Barr virus, human herpesvirus 6, and human herpesvirus 8. *Hum Pathol*. 2013;44(2):255-9. <https://doi.org/10.1016/j.humpath.2012.05.016> PMid:22939574
  98. Sumiyoshi Y, Kikuchi M, Ohshima K, Yoneda S, Kobari S, Takeshita M, Eizuru Y, Minamishima Y. Human herpesvirus-6 genomes in histiocytic necrotizing lymphadenitis (Kikuchi's disease) and other

- forms of lymphadenitis. *Am J Clin Pathol.* 1993;99(5):609-14. <https://doi.org/10.1093/ajcp/99.5.609> PMID:8388164
99. Usui Y, Rao NA, Takase H, Tsubota K, Umazume K, Diaz-Aguilar D, Kezuka T, Mochizuki M, Goto H, Sugita S. Comprehensive polymerase chain reaction assay for detection of pathogenic DNA in lymphoproliferative disorders of the ocular adnexa. *Sci Rep.* 2016;6:36621. <https://doi.org/10.1038/srep36621> PMID:27830722 PMCID:PMC5103257
  100. Sugita S, Shimizu N, Kawaguchi T, Akao N, Morio T, Mochizuki M. Identification of human herpesvirus 6 in a patient with severe unilateral panuveitis. *Arch Ophthalmol.* 2007;125(10):1426-7. <https://doi.org/10.1001/archophth.125.10.1426> PMID:17923557
  101. Sugita S, Shimizu N, Watanabe K, Ogawa M, Maruyama K, Usui N, Mochizuki M. Virological analysis in patients with human herpes virus 6-associated ocular inflammatory disorders. *Invest Ophthalmol Vis Sci.* 2012;53(8):4692-8. <https://doi.org/10.1167/iovs.12-10095> PMID:22700707
  102. Bai Y, Wang Z, Sun K, Yao H. HHV-6-associated acute lymphadenitis in immunocompetent patients: a case report and review of literature. *Int J Clin Exp Pathol.* 2014;7(6):3413-7. PMID:25031769 PMCID:PMC4097211
  103. Krueger GR, Ablashi DV, Salahuddin SZ, Josephs SF. Diagnosis and differential diagnosis of progressive lymphoproliferation and malignant lymphoma in persistent active herpesvirus infection. *J Virol Methods.* 1988;21(1-4):255-64. [https://doi.org/10.1016/0166-0934\(88\)90071-7](https://doi.org/10.1016/0166-0934(88)90071-7)
  104. Karino T, Asaoka N, Sunagawa T, Ohba H, Yoneyama H, Kobashi Y, Okimoto J, Soejima R. A case with infectious mononucleosis-like syndrome caused by human herpes virus-6 infection. *Kansenshogaku Zasshi.* 2000;74(3):264-8. <https://doi.org/10.11150/kansenshogakuzasshi1970.74.264> PMID:10783582
  105. Buchwald D, Freedman AS, Ablashi DV, Sullivan JL, Caligiuri M, Weinberg DS, Hall CG, Ashley RL, Saxinger C, Balachandran N, Ritz J, Nadler LM, Komaroff AL. A chronic "postinfectious" fatigue syndrome associated with benign lymphoproliferation, B-cell proliferation, and active replication of human herpesvirus-6. *J Clin Immunol.* 1990;10(6):335-44. <https://doi.org/10.1007/BF00917479> PMID:1964694
  106. Steeper TA, Horwitz CA, Ablashi DV, Salahuddin SZ, Saxinger C, Saltzman R, Schwartz B. The spectrum of clinical and laboratory findings resulting from human herpesvirus-6 (HHV-6) in patients with mononucleosis-like illnesses not resulting from Epstein-Barr virus or cytomegalovirus. *Am J Clin Pathol.* 1990;93(6):776-83. <https://doi.org/10.1093/ajcp/93.6.776> PMID:2161178
  107. Naito T, Kudo N, Inui A, Matsumoto N, Takeda N, Isonuma H, Dambara T, Hayashida Y. Causes of infectious mononucleosis-like syndrome in adult patients. *Intern Med.* 2006;45(13):833-4. <https://doi.org/10.2169/INTERNALMEDICINE.45.1725> PMID:16880711
  108. Horwitz CA, Krueger GRF, Steeper TA, Bertram G. HHV-6-induced mononucleosis-like illnesses. Perspectives in Medical Virology. 1992;4:159-74. [https://doi.org/10.1016/S0168-7069\(08\)70064-8](https://doi.org/10.1016/S0168-7069(08)70064-8)
  109. Ramon A, Krueger GRF, Simoes P, Jockenhoevel F, Neumann R, Rojo J, Ablashi DV: Immunopathology of liver diseases. *Revista Med Hosp Gen Mexico.* 1998;61:241-61.
  110. Kirchesch H, Mertens T, Burkhardt U, Kruppenbacher JP, Höffken A, Eggers HJ. Seroconversion against human herpesvirus-6 (and other herpesviruses) and clinical illness. *Lancet.* 1988;2(8605):273-4. [https://doi.org/10.1016/S0140-6736\(88\)92557-3](https://doi.org/10.1016/S0140-6736(88)92557-3)
  111. Sobue R, Miyazaki H, Okamoto M, Hirano M, Yoshikawa T, Suga S, Asano Y. Fulminant hepatitis in primary human herpesvirus-6 infection. *N Engl J Med.* 1991;324(18):1290. <https://doi.org/10.1056/NEJM199105023241818> PMID:1849614
  112. Krueger GR, Bertram G, Ramon A, Koch B, Ablashi DV, Brandt ME, Wang G, Buja LM. Dynamics of infection with human herpesvirus-6 in EBV-negative infectious mononucleosis: data acquisition for computer modeling. *In Vivo.* 2001;15(5):373-80. PMID:11695232
  113. Akashi K, Eizuru Y, Sumiyoshi Y, Minematsu T, Hara S, Harada M, Kikuchi M, Niho Y, Minamishima Y. Brief report: severe infectious mononucleosis-like syndrome and primary human herpesvirus 6 infection in an adult. *N Engl J Med.* 1993;329(3):168-71. <https://doi.org/10.1056/NEJM199307153290304> PMID:8390615
  114. Sumiyoshi Y, Akashi K, Kikuchi M. Detection of human herpes virus 6 (HHV 6) in the skin of a patient with primary HHV 6 infection and erythroderma. *J Clin Pathol.* 1994;47(8):762-3. <https://doi.org/10.1136/jcp.47.8.762> PMID:7962635 PMCID:PMC502155
  115. Sumiyoshi Y, Kikuchi M, Ohshima K, Takeshita M, Eizuru Y, Minamishima Y. A case of human herpesvirus-6 lymphadenitis with infectious mononucleosis-like syndrome. *Pathol Int.* 1995;45(12):947-51. <https://doi.org/10.1111/j.1440-1827.1995.tb03420.x> PMID:8808300
  116. Tsaparas YF, Brigden ML, Mathias R, Thomas E, Raboud J, Doyle PW. Proportion positive for Epstein-Barr virus, cytomegalovirus, human herpesvirus 6, Toxoplasma, and human immunodeficiency virus types 1 and 2 in heterophile-negative patients with an absolute lymphocytosis or an instrument-generated atypical lymphocyte flag. *Arch Pathol Lab Med.* 2000;124(9):1324-30. PMID:10975931
  117. Wang G, Krueger GR, Buja LM. Mathematical model to simulate the cellular dynamics of infection with human herpesvirus-6 in EBV-negative infectious mononucleosis. *J Med Virol.* 2003;71(4):569-77. <https://doi.org/10.1002/jmv.10522> PMID:14556271
  118. Krueger GR, Brandt ME, Wang G, Berthold F, Buja LM. A computational analysis of Canale-Smith syndrome: chronic lymphadenopathy simulating malignant lymphoma. *Anticancer Res.* 2002;22(4):2365-71. PMID:12174928
  119. Hoang MP, Dawson DB, Rogers ZR, Scheuermann RH, Rogers BB. Polymerase chain reaction amplification of archival material for Epstein-Barr virus, cytomegalovirus, human herpesvirus 6, and parvovirus B19 in children with bone marrow hemophagocytosis. *Hum Pathol.* 1998;29(10):1074-7. [https://doi.org/10.1016/S0046-8177\(98\)90416-6](https://doi.org/10.1016/S0046-8177(98)90416-6)
  120. Syručková Z, Starý J, Sedláček P, Smíšek P, Vavrinec J, Komrská V, Roubalová K, Vandasová J, Sintáková B, Housková J, Hassan M. Infection-associated hemophagocytic syndrome complicated by infectious lymphoproliferation: a case report. *Pediatr Hematol Oncol.* 1996;13(2):143-50. <https://doi.org/10.3109/08880019609030804> PMID:8721028
  121. Tadokoro R, Okumura A, Nakazawa T, Hara S, Yamakawa Y, Kamata A, Kinoshita K, Obinata K, Shimizu T. Acute encephalopathy with biphasic seizures and late reduced diffusion associated with hemophagocytic syndrome. *Brain Dev.* 2010;32(6):477-81. <https://doi.org/10.1016/j.braindev.2009.05.007> PMID:19556082
  122. Tanaka H, Nishimura T, Hakui M, Sugimoto H, Tanaka-Taya K, Yamanishi K. Human herpesvirus 6-associated hemophagocytic syndrome in a healthy adult. *Emerg Infect Dis.* 2002;8(1):87-8. <https://doi.org/10.3201/eid0801.010149> PMCID:PMC2730277
  123. Dharancy S, Crombe V, Copin MC, Boleslawski E, Bocket L, Declercq N, Canva V, Dewilde A, Mathurin P, Pruvot FR. Fatal hemophagocytic syndrome related to human herpesvirus-6 reinfection following liver transplantation: a case report. *Transplant Proc.* 2008;40(10):3791-3. <https://doi.org/10.1016/j.transproceed.2008.05.083> PMID:19100492
  124. Marabelle A, Bergeron C, Billaud G, Mekki Y, Girard S. Hemophagocytic syndrome revealing primary HHV-6 infection. *J Pediatr.* 2010;157(3):511. <https://doi.org/10.1016/j.jpeds.2010.02.064> PMID:20400100
  125. Takagi M, Unno A, Maruyama T, Kaneko K, Obinata K. Human herpesvirus-6 (HHV-6)-associated hemophagocytic syndrome. *Pediatr Hematol Oncol.* 1996;13(5):451-6. <https://doi.org/10.3109/08880019609030857> PMID:10897817
  126. Chen RL, Lin KH, Lin DT, Su JJ, Huang LM, Lee PI, Hsieh KH, Lin KS, Lee CY. Immunomodulation treatment for childhood virus-associated haemophagocytic lymphohistiocytosis. *Br J Haematol.* 1995;89(2):282-90. <https://doi.org/10.1111/j.1365-2141.1995.tb03302.x> PMID:7873378
  127. Huang LM, Lee CY, Lin KH, Chuu WM, Lee PI, Chen RL, Chen JM, Lin DT. Human herpesvirus-6 associated with fatal haemophagocytic syndrome. *Lancet.* 1990;336(8706):60-1. [https://doi.org/10.1016/0140-6736\(90\)91580-4](https://doi.org/10.1016/0140-6736(90)91580-4)
  128. Liu DL, Teng RJ, Ho MM, Hwang KC, Hwang LM. Human herpesvirus-6 associated hemophagocytic syndrome in beta-thalassemia: report of one case. *Zhonghua Min Guo Xiao Er Ke Yi Xue Hui Za Zhi.* 1995;36(5):373-5. PMID:8607365
  129. Randhawa PS, Jenkins FJ, Nalesnik MA, Martens J, Williams PA, Ries A, Pham S, Demetris AJ. Herpesvirus 6 variant A infection after heart transplantation with giant cell transformation in bile ductular and gastroduodenal epithelium. *Am J Surg Pathol.* 1997;21(7):847-53. <https://doi.org/10.1097/00000478-199707000-00014> PMID:9236842
  130. Potenza L, Luppi M, Barozzi P, Rossi G, Cocchi S, Codeluppi M,

- Pecorari M, Masetti M, Di Benedetto F, Gennari W, Portolani M, Gerunda GE, Lazzarotto T, Landini MP, Schulz TF, Torelli G, Guaraldi G. HHV-6A in syncytial giant-cell hepatitis. *N Engl J Med*. 2008;359(6):593-602. <https://doi.org/10.1056/NEJMoa074479> PMID:18687640
131. Mori Y, Seya T, Huang HL, Akkapaiboon P, Dhepakson P, Yamanishi K. Human herpesvirus 6 variant A but not variant B induces fusion from without in a variety of human cells through a human herpesvirus 6 entry receptor, CD46. *J Virol*. 2002;76(13):6750-61. <https://doi.org/10.1128/JVI.76.13.6750-6761.2002> PMID:12050388 PMCID:PMC136280
132. Pedersen SM, Oster B, Bundgaard B, Höllsberg P. Induction of cell-cell fusion from without by human herpesvirus 6B. *J Virol*. 2006;80(19):9916-20. <https://doi.org/10.1128/JVI.02693-05> PMID:16973598 PMCID:PMC1617257
133. Bastida-Ruiz D, Van Hoesen K, Cohen M. The Dark Side of Cell Fusion. *Int J Mol Sci*. 2016;17(5):638. <https://doi.org/10.3390/ijms17050638> PMID:27136533 PMCID:PMC4881464
134. Lautenschlager I, Härmä M, Höckerstedt K, Linnavuori K, Loginov R, Taskinen E. Human herpesvirus-6 infection is associated with adhesion molecule induction and lymphocyte infiltration in liver allografts. *J Hepatol*. 2002;37(5):648-54. [https://doi.org/10.1016/S0168-8278\(02\)00246-5](https://doi.org/10.1016/S0168-8278(02)00246-5)
135. Schmitt K, Deutsch J, Tulzer G, Meindi R, Aberle S. Autoimmune hepatitis and adrenal insufficiency in an infant with human herpesvirus-6 infection. *Lancet*. 1996;348(9032):966. [https://doi.org/10.1016/S0140-6736\(96\)5385-8](https://doi.org/10.1016/S0140-6736(96)5385-8)
136. Charnot-Katsikas A, Baewer D, Cook L, David MZ. Fulminant hepatic failure attributed to infection with human herpesvirus 6 (HHV-6) in an immunocompetent woman: A case report and review of the literature. *J Clin Virol*. 2016;75:27-32. <https://doi.org/10.1016/j.jcv.2015.12.002> PMID:26745830
137. Asano Y, Yoshikawa T, Suga S, Yazaki T, Kondo K, Yamanishi K. Fatal fulminant hepatitis in an infant with human herpesvirus-6 infection. *Lancet*. 1990;335(8693):862-3. [https://doi.org/10.1016/0140-6736\(90\)90983-C](https://doi.org/10.1016/0140-6736(90)90983-C)
138. Chang YL, Parker ME, Nuovo G, Miller JB. Human herpesvirus 6-related fulminant myocarditis and hepatitis in an immunocompetent adult with fatal outcome. *Hum Pathol*. 2009;40(5):740-5. <https://doi.org/10.1016/j.humpath.2008.08.017> PMID:19144379
139. Grima P, Chiavaroli R, Calabrese P, Tundo P, Grima P. Severe hepatitis with autoimmune features following a HHV-6: a case report. *Cases J*. 2008;1(1):110. <https://doi.org/10.1186/1757-1626-1-110> PMID:18710564 PMCID:PMC2531091
140. Descamps V, Bouscarat F, Laglenne S, Aslangul E, Veber B, Descamps D, Sarau JL, Grange MJ, Grossin M, Navratil E, Crickx B, Belaich S. Human herpesvirus 6 infection associated with anticonvulsant hypersensitivity syndrome and reactive haemophagocytic syndrome. *Br J Dermatol*. 1997;137(4):605-8. <https://doi.org/10.1111/j.1365-2133.1997.tb03795.x> PMID:9390340
141. Johnson S, Mathews S, Hudnall SD. Human herpesvirus 6 lymphadenitis in drug rash with eosinophilia and systemic symptoms syndrome: a lymphoma mimic. *Histopathology*. 2017;70(7):1166-70. <https://doi.org/10.1111/his.13157> PMID:28008656
142. Saraya T, Mikoshiba M, Kamiyama H, Yoshizumi M, Tsuchida S, Tsukagoshi H, Ishioka T, Terada M, Tanabe E, Tomioka C, Ishii H, Kimura H, Kozawa K, Shiohara T, Takizawa H, Goto H. Evidence for reactivation of human herpesvirus 6 in generalized lymphadenopathy in a patient with drug-induced hypersensitivity syndrome. *J Clin Microbiol*. 2013;51(6):1979-82. <https://doi.org/10.1128/JCM.00097-13> PMID:23536404 PMCID:PMC3716082
143. Eshki M, Allanore L, Musette P, Milpied B, Grange A, Guillaume JC, Chosidow O, Guillot I, Paradis V, Joly P, Crickx B, Ranger-Rogez S, Descamps V. Twelve-year analysis of severe cases of drug reaction with eosinophilia and systemic symptoms: a cause of unpredictable multiorgan failure. *Arch Dermatol*. 2009;145(1):67-72. <https://doi.org/10.1001/archderm.145.1.67> PMID:19153346
144. Fujino Y, Nakajima M, Inoue H, Kusuhara T, Yamada T. Human herpesvirus 6 encephalitis associated with hypersensitivity syndrome. *Ann Neurol*. 2002;51(6):771-4. <https://doi.org/10.1002/ana.10194> PMID:12112085
145. Mennicke M, Zawodniak A, Keller M, Wilkens L, Yawalkar N, Stickel F, Keogh A, Inderbitzin D, Candinas D, Pichler WJ. Fulminant liver failure after vancomycin in a sulfasalazine-induced DRESS syndrome: fatal recurrence after liver transplantation. *Am J Transplant*. 2009;9(9):2197-202. <https://doi.org/10.1111/j.1600-6143.2009.02788.x> PMID:19706026
146. Miyashita K, Shobatake C, Miyagawa F, Kobayashi N, Onmori R, Yonekawa S, Tanabe K, Kawate K, Morita K, Asada H. Involvement of Human Herpesvirus 6 Infection in Renal Dysfunction Associated with DIHS/DRESS. *Acta Derm Venereol*. 2016;96(1):114-5. <https://doi.org/10.2340/00015555-2149> PMID:26039936
147. Hagiya H, Iwamuro M, Tanaka T, Hasegawa K, Hanayama Y, Kimura M, Otsuka F. Reactivation of Human Herpes Virus-6 in the Renal Tissue of a Patient with Drug-induced Hypersensitivity Syndrome/Drug Rash with Eosinophilia and Systemic Symptoms (DIHS/DRESS). *Intern Med*. 2016;55(13):1769-74. <https://doi.org/10.2169/internalmedicine.55.6287> PMID:27374681
148. Mine S, Suzuki K, Sato Y, Fukumoto H, Kataoka M, Inoue N, Ohbayashi C, Hasegawa H, Sata T, Fukayama M, Katano H. Evidence for human herpesvirus-6B infection of regulatory T-cells in acute systemic lymphadenitis in an immunocompetent adult with the drug reaction with eosinophilia and systemic symptoms syndrome: a case report. *J Clin Virol*. 2014;61(3):448-52. <https://doi.org/10.1016/j.jcv.2014.08.025> PMID:25249343
149. Descamps V, Ranger-Rogez S. DRESS syndrome. *Joint Bone Spine*. 2014;81(1):15-21. <https://doi.org/10.1016/j.jbspin.2013.05.002> PMID:23816504
150. Nakazato T, Suzuki K, Mihara A, Sanada Y, Aisa Y, Kakimoto T. ATL-like marked atypical lymphocytosis associated with drug-induced hypersensitivity syndrome and human herpesvirus-6 reactivation. *Int J Hematol*. 2009;90(5):648-50. <https://doi.org/10.1007/s12185-009-0449-4> PMID:19937484
151. Tohyama M, Hashimoto K, Yasukawa M, Kimura H, Horikawa T, Nakajima K, Urano Y, Matsumoto K, Iijima M, Shear NH. Association of human herpesvirus 6 reactivation with the flaring and severity of drug-induced hypersensitivity syndrome. *Br J Dermatol*. 2007;157(5):934-40. <https://doi.org/10.1111/j.1365-2133.2007.08167.x> PMID:17854362
152. Maric I, Bryant R, Abu-Asab M, Cohen JI, Vivero A, Jaffe ES, Raffeld M, Tsokos M, Banks PM, Pittaluga S. Human herpesvirus-6-associated acute lymphadenitis in immunocompetent adults. *Mod Pathol*. 2004;17(11):1427-33. <https://doi.org/10.1038/modpathol.3800179> PMID:15494709 PMCID:PMC2288737
153. Takahashi R, Kano Y, Yamazaki Y, Kimishima M, Mizukawa Y, Shiohara T. Defective regulatory T cells in patients with severe drug eruptions: timing of the dysfunction is associated with the pathological phenotype and outcome. *J Immunol*. 2009;182(12):8071-9. <https://doi.org/10.4049/jimmunol.0804002> PMID:19494333
154. Wang F, Chi J, Peng G, Zhou F, Wang J, Li L, Feng D, Xie F, Gu B, Qin J, Chen Y, Yao K. Development of virus-specific CD4+ and CD8+ regulatory T cells induced by human herpesvirus 6 infection. *J Virol*. 2014;88(2):1011-24. <https://doi.org/10.1128/JVI.02586-13> PMID:24198406 PMCID:PMC3911638
155. Wang F, Yao K, Yin QZ, Zhou F, Ding CL, Peng GY, Xu J, Chen Y, Feng DJ, Ma CL, Xu WR. Human herpesvirus-6-specific interleukin 10-producing CD4+ T cells suppress the CD4+ T-cell response in infected individuals. *Microbiol Immunol*. 2006;50(10):787-803. <https://doi.org/10.1111/j.1348-0421.2006.tb03855.x> PMID:17053315
156. Fazakas A, Csire M, Berencsi G, Szepesi A, Matolcsy A, Jakab L, Karádi I, Várkonyi J. Multicentric plasmocytic Castleman's disease with polyneuropathy, organomegaly, endocrinopathy, M protein, skin changes syndrome and coexistent human herpes virus-6 infection--a possible relationship. *Leuk Lymphoma*. 2009;50(10):1661-5. <https://doi.org/10.1080/10428190903162743> PMID:19863339
157. Ohyashiki JH, Abe K, Ojima T, Wang P, Zhou CF, Suzuki A, Ohyashiki K, Yamamoto K. Quantification of human herpesvirus 6 in healthy volunteers and patients with lymphoproliferative disorders by PCR-ELISA. *Leuk Res*. 1999;23(7):625-30. [https://doi.org/10.1016/S0145-2126\(99\)00079-X](https://doi.org/10.1016/S0145-2126(99)00079-X)
158. Barozzi P, Luppi M, Masini L, Marasca R, Savarino M, Morselli M, Ferrari MG, Bevini M, Bonacorsi G, Torelli G. Lymphotropic herpes virus (EBV, HHV-6, HHV-8) DNA sequences in HIV negative Castleman's disease. *Clin Mol Pathol*. 1996;49(4):M232-5. <https://doi.org/10.1136/mp.49.4.M232> PMID:16696081 PMCID:PMC408065
159. Krueger GR, Guenther A, Knuefermann R, Kluppelberg U, Luka J,



- Pearson GR, Ablashi DV, Juecker M, Tesch H. Human herpesvirus-6 (HHV-6) in Hodgkin's disease: cellular expression of viral antigens as compared to oncogenes met and fes, tumor suppressor gene product p53, and interleukins 2 and 6. *In Vivo*. 1994;8(4):501-16. PMID:7893977
160. Valente G, Secchiero P, Lusso P, Abete MC, Jemma C, Reato G, Kerim S, Gallo RC, Palestro G. Human herpesvirus 6 and Epstein-Barr virus in Hodgkin's disease: a controlled study by polymerase chain reaction and in situ hybridization. *Am J Pathol*. 1996;149(5):1501-10. PMID:8909240 PMCid:PMC1865277
161. Collot S, Petit B, Bordessoule D, Alain S, Touati M, Denis F, Ranger-Rogez S. Real-time PCR for quantification of human herpesvirus 6 DNA from lymph nodes and saliva. *J Clin Microbiol*. 2002;40(7):2445-51. <https://doi.org/10.1128/JCM.40.7.2445-2451.2002> PMID:12089260 PMCid:PMC120581
162. Lacroix A, Jaccard A, Rouzioux C, Piguet C, Petit B, Bordessoule D, Ranger-Rogez S. HHV-6 and EBV DNA quantitation in lymph nodes of 86 patients with Hodgkin's lymphoma. *J Med Virol*. 2007;79(9):1349-56. <https://doi.org/10.1002/jmv.20868> PMID:17607791
163. Kashanchi F, Araujo J, Doniger J, Muralidhar S, Hoch R, Khleif S, Mendelson E, Thompson J, Azumi N, Brady JN, Luppi M, Torelli G, Rosenthal LJ. Human herpesvirus 6 (HHV-6) ORF-1 transactivating gene exhibits malignant transforming activity and its protein binds to p53. *Oncogene*. 1997;14(3):359-67. <https://doi.org/10.1038/sj.onc.1200840> PMID:9018122
164. Lacroix A, Collot-Teixeira S, Mardivirin L, Jaccard A, Petit B, Piguet C, Sturtz F, Preux PM, Bordessoule D, Ranger-Rogez S. Involvement of human herpesvirus-6 variant B in classic Hodgkin's lymphoma via DR7 oncoprotein. *Clin Cancer Res*. 2010;16(19):4711-21. <https://doi.org/10.1158/1078-0432.CCR-10-0470> PMID:20858841
165. Siddon A, Lozovatsky L, Mohamed A, Hudnall SD. Human herpesvirus 6 positive Reed-Sternberg cells in nodular sclerosis Hodgkin lymphoma. *Br J Haematol*. 2012;158(5):635-43. <https://doi.org/10.1111/j.1365-2141.2012.09206.x> PMID:22757777
166. Carbone A, Dolcetti R, Ghoghini A, Maestro R, Vaccher E, di Luca D, Tirelli U, Boiocchi M. Immunophenotypic and molecular analyses of acquired immune deficiency syndrome-related and Epstein-Barr virus-associated lymphomas: a comparative study. *Hum Pathol*. 1996;27(2):133-46. [https://doi.org/10.1016/S0046-8177\(96\)90366-4](https://doi.org/10.1016/S0046-8177(96)90366-4)
167. Braun DK, Pellett PE, Hanson CA. Presence and expression of human herpesvirus 6 in peripheral blood mononuclear cells of S100-positive, T cell chronic lymphoproliferative disease. *J Infect Dis*. 1995;171(5):1351-5. <https://doi.org/10.1093/infdis/171.5.1351> PMID:7751716
168. Lu C, Zeng Y, Huang Z, Huang L, Qian C, Tang G, Qin D. Human herpesvirus 6 activates lytic cycle replication of Kaposi's sarcoma-associated herpesvirus. *Am J Pathol*. 2005;166(1):173-83. [https://doi.org/10.1016/S0002-9440\(10\)62242-0](https://doi.org/10.1016/S0002-9440(10)62242-0)
169. Josephs SF, Buchbinder A, Streicher HZ, Ablashi DV, Salahuddin SZ, Guo HG, Wong-Staal F, Cossman J, Raffeld M, Sundeen J. Detection of human B-lymphotropic virus (human herpesvirus 6) sequences in B cell lymphoma tissues of three patients. *Leukemia*. 1988;2(3):132-5. PMID:3258048
170. Zhou Y, Attygalle AD, Chuang SS, Diss T, Ye H, Liu H, Hamoudi RA, Munson P, Bacon CM, Dogan A, Du MQ. Angioimmunoblastic T-cell lymphoma: histological progression associates with EBV and HHV6B viral load. *Br J Haematol*. 2007;138(1):44-53. <https://doi.org/10.1111/j.1365-2141.2007.06620.x> PMID:17555446
171. Strong MJ, O'Grady T, Lin Z, Xu G, Baddoo M, Parsons C, Zhang K, Taylor CM, Flemington EK. Epstein-Barr virus and human herpesvirus 6 detection in a non-Hodgkin's diffuse large B-cell lymphoma cohort by using RNA sequencing. *J Virol*. 2013;87(23):13059-62. <https://doi.org/10.1128/JVI.02380-13> PMID:24049168 PMCid:PMC338131
172. Luppi M, Marasca R, Barozzi P, Artusi T, Torelli G. Frequent detection of human herpesvirus-6 sequences by polymerase chain reaction in paraffin-embedded lymph nodes from patients with angioimmunoblastic lymphadenopathy and angioimmunoblastic lymphadenopathy-like lymphoma. *Leuk Res*. 1993;17(11):1003-11. [https://doi.org/10.1016/0145-2126\(93\)90049-Q](https://doi.org/10.1016/0145-2126(93)90049-Q)
173. Campioni D, Gentili V, Cavazzini F, Bortolotti D, Nacheva EP, Cuneo A, Di Luca D, Rizzo R. Detection of inherited chromosomally integrated HHV-6 (ciHHV-6) in a marker chromosome. *Eur J Haematol*. 2017;98(6):635-7. <https://doi.org/10.1111/ejh.12872> PMID:28244148
174. Zhang E, Cotton VE, Hidalgo-Bravo A, Huang Y, Bell AJ, Jarrett RF, Wilkie GS, Davison AJ, Nacheva EP, Siebert R, Majid A, Kelpandies I, Jayne S, Dyer MJ, Royle NJ. HHV-8-unrelated primary effusion-like lymphoma associated with clonal loss of inherited chromosomally-integrated human herpesvirus-6A from the telomere of chromosome 19q. *Sci Rep*. 2016;6:22730. <https://doi.org/10.1038/srep22730> PMID:26947392 PMCid:PMC4779988
175. Seror E, Coquerel B, Gautheret-Dejean A, Ballerini P, Landman-Parker J, Leverger G, Schneider P, Vannier JP. Quantitation of human herpes virus 6 genome in children with acute lymphoblastic leukemia. *J Med Virol*. 2008;80(4):689-93. <https://doi.org/10.1002/jmv.21118> PMID:18297709
176. Mori S, Sugahara K, Uemura A, Akamatsu N, Hirakata Y, Murata K, Hasegawa H, Yamada Y, Kamihira S. Usefulness of a comprehensive PCR-based assay for human herpes viral DNA in blood mononuclear cell samples. *Lab Hematol*. 2005;11(3):163-70. <https://doi.org/10.1532/LH96.05027> PMID:16174601
177. Levine PH, Ablashi DV, Saxinger WC, Connelly RR. Antibodies to human herpes virus-6 in patients with acute lymphocytic leukemia. *Leukemia*. 1992;6(11):1229-31. PMID:1331626
178. Schlehofer B, Blettner M, Geletnek K, Haaf HG, Kaatsch P, Michaelis J, Mueller-Lantzsch N, Niehoff D, Winkelspecht B, Wahrendorf J, Schlehofer JR. Sero-epidemiological analysis of the risk of virus infections for childhood leukaemia. *Int J Cancer*. 1996;65(5):584-90. [https://doi.org/10.1002/\(SICI\)1097-0215\(19960301\)65:5<584::AID-IJC5>3.0.CO;2-Z](https://doi.org/10.1002/(SICI)1097-0215(19960301)65:5<584::AID-IJC5>3.0.CO;2-Z)
179. Steininger C, Rassenti LZ, Vanura K, Eigenberger K, Jäger U, Kipps TJ, Mannhalter C, Stiglbauer S, Popow-Kraupp T. Relative seroprevalence of human herpes viruses in patients with chronic lymphocytic leukaemia. *Eur J Clin Invest*. 2009;39(6):497-506. <https://doi.org/10.1111/j.1365-2362.2009.02131.x> PMID:19490058 PMCid:PMC3709071
180. Faten N, Agnès GD, Nadia BF, Nabil AB, Monia Z, Abderrahim K, Henri A, Salma F, Mahjoub A. Quantitative analysis of human herpesvirus-6 genome in blood and bone marrow samples from Tunisian patients with acute leukemia: a follow-up study. *Infect Agent Cancer*. 2012;7(1):31. <https://doi.org/10.1186/1750-9378-7-31> PMID:23146098 PMCid:PMC3527176
181. Hermouet S, Sutton CA, Rose TM, Greenblatt RJ, Corre I, Garand R, Neves AM, Bataille R, Casey JW. Qualitative and quantitative analysis of human herpesviruses in chronic and acute B cell lymphocytic leukemia and in multiple myeloma. *Leukemia*. 2003;17(1):185-95. <https://doi.org/10.1038/sj.leu.2402748> PMID:12529677
182. Krueger GR, Kudlimay D, Ramon A, Klueppelberg U, Schumacher K. Demonstration of active and latent Epstein-Barr virus and human herpesvirus-6 infections in bone marrow cells of patients with myelodysplasia and chronic myeloproliferative diseases. *In Vivo*. 1994;8(4):533-42. PMID:7893980
183. Morales-Sánchez A, Pompa-Mera EN, Fajardo-Gutiérrez A, Alvarez-Rodríguez FJ, Bekker-Méndez VC, Flores-Chapa Jde D, Flores-Lujano J, Jiménez-Hernández E, Pe-alozza-González JG, Rodríguez-Zepeda MC, Torres-Nava JR, Velázquez-Avi-a MM, Amador-Sánchez R, Alvarado-Ibarra M, Reyes-Zepeda N, Espinosa-Elizondo RM, Pérez-Saldivar ML, Nú-ez-Enríquez JC, Mejía-Aranguré JM, Fuentes-Pananá EM. EBV, HCMV, HHV6, and HHV7 screening in bone marrow samples from children with acute lymphoblastic leukemia. *Biomed Res Int*. 2014;2014:548097. <https://doi.org/10.1155/2014/548097> PMID:25309913 PMCid:PMC4189769
184. Krueger GR, Klueppelberg U, Hoffmann A, Ablashi DV. Clinical correlates of infection with human herpesvirus-6. *In Vivo*. 1994;8(4):457-85. PMID:7893974
185. Krueger GR, Ferrer Argote V. A unifying concept of viral immunopathogenesis of proliferative and aroliferative diseases (working hypothesis). *In Vivo*. 1994;8(4):493-9. PMID:7893976