

# Expression of MDM2 mRNA, MDM2, P53 and P16 Proteins in Urothelial Lesions in the View of the WHO 4<sup>th</sup> Edition Guidelines as a Molecular Insight towards Personalized Medicine

Olfat Hammam<sup>1\*</sup>, Mona Magdy<sup>1</sup>, Mohamed Badawy<sup>2</sup>, Khalid Al Osili<sup>2</sup>, Amr El Kholy<sup>2</sup>, Tarek El LeitHy<sup>2</sup>

<sup>1</sup>Department of Pathology, Theodor Bilharz Research Institute (TBRI), Imbaba, Giza, Egypt; <sup>2</sup>Department of Urology, Theodor Bilharz Research Institute (TBRI), Imbaba, Giza, Egypt

## Abstract

**Citation:** Hammam O, Magdy M, Badawy M, Al Osili K, El Kholy A, El LeitHy T. Expression of MDM2 mRNA, MDM2, P53 and P16 Proteins in Urothelial Lesions in the View of the WHO 4th Edition Guidelines as a Molecular Insight towards Personalized Medicine. Open Access Maced J Med Sci. 2017 Aug 15; 5(5):578-586. <https://doi.org/10.3889/oamjms.2017.100>

**Keywords:** P53; MDM2mRNA; P16; urothelial; grade; bilharzia.

**\*Correspondence:** Professor Dr Olfat Hammam, Pathology Department, Theodor Bilharz Research Institute, El-Nile Street, Warrak El-Hadar, Imbaba P.O. Box 30, Giza 12411, Egypt. Mobile number: 202 01001815577. E-mail: totoali1@hotmail.com

Received: 18-Mar-2017; Revised: 15-May-2017; Accepted: 19-May-2017; Online first: 05-Aug-2017

**Copyright:** © 2017 Olfat Hammam, Mona Magdy, Mohamed Badawy, Khalid Al Osili, Amr El Kholy, Tarek El LeitHy. This is an open-access article distributed under the terms of the Creative Commons Attribution-NonCommercial 4.0 International License (CC BY-NC 4.0).

**Funding:** This research did not receive any financial support.

**Competing Interests:** The authors have declared that no competing interests exist.

**AIM:** Here we imposed a multimarker molecular panel composed of P53, MDM2 protein & mRNA & P16 with the identification of sensitive and specific cut offs among the Egyptian urothelial carcinomas bilharzial or not emphasize the pathological and molecular classifications, pathways and prognosis as a privilege for adjuvant therapy.

**METHODS:** Three hundred and ten urothelial lesions were pathologically evaluated and grouped as follows: 50 chronic cystitis as benign, 240 urothelial carcinomas and 20 normal bladder tissue as a control. Immunohistochemistry for MDM Protein, P16 & p53 and In Situ Hybridization for MDM2mRNA were done.

**RESULTS:** MDM2mRNA overexpression correlated with low grade low stage non invasive tumors, while P53 > 40% & p16 < 10% cut offs correlated with high grade high stage invasive carcinomas & bilharzial tumors (P=0.000).

**CONCLUSION:** MDM2mRNA overexpression vs. P53 > 40% & P16 < 10% constitutes a multimarker molecular panel with significant cut offs, proved to distinguish low grade, low stage non invasive urothelial carcinomas (MDM2mRNA overexpression, P53 < 40%, P16 > 10%) from high grade, high stage invasive urothelial carcinomas (with p53 > 40, p16 < 10% & absent MDM2mRNA overexpression). Combined P53 > 40 & p16 < 10%, together with the histopathological features can distinguish in situ urothelial lesions from dysplastic and atypical lesions.

## Introduction

Bladder cancer is the 7th most common cancer worldwide [1] and constitutes 30.3% of all cancers in Egypt [2]. Grading of urothelial carcinomas is important in noninvasive disease. Most of the invasive carcinomas are high grade [3].

The 4th edition 2016 WHO guidelines continue to recommend the application of the grading classification of urothelial lesions ISUP 1997 [4] into two major categories as non-invasive group (whether papillary or flat) or invasive group with several advantages, among them are the definite definition of a high grade lesions group which has high risk of progression and can be candidates for adjuvant

therapy, with elimination of diagnostic ambiguity particularly grade 2 lesions [3]. Also whereas low-grade tumours are almost noninvasive (Ta), high-grade tumours are classified based on muscle invasion as Non-Muscle Invasive Bladder cancer (NMIBC; Tis, Ta, T1) or Muscle Invasive Bladder cancer (MIBC; ≥ T2) [5].

Since molecular alterations differ markedly between low and high grade, invasive and not invasive tumours [3], two distinct pathogenic molecular alterations documented: low-grade pathway which involves mutations in FGFR3, PIK3CA, and inactivating KDM6A mutations, whereas high-grade muscle-invasive tumours pathway shows TP53 and RB1 alterations [6].

Moreover, with the use of whole genome mRNA expression profiling, three intrinsic unique molecular subtypes of muscle invasive bladder carcinomas documented, strikingly recapitulating molecular subtypes of breast cancer as basal type, luminal type and p53-like muscle-invasive type tumours. The p53-like tumours are resistant to neoadjuvant chemotherapy. Thus, all chemoresistant tumours adopted a p53-like phenotype after therapy [7-8].

The p53 protein is encoded by the TP53 tumor-suppressor gene which located at 17p13.1 [9]. It inhibits cell-cycle progression at the G1-S transition. Altered p53 expression increases progressively from normal urothelium to in situ urothelial carcinomas (flat or papillary) to not muscle-invasive, to muscle-invasive disease with metastatic lymph nodes [8, 10]. P53 used for urothelial carcinoma stratification [8, 11] however alone is not sufficient to suggest p53 alterations and can't be used as a prognostic marker in urothelial carcinomas or chemotherapeutic response stratification [8, 12]. Therefore, a combination of p53 with other molecular markers improves risk stratification [8, 12].

Human MDM2 gene located at 12q13-14 [13]. It contains a p53 binding domain. MDM2 protein is an oncoprotein has a negative regulating effect on p53 [14]. MDM2 gene amplification is infrequent in bladder cancer despite elevated MDM2 protein levels [15]. MDM2 expression correlates with tumour grade and recurrence in superficial bladder cancer. Acquisition of MDM2 gene expression significantly associated with high tumour grade [16, 17]. Amplification of MDM2 may increase sensitivity to MDM2 antagonists [18]. In addition, the absence of MDM2mRNA was reported in bilharzial tumours indicating their aggressiveness and poor prognosis [18].

P16 is an early marker for malignant transformation in human cancers [19, 20]. P16 is a TP53-related kinase that controls cell cycle progression. P16 gene locates at 9p21, which is a major site for deletions in bladder cancer. The p16 gene abnormalities are predominant in schistosomal SQCC than conventional TCC. P16 and TP53 show mutually complementary role in the pathogenesis of bladder cancer [21, 22]. Loss of p16 expression is significantly associated with high-grade tumours and reduced progression-free survival [21], particularly in early stage bladder cancers [22].

Moreover, mutations of genes associated with cell cycle control were detected in schistosomal bladder cancers [23]. Early deletion of P16 gene occurs in schistosomal TCC than schistosomal SCC [24]. This is due to chromosomal instability induced by bilharzial irritation [23-26]. Molecular subtyping of bladder cancer is a tool for personalized medicine [8]. No molecular biomarkers are widely used for clinical outcome prediction [21].

Our study aimed at establishing an applicable multimer molecular panel of MDM2 (mRNA & Protein), P16 and p53, with sensitive and specific cut offs, to stratify Egyptian urothelial carcinomas according to their molecular pathways within the context of WHO 2016 grade and stage classification, and to predict tumor progression & prognosis, particularly for high grade carcinomas, as a privilege for adjuvant therapy.

## Patients and Methods

The study held on 310 urothelial lesions obtained from archival paraffin blocks at pathology department TBRI (2012-2016) and grouped as follows: 50 chronic cystitis as benign, 240 urothelial carcinomas and 20 normal bladder tissue as a control.

### Immunohistochemistry

Immunohistochemistry was performed using antihuman monoclonal MDM2 & P53 antibodies (Dako, Glostrup, Denmark) at the working dilution of 1:100. P16 monoclonal antibody (Santa Cruz Biotechnology, Dallas, CA, USA) was used at 1:150 dilutions.

### In Situ Hybridization for MDM2mRNA

Paraffin-embedded sections were deparaffinized and treated with prehybridization mixture. ISH was performed overnight. Human MDM2 cDNA probe kindly provided by Bruno Voss (Professional Associations' Research Institute for Occupational Medicine BGFA, Ruhr-University, Bochum, Germany) was used. The reaction signals were amplified by Tyramide signal amplification (TSA) kit (Invitrogen, Grand Island, NY). Counterstaining was done. Slides washed in PBS buffer and kept moist with glycerol.

### Assessment of MDM2 mRNA in Situ Hybridization, MDM2 protein, p16 & p53 immunostaining

- P16 was considered positive when at least one atypical cell with strong nuclear expression with or without cytoplasmic positivity, independently of the percentage of positive cells. Cases with weak or absent nuclear expression were considered negative [27].
- Only intense p53 and MDM2 nuclear staining were counted. P53 was considered positive at > 5% cut off [28].

- MDM2 was considered positive at > 20% cut off [29, 30].
- MDM2 mRNA was scored as follows: + normal or weak expression, ++ moderate expression, +++ overexpression. Mild (+) score was excluded. Moderate (++) and overexpression (+++) scores only were considered.

### Statistical analysis

Statistical evaluation was performed with SPSS (version 20, IBM, Chicago, IL, USA). The correlation between expressions and clinicopathological parameters was assessed using Spearman's correlation test. Differences between proportions studied using Chi square test were deemed significant at the level of  $p < 0.05$ . Sensitivity, specificity, false positive & negative rates were calculated.

## Results

MDM2 protein was expressed in 47.1% of malignant cases. All control and benign cases were

negative. Similarly, MDM2mRNA was expressed in all malignant cases with negative expression in both benign and control cases ( $P < 0.000$ ) (Table 1 and 2; Figs. 1 & 2).

P53 showed positive expression in 50% of benign cases and all malignant cases ( $P < 0.01$ ). Surprisingly most of the non-neoplastic cases showed rather a variable expression up to 40%. However, none expressed P53 > 40% in comparison with urothelial carcinomas ( $P < 0.001$ ).

P16 exhibited positivity in 40% of the control cases ( $N = 4$ ), 32% of the cystitis cases (16% of bilharzial cystitis & 16% of non bilharzial cystitis) and in all malignant cases ( $P < 0.001$ ). All cystitis cases expressed >10% of P16. Significantly in contrast, non of cystitis cases showed p16 < 10% expression ( $p < 0.000$ ).

MDM2 mRNA score was significantly inversely correlated with the MDM2 protein expression, P53 expression & score, as well as P16 score ( $p < 0.001$ ). In contrast, MDM2 protein expression was significantly directly correlated with P53 expression & score, as well as P16 score. Moreover, P53 expression & score were directly correlated with each other, with the P16 score and with MDM2 protein expression, however inversely correlated with MDM2 mRNA score (Tables 2 and 3).

**Table 1: MDM2 protein, p53 & p16 expression in relation to clinicopathological features**

Group	MDM2 protein				P53			P16			
	No.	Negative	Positive	Significance	Negative (<5%)	Positive (>5%)	Significance	Negative	<10%	>10%	Significance
Control	20	20 100%	0 0%		10 50%	10 50%		16 60%	0 0%	4 40%	
Malignant	240	127 52.9%	113 47.1%	$P = 0.001^{**}$	0 0%	240 100%	$P = 0.001^{**}$	0 0%	167 69.6%	73 30.4%	$P = 0.001^{**}$
Benign	50	50 100%	0 %		0 0%	50 100%		42 84%	0 0%	8 16%	
Tumor type											
TCC	154	81 52.6%	73 47.4%	$P = 0.501$	44 28.6%	110 71.4%	$P = 0.001^{**}$	0 0%	93 60.4%	61 39.6%	$P = 0.001^{**}$
SQCC	86	46 53.5%	40 46.5%		48 55.8%	38 44.2%		0 0%	74 86.0%	12 14.0%	
Invasiveness											
Non invasive (Ta)	46	22 47.8%	24 52.2%	$P = 0.001^{**}$	33 71.7%	13 28.3%	$P = 0.001^{**}$	0 0%	16 34.8%	30 65.5%	$P = 0.001^{**}$
Invasive	194	105 54.1%	89 45.9%		59 30.4%	135 69.6%		0 0%	151 77.8%	43 22.2%	
Stage											
T1	47	22 46.8%	25 53.2%		38 80.9%	9 19.1%		0 0%	17 36.2%	30 63.8%	
T2	107	59 55.1%	48 44.9%	$P = 0.000^{**}$	6 5.6%	101 94.4%	$P = 0.001^{**}$	0 0%	76 71.0%	31 29.0%	$P = 0.001^{**}$
T3	86	46 53.5%	40 46.5%		48 55.8%	38 44.2%		0 0%	74 86.0%	12 14.0%	
Grade											
Low grade (G1)	28	11 39.3%	17 60.7%	$P = 0.01^{**}$	22 78.6%	6 21.4%	$P = 0.001^{**}$	0 0%	10 35.7%	18 64.3%	$P = 0.001^{**}$
High grade (G2-G3)	212	116 54.7%	96 45.3%		70 33%	142 67%		0 0%	157 74%	55 26%	
Bilharzia associated tumors											
Bilharzial	164	99 60.4%	65 39.6%	$P = 0.001^{**}$	75 45.7%	89 54.4%	$P = 0.0010^{**}$	0 0%	119 72.6%	45 27.4%	$P = 0.094$
Non bilharzial	76	28 36.8%	48 63.2%		17 22.4%	59 77.6%		0 0%	48 27.4%	28 26.8%	

\*\*Significance differences between groups by Chi Square Test ( $p < 0.01$ ); \* Significance differences between groups by Chi Square Test ( $p < 0.05$ ).

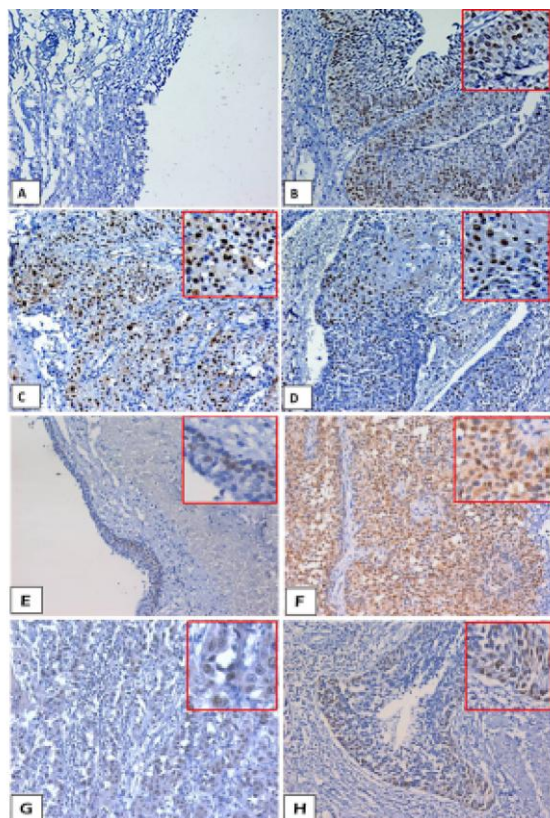


Figure 1: Immunohistochemistry expression of the MDM2 protein, P53 & P16. (IHC, DAB, ×200). (A) Control case showing negative expression of MDM2 antibody; (B) High grade (G2) invasive papillary urothelial carcinoma, showing P53 > 40% nuclear expression, (in focus); (C) High grade (G3) invasive urothelial carcinoma showing P53 > 40% nuclear expression in the squamous cells (in focus); (D) High grade (G2) SQCC showing moderate number of nuclei positive for MDM2 antibody in the squamous cells (in focus); (E) Control case expressing p16 antibody (in focus); (F) Low grade papillary urothelial carcinoma, showing large number (> 10%) of nuclei positive for p16 antibody, (in focus); (G) High grade (G3) invasive urothelial carcinoma showing few (< 10%) of nuclei positive for p16 antibody in the squamous cells; (H) High grade (G2) showing positivity (> 20%) for MDM2 antibody

TCC showed significantly higher P53 expression (71.4%) in comparison to SQCC (44.2%). Also, TCC significantly showed MDM2 mRNA overexpression in 27.9% in contrast to 11.9% of SQCC (P<0.01). Nevertheless, MDM2 protein showed no significant difference. On the other hand, 86% of SQCC showed significant P16<10% expression in contrast to only 14.5% for P16>10%.

All urothelial carcinomas regardless their types expressed MDM2 mRNA. Overall, bilharzial association with tumours significantly inversely correlated with the MDM2 mRNA score (P< 0.001). In contrast, it showed significant direct correlation with MDM2 protein & P53 positivity, P53 & P16 scoring, tumour stage, grade & invasion (P<0.001). Nevertheless, 32.1% of bilharzial associated TCC significantly overexpressed MDM2 mRNA in contrast to 23.7% of the non-bilharzial associated TCC, and to only 11.6% of SQCC (P < 0.001). On the other hand,

63.2% of the non bilharzial associated tumours showed higher MDM2 protein expression in comparison with 39.6% for the bilharzial associated tumours whether TCC or SQCC (Figs 1&2&3). Furthermore, 91% of bilharzial associated TCC significantly expressed > 40% of P53 in comparison to 71.1% for the no bilharzial associated TCC, and to only 62.8% for SQCC. On the other hand, 86% of the SQCC (all are bilharzial) showed P16<10% in comparison to none bilharzial TCC (63.2%).

Table 2: MDM2mRNA expression regarding clinicopathological features

	MDM2 mRNA				Significance
	No.	Negative (-/normal / +1)	Moderate (+2)	Over expression (+3)	
Groups					
Control	20	N = 10 100%	N = 0 0%	N = 0 0%	
Malignant	240	N = 74 30.8%	N = 113 47.1%	N = 53 22.1%	P = 0.001**
Benign	50	N = 50 100%	N = 0 0%	N = 0 0%	
Tumor type					
TCC	154	N = 42 27.3%	N = 69 44.8%	N = 43 27.9%	P = 0.012*
SQCC	86	N = 32 37.2%	N = 44 51.2%	N = 10 11.6%	
Invasiveness					
Non invasive (Ta)	46	N = 2 4.3%	N = 17 37.0%	N = 27 58.7%	P = 0.001**
Invasive	194	N = 72 37.1%	N = 96 49.5%	N = 26 13.4%	
Stage					
T1	47	N = 0 0%	N = 20 42.6%	N = 27 57.4%	
T2	107	N = 42 39.3%	N = 49 45.8%	N = 16 15.0%	P = 0.001**
T3	86	N = 32 37.2%	N = 44 51.2%	N = 10 11.6%	
Grade					
Low grade (G1)	28	N = 2 7.1%	N = 8 28.6%	N = 18 64.3%	P = 0.001**
High grade (G2-G3)	126	N = 72 34%	N = 105 49.5%	N = 35 16.5%	
Bilharzia associated tumors					
Bilharzial	164	N = 46 28.0%	N = 83 50.6%	N = 35 21.3%	P = 0.247
Non bilharzial	76	28 36.8%	30 39.5%	18 23.7%	
MDM2 protein expression					
Negative	187	N = 108 79.10%	N = 51 45.1%	N = 28 52.8%	P = 0.001**
Positive	113	N = 26 19.40%	N = 62 54.9%	N = 25 47.2%	
P53 score					
>5%-10%	50	N = 39 78%	N = 4 8%	N = 7 14%	
>10%-20%	21	N = 12 %57.1	N = 4 19%	N = 5 23.8%	P = 0.001*
>20%-40%	50	N = 21 42%	N = 20 40%	N = 9 18%	
P53>40%	179	N = 62 34.6%	N = 85 47.5%	N = 32 17.9%	
P16 score					
<10%	167	57 77%	N = 83 73.5%	N = 27 50.9%	P = 0.001**
>10%	85	N = 29 43%	N = 30 26.5%	N = 26 49.1%	

\*\*Significance differences between groups by Chi Square Test (p < 0.01); \* Significance differences between groups by Chi Square Test (p < 0.05).

Tumor invasion significantly inversely correlated with the MDM2 mRNA score. Conversely, it directly correlated with the MDM2 protein & P53 positivity, P53 & P16 scoring, tumor stage & grade (P < 0.001). About 58% of non invasive urothelial carcinomas showed MDM2 mRNA overexpression in comparison to only 13.4% of the invasive ones.

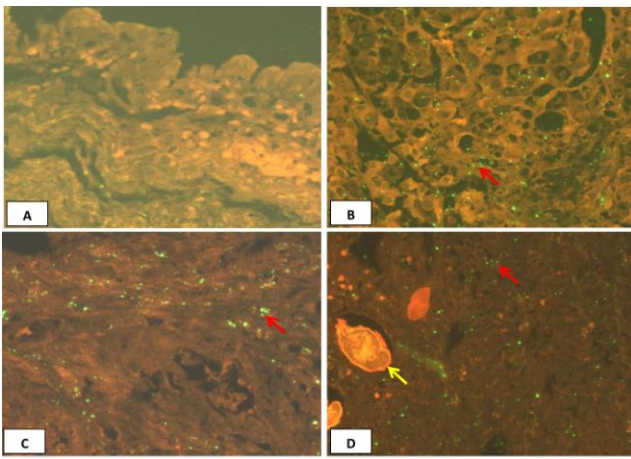


Figure 2. ISH staining for MDM2mRNA. (A–D) ISH; x625. (A) Normal expression in a control case, showing negative expression of MDM2 mRNA in the urothelium. (B) Low grade papillary, noninvasive (G1) UC showing (+++) green signal for MDM2mRNA (overexpression) in a urothelial cells (red arrow). (C) High grade SQCC G2-3 showing a moderate (++) green signal for MDM2 mRNA in urothelial cells (red arrow). (D) High grade invasive UC associated with bilharziasis showing mild (+) green signal for MDM2 mRNA in a urothelial cells (red arrow), bilharzial ova (yellow arrow)

On the contrary, only 15% of the non invasive carcinomas showed P53 > 40% in comparison to 85% of the invasive carcinomas. Moreover, 65.2% of the non invasive carcinomas showed P16 > 10%, while in contrast 77.8% of the invasive carcinomas expressed < 10% of P16 (P < 0.001) (Fig. 3 and 4).

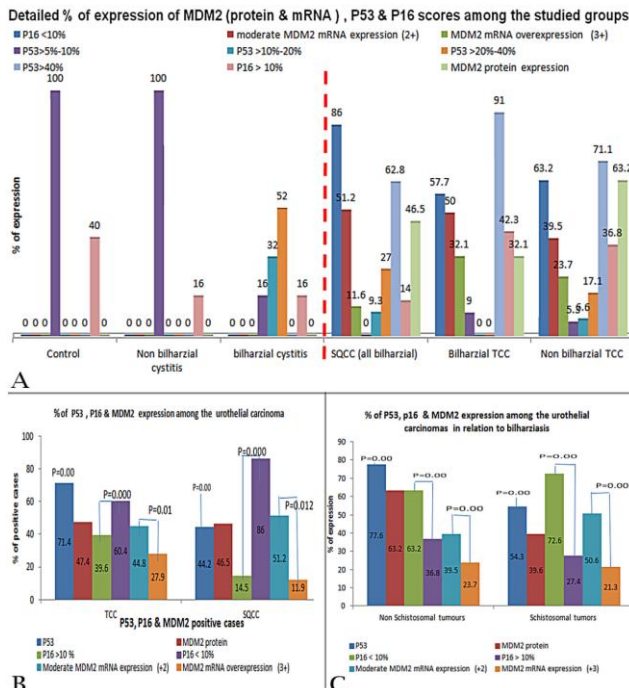


Figure 3: Percentage of expression of MDM2 (protein & mRNA), P53 & P16 scores. (A) Among the studied groups; (B) Regarding tumour type; (C) Regarding bilharzia association in tumours

Since the majority of our cases are TUR biopsies, T3 were excluded. Overall, tumour stage is significantly inversely correlated with the MDM2

mRNA score (P < 0.001). In contrast, it directly correlated with MDM2 protein & P53 positivity, P53 & P16 scoring, tumor stage & grade (P < 0.001) (Figures 3 and 6B). The majority of T1 carcinomas showed MDM2 mRNA overexpression in contrast to 15% of T2 tumours. Conversely, T2 tumours showed highly significant P53 > 40% expression in 55%, in contrast to only 14.4%. Furthermore, 63.8% of T1 tumors exhibited P16 <10%, while in contrast 71% of T2 carcinomas showed P16 < 10%.

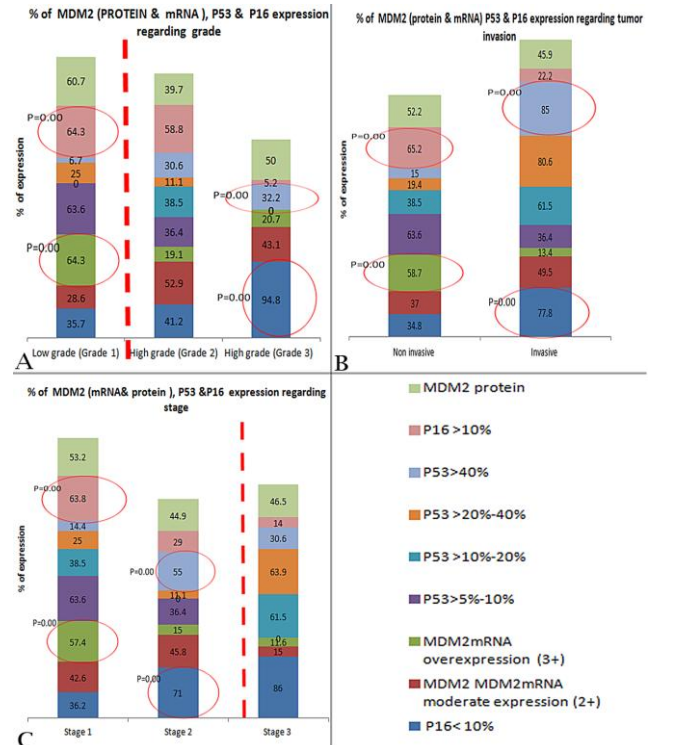


Figure 4: Percentage of expression of MDM2 (protein & mRNA), P53 & P16 scores. (A) Regarding tumour grade; (B) Regarding tumour stage; (C) Regarding invasion

We considered G1 tumors as low grade while G2 & G3 tumors as high grade. Grade is significantly inversely correlated with the MDM2 mRNA score, while directly correlated with the MDM2 protein & P53 positivity, P53 & P16 scoring, tumor stage & grade (P < 0.001). Majority of G1 low grade carcinomas (64.3%) showed MDM2 mRNA overexpression in contrast to the G2 & G3 high grade tumors with only 19.1% & 20.7% respectively (P < 0.001). Conversely, G2 & G3 showed significant expression of P53 > 40% in 30.6% & 32.2% respectively, in comparison to only 6.7% in T1 tumors (P < 0.05). Also, 35.7% of low grade tumors exhibited P16 < 10% in contrast to 94.8% in G3 high grade tumors (P < 0.001) (Figs. 3 and 4).

Sensitivity & specificity of the chosen cut off regarding the tumour grade as a milestone for the WHO 4th edition of urothelial lesions: From all above, using P53 > 40% & P16 < 10% against MDM2 mRNA overexpression (++) as cut offs can stratify urothelial carcinomas, suggest the invasive status, stage & grade and predict their pathways & progression.

**Table 3: Non-parametric correlation (Spearman's rho test) & Chi Square Test among the studied markers (N = 310)**

	Correlation coefficient Sig. (2 tailed)					Pearson Chi Square Test				
	P16 score	MDM2 mRNA score	MDM2 protein positivity	P53 score	P53 positivity	P16 score	MDM2 mRNA score	MDM2 protein	P53 score	P53 positivity
P16 score	1	-0.283-**-0.000	0.060 0.296	0.259** 0.000	0.176** 0.002	1	P=0.004*	P=0.000**	P=0.000**	P=0.000**
MDM2 mRNA score	-0.283-**-0.000	1	-0.212-**-0.000	-0.602-**-0.000	-0.437-**-0.000	P=0.000**	1	P=0.000**	P=0.006*	P=0.000**
MDM2 protein positivity	0.060 0.296	-0.212-**-0.000	1	0.321** 0.000	0.334** 0.000	P=0.000**	P=0.000**	1	P=0.000**	P=0.000**
P53 score	0.259** 0.000	-0.602-**-0.000	0.321** 0.000	1	0.505** 0.000	P=0.000**	P=0.000**	P=0.000**	1	P=0.000**
P53 positivity	0.176** 0.002	-0.437-**-0.000	0.334** 0.000	0.505** 0.000	1	P=0.000**	P=0.000**	P=0.000**	P=0.000**	1

\*\* : Correlation is significant at 0.01 level (2-tailed) by both tests; \* : Correlation is significant at 0.05 level (2-tailed) by both tests; - : Inverse on parametric Spearman's rho test's correlation coefficient.

Both P53 positivity & scoring showed near sensitivity & specificity values. However, P53>40% cut off showed better sensitivity (77.9%) but less specificity (88.7%) than 66.7% sensitivity & 93.8% specificity for positivity P53 without scoring. Moreover, P53>40% cut off showed an advantage of less false positive rate (22.1%) over 33.3% for P53 positivity only.

On the other hand, MDM2 mRNA overexpression shows higher sensitivity (78.5%) in contrast to MDM2 protein positivity (45%). Moreover, MDM2 mRNA overexpression showed higher specificity (98.40 %) with lower false positive rate (12.5%) & lower false negative rate (1.6%) against 81.80%, 55% & 18.20% for specificity, false positive & false negative rates of MDM2 protein positivity respectively. P16 < 10 cut off showed (78.50%) sensitivity, (42.40%) specificity, (26.10%) false positive rate and (57.60%) false negative rate.

## Discussion

The challenging task in molecular pathology analysis is to establish the clinical relevance of molecular types beyond the histopathologic appearance [31]. Bladder cancer shouldn't be managed only according the clinical or pathological features. The molecular approach in combination with the clinicopathological features is mandatory. Nevertheless, a routine use of a well-established molecular approach (as in breast cancer) still not identified or recommended [32]. And due to tumour heterogeneity, no single marker can reflect the tumour biology. Therefore, combined biomarkers panel improves predictive and prognostic accuracy in order to get a personalized treatment approach [33].

Here we imposed a multimarker molecular panel composed of P53, MDM2 protein & mRNA & P16 with the identification of sensitive and specific cut

offs among the Egyptian urothelial carcinomas bilharzial or not. The target is to emphasize their pathological classification according to the WHO 4th edition into low vs. high grade particularly in ambiguous cases and to facilitate prediction of potential course, pathways & prognosis.

In our study, all non-neoplastic cases showed neither MDM2 protein nor MDM2mRNA expression. Similarly, El-Abd et al., 2008 [18] showed the absence of MDM2mRNA in controls and benign cases. However, our study showed that the overexpression of MDM2 mRNA significantly indicated low-grade low stage and rather non invasive tumours with sensitivity (87.5 %) and high specificity (98.4 %), in contrast to high-grade, high stage invasive tumours. This came similar to Schlott et al., 2004 [34] in which MDM2mRNA was significantly 5-folds lower in advanced high grade, high stage urothelial carcinomas. Moreover, we showed that MDM2 mRNA score was inversely correlated with the MDM2 protein expression. Similarly, it was mentioned that MDM2 gene amplification is infrequent in bladder cancer despite elevated MDM2 protein levels [34]. It is amplified in 10% of urothelial carcinomas [15].

Furthermore, we that MDM2 mRNA score was significantly inversely correlated with the MDM2 protein expression, P53 expression & score, as well as P16 score. This may be due to that MDM2 amplification doesn't occur with p53 mutations within the same tumour, indicating that carcinogenesis results from MDM2 amplification alone [34]. This also came along with Pfister et al., 2000 [35] who stated that tumours overexpressing MDM2 but not p53 are rarely of high grade. In the same context, Uchida et al., 2002 [36] showed that co-expression of p53 and MDM2 with MDM2 overexpression is associated with favourable prognosis in invasive carcinomas. This is due to loss of MDM2 inhibition and/or DNA damage resulting in increase of wild-type of p53 at a level not sufficient for immunohistochemistry detection [35]. However if p53 gene become mutated, tumor will show higher grade, worse prognosis, higher recurrence rate and shorter progression time & survival in contrast to wild type non-mutant P53 [22,

37].

P53 was significantly expressed in high grade, high stage, invasive tumours ( $P < 0.01$ ) in our study. Furthermore, only P53>40% cut off was found significantly directly correlated with tumour grade, stage & invasiveness ( $P < 0.001$ ) with sensitivity (77.9%), specificity (88.7%), false positive rate (22.1%) & (11.3%) false negative rate. Coming along, it has been reported that p53 can help to stratify patients into different risk groups regarding progression, but not overall survival [22, 38]. Mutant TP53 prolongs survival of cells with established genetic defects, allowing them to become more unstable and aggressive [22].

Moreover, surprisingly 50% of benign cases showed rather a variable expression of up to 40%, however none expressed P53>40%. Thus P53>40 cut off together with the cellular morphology can identify and distinguish the in situ urothelial lesions versus otherwise urothelial atypia or dysplasia. This came along with Cheng et al., 2014 [22] since the p53 nuclear expression is not always indicative of TP53 mutations, and not all TP53 mutations result in protein accumulation [22].

Immunohistochemistry relies on the accumulation of p53 protein due to prolonged half-life of cells. The half-life of wild type p53 is estimated between 20 and 30 min, whereas mutation there is decreased degradation of mutant p53 which has a longer half life up to 24 hours [22, 39]. A TP53 mutation is a late event in carcinogenesis leads to loss of the remaining wild type allele and inactivation of growth control function [22, 39] resulting in an altered protein resistant to degradation, and shows nuclear accumulation, altered DNA repair, cancer development and progression [31, 41].

The low p16 expression is associated with tumorigenesis [23, 42, 43]. Our study interestingly showed p16<10% expression in benign cases ( $P < 0.001$ ). Similarly, the possibility of P16 gene deletion in some benign and control cases was reported [25]. Nevertheless, the absence of p16 was also mentioned in benign urothelium [44]. Therefore, combined P16<10% and P53>40% together with cellular morphology can distinguish in situ urothelial lesions versus otherwise atypia or dysplasia. P16<10% cut off was significant in high grade, high stage, invasive tumours with (78.50%) sensitivity and (42.40%) specificity. Emphasis on the value of low p16 in the early diagnosis and prognosis of early stage bladder cancer as it indicates poor progression and recurrence free survival rates were reported [21,23,45].

P16 expression in bilharzial SQCC in comparison to non-bilharzial TCC was mentioned [22] and showed similarity to our results however with no significance. Additionally, we showed that bilharziasis significantly directly correlated with MDM2 protein &

P53 positivity, P53 & P16 scoring, stage, grade & invasion and exhibited predominant P16<10% in tumours, while inversely correlated with MDM2 mRNA score, indicating aggressiveness and poor prognosis [18, 23].

In conclusion, MDM2 mRNA overexpression vs P53>40% & P16<10% constitutes a multimarker molecular panel with significant cut offs, proved to distinguish low grade, low stage non invasive urothelial carcinomas (MDM2 mRNA overexpression, P53<40%, P16>10%) from high grade, high stage invasive urothelial carcinomas (with p53>40, p16<10% & absent MDM2mRNA overexpression). Also, combined P53>40 & p16<10%, together with the histopathological features can distinguish in situ urothelial lesions from dysplastic and other proliferative urothelial lesions.

## Acknowledgment

Authors acknowledge and thank the technicians in the pathology department Theodor Bilharz Research Institute for their efforts and help in slides preparation and handling.

## References

1. El-Bolkainy MN. Topographic pathology of cancer 2nd. Edition, chapter 7, AL Ahram Press, Cairo, 2000: 57-63.
2. Ferlay J, Bray F, Pisani P, Parkin DM. International Agency for Research on Cancer (IARC). Cancer Incidence, Mortality and Prevalence Worldwide. GLOBOCAN . 2002: Cancer Base No. 5, version 2.0. Lyon, France: IARC Press, 2004.
3. Humphrey AP, Moch H, Cubilla LA, Ulbright MT, Reuter EV. 2016 WHO Classification of Tumours of the Urinary System and Male Genital Organs Part B: Prostate and Bladder Tumours. *European Urology*. 2016; 70 (1):106-119. <https://doi.org/10.1016/j.eururo.2016.02.028> PMID:26996659
4. Epstein JI, Amin MB, Reuter VR, Mostofi FK. The World Health Organization/International Society of Urological Pathology consensus classification of urothelial (transitional cell) neoplasms of the urinary bladder. *Bladder Consensus Conference Committee. Am J Surg Pathol*. 1998; 22:1435-48. <https://doi.org/10.1097/00000478-199812000-00001> PMID:9850170
5. Netto GJ. Molecular biomarkers in urothelial carcinoma of the bladder: are we there yet? *Nat Rev Urol*. 2011; 9: 41-51. <https://doi.org/10.1038/nrurol.2011.193> PMID:22158597
6. Hsu I, Vitkus S, Da J & Yeh S. Role of oestrogen receptors in bladder cancer development. *Nature Reviews Urology*. 2013; 10: 317-326. <https://doi.org/10.1038/nrurol.2013.53> PMID:23588401
7. Damrauer SJ, Hoadley AK, Chism DD, Fan C, Tiganelli JC, Wobker ES, Yeh JJ, Milowsky IM, Iyer G, Parker SJ, and Kim WY. Intrinsic subtypes of high-grade bladder cancer reflect the hallmarks of breast cancer biology. *Proc Natl Acad Sci USA*. 2014;111(8): 3110-3115. <https://doi.org/10.1073/pnas.1318376111> PMID:24520177 PMCID:PMC3939870

8. Choi W, Porten S, Kim S, Willis D, Plimack E, Hoffman-Censits J, et al. Identification of distinct basal and luminal subtypes of muscle-invasive bladder cancer with different sensitivities to frontline chemotherapy. *Cancer Cell*. 2014; 25: 152–165. <https://doi.org/10.1016/j.ccr.2014.01.009> PMID:24525232 PMCid:PMC4011497
9. Mitra PA. Molecular sub stratification of bladder cancer: moving towards individualized patient management. *Ther Adv Urol*. 2016; 8(3): 215–233. <https://doi.org/10.1177/17562872166638981> PMID:27247631 PMCid:PMC4872193
10. Mitra A, Cote R. Searching for novel therapeutics and targets: insights from clinical trials. *Urol Oncol*. 2007; 25: 341–343. <https://doi.org/10.1016/j.urolonc.2007.05.004> PMID:17628305
11. Mitra A, Datar R, Cote R. Molecular pathways in invasive bladder cancer: new insights into mechanisms, progression, and target identification *Clin Oncol* . 2006; 24: 5552–5564. <https://doi.org/10.1200/JCO.2006.08.2073> PMID:17158541
12. Malats N, Bustos A, Nascimento C, Fernandez F, Rivas M, Puente D, et al. p53 as a prognostic marker for bladder cancer: a meta-analysis and review. *Lancet Oncol*. 2005; 6: 678–686. [https://doi.org/10.1016/S1470-2045\(05\)70315-6](https://doi.org/10.1016/S1470-2045(05)70315-6)
13. Shariat SF, Chromecki TF, Cha EK, Karakiewicz PI, Sun M, Fradet Y, Isbarn H, Scherr DS, Bastian PJ, Pummer K, Fajkovic H, Sagalowsky AI, Ashfaq R, Doblinger M, Cote RJ, Lotan Y. Risk stratification of organ confined bladder cancer after radical cystectomy using cell cycle related biomarkers. *J Urol*. 2012;187(2):457-62. <https://doi.org/10.1016/j.juro.2011.10.031> PMID:22177145
14. Oliner JD, Pietenpol JA, Thiagalingam S, Gyuris J, Kinzler KW, Vogelstein B. Oncoprotein MDM2 conceals the activation domain of tumour suppressor p53. *Nature*. 1993;362(6423):857-60. <https://doi.org/10.1038/362857a0> PMID:8479525
15. Kubbutat MH, Jones SN, Vousden KH. Regulation of p53 stability by Mdm2. *Nature*. 1997;387(6630):299-303. <https://doi.org/10.1038/387299a0> PMID:9153396
16. Stephen G. Williams, Maurizio Buscarini, and John P. Stein. Molecular Markers for Diagnosis, Staging, and Prognosis of Bladder Cancer. *Oncology*. 2001. <http://www.cancernetwork.com/review-article/molecular-markers-diagnosis-staging-and-prognosis-bladder-cancer-2/page/0/5>
17. Tuna B, Yorukoğlu K, Tuzel E, et al. Expression of p53 and mdm2 and their significance in recurrence of superficial bladder cancer. *Pathol Res Pract*. 2003;199:323-8. <https://doi.org/10.1078/0344-0338-00424> PMID:12908522
18. El-Abd E, Hassan A, El-Ashry O, Al-Ipshiti M, El-Swedy S. P27 And Mdm2 As Molecular Grading Biomarkers In Transitional Cell Carcinoma. *Turkish Journal Of Cancer*. 2008;38 (2).
19. Ross SJ, Wang K, Al-Rohil NR, Nazeer T, Sheehan EC, Otto AG, He J, Palmer G, Yelensky R, Lipson D, Ali S, Balasubramanian S, Curran AJ, Garcia L, Mahoney K, Downing RS, Hawryluk M, Miller AV and Stephens JP. Advanced urothelial carcinoma: next-generation sequencing reveals diverse genomic alterations and targets of therapy. *Modern Pathology*. 2014; 27: 271–280. <https://doi.org/10.1038/modpathol.2013.135> PMID:23887298
20. Shigemasa K, Hu C, West CM, Clarke J, Parham GP, Parmley TH, et al. p16 overexpression: a potential early indicator of transformation in ovarian carcinoma. *J Soc Gynecol Investig*. 1997;4:95e102.
21. Yang HC, Wu CC, Chen ZW, Chai YC, Yang FC. Expressions of p16 and p27 in urothelial carcinoma and their prognostic value. *Kaohsiung Journal of Medical Sciences*. 2014; 30: 453e458.
22. Cheng L, Davison DD, Adams J, Lopez-Beltran A, Wang L, Montironi R, Zhang S. Biomarkers in bladder cancer: Translational and clinical implications. *Critical Reviews in Oncology/Hematology*. 2014; 89(1): 73-111. <https://doi.org/10.1016/j.critrevonc.2013.08.008> PMID:24029603
23. Gan X, Lin X, He R, Lin X, Wang H, Yan L, Zhou H, Qin H, and Chen G. Prognostic and Clinicopathological Significance of Downregulated p16 Expression in Patients with Bladder Cancer: A Systematic Review and Meta-Analysis. *Disease Markers*. 2016; 5259602:13. <https://doi.org/10.1155/2016/5259602>
24. Mostafa MH, Sheweita S, O'Connor PJ. Relationship between schistosomiasis and bladder cancer. *Clin Microbiol Rev*. 1999; 12:97-11. PMID:9880476 PMCid:PMC88908
25. Osman H, Abadeer N, Mohamed S, Fahmy A. Expression of p16, p15 and Cyclin D1 in bladder cancer and correlates with cancer progression and clinical outcome. *The Internet Journal of Urology*. 2006; 4(2).
26. Rosin MP, Anwar WA and Ward AJ. Inflammation, chromosomal instability, and cancer: the schistosomiasis model. *Cancer Res*. 1994; 54(suppl.): 1929-193.
27. Alameda F, Juanpere N, Pijuan L , Lloveras B, Gimeno J, Baró T, Salido M, Serrano S and Lloreta J. Value of p16INK4a in the diagnosis of low-grade urothelial carcinoma of the urinary bladder in urinary cytology. *Cancer cytopathology*. 2012; 120 (4): 276–282. <https://doi.org/10.1002/cncy.21193> PMID:22419364
28. Larue, H, Allard P, Simoneau M, Normand C, Pfister C, Moore L, Meyer F, Têtu, B, Fradet Y. p53 point mutations in initial superficial bladder cancer occur only in tumors from current or recent cigarette smokers. *Carcinogenesis*. 1999.
29. Lianes P, Orlov, I, Zhang ZF, Oliva MR, Sarkis AS, Reuter VE and Cordon-Cardo, C. Altered patterns of MDM2 and p53 expression in human bladder cancer. *J Nat Cancer Inst*. 1994; 86:1325-1330. <https://doi.org/10.1093/jnci/86.17.1325> PMID:8064890
30. Schmitz-Dräger BJ, Kushima M, Goebell P, Jax TW, Gerharz CD, Büttel, H, Schulz W, Ebert T. and Ackermann R. p53 and MDM2 in the development and progression of bladder cancer. *Europ Urol*. 1997; 32: 487-493. PMID:9412812
31. Zhao M, He LH, Teng DX. Understanding the molecular pathogenesis and prognostics of bladder cancer: an overview. *Chinese journal of cancer research*. 2016; 28(1).
32. Mohammed AA, EL-Tanni H, EL-Khatib MH, Mirza AA, and Alturafi HT . Urinary Bladder Cancer: Biomarkers and Target Therapy, New Era for More Attention. *Onchology reviews*. 2016; 10(2).
33. Stephen G. Williams, Maurizio Buscarini, and John P. Stein. Molecular Markers for Diagnosis, Staging, and Prognosis of Bladder Cancer. *Oncology*. 2001.
34. Schlott T, Quentin T, Korabiowska M, Budd B, Kunze E. Alteration of the MDM2-p73-P14ARF pathway related to tumour progression during urinary bladder carcinogenesis. *Int J Mol Med*. 2004;14(5):825-36. <https://doi.org/10.3892/ijmm.14.5.825>
35. Pfister C, Larue LH, Moore L, Lacombe L, Veilleux C, Tetu B, Meyer F and Fradet Y. Tumorigenic Pathways In Low-Stage Bladder Cancer Based On P53, Mdm2 And P21 Phenotypes. *Int J Cancer (Pred Oncol)*. 2000; 89: 100–104. [https://doi.org/10.1002/\(SICI\)1097-0215\(20000120\)89:1<100::AID-IJC16>3.0.CO;2-Q](https://doi.org/10.1002/(SICI)1097-0215(20000120)89:1<100::AID-IJC16>3.0.CO;2-Q)
36. Uchida T, Minei S, Gao JP, Wang C, Satoh T, Baba S. Clinical significance of p53, MDM2 and bcl-2 expression in transitional cell carcinoma of the bladder. *Oncol Rep*. 2002; 9(2):253-9. <https://doi.org/10.3892/or.9.2.253>
37. Olsson H , Hultman P, Rosell J, Söderkvist P, Jahnson S. MDM2 SNP309 promoter polymorphism and p53 mutations in urinary bladder carcinoma stage T1. *BMC Urol*. 2013;28:13-5. <https://doi.org/10.1186/1471-2490-13-5>
38. Peter J. Goebell, Susan G. Groshen, Bernd J. Schmitz-Dräger. p53 immunohistochemistry in bladder cancer—a new approach to an old question. *Urologic oncology*. 2010; 28(4): 377–388. <https://doi.org/10.1016/j.urolonc.2010.03.021> PMID:20610276
39. Xu X, Stower, MJ, Reid IN, Garner RC, Burns PA. A hot spot for p53 mutation in transitional cell carcinoma of the bladder: Clues to the etiology of bladder cancer. *Cancer Epidemiology Biomarkers and Prevention*. 1997; 6 (8): 611-616. PMID:9264274
40. Dalbagni G, Cordon-Cardo C, Reuter V, Fair WR. Tumor



suppressor gene alterations in bladder carcinoma. Translational correlates to clinical practice. *Surgical oncology clinics of North America* . 1995;4(2): 231-240. PMID:7796283

41. Petitjean A, Achatz MI, Borresen-Dale AL, et al. TP53 mutations in human cancers: functional selection and impact on cancer prognosis and outcomes. *Oncogene*. 2007;26:2157-65. <https://doi.org/10.1038/sj.onc.1210302> PMID:17401424

42. Yurakh AO, Ramos D, Calabuig-Fari-as S, et al., Molecular and immunohistochemical analysis of the prognostic value of cell-cycle regulators in urothelial neoplasms of the bladder. *European Urology*. 2006; 50(3): 506–515. <https://doi.org/10.1016/j.eururo.2006.03.027> PMID:16624482

43. Mitra AP, Hansel DE, Cote RJ. Prognostic value of cell-cycle regulation biomarkers in bladder cancer. *Seminars in Oncology*. 2012; 39(5): 524–533.

<https://doi.org/10.1053/j.seminoncol.2012.08.008> PMID:23040249  
PMCID:PMC3478886

44. Krüger S, Mahnken A, Kausch I, Feller AC. P16 immunoreactivity is an independent predictor of tumor progression in minimally invasive urothelial bladder carcinoma. *European Urology*. 1995;47(4): 463–467. <https://doi.org/10.1016/j.eururo.2004.12.018> PMID:15774242

45. Yang C, Chu KC, Chen HY, Chen W. Expression of p16 and Cyclin D1 in Bladder Cancer and Correlation in Cancer Progression. *Urol Int*. 2002;69:190–194. <https://doi.org/10.1159/000063945> PMID:12372886