

# Endoscopic Ultrasound Guided Drainage of a Post-Surgical Fluid Collection Using a Lumen-Apposing Metal Stent in a Patient With Crohn's Disease

Nabeeha Mohy-ud-din, MD<sup>1</sup>, Gursimran Kochhar, MD<sup>2</sup>, and Manish Dhawan, MD<sup>2</sup>

<sup>1</sup>Medicine Institute, Allegheny Health Network, Pittsburgh, PA

<sup>2</sup>Department of Gastroenterology and Hepatology, Allegheny Health Network, Pittsburgh, PA

## ABSTRACT

Patients with Crohn's disease (CD) are susceptible to postsurgical fluid collections and abscesses. Traditionally, these have been drained either percutaneously or surgically. Endoscopic ultrasound-guided drainage using a lumen apposing metal stent has not been used commonly for drainage of abdominal abscesses in patients with CD, given the concern of fistula formation because of transmural inflammation in patients with CD. We report a case of a large perigastric abscess that was drained through the stomach, using a lumen apposing metal stent with complete resolution of the abscess.

## INTRODUCTION

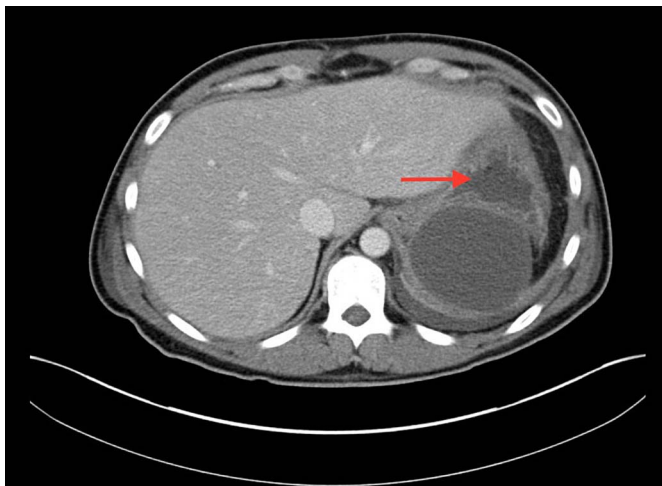
Endoscopic ultrasonography (EUS) is a procedure that can allow efficient and quick drainage of pancreatic fluid collections, gallbladder, and the biliary tract by the use of a lumen apposing metal stent (LAMS).<sup>1-4</sup> The Hot AXIOS stent (Boston Scientific, Marlborough, MA) is a commonly used LAMS that allows transgastric and transduodenal endoscopic drainage. Patients with Crohn's disease (CD) can have postoperative complications, including postoperative leaks leading to fluid collections and abscesses. Traditionally, these fluid collections can be drained by image-guided percutaneous drainage or surgical drainage or both. We describe a case of EUS-guided drainage of a perigastric abscess in a patient with a history of CD.

## CASE REPORT

A 44-year-old man with a history of ileocolonic CD since 2015 and B cell lymphoma of the skull was admitted to a hospital for an elective total abdominal colectomy because of the failure of the medical therapy of CD (failed therapies with infliximab, azathioprine, vedolizumab, and ustekinumab in the past). He underwent a laparoscopic colectomy and end ileostomy. Intraoperative findings revealed thickening and fat stranding of the entire colon with no evidence of disease in the small bowel. Pathology of the colonic samples revealed active chronic colitis.

Postprocedure, he developed abdominal pain and fever and was initiated on ceftriaxone and metronidazole for empiric coverage. Abdominal computed tomography (CT) with oral contrast revealed an iatrogenic small bowel perforation 20 cm proximal to the end ileostomy. An exploratory laparotomy was performed with the resection of approximately 10 cm of the intestine and placement of a biomesh over the enterotomy to prevent future herniation.

However, postsurgery, the patient remained febrile and continued to complain of abdominal pain. Abdominal and pelvic CT with intravenous and retrograde ileostomy contrast was performed 4 days after the surgery, and this revealed multiple intra-abdominal and pelvic fluid collections. The largest anterior midabdominal fluid collection was noted to be 18 × 5 cm and extended into the right

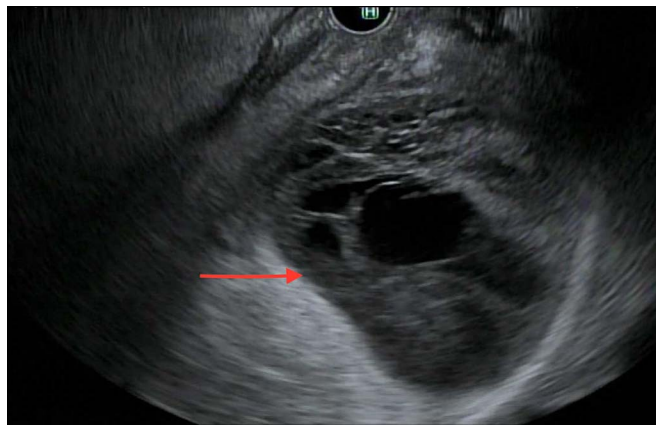


**Figure 1.** Axial abdominal computed tomography before endoscopic drainage showing large perigastric fluid collection (red arrow).

paracolic gutter. Imaging also revealed a large perigastric (6 × 7 cm) fluid collection in the splenic bed, with the wall of the collection in contact with the stomach (Figure 1).

The patient underwent CT-guided percutaneous drainage of the midabdominal fluid collection, and this grew *Candida albicans*, for which the patient was started on fluconazole. The perigastric fluid collection was found not to be amenable to percutaneous drainage. Gastroenterology was consulted, and the patient underwent EUS-guided drainage of the perigastric abscess using a curvilinear array echoendoscope (GF-UCT180; Olympus, Center Valley, PA) (Figure 2).

The EUS-guided drainage was performed using a 15 × 10 mm LAMS (Hot AXIOS; Boston Scientific Corp., Marlborough, MA). After deployment of the stent through the greater curvature of the stomach, the stent lumen was dilated with a 15-mm wire-guided balloon. Two 8.5 × 5 Fr plastic stents (Cook Medical Inc [Wilson], Bloomington, IN) were placed across the LAMS to prevent stent migration, ensure the patency of the LAMS, and prevent delayed bleeding. A large amount of purulent fluid was



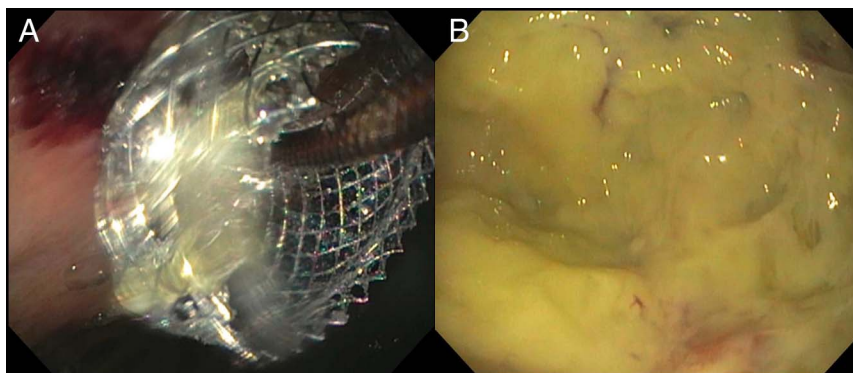
**Figure 2.** Endoscopic ultrasound showing a 6-cm perigastric abscess (red arrow).

suctioned out (Figure 3). Follow-up imaging 4 days later revealed near-total resolution of the perigastric abscess (Figure 4).

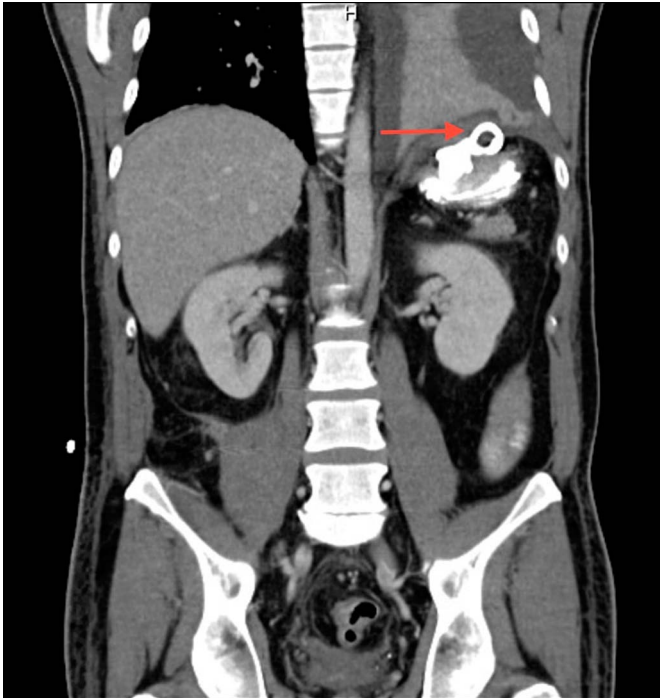
The LAMS was removed at the follow-up endoscopy 1 week after placement because the follow-up CT scan had shown resolution of the abscess. The LAMS was removed using a rat-toothed forceps and snare. Abdominal CT with oral contrast was performed 1 week after the removal of the LAMS, and this did not reveal any leak from the stomach, indicating complete closure of the gastric fistula, and no further collection was noted (Figure 5). The patient was discharged a day after the removal of the LAMS. He was followed up in the gastroenterology clinic, and the plan was to manage conservatively using immunosuppressive therapy with a repeat endoscopic evaluation in 6 months' time.

## DISCUSSION

Patients with CD who undergo abdominal surgeries can develop postoperative complications, including postoperative fluid collections and abscesses. Physicians are often presented with the challenging task of treating these patients and deciding what mode of drainage is the most efficacious. Surgical drainage of abscesses puts the patients at a higher risk of



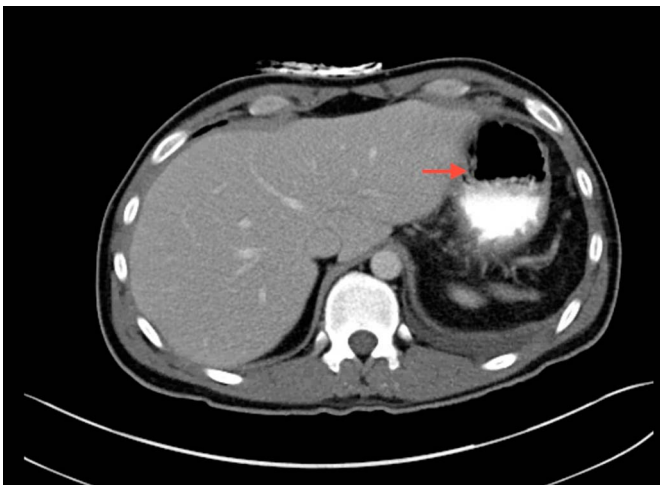**Figure 3.** Endoscopic image showing (A) the placement of lumen apposing metal stent into the abscess and (B) the abscess cavity revealing purulent fluid.



**Figure 4.** Coronal abdominal computed tomography performed 4 days after lumen apposing metal stent placement showing near-total resolution of the abscess (red arrow).

bleeding, infection, and perforation and may increase the length of stay. Percutaneous drainage has a success rate between 60% and 84%, poses an increased risk of cutaneous fistula and electrolyte losses, and requires closer monitoring by nursing staff.<sup>5-11</sup>

Simon-Linares et al described a similar case of a 29-year-old woman with ileocolonic fistulizing CD with a history of exploratory laparotomy. She developed a 7 × 5 cm left subdiaphragmatic abscess and underwent a successful EUS-



**Figure 5.** Axial abdominal computed tomography 1 week after the removal of the AXIOS stent revealing no evidence of extravasation of oral contrast (red arrow).

guided transgastric drainage of the abscess using a LAMS with a complete resolution of the abscess.<sup>12</sup> Mudireddy et al reported a case series on the usage of the LAMS to drain postsurgical fluid collections (PSFCs) in 47 patients (without a history of inflammatory bowel disease) and concluded that the use of the LAMS to drain PSFCs has a high technical and clinical success rate with low adverse events.<sup>13</sup> Most of the PSFCs (55%) were due to pancreatic duct leaks. Transgastric drainage of PSFCs had a 94.1% success rate, whereas transduodenal and transrectal drainage had 80% and 100% success rates, respectively. Intraprocedural stent migration occurred in 4.25% of the cases, and the incidence of post-procedural stent migration, perforation, and infection was low at 2% each.<sup>13</sup> Data regarding the usage of the LAMS for drainage of postoperative fluid collections in CD are lacking.

Our case and the case by Simon-Linares et al point to the safety and efficacy of using the LAMS to drain fluid collections in patients with CD. Both cases had no fistula formation after the drainage was established. In our case, a decision to use the LAMS and not plastic stents for drainage of the fluid collection was made because the initial visualization of the fluid collection revealed complex abscess-like contents that could have led to the occlusion of the plastic stents. Because the usage of the LAMS to drain fluid collections in patients with CD is infrequently described in the literature, complications of this procedure in patients with a history of CD are not well known but may involve stent migration, perforation, bleeding, and infection. This case report highlights the use of existing technology to better manage PSFCs in patients with CD, which may have a decreased complication rate and length of stay and allow fast and efficient drainage.

## DISCLOSURES

Author contributions: N. Mohy-ud-din wrote the manuscript and reviewed the literature. G. Kochhar reviewed the manuscript and reviewed the literature. M. Dhawan performed the endoscopy and is the article guarantor.

Financial disclosure: None to report.

Informed consent was obtained for this case report.

Received April 19, 2019; Accepted October 22, 2019

## REFERENCES

1. Siddiqui AA, Adler DG, Nieto J, et al. EUS-guided drainage of peri-pancreatic fluid collections and necrosis by using a novel lumen-apposing stent: A large retrospective, multicenter U.S. Experience (with videos). *Gastrointest Endosc.* 2016;83(4):699-707.
2. Irani S, Ngamruengphong S, Teoh A, et al. Similar efficacies of endoscopic ultrasound gallbladder drainage with a lumen-apposing metal stent versus percutaneous transhepatic gallbladder drainage for acute cholecystitis. *Clin Gastroenterol Hepatol.* 2017;15(5):738-45.

3. Anderloni A, Buda A, Vieceli F, Khashab MA, Hassan C, Repici A. Endoscopic ultrasound-guided transmural stenting for gallbladder drainage in high-risk patients with acute cholecystitis: A systematic review and pooled analysis. *Surg Endosc.* 2016;30(12):5200–8.
4. Kunda R, Pérez-Miranda M, Will U, et al. EUS-guided choledochoduodenostomy for malignant distal biliary obstruction using a lumen-apposing fully covered metal stent after failed ERCP. *Surg Endosc.* 2016;30(11):5002–8.
5. Cronin CG, Gervais DA, Castillo CF, Mueller PR, Arellano RS. Interventional radiology in the management of abdominal collections after distal pancreatectomy: A retrospective review. *AJR Am J Roentgenol.* 2011;197(1):241–6.
6. Marano I, Mainenti PP, Selva G, Cannavale M, Sodano A. Computerized tomography-guided drainage of postoperative abdominal fluid collections. *Radiol Med.* 1999;97(3):160–5. [Italian.]
7. Azeem N, Baron TH, Topazian MD, Zhong N, Fleming CJ, Kendrick ML. Outcomes of endoscopic and percutaneous drainage of pancreatic fluid collections arising after pancreatic tail resection. *J Am Coll Surg.* 2012;215(2):177–85.
8. Téllez-Ávila F, Carmona-Aguilera GJ, Valdovinos-Andraca F, et al. Post-operative abdominal collections drainage: Percutaneous versus guided by endoscopic ultrasound. *Dig Endosc.* 2015;27(7):763–7.
9. Tilara A, Gerdes H, Allen P, et al. Endoscopic ultrasound-guided transmural drainage of postoperative pancreatic collections. *J Am Coll Surg.* 2014;218(1):33–40.
10. Varadarajulu S, Trevino JM, Christein JD. EUS for the management of peripancreatic fluid collections after distal pancreatectomy. *Gastrointest Endosc.* 2009;70(6):1260–5.
11. Kwon YM, Gerdes H, Schattner MA, et al. Management of peripancreatic fluid collections following partial pancreatectomy: A comparison of percutaneous versus EUS-guided drainage. *Surg Endosc.* 2013;27(7):2422–7.
12. Simons-Linares CR, Chahal P. Successful EUS-guided drainage of a persistent subdiaphragmatic fluid collection in a patient with Crohn's Disease. *Inflamm Bowel Dis.* 2019;25:e85–6.
13. Mudireddy PR, Sethi A, Siddiqui AA, et al. EUS-guided drainage of post-surgical fluid collections using lumen-apposing metal stents: A multicenter study. *Gastrointest Endosc.* 2018;87(5):1256–62.

---

**Copyright:** © 2020 The Author(s). Published by Wolters Kluwer Health, Inc. on behalf of The American College of Gastroenterology. This is an open-access article distributed under the terms of the Creative Commons Attribution-Non Commercial-No Derivatives License 4.0 (CCBY-NC-ND), where it is permissible to download and share the work provided it is properly cited. The work cannot be changed in any way or used commercially without permission from the journal.