

Case Report

Hypocalcemia Masquerading as Schizophreniform Disorder

Shivangi Mehta, Sahil Mehta¹

ABSTRACT

Among the symptoms of hypocalcemia, tetany, papilledema, and seizures may occur in patients who develop hypocalcemia acutely. We describe a rare case of hypocalcemia presenting as schizophreniform disorder. Among other presentations of hypocalcemia, one should also look for the relation between psychotic symptoms and calcium levels in a patient presenting with psychotic symptoms.

Key words: Hypocalcemia, psychotic symptoms, schizophreniform disorder

INTRODUCTION

Hypocalcemia may be associated with a spectrum of clinical manifestations ranging from tingling to life-threatening seizures, refractory heart failure, or laryngospasm. Besides severity, the rate of development of hypocalcemia and chronicity determine the clinical manifestations. Among the symptoms of hypocalcemia, tetany, papilledema, and seizures may occur in patients who develop hypocalcemia acutely. By comparison, ectodermal and dental changes, cataract, basal ganglia calcification, and extrapyramidal disorders are features of chronic hypocalcemia. These last findings are most common in patients with hypoparathyroidism.^[1]

CASE REPORT

A 30-year-old female presented with symptoms of fearfulness, self-talking, asociality, anhedonia,

avolition, apathy, suicidal ideations, decreased sleep, aggressive behavior for the past 2 months, and, in addition, delusion of persecution and auditory and visual hallucinations on mental status examination (MSE). She had two episodes of generalized tonic clonic seizures prior to admission. There was no history of fever, headache, vomiting, or weakness of any side. She denied the history of any cognitive impairment. She also complained of intermittent paresthesias in her hands and feet but denied any muscle weakness or cramps. She had no past history of psychiatric illness or mood disorder. General physical examination revealed positive Chvostek and Trousseau signs [Figure 1]. She was oriented to time, place, and person with no focal neurological deficit. Meningeal signs were absent. There were no cerebellar signs and

This is an open access article distributed under the terms of the Creative Commons Attribution-NonCommercial-ShareAlike 3.0 License, which allows others to remix, tweak, and build upon the work non-commercially, as long as the author is credited and the new creations are licensed under the identical terms.

For reprints contact: reprints@medknow.com

How to cite this article: Mehta S, Mehta S. Hypocalcemia masquerading as schizophreniform disorder. Indian J Psychol Med 2016;38:463-5.

Access this article online	
Website: www.ijpm.info	Quick Response Code 
DOI: 10.4103/0253-7176.191386	

Department of Psychiatry, Government Medical College and Hospital, ¹Department of Neurology, Postgraduate Institute of Medical Education and Research, Chandigarh, India

Address for correspondence: Dr. Shivangi Mehta,
Department of Psychiatry, Government Medical College and Hospital, Sector 32, Chandigarh, India. E-mail: shivangi02@gmail.com

no evidence of extrapyramidal disorder in the form of tremor, rigidity, or bradykinesia.

Laboratory studies revealed serum calcium of 5.6 mg/dl (normal range: 8.4-10.5 mg/dl), phosphate 4.7 mg/dl (normal range: 2.7-4.5 mg/dl), and 3.4 g/dl of albumin (normal range: 3.5-5.3 g/dl). In view of hypocalcemia, her parathormone levels were sent, which came out to be normal 30 pg/ml parathyroid hormone (PTH) (normal range: 10-65 pg/ml). Renal functions tests, liver function tests, thyroid function tests, and viral markers did not reveal any abnormality. Computed tomography head showed diffuse, symmetric parenchymal calcifications involving the globus pallidus [Figure 2].

In view of normal PTH levels with basal ganglia calcification, a diagnosis of Fahr's Syndrome was made. The patient was started on 0.5 µg calcitriol and 1000 mg calcium carbonate (oral, daily). After 1 week, her chronic paresthesias resolved and serum calcium rose to 9.2 mg/dl. She was also started on 100 mg/day of quetiapine, increased to 600 mg/day in divided doses, and subsequently reduced to 50 mg/day within 1 year. There was a significant improvement in her psychotic symptoms with antipsychotics and calcium supplementation. The patient was lost to follow-up and subsequently presented after about 14 months with the same psychopathology of paranoid behavior, asociality, anhedonia, and auditory and visual hallucinations, and again was found to have serum calcium levels of 6 mg/dl (rest all investigations within normal range). The patient was started on quetiapine gradually increased to 600 mg/day along with serum calcium correction, and the patient maintained well-till a period of 1 year (till the time patient was followed up).

DISCUSSION

Fahr disease, first described in 1930, is an autosomal dominant disorder characterized by symmetric

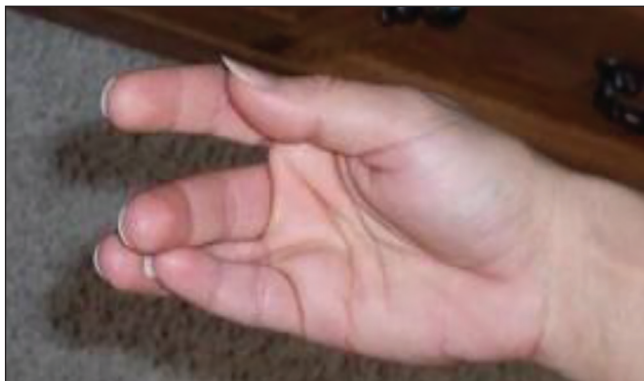


Figure 1: Image showing positive Trousseau's sign

calcifications in basal ganglia, dentate nucleus, and cerebral white matter. Globus pallidus is the most frequently involved site. Various clinical manifestations include cognitive impairment, extrapyramidal features, cerebellar dysfunctions, and seizures. Psychotic symptoms include auditory and visual hallucinations, paranoid delusions, ideas of reference, ideas of influence, catatonia, and atypical features such as complex perceptual disturbances. Mood disorders can occur in 20-30% of the patients. Anxiety symptoms especially obsessive compulsive disorders are noted in around 30% of the patients.

The common signs and symptoms of patients presenting with hypocalcemia are seizures (all types), dementia (in adults), mental retardation (in children), emotional problems (anxiety, depression), extrapyramidal symptoms (parkinsonism is most common), calcifications of basal ganglia (in longstanding disease), papilledema, increased neuromuscular irritability, Chvostek's sign, Trousseau's sign, paresthesias in circumoral and acral areas (fingers, toes), muscle stiffness, myalgias, and spasms; cardiovascular symptoms include prolongation of QT interval, congestive heart failure, hypotension, autonomic symptoms, biliary colic, bronchospasm, diaphoresis, and other symptoms such as cataract, dry coarse skin, dermatitis, hyperpigmentation, and eczema.^[2]

In mild hypocalcemia, patients have anxiety, paresthesias, irritability, and emotional lability. Mania, psychosis, tetany, and seizures are common in severe hypocalcemia.^[3]

A case of psychosis due to idiopathic hypoparathyroidism (IHP) has been followed for over 9 years. The optimal treatment for IHP psychosis was found to be a combination of ergocalciferol and fairly large doses of

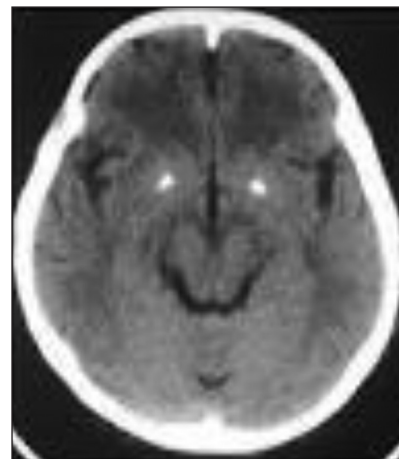


Figure 2: Computed tomography of head showing calcification of B/L Globus Pallidus

antipsychotic medication. In general, psychotic episodes occurred when there was hypocalcemia, hypercalcemia, or hypomagnesemia. Antipsychotic medication was not efficacious unless serum calcium and magnesium levels were both normal. It is suggested that psychiatric disturbances in IHP and treatment resistance to antipsychotic medication in other psychoses may also be related to hypomagnesemia.^[4]

Although Virchow and Bamberger independently described the histology of bilateral basal ganglia calcifications in 1855, it was not until 1939 that their association with chronic hypocalcemia was recognized by Eaton *et al.*^[5] Microscopic colloid deposition around cerebral blood vessels is followed by calcification most commonly in the basal ganglia, but also in the thalami, dentate nuclei, cerebral cortex, centrum semiovale, and mesencephalic gray matter. Patients may remain asymptomatic or develop Parkinsonian features.^[6]

To conclude, we report an unusual presentation of hypocalcemia manifesting as schizophreniform disorder.

CONCLUSION

It is an interesting case worth reporting because this patient of hypocalcemia with schizophreniform disorder was found to have two such episodes of

schizophreniform disorder over a period of about 3 years and is currently under remission with treatment with no cognitive decline.

Hence, hypocalcemia can present with Schizophreniform disorder.

Financial support and sponsorship

Nil.

Conflicts of interest

There are no conflicts of interest.

REFERENCES

1. Holick MF. Vitamin D deficiency. *N Engl J Med* 2007;357:266-81.
2. Cooper MS, Gittoes NJ. Diagnosis and management of hypocalcaemia. *BMJ* 2008;336:1298-302.
3. Levenson JL. Psychiatric issues in endocrinology. *Prim Psychiatry* 2006;13:27-30.
4. Ang AW, Ko SM, Tan CH. Calcium, magnesium, and psychotic symptoms in a girl with idiopathic hypoparathyroidism. *Psychosom Med* 1995;57:299-302.
5. Eaton LM, Camp JD, Love JG. Symmetric cerebral calcification, particularly of the basal ganglia, demonstrable roentgenographically; calcification of the finer cerebral blood vessels. *Arch Neurol Psychiatry* 1939;41:921-42.
6. Rastogi R, Beauchamp NJ, Ladenson PW. Calcification of the basal ganglia in chronic hypoparathyroidism. *J Clin Endocrinol Metab* 2003;88:1476-7.