

“Better explanations” in multiple sclerosis diagnostic workup

A 3-year longitudinal study

Massimiliano Calabrese, MD, Claudio Gasperini, MD, Carla Tortorella, MD, Gianmarco Schiavi, MD, Giovanni Frisullo, MD, Paolo Ragonese, MD, Roberta Fantozzi, MD, Luca Prosperini, MD, Pietro Annovazzi, MD, Cinzia Cordioli, MD, Massimiliano Di Filippo, MD, Diana Ferraro, MD, Alberto Gajofatto, MD, Simona Malucchi, MD, Salvatore Lo Fermo, MD, Giovanna De Luca, MD, Maria L. Stromillo, MD, Eleonora Cocco, MD, Antonio Gallo, MD, Damiano Paolicelli, MD, Roberta Lanzillo, MD, Valentina Tomassini, MD, Ilaria Pesci, MD, Maria E. Rodegher, MD, and Claudio Solaro, MD, the RIREMS group (Rising Italian Researchers in Multiple Sclerosis)

Correspondence

Prof. Calabrese
massimiliano.calabrese@univr.it

Neurology® 2019;92:e2527-e2537. doi:10.1212/WNL.00000000000007573

Abstract

Background

The exclusion of other diseases that can mimic multiple sclerosis (MS) is the cornerstone of current diagnostic criteria. However, data on the frequency of MS mimics in real life are incomplete.

Methods

A total of 695 patients presenting with symptoms suggestive of MS in any of the 22 RIREMS centers underwent a detailed diagnostic workup, including a brain and spinal cord MRI scan, CSF and blood examinations, and a 3-year clinical and radiologic follow-up.

Findings

A total of 667 patients completed the study. Alternative diagnoses were formulated in 163 (24.4%) cases, the most frequent being nonspecific neurologic symptoms in association with atypical MRI lesions of suspected vascular origin (40 patients), migraine with atypical lesions (24 patients), and neuromyelitis optica (14 patients). MS was diagnosed in 401 (60.1%) patients according to the 2017 diagnostic criteria. The multivariate analysis revealed that the absence of CSF oligoclonal immunoglobulin G bands (IgG-OB) (odds ratio [OR] 18.113), the presence of atypical MRI lesions (OR 10.977), the absence of dissemination in space (DIS) of the lesions (OR 5.164), and normal visual evoked potentials (OR 3.550) were all independent predictors of an alternative diagnosis.

Interpretation

This observational, unsponsored, real-life study, based on clinical practice, showed that diseases that mimicked MS were many, but more than 45% were represented by nonspecific neurologic symptoms with atypical MRI lesions of suspected vascular origin, migraine, and neuromyelitis optica. The absence of IgG-OB and DIS, the presence of atypical MRI lesions, and normal visual evoked potentials should be considered suggestive of an alternative disease and red flags for the misdiagnosis of MS.

From the Departments of Neuroscience, Biomedicine and Movement (M.C., A. Gajofatto) and Neurological and Movement Sciences (G.S.), University of Verona; Department of Neurosciences (C.G., C.T.), Azienda Ospedaliera San Camillo Forlanini, Roma; Department of Basic Medical Sciences, Neurosciences and Sense Organs (C.T., D.P.), University of Bari; Policlinico Gemelli (G.F.), Rome; Dipartimento di Biomedicina Sperimentale e Neuroscienze Cliniche (BIONEC) (P.R.), Università di Palermo; Istituto Neurologico Mediterraneo (R.F.), Pozzilli; Department of Neurology and Psychiatry (L.P.), Sapienza University of Rome; Multiple Sclerosis Center (P.A.), ASST Valle Olona, PO di Gallarate; Multiple Sclerosis Center (C.C.), Ospedale di Montichiari, Spedali Civili di Brescia; Clinica Neurologica (M.D.), Dipartimento di Medicina, Università di Perugia; Department of Biomedical, Metabolic and Neurosciences (D.F.), University of Modena and Reggio Emilia, Modena; Neurologia 2-CRESM (S.M.), AOU San Luigi Gonzaga, Orbassano; Multiple Sclerosis Centre (S.L.), A.O.U. Policlinico-Vittorio Emanuele, Catania; Neurology Clinic (G.D.), Multiple Sclerosis Center, SS. Annunziata Hospital, Chieti; Department of Medicine, Surgery and Neuroscience (M.L.S.), University of Siena; Department of Medical Science and Public Health (E.C.), University of Cagliari; Department of Medical, Surgical, Neurological, Metabolic and Aging Science (A. Gallo), University of Campania; Department of Neuroscience, Reproductive Sciences (R.L.), University Federico II, Naples, Italy; Institute of Psychological Medicine and Clinical Neurosciences (V.T.), Cardiff University School of Medicine, UK; Ospedale di Vaio (I.P.), Centro SM, Fidenza, Parma; Ospedale San Raffaele (M.E.R.), Milan; and Department of Rehabilitation (C.S.), Mons L. Novarese Hospital, Moncrivello, Italy.

Go to Neurology.org/N for full disclosures. Funding information and disclosures deemed relevant by the authors, if any, are provided at the end of the article.

The Article Processing Charge was funded by the University of Verona.

This is an open access article distributed under the terms of the Creative Commons Attribution-NonCommercial-NoDerivatives License 4.0 (CC BY-NC-ND), which permits downloading and sharing the work provided it is properly cited. The work cannot be changed in any way or used commercially without permission from the journal.

RELATED ARTICLE

Editorial

Differential diagnosis of multiple sclerosis: The better explanations in clinical practice

Page 1037

MORE ONLINE

CME Course

NPub.org/cmelist

Glossary

ANA = antinuclear antibodies; CI = confidence interval; CIS = clinically isolated syndrome; CMV = cytomegalovirus; DIS = dissemination in space; DIT = dissemination in time; ENA = extractable nuclear antigen; IgG-OB = immunoglobulin G oligoclonal bands; MS = multiple sclerosis; NMO = neuromyelitis optica; NMOSD = neuromyelitis optica spectrum disorder; OR = odds ratio; UI = under investigation; VEP = visual evoked potentials.

Multiple sclerosis (MS) diagnostic criteria have evolved over time with an increasing use of paraclinical markers, especially MRI,¹⁻⁴ to enable a definite diagnosis earlier than clinical features alone would allow.^{5,6} Despite technological advancements, current diagnostic criteria still rely on key principles of MS diagnosis articulated in the mid-20th century: demonstration of dissemination in space and in time of demyelinating lesions and exclusion of alternative explanations.^{1-4,7}

The 2010 and, more recently, the 2017 McDonald diagnostic criteria revision^{3,4} simplified the diagnostic process, allowing a more rapid diagnosis.^{5,6} However, the increasing focus on an earlier diagnosis of MS, to allow initiation of disease-modifying therapies, may increase the risk of misdiagnosis, which remains an important issue in clinical practice.^{7,8} In daily clinical practice, the neurologist must pay extreme attention to clinical presentation, since MS diagnostic criteria are better applicable in patients with typical presentations suggestive of MS compared to patients with atypical or nonspecific symptoms (e.g., headache, arthralgias)⁹; moreover, any diagnostic tests that suggest the possibility of an alternative diagnosis, so-called red flags,¹⁰ should be carefully evaluated. Interpretation of personal history, physical examination, and results of imaging and laboratory testing by a clinician with expertise in MS remains fundamental in correctly diagnosing MS.

Nevertheless, the differentiation of MS from other MS-mimicking conditions might be difficult. This is due to the low amount of data available on the frequency of alternative diagnoses in real life. Clinical and paraclinical information about these diseases is also poor, thus making it even more complicated to define which examinations could be useful in the diagnostic workup to confirm that “no better explanation” exists.

We therefore designed a real-life study aimed at evaluating (1) the main diseases that mimic MS at clinical onset and their frequency, (2) the most relevant clinical and paraclinical characteristics suggesting a diagnosis different from MS, and, finally, (3) the best diagnostic workup for the exclusion of other possible explanations of clinical symptoms suggesting MS.

Methods

Setup of a shared diagnostic workup

A restricted subgroup of participants revised the literature in order to obtain a list of blood, CSF, and instrumental

examinations needed to identify possible alternative diagnoses.¹⁰⁻¹³ Then, a shareable list of examinations to be included in the diagnostic workup was created and submitted to each center in order to obtain a consensus statement. We considered an item accepted if agreed on by at least 70% of centers. The main reasons to reject an item were (1) not available in all centers, (2) available but not extensively used in every day clinical practice, since it requires a motivated request based on a specific clinical suspicion (e.g., anti-MOG antibodies), (3) too expensive. The minimum set of examinations suggested by consensus by the panel is reported in table 1. However, each center was free to exclude some examinations if considered of no use in relation to the clinical presentation.

Finally, after a revision of the literature, each alternative diagnosis was based on the most recent international guidelines, where possible (i.e., migraine, neuromyelitis optica spectrum disorder [NMOSD], Behcet disease, Sjögren syndrome, systemic lupus erythematosus, Susac syndrome, fibromyalgia)¹⁴⁻²⁰ and on common clinical practice where clear guidelines were not available. The diagnosis of nonspecific neurologic symptoms associated with atypical MRI lesions of suspected ischemic origin was formulated, on the base of the clinical practice, in those patients presenting with nonspecific (for MS) neurologic symptoms (e.g., migraine, arthralgia, and myalgia), normal neurologic examination, no CSF immunoglobulin G oligoclonal bands (IgG-OB), normal visual evoked potentials, MRI lesions atypical for MS, without spinal cord lesions, and at least one major vascular risk factor (i.e., hypertension, patent foramen ovale, hypercholesterolemia). The diagnosis of nonspecific neurologic symptoms associated with atypical MRI lesions was reserved for those cases where no hypothesis about the origin of the MRI lesions was possible, the symptoms were not suggestive of MS, and all the other examinations were normal. The characteristics of the typical MRI lesions are reported below.

Study population

We included all patients referred to any of the 22 participating MS centers between March and September 2014 because MS was suspected, and who required a diagnostic workup, including blood, CSF, and instrumental examinations, in order to confirm the diagnosis of MS.

Inclusion criteria

The 2 main groups were as follows:

1. Patients presenting with symptoms or signs suggestive of MS.

Table 1 Minimum set of examinations required to exclude alternative diagnoses in patients presenting with clinical symptoms suggestive of demyelinating diseases of the CNS

Clinical evaluation	Laboratory examinations
Neurologic examination with EDSS	Complete blood count
CSF examinations	AST, ALT, gGT
IgG-OB	Kidney profile
IgG index	ANA, ENA, and AQP4 ab ^a
Total proteins	Homocysteine
Cell count	Antithyroid Ab
CSF/serum albumin ratio	Vitamin B ₁₂ and folate
Instrumental examinations	Antiphospholipid Ab
VEP	ESR and CRP
MRI	Urine examination

Abbreviations: Ab = antibodies; ALT = alanine transaminase; ANA = antinuclear antibodies; AQP4 = anti-aquaporin 4; AST = aspartate transaminase; CRP = C-reactive protein; EDSS = Extended Disability Status Scale; ENA = extractable nuclear antibodies; ESR = erythrocyte sedimentation rate; gGT = γ -glutamyltransferase; IgG-OB = immunoglobulin G oligoclonal bands; VEP = visual evoked potentials.

^a Anti-AQP4 antibodies were mandatory in case of symptoms/signs suggestive of optic neuritis or myelitis.

- Patients presenting with atypical symptoms or signs but referred to one of the centers because MS was suspected, and who required a specialized diagnostic assessment. Usually these patients were referred to one of our MS centers by a general neurologist or by an emergency department physician (i.e., colleagues without specific experience in MS) and were included, following a general neurologic examination, if the hypothesis of an MS diagnosis was not immediately rejected.

Exclusion criteria

The only exclusion criterion was an already established diagnosis of MS.

Clinical and paraclinical examinations

Information about family history, type of first clinical manifestation (motor, sensory, cortical, visual, spinal cord, or cerebellar), and the co-occurrence of atypical symptoms or signs (i.e., arthralgia, myalgia, fever, oral ulceration, xerophthalmia, xerostomia, rash, migraine, livedo reticularis, epilepsy, gastrointestinal disorders, signs of neuropathy, history of abortion, or thrombosis) were collected.

During the diagnostic assessment, each patient underwent a complete neurologic examination, assessed by means of the Expanded Disability Status Scale²¹ and a 1.5T brain MRI according to recent Italian guidelines.²²

For each MRI lesion, the size, morphology, and location were evaluated. Oval, asymmetric white matter lesions perpendicular to the ventricles (Dawson fingers) or in the periventricular, juxtacortical, infratentorial or spinal cord region, and having a diameter >6 mm, were considered typical of MS.^{22,23} All other lesions were considered atypical. We also evaluated the number of contrast-enhancing lesions and the dissemination in space of the lesions; IgG-OB were investigated through isoelectric focusing.²⁴ IgG-OB testing in the CSF was paired with the serum to confirm that IgG-OB were unique to CSF.

Visual evoked potentials (VEP) were performed, in accordance with International Society for Clinical Electrophysiology of Vision international recommendations,²⁵ and latency and morphology were recorded.

Finally, blood-based examinations were carried out in order to exclude alternative diagnoses (table 1).

Local ethics committees approved the study. The present study was conducted in accordance with specific national laws and the ethical standards laid down in the 1964 Declaration of Helsinki and its later amendments.

Study design and follow-up

The flowchart of the study is summarized in figure 1.

At the end of the diagnostic workup, all recruited patients were classified into 3 groups according to their diagnosis:

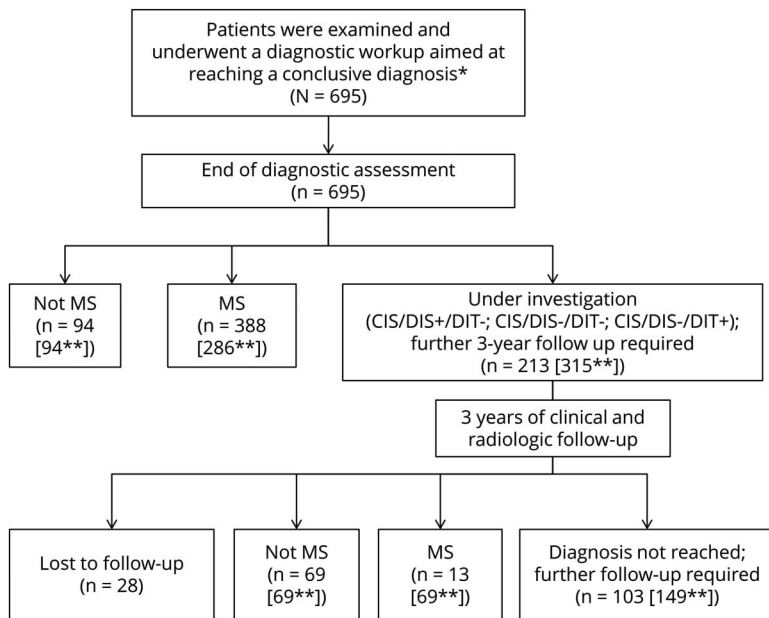
- MS according to the 2010 revisions of McDonald diagnostic criteria³
- Not MS (specification of the alternative diagnosis was required)
- Under investigation (UI): in case a conclusive diagnosis could not be formulated, and additional follow-up was deemed necessary

The latter was further divided into the following:

- Clinically isolated syndrome (CIS)/dissemination in space (DIS)+: patients with a CIS and CIS of the lesions but lacking dissemination in time (DIT) of lesions and a better explanation for signs and symptoms
- CIS/DIS-/DIT-: patients with CIS but lacking DIS and DIT; this group included optic neuritis and myelitis (with negative anti-aquaporin-4 antibodies) with normal brain MRI scans
- CIS/DIS-/DIT+: patients with CIS lacking DIS but with evidence of DIT (e.g., patients with optic neuritis and 2 periventricular brain lesions, one of which enhanced by gadolinium)

Each patient without a conclusive diagnosis at the end of the initial diagnostic workup (3a, 3b, and 3c groups) underwent a clinical and radiologic 3-year follow-up, in order to assess

Figure Study algorithm



*Including patients with symptoms or signs suggestive of multiple sclerosis (MS) presenting to one of the centers or patients sent to one of our centers by their physician or by the local emergency department with suspected MS. **Within the bracket number according to 2017 diagnostic criteria. CIS/DIS+ = clinically isolated syndrome with dissemination in space of the lesions; CIS/DIS- = clinically isolated syndrome without dissemination in space of the lesions.

whether DIS or DIT occurred. During this period, each patient was evaluated at least every 6 months and underwent a new MRI at least every year. At the end of the 3 years, based on the clinical and radiologic follow-up, each patient of the previous UI group was reclassified as MS, not MS (with a definitive alternative diagnosis), or still as UI. Since the 2017 revised diagnostic criteria for MS were published during the course of the study,⁴ each diagnosis was revised, and each patient reclassified according to the new criteria.

Recurrent optic neuritides or myelitides that did not show DIS at the end of the follow-up were included in the not-MS group.

Statistical analysis

The χ^2 test was applied to test the effect of IgG-OB, type, number, and location of MRI lesions and VEP abnormalities in identifying MS vs not MS patients both at the end of the initial diagnostic workup and at the end of the follow-up period.

For each variable, we also calculated sensitivity, specificity, and accuracy.

A logistic multivariate analysis was performed, using the occurrence of an alternative diagnosis at the end of the study as dependent variable. As independent variables at baseline, we included the presence of atypical MRI lesions, the location of the lesions (periventricular, juxtacortical, infratentorial, spinal cord), DIS of lesions, the number of contrast-enhancing lesions, the presence/absence of IgG-OB, the VEP results, the presence of atypical symptoms, and any significantly abnormal blood assay.

Data availability statement

The entire dataset, including all data used in this study, and completely anonymized, is located in a Dropbox folder and will be shared following request by qualified investigators.

Results

Results after the initial diagnostic workup

According to inclusion/exclusion criteria, 695 patients (481 female, mean age 40.6 years) were enrolled in this study.

At the end of the initial diagnostic workup, an alternative diagnosis was formulated in 94 patients (13.5%); among these, nonspecific neurologic symptoms associated with atypical MRI lesions of suspected ischemic origin (4.3% of the total diagnoses and 31.9% of the alternative diagnoses) was the most frequent alternative diagnosis. Migraine associated with atypical MRI lesions (3.2% of the total diagnoses and 23.4% of the alternative diagnoses) and NMOSDs (1.6% of the total diagnoses and 11.7% of the alternative diagnoses) were the other most frequent diagnoses (table 2 for more details).

According to the 2010 revision of diagnostic criteria, an MS diagnosis was possible in 286 (41.2%) patients while a conclusive diagnosis was not reached in 315 (45.3%) patients, who remained under investigation. Among these 315 patients without a definite diagnosis, 206 showed DIS of MRI lesions (CIS/DIS+) and 102 showed both DIS and IgG-OB. Following the publication of the 2017 revision of MS diagnostic criteria, the latter group was reclassified as MS. Therefore, among the 695 patients included in the study, the application of the 2017 revision of diagnostic criteria has allowed the

Table 2 Main diagnoses of the patients included in the study at the end of the diagnostic workup or at the end of the 3-year follow-up period

Diagnosis at the end of initial diagnostic workup	Total (695)	%
Under investigation ^a	213 (315)	30.6 (45.3)
Multiple sclerosis ^a	388 (286)	55.8 (41.1)
Nonspecific neurologic symptoms associated with atypical MRI lesions of suspected vascular origin^b	30	4.3
Migraine	22	3.2
NMOSD	11	1.6
Sjögren syndrome	4	0.6
Behçet disease	3	0.4
Antiphospholipid syndrome	2	0.3
Chronic inflammatory demyelinating polyneuropathy	2	0.3
Systemic lupus erythematosus	2	0.3
Subcombined degeneration spinal cord	2	0.3
Nonspecific neurologic symptoms with nonspecific MRI ^c	2	0.3
Arteritic anterior ischemic optic neuropathy	2	0.3
ADEM	1	0.1
Atypical facial pain	1	0.1
Fibromyalgia	1	0.1
Glaucoma	1	0.1
Hereditary spastic paraplegia	1	0.1
Metabolic leukoencephalopathy	1	0.1
Polyneuritis cranialis	1	0.1
Psychiatric disorder	1	0.1
Spinocerebellar ataxia	1	0.1
Myotonic dystrophy type 1	1	0.1
Susac syndrome	1	0.1
Syringomyelia	1	0.1
Diagnosis at the end of the study	Total (667)	%
Multiple sclerosis ^a	401 (355)	60.1 (53.2)
CIS/DIS+/DIT ^{-a}	28 (78)	4.2 (11.7)
CIS/DIS ⁻ /DIT ^{-a}	62 (71)	9.3 (10.6)
CIS/DIS ⁻ /DIT ⁺ ^a	13 (0)	2.0 (0)

Table 2 Main diagnoses of the patients included in the study at the end of the diagnostic workup or at the end of the 3-year follow-up period (*continued*)

Diagnosis at the end of initial diagnostic workup	Total (695)	%
Nonspecific neurologic symptoms associated with atypical MRI lesions of suspected vascular origin^b	40	6.0
Migraine with atypical MRI lesions	24	3.6
NMOSD	14	2.1
Nonspecific neurologic symptoms with atypical MRI^c	10	1.5
Recurrent optic neuritis	7	1.0
Behçet disease	7	1.0
Sjögren syndrome	6	0.9
ADEM	6	0.9
Psychiatric disorder	5	0.7
Antiphospholipid syndrome	5	0.7
Fibromyalgia	4	0.6
Systemic lupus erythematosus	4	0.6
Hereditary spastic paraplegia	4	0.6
Susac syndrome	4	0.6
Chronic inflammatory demyelinating polyneuropathy	3	0.4
Arteritic anterior ischemic optic neuropathy	3	0.4
Subcombined degeneration spinal cord	3	0.4
Glaucoma	2	0.3
Undifferentiated connective tissue disease	2	0.3
Atypical facial pain	2	0.3
Cerebellar hamartoma	1	0.1
Metabolic leukoencephalopathy	1	0.1
Myasthenia gravis	1	0.1
Polyneuritis cranialis	1	0.1
Recurrent myelitis	1	0.1
Spinocerebellar ataxia	1	0.1
Myotonic dystrophy type 1	1	0.1
Syringomyelia	1	0.1

Abbreviations: ADEM = acute disseminated encephalomyelitis; CIS/DIS+ = clinically isolated syndrome with dissemination in space of the lesions; CIS/DIS- = clinically isolated syndrome without dissemination in space of the lesions; DIT = dissemination in time; NMOSD = neuromyelitis optica spectrum disorder.

^a Data are according to 2017 diagnostic criteria (and 2010 diagnostic criteria).

^b This group included patients with atypical MRI lesions without IgG-OBs and spinal cord lesions, with normal VEP and with several vascular risk factors (i.e., hypertension, patent foramen ovale, hypercholesterolemia).

^c This group included patients where no hypothesis about the origin of the symptom or of the MRI lesions was possible.

Table 3 Role of the main paraclinical tests in the identification of alternative diseases

	Not MS (163), n (%)	MS ^a (401), n (%)	Under investigation (103), n (%)
Absence of CSF IgG-OB	121 of 135 (89.6)	38 of 344 (11.0)	49 of 103 (47.6)
Atypical MRI lesions	109 of 163 (66.9)	34 of 401 (8.5)	29 of 103 (28.1)
Normal VEP	117 of 151 (77.5)	161 of 351 (45.9)	62 of 98 (63.3)
No DIS	97 of 163 (59.5)	0 of 401	33 of 103 (32.0)
GAD + lesions	13 of 158 (8.2)	155 of 369 (42.0)	9 of 103 (8.7)
Spinal cord lesions	33 of 146 (22.6)	269 of 368 (73.1)	36 of 101 (35.6)

Abbreviations: DIS = dissemination in space of the lesions; GAD = gadolinium; IgG-OB = CSF IgG oligoclonal bands; MS = multiple sclerosis; VEP = visual evoked potentials.

^a The diagnosis of MS was formulated according to the 2017 diagnostic criteria.

identification of 388 (55.8%) patients with MS (instead of 286, according to the 2010 criteria) while a conclusive diagnosis was missing in only 213 (30.6%) patients (instead of 315, table 2 for more details).

Results at the end of the study

Among the 315 patients without a definite diagnosis during the initial diagnostic workup, 28 were lost to follow-up, while 287 completed a 3-year clinical and radiologic follow-up (mean 36.6 ± 4.1, range 34–40 months).

At the end of the follow-up, an alternative diagnosis was made in an additional 69 patients. Among the 667 patients who completed the study, an alternative diagnosis was formulated in 163 (24.4%) patients (figure 1 for more details). Non-specific neurologic symptoms associated with atypical MRI lesions of suspected ischemic origin (24.5% of the alternative diagnoses) and migraine associated with atypical MRI lesions (14.7% of the alternative diagnoses) were still the main alternative diagnoses. Table 2 summarizes the total alternative diagnoses at the end of the study.

Table 4 Sensitivity, specificity, and predictive values of atypical MRI lesions, lack of dissemination in space (DIS) of lesions, absence of CSF oligoclonal bands, and normal visual evoked potentials (VEP), for the not multiple sclerosis (MS) diagnosis

	No. of patients	Sensitivity	Specificity	PPV	NPV
Based on the patients who received a not-MS diagnosis at the end of diagnostic workup					
Presence of atypical MRI lesions	77	66.9 (62.7–71.0)	76.3 (72.3–79.9)	40.8 (36.6–45.3)	90.4 (87.5–92.8)
No MRI DIS	91	59.5 (55.2–63.9)	75.4 (71.3–79.0)	35.4 (31.3–39.8)	89.1 (86.0–91.6)
Normal VEP	84	77.5 (76.2–79.0)	45.1 (43.2–48.8)	17.9 (15.1–19.3)	92.5 (90.1–95.2)
Absence of CSF IgG-OB	67	89.6 (86.5–91.7)	69.8 (66.2–73.2)	31.6 (27.0–35.6)	97.7 (96.2–98.6)
Based on the patients who received a not-MS diagnosis at the end of 3-year follow-up					
Presence of atypical MRI lesions	46	73.9 (70.1–75.3)	66.7 (63.8–68.9)	69.4 (67.3–71.8)	70.4 (68.4–73.2)
No MRI DIS	63	67.2 (65.2–70.0)	81.5 (79.7–83.6)	100	64.8 (62.3–67.7)
Normal VEP	56	64.3 (62.1–67.6)	38.4 (36.3–40.1)	80.6 (78.6–82.9)	20.2 (18.3–23.1)
Absence of CSF IgG-OB	51	80.4 (78.2–82.1)	62.0 (60.1–64.3)	79.1 (77.3–81.5)	68.8 (66.1–70.9)

Abbreviations: IgG-OB = immunoglobulin G oligoclonal bands; NPV = negative predictive value; PPV = positive predictive value. Data are reported as % (95% CI).

The diagnosis of MS was made according to the 2010 diagnostic criteria in 355 patients, while in 149 patients it was not possible to reach a conclusive diagnosis. Among these, 78 patients showed only DIS of MRI lesions (CIS/DIS+/DIT-) while 71 did not show DIS or DIT (CIS/DIS-/DIT-). There were no CIS/DIS-/DIT+ patients. However, following the application of the 2017 revision of diagnostic criteria, 401 patients were reclassified as MS, whereas only 103 were still under investigation. Among these 103 patients, 28 patients showed only DIS of MRI lesions (CIS/DIS+/DIT-), 62 did not show DIS or DIT (CIS/DIS-/DIT-), and 13 showed only DIT (CIS/DIS-/DIT+) (table 2).

The role of clinical presentation and paraclinical tests

Among the 695 patients included in the study, 653 patients presented with symptoms suggestive of MS (168 sensory, 145 visual, 127 brainstem or cerebellar, 101 motor, 21 cortical, 91 multifocal), 42 patients presented only with atypical symptoms, and 92 patients showed concomitant typical and atypical symptoms. The main atypical symptoms were migraine, arthralgia, and myalgia. No significant difference in the type of the first clinical manifestation or in the presence of atypical symptoms was observed between groups (data not shown).

The CSF was examined in 593 (85.3%) patients, VEPs were collected in 610 (87.8%) patients, brain MRI was collected in all patients, and the complete set of laboratory examinations was carried out in 602 (86.7%) patients. In addition, gadolinium was administered in 635 (91.3%) patients and spinal cord MRI was performed in 623 (89.6%) patients.

The results of the main paraclinical tests in the 3 groups (MS, not MS, and UI) at the end of the study are reported in table 3. The sensitivity and specificity of the main paraclinical tests are reported in table 4. The presence of atypical MRI lesions and the absence of DIS and of CSF IgG-OB showed the highest accuracy in the identification of not MS patients (table 4 for more details). The relationship between the site of MRI lesions and the final diagnosis is reported in figure e-1 (doi.org/10.5061/dryad.33770ms).

The role of hematologic, immunologic, and rheumatologic screening

Among the blood tests performed in the not MS group of patients, abnormal results were present in 67 patients: abnormal values of antinuclear antibodies/extractable nuclear antigen (ANA/ENA) antibodies (>1:640 dilutions) were observed in 13 and anti-aquaporin-4 antibodies in 12 patients, homocysteine was increased in 10 patients, anti-thyroid antibodies were observed in 9, and antiphospholipid antibodies in 8 patients; abnormally low levels of B₁₂ and folate were observed in 8 patients and antineutrophil cytoplasmic

antibodies and immunoglobulin M antibodies against Epstein-Barr virus, cytomegalovirus (CMV), varicella-zoster virus, herpes simplex virus 1, measles, and rubella in 1 patient each.

The abnormal results of blood-based examinations were crucial for the conclusive diagnosis only in 24 cases: anti-aquaporin-4 antibodies drove the diagnosis in 12 of the 14 neuromyelitis optica (NMO) cases, increased levels of homocysteine (6 cases) and the presence of antiphospholipid antibodies (2 cases) were helpful in the diagnosis of non-specific neurologic symptoms associated with atypical MRI lesions of suspected vascular origin and antiphospholipid syndrome, respectively; the evidence of low vitamin B₁₂ levels was helpful in the identification of 2 cases of subacute combined degeneration of the spinal cord, while the presence of ANA/ENA antibodies was helpful in 2 cases of systemic lupus erythematosus.

Predictors of alternative diagnoses

The multivariate analysis revealed that the absence of IgG-OBs ($p < 0.001$, odds ratio [OR] 18.113, 95% confidence interval [CI] 15.123–21.463), the presence of atypical MRI lesions ($p < 0.001$, OR 10.977, 95% CI 9.011–13.103), the absence of DIS of the lesions ($p = 0.002$, OR 5.164, 95% CI 3.226–7.338), and normal visual evoked potentials ($p = 0.008$, OR 3.550, 95% CI 2.011–5.121) were all independent predictors of an alternative diagnosis and should be considered red flags for the misdiagnosis of MS. Of note, the presence of abnormal blood examinations did not reach statistical significance.

Discussion

The concept of no better explanation is a key element of all MS diagnostic criteria revisions^{1–4,10}; however, little has been done in recent years to gather information on diseases that are part of the differential diagnosis of MS in real life. Diagnostic criteria were created to predict the development of MS in patients with a CIS suggestive of inflammatory demyelination and, therefore, with a clinical presentation typical for MS. When used in a different context, however, these criteria might not perform as well in distinguishing MS from other disorders since they could be fulfilled by several other neurologic diseases, leading to possible misdiagnoses and inappropriate treatments.

The European Magnetic Resonance Network in MS (MAGNIMS) expanded the criterion of the no better explanation over a decade ago by establishing, mostly on the basis of literature, some red flags that should help clinicians in the differential diagnosis of MS.¹⁰ Recently, the same group suggested a diagnostic algorithm¹³ that incorporates features that have been identified as useful in differentiating MS from NMOSD and imaging features that suggest alternative diagnoses in the current MS diagnostic criteria. This review

summarized several new developments in the MS imaging field that have occurred in the last decade; it described the coexistence of age-related changes and vascular diseases that have been recognized in patients with MS and pose major diagnostic challenges; finally, it highlighted those features that distinguish MS from the newly recognized antibody-mediated syndromes of NMOSD and acute demyelinating encephalomyelitis. The authors stated that several challenges will be faced in the near future to differentiate MS from all those diseases that can mimic it clinically and radiologically. They concluded that real-world studies on this topic are necessary and desirable.

The frequency of MS mimics in real life and, hence, their relevance and effect on everyday clinical practice has remained largely unexplored. Consequently, a precise and evidence-based diagnostic workup aimed at the exclusion of other diseases mimicking MS has not yet been developed.

To better define the concept of no better explanation, we performed a prospective longitudinal observational study that involved 22 highly specialized MS centers. Since this is a real-life study we decided to include all consecutive patients who required a diagnostic assessment to confirm/exclude the diagnosis of MS: this included patients with a CIS suggestive of MS but also patients without typical MS signs or symptoms referred to one of our centers with a suspicion of MS based on the evaluation of a general physician or a non-MS neurologist.

We also defined, by consensus, the minimum set of laboratory/paraclinical examinations that should be performed in patients enrolled in the study, in order to exclude most common better explanations of the clinical presentation (table 1). Since this is a real-life study, each clinician was still free to exclude some examinations and to include additional examinations, according to the clinical presentation. For example, as reported in table 1, anti-aquaporin-4 antibodies were searched only in case of optic neuritis or myelitis. This is why not all the examinations are available for each patient. Nevertheless, the majority of the patients underwent a comprehensive battery of blood tests. Finally, since the current diagnostic criteria at the time of this study were those described in 2011 by Polman et al.,³ we decided to describe the classification of each patient on the basis of both the 2010³ and the 2017⁴ diagnostic criteria.

The first result of this study was, therefore, a portrait of the pathologic conditions that mimic MS in the everyday clinical practice of highly specialized MS centers: among these, nonspecific neurologic symptoms associated with atypical MRI lesions of suspected ischemic origin, migraine, and NMOSD are by far the most common. Regarding these diagnoses, it has to be underlined that, differently from NMOSD and migraine, for which specific diagnostic guidelines are available, the diagnosis of

nonspecific neurologic symptoms (i.e., a CIS with symptoms not suggestive of MS) associated with atypical MRI lesions of suspected ischemic origin is mainly based on common clinical practice. In order to make this diagnosis more consistent across the centers, we asked each center to include in this group only patients with at least one major vascular risk factor and no evidence of MS or other diseases.

Our results are mostly in line with those of a previous study⁷ aimed at characterizing patients misdiagnosed with MS: as in our study, migraine, NMOSD, CIS, and nonspecific MRI changes were among the most frequent alternative diagnoses. The main differences between the 2 studies refer to the frequency of functional disorders and fibromyalgia, which could be explained by differences in the recognition of these disorders as well as patient enrollment procedures. As also highlighted by Solomon et al.,^{7,8} fibromyalgia was reported significantly more often by the Mayo Clinic neurologists than by other centers.

The second interesting result was the observation that in 30% of the cases, a conclusive diagnosis was not reached at the end of the initial diagnostic workup even after applying 2017 revised MS diagnostic criteria.⁴ Moreover, after extending the clinical and radiologic follow-up up to 3 years, we still had 15% of participants without a definitive diagnosis. As expected, 2010 diagnostic MS criteria performed significantly worse than 2017 criteria, with more than 20% of patients still without a diagnosis at the end of the follow-up.

From a clinical point of view, and in order to define the best diagnostic workup for those patients with a CIS suggestive of MS, it is of interest to analyze the sensitivity and specificity of the radiologic and immunologic examinations currently used in clinical practice.

The presence of atypical lesions, or lesions located in the subcortical or in the infratentorial white matter and the absence of IgG-OB, characterized the 163 patients who received an alternative diagnosis. A similar finding was reported for the CIS/DIS- patients. This result was confirmed by the multivariate analysis run in the followed up subjects that showed that the absence of CSF IgG-OB, DIS of the lesions, and the presence of atypical MRI lesions were the most relevant predictors of an alternative diagnosis, and should be considered red flags for the misdiagnosis of MS.

As far as the blood tests are concerned, the presence of abnormal examinations did not reach statistical significance at the multivariate analysis. This is in line with previous evidence showing the inconsistent significance for conversion to clinically definite MS of blood tests such as EBNA1 and CMV IgG dosages.²⁶ We observed very few cases in which one or more blood tests contributed to the

final diagnosis, with the exception of anti-aquaporin-4 antibodies that allowed the identification of several NMO cases, as already reported.²⁷ We do not suggest, therefore, a comprehensive battery of blood tests in all patients with clinical and radiologic findings suggestive of MS, but only in those patients showing red flags suggestive of alternative diagnosis.

This study is not without limitations. The ascertainment bias could be the first limitation of this study. This is why, in order to limit its effect, we included both patients presenting directly to one of the MS centers with symptoms or signs suggestive of MS and patients presenting with atypical symptoms or signs who were referred to one of our MS centers by the general physician or by non-MS neurologist. Moreover, the entire battery of blood-based or paraclinical examinations was not performed in all patients. Although a minimum set of laboratory/paraclinical examinations was highly recommended, as all centers had very good expertise on MS, they were free to exclude or add examinations in relation to patients' manifestations. The third possible limitation concerns the MRI protocol, which was not standardized across the centers. However, it has to be pointed out that all centers followed recent Italian guidelines¹⁵; this guarantees a sufficient quality of the images that were also comparable between centers.

Finally, as already acknowledged, the 3-year clinical and radiologic follow-up was not enough to make a final—MS/no MS—diagnosis in all subjects. We will therefore continue to follow-up all patients without a conclusive diagnosis.

This observational, unsponsored, real-life study, based on common clinical practice, showed that, among diseases mimicking MS, nonspecific neurologic symptoms associated with atypical MRI lesions of suspected vascular origin, migraine associated with atypical MRI lesions, and NMO/D were the main alternative diagnoses.

The absence of IgG-OBs and of DIS, the presence of atypical MRI lesions, and normal VEP should be considered red flags for the misdiagnosis of MS. Despite the inclusion of several blood tests in the study, only a few of these (in particular, anti-aquaporin-4 antibodies) proved to be relevant in obtaining a conclusive alternative diagnosis.

Study funding

RIREMS meetings during the planning and the conduction of the project were supported by an unrestricted contribution by Merck Serono. The sponsor only contributed to the logistics of the meetings but had no role in the planning, study design, or conduction of the project.

Disclosure

M. Calabrese has served on scientific advisory boards for Biogen, Teva, Genzyme, Merck, Bayer, and Novartis and has received travel and/or speaker honoraria from Merck, Roche,

Biogen, Novartis, and Genzyme. C. Gasperini has received compensation for consulting from Bayer HealthCare Pharmaceuticals and Biogen Idec and as a speaker for lectures from Biogen Idec, Bayer HealthCare Pharmaceuticals, Genzyme, Merck Serono, Novartis, and Teva Pharmaceutical Industries. C. Tortorella received honoraria for speaking and travel grant from Biogen, Sanofi-Aventis, Merck Serono, Bayer-Schering, Teva, Genzyme, Almirall, and Novartis. G. Schiavi, G. Frisullo, P. Ragonese, and R. Fantozzi report no disclosures relevant to the manuscript. L. Prosperini: consulting fees from Biogen, Novartis, and Roche; speaker honoraria from Biogen, Genzyme, Merck Serono, Novartis, and Teva; travel grants from Biogen, Genzyme, Novartis, and Teva; research grants from the Italian MS Society (Associazione Italiana Sclerosi Multipla) and Genzyme. P. Annovazzi received honoraria for lecturing and participation in advisory boards and/or travel expenses for attending congresses and meetings from Merck, Biogen, Teva, Sanofi-Genzyme, Almirall, Mylan, Roche, and Novartis. C. Cordioli and M. Di Filippo report no disclosures relevant to the manuscript. D. Ferraro has served on scientific advisory boards for Biogen, Roche, and Novartis and has received travel and/or speaker honoraria from Merck, Teva, Biogen, Novartis, and Sanofi-Genzyme. A. Gajofatto received research funding and advisory board compensation from Merck-Serono. S. Malucchi, S. Lo Fermo, G. De Luca, and M. Stromillo report no disclosures relevant to the manuscript. E. Cocco serves on scientific advisory boards and received honoraria for speaking from Almirall, Bayer, Biogen, Merck Serono, Novartis, Sanofi-Genzyme, and Teva. A. Gallo, D. Paolicelli, R. Lanzillo, V. Tomassini, I. Pesci, and M. Rodegher report no disclosures relevant to the manuscript. C. Solaro have received honoraria and travel grants from TEVA, Merck-Serono, Biogen, Almirall, GW Pharma, and Genzyme. Go to Neurology.org/N for full disclosures.

Publication history

Received by *Neurology* August 22, 2018. Accepted in final form January 30, 2019.

Appendix Authors

Name	Location	Role	Contribution
Massimiliano Calabrese, MD	Department of Neuroscience, Biomedicine and Movements, University of Verona, Italy	Author	Designed and conceptualized study; role in the acquisition, analysis, and interpretation of data; drafted the manuscript for intellectual content
Claudio Gasperini, MD	Department of Neurosciences Azienda S. Camillo Forlanini Roma, Italy	Author	Designed and conceptualized study; role in the acquisition, analysis, and interpretation of data; drafted the manuscript for intellectual content

Continued

Appendix (continued)

Name	Location	Role	Contribution
Carla Tortorella, MD	Department of Basic Medical Sciences Neurosciences and Sense Organs, University of Bari, Italy	Author	Designed and conceptualized study; role in the acquisition, analysis, and interpretation of data; drafted the manuscript for intellectual content
Gianmarco Schiavi, MD	Department of Neuroscience, Biomedicine and Movements, University of Verona, Italy	Author	Designed and conceptualized study; role in the acquisition, analysis, and interpretation of data; drafted the manuscript for intellectual content
Giovanni Frisullo, MD	Policlinico Gemelli, Rome, Italy	Author	Designed and conceptualized study; role in the acquisition and interpretation of data; drafted the manuscript for intellectual content
Paolo Ragone, MD	Dipartimento di Biomedicina Sperimentale e Neuroscienze Cliniche (BIONEC), Università di Palermo, Italy	Author	Designed and conceptualized study; role in the acquisition and interpretation of data; drafted the manuscript for intellectual content
Roberta Fantozzi, MD	Istituto Neurologico Mediterraneo, Pozzilli, Italy	Author	Designed and conceptualized study; role in the acquisition and interpretation of data; drafted the manuscript for intellectual content
Luca Prosperini, MD	Department of Neurology and Psychiatry, Sapienza University of Rome, Italy	Author	Designed and conceptualized study; role in the acquisition and interpretation of data; drafted the manuscript for intellectual content
Pietro Annovazzi, MD	Multiple Sclerosis Center, ASST Valle Olona, PO di Gallarate (VA), Italy	Author	Designed and conceptualized study; role in the acquisition and interpretation of data; drafted the manuscript for intellectual content
Cinzia Cordioli, MD	Ospedale di Montichiari Spedali Civili di Brescia, Italy	Author	Designed and conceptualized study; role in the acquisition and interpretation of data; drafted the manuscript for intellectual content

Appendix (continued)

Name	Location	Role	Contribution
Massimiliano Di Filippo, MD	Clinica Neurologica, Università di Perugia, Italy	Author	Designed and conceptualized study; role in the acquisition and interpretation of data; drafted the manuscript for intellectual content
Diana Ferraro, MD	Department of Biomedical Metabolic and Neurosciences, University of Modena, Italy	Author	Designed and conceptualized study; role in the acquisition and interpretation of data; drafted the manuscript for intellectual content
Simona Malucchi, MD	AOU San Luigi Gonzaga Orbassano, Italy	Author	Designed and conceptualized study; role in the acquisition and interpretation of data; drafted the manuscript for intellectual content
Salvatore Lofermo, MD	Multiple Sclerosis Centre A.O.U. Policlinico-Vittorio Emanuele, Italy	Author	Designed and conceptualized study; role in the acquisition and interpretation of data; drafted the manuscript for intellectual content
Giovanna de Luca, MD	Neurology Clinic, Multiple Sclerosis Center SS Annunziata Hospital, Chieti, Italy	Author	Designed and conceptualized study; role in the acquisition and interpretation of data; drafted the manuscript for intellectual content
Marialaura Stromillo, MD	Department of Medicine, University of Siena, Italy	Author	Designed and conceptualized study; role in the acquisition and interpretation of data; drafted the manuscript for intellectual content
Eleonora Cocco, MD	Department of Medical Science and Public Health, University of Cagliari, Italy	Author	Designed and conceptualized study; role in the acquisition and interpretation of data; drafted the manuscript for intellectual content
Antonio Gallo, MD	Department of Medical, Surgical, Neurologic, Metabolic and Aging Science, University of Campania, Naples, Italy	Author	Designed and conceptualized study; role in the acquisition and interpretation of data; drafted the manuscript for intellectual content

Appendix (continued)

Name	Location	Role	Contribution
Damiano Paolicelli, MD	Department of Basic Medical Sciences, University of Bari, Italy	Author	Designed and conceptualized study; role in the acquisition and interpretation of data; drafted the manuscript for intellectual content
Roberta Lanzillo, MD	Department of Neuroscience, University Federico II, Naples, Italy	Author	Designed and conceptualized study; role in the acquisition and interpretation of data; drafted the manuscript for intellectual content
Valentina Tomassini, MD	Institute of Psychological Medicine and Clinical Neurosciences, Cardiff University School of Medicine, UK	Author	Designed and conceptualized study; role in the acquisition and interpretation of data; drafted the manuscript for intellectual content
Ilaria Pesci, MD	Ospedale di Vaio Centro SM, Fidenza, Italy	Author	Designed and conceptualized study; role in the acquisition and interpretation of data; drafted the manuscript for intellectual content
Mariaemma Rodegher, MD	Ospedale San Raffaele, Milan, Italy	Author	Designed and conceptualized study; role in the acquisition and interpretation of data; drafted the manuscript for intellectual content
Claudio Solaro, MD	Department of Rehabilitation, Mons L Novarese Hospital, Moncrivello, Italy	Author	Designed and conceptualized study; role in the acquisition, analysis, and interpretation of data; drafted the manuscript for intellectual content

References

- Poser CM, Paty DW, Scheinberg L, et al. New diagnostic criteria for multiple sclerosis: guidelines for research protocols. *Ann Neurol* 1983;13:227–231.
- McDonald WI, Compston A, Edan G, et al. Recommended diagnostic criteria for multiple sclerosis: guidelines from the International Panel on the Diagnosis of Multiple Sclerosis. *Ann Neurol* 2001;50:121–127.
- Polman CH, Reingold SC, Banwell B, et al. Diagnostic criteria for multiple sclerosis: 2010 revisions to the McDonald criteria. *Ann Neurol* 2011;69:292–302.
- Thompson AJ, Banwell BL, Barkhof F. Diagnosis of multiple sclerosis: 2017 revisions of the McDonald criteria. *Lancet Neurol* 2018;17:162–173.
- Brownlee WJ, Swanton JK, Altmann DR, Ciccarelli O, Miller DH. Earlier and more frequent diagnosis of multiple sclerosis using the McDonald criteria. *J Neurol Neurosurg Psychiatry* 2015;86:584–585.
- Gaetani L, Prosperini L, Mancini A, et al. Revisions of McDonald criteria shorten the time to diagnosis of multiple sclerosis in clinically isolated syndromes. *J Neurol* 2017;265:2684–2687.
- Solomon AJ, Bourdette DN, Cross AH, et al. The contemporary spectrum of multiple sclerosis misdiagnosis: a multicenter study. *Neurology* 2016;87:1393–1399.
- Solomon AJ, Naismith RT, Cross AH. Misdiagnosis of multiple sclerosis: impact of the 2017 McDonald criteria on clinical practice. *Neurology* 2018;92:26–33.
- Brownlee WJ, Hardy TA, Fazekas F, Miller DH. Diagnosis of multiple sclerosis: progress and challenges. *Lancet* 2017;389:1336–1346.
- Charil A, Yousry TA, Rovaris M, et al. MRI and the diagnosis of multiple sclerosis: expanding the concept of “no better explanation.” *Lancet Neurol* 2006;5:841–852. Review.
- Miller D, Weinschenker B, Filippi M, et al. Differential diagnosis of suspected multiple sclerosis: a consensus approach. *Mult Scler J* 2008;14:1157–1174.
- Katz Sand I. Classification, diagnosis, and differential diagnosis of multiple sclerosis. *Curr Opin Neurol* 2015;28:193–205.
- Filippi M, Rocca MA, Ciccarelli O, et al. MRI criteria for the diagnosis of multiple sclerosis: MAGNIMS consensus guidelines. *Lancet Neurol* 2016;15:292–303.
- The International Classification of Headache Disorders. *Cephalalgia* 2018;38:1–211.
- Wingerchuk DM, Banwell B, Bennett JL, et al. International consensus diagnostic criteria for neuromyelitis optica spectrum disorders: International Panel for NMO Diagnosis. *Neurology* 2015;85:177–189.
- Davatchi F, Assaad-Khalil S, Calamia KT, et al. The International Criteria for Behçet's Disease (ICBD): a collaborative study of 27 countries on the sensitivity and specificity of the new criteria. *J Eur Acad Dermatol Venereol* 2014;28:338–347.
- Shiboski CH, Shiboski SC, Seror R, et al. A consensus and data-driven methodology involving three international patient cohorts. *Ann Rheum Dis* 2017;76:9–16.
- Kleffner I, Dörr J, Ringelstein M, et al. Diagnostic criteria for Susac syndrome. *J Neurol Neurosurg Psychiatry* 2016;87:1287–1295.
- Petri M, Orbai AM, Alarcón GS, et al. Derivation and validation of the systemic lupus international collaborating clinics classification criteria for systemic lupus erythematosus. *Arthritis Rheum* 2012;64:2677–2686.
- Heymann RE, Paiva ES, Martinez JE, et al. New guidelines for the diagnosis of fibromyalgia. *Rev Bras Reumatol Engl Ed* 2017;57(suppl 2):467–476.
- Kurtzke JF. Rating neurologic impairment in multiple sclerosis: an expanded disability status scale (EDSS). *Neurology* 1983;33:1444–1452.
- Filippi M, Rocca MA, Bastianello S, et al. Guidelines from the Italian Neurological and Neuroradiological Societies for the use of magnetic resonance imaging in daily life clinical practice of multiple sclerosis patients. *Neurol Sci* 2013;34:2085–2093.
- Barkhof F, Filippi M, Miller D, et al. Comparison of MRI criteria at first presentation to predict conversion to clinically definite multiple sclerosis. *Brain* 1997;120:2059–2069.
- Kostulas VK, Link H, Lefvert AK. Oligoclonal IgG bands in cerebrospinal fluid: principles for demonstration and interpretation based on findings in 1114 neurological patients. *Arch Neurol* 1987;44:1041–1044.
- Odom JV, Bach M, Brigell M, et al. ISCEV standard for clinical visual evoked potentials: (2016 update). *Doc Ophthalmol* 2016;133:1–9.
- Geraldes R, Ciccarelli O, Barkhof F, et al, on behalf of the MAGNIMS study group. The current role of MRI in differentiating multiple sclerosis from its imaging mimics. *Nat Rev Neurol* 2018;14:213.
- Kuhle J, Disanto G, Dobson R, et al. Conversion from clinically isolated syndrome to multiple sclerosis: a large multicentre study. *Mult Scler* 2015;21:1013–1024.