

# Horseshoe appendix identified during laparoscopic appendectomy

## A case report and literature review

Sang-Ji Choi, MD, Gibong Chae, MD, PhD\*, Sung-Bae Park, MD, PhD, Seong Kweon Hong, MD, PhD, Yang Hee Kim, MD, Suk-Bae Moon, MD, PhD, Song-Yi Kim, MD, Hwansoo Kim, MD

### Abstract

**Rationale:** The horseshoe anomaly of the vermiform appendix is extremely rare. Preoperative confirmation of this anomaly is difficult; therefore, routine procedures, such as appendectomy, may become unexpectedly challenging when such anomalies are encountered during the surgical process.

**Patient concerns:** A 33-year-old man presented with abdominal pain in the right lower abdomen owing to acute appendicitis confirmed via computed tomography. Immediate laparoscopic appendectomy was decided as the method for treatment.

**Diagnosis:** Horseshoe anomaly was diagnosed as a gross finding during surgery.

**Intervention:** First, the appendiceal base was resected and appendectomy was performed via the retrograde method because the appendiceal tip was curled behind the cecum. However, it was discovered that the appendiceal tip was connected to the lateral part of the ascending colon and showed a horseshoe-shaped anomaly. The second appendiceal base arising from the ascending colon was also ligated, and the appendectomy was completed without any further complications.

**Outcomes:** After successful completion of appendectomy, the patient was discharged without any complications 2 days later.

**Lessons:** An appendiceal anomaly is rarely seen during appendectomy or other forms of abdominal surgery; however, the ability of surgeons to both recognize and categorize an appendiceal anomaly is crucial if detected during surgery. After successfully recognizing the horseshoe anomaly of the appendix, it is important to know that 2 appendiceal base ligations will be required to complete the surgery successfully.

**Abbreviation:** CT = computed tomography.

**Keywords:** appendiceal anomaly, horseshoe appendicitis

## 1. Introduction

Acute appendicitis is a very common disease,<sup>[1]</sup> and appendectomy is a relatively uncomplicated procedure for surgeons.<sup>[2]</sup> At the start of a routine appendectomy, it is usually not difficult to locate

the vermiform appendix. When the appendix is perforated or when a phlegmon is present, precise visualization of the appendix is often more problematic; nevertheless, the procedure should not be too challenging for an experienced surgeon, particularly when assisted by preoperative computed tomography (CT) scans. Even during cases of simple appendicitis, the appendix may not be located precisely where the surgeon anticipates, thereby making the operation more difficult. An appendiceal anomaly is one such situation where the appendix morphology may be different from what is expected. Therefore, we present a case of laparoscopic appendectomy for the extremely rare horseshoe appendix.

## 2. Case presentation

A 33-year-old man presented with an acute onset of abdominal pain that began 1 day prior to admission; the pain originated around the umbilicus, but later shifted to the right lower abdomen, and was associated with nausea and vomiting by the second day. There was no relevant medical, family, or psychosocial history; other pertinent co-morbidities and interventions were not noted. The vital signs of the patient during the admission were as follows: blood pressure 120/80 mm Hg, heart rate 80 beats/min, respiration rate 12 breaths/min, and body temperature 37°C. Physical examination showed tenderness in the right lower abdomen, but no rebound tenderness. Results for blood laboratory values were normal, except for a slight elevation in the white blood cell count of 11,100/μl. Acute appendicitis was suspected and soon confirmed through an abdominal CT scan

Editor: N/A.

This study did not receive any funding.

The study was approved by the institutional ethics board of Kangwon National University Hospital.

Written informed consent was obtained from the patient for publication of this case presentation and accompanying images.

The authors declare that they have no competing interest.

Department of Surgery, Kangwon National University Hospital, Kangwon National University School of Medicine, Chuncheon, South Korea.

\* Correspondence: Gibong Chae, Department of Surgery, Kangwon National University Hospital, Kangwon National University School of Medicine, 156 Baekryoung-ro, Chuncheon 200-722, South Korea (e-mail: cgb3377@kangwon.ac.kr).

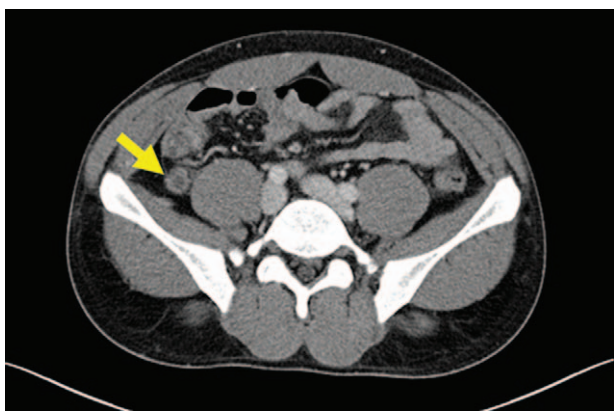Copyright © 2019 the Author(s). Published by Wolters Kluwer Health, Inc. This is an open access article distributed under the terms of the Creative Commons Attribution-Non Commercial-No Derivatives License 4.0 (CCBY-NC-ND), where it is permissible to download and share the work provided it is properly cited. The work cannot be changed in any way or used commercially without permission from the journal.

Medicine (2019) 98:5(e14104)

Received: 20 August 2018 / Received in final form: 12 December 2018 /

Accepted: 18 December 2018

<http://dx.doi.org/10.1097/MD.0000000000014104>



**Figure 1.** Appendiceal dilatation with wall enhancement in abdominal CT (arrows indicate the dilatated appendix). CT = computed tomography.

(Fig. 1), prompting an immediate laparoscopic appendectomy to be performed after informed consent was obtained.

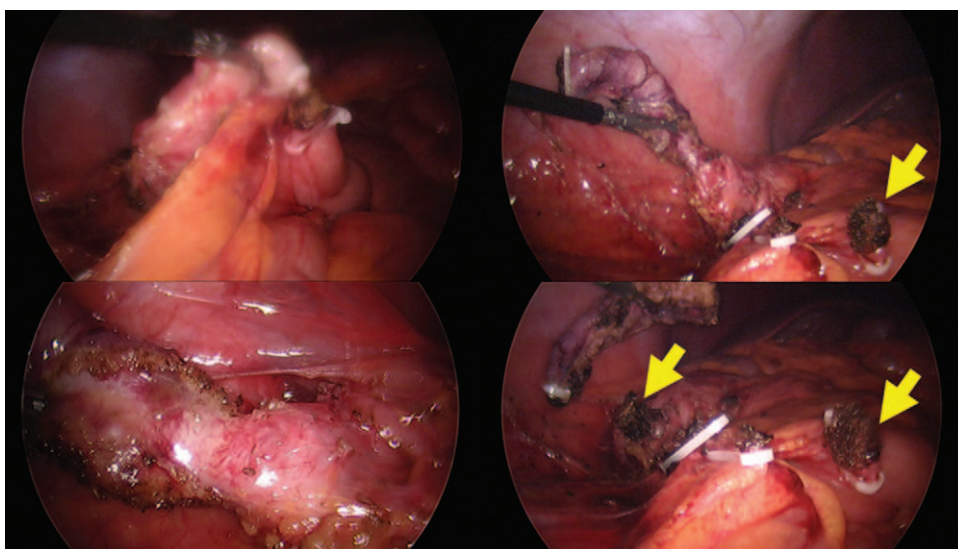
According to the operative findings, the appendix was a retrocecal type, and was curled behind the ascending colon. Initially, the appendiceal tip could not be located, so the resection of the appendiceal base proceeded first by using the retrograde method, and the appendiceal tissue was dissected in the direction of the tip. When the tip of the appendix was located, the noted inflammation was not severe, but it was located fairly superior to the cecum and connected to the lateral part of the ascending colon (Fig. 2). In fact, it was not simply adhered to the ascending colon, but rather the lumen itself was connected. After checking the initially resected appendiceal base several times, we confirmed that the original vermiform appendix base position was indeed at the confluence of the tenia coli of the cecum. A second appendiceal base arising from the ascending colon was also ligated, and the appendectomy was completed without any further problems. The patient made an uneventful recovery and was discharged from the hospital 2 days later. Postoperative follow-up was scheduled for the next week to evaluate the wound and ensure no complications developed.

### 3. Discussion and conclusions

The horseshoe anomaly of the appendix is a very rare anomaly. Based on our review of the literature, this patient is the seventh reported case of a horseshoe appendix (Table 1).

The classification system for appendiceal anomalies was first developed by Cave in 1936,<sup>[9]</sup> modified by Wallbridge in 1962,<sup>[10]</sup> and further modified by Biermann in 1993.<sup>[11]</sup> In 2010, however, Calota et al proposed a new classification system that adds a classification by shape, because the horseshoe appendix was not included anywhere in previous classification systems.<sup>[10]</sup> This proposed classification system is a relatively simple one that can cover all the anomalies reported so far, including the horseshoe appendix (Table 2). The system largely categorized the appendiceal anomalies based on shape and/or number. The numerical appendiceal anomalies were further divided into multiple (multifarious) or none at all (congenital agenesis). In the case of multiple appendices, a distinction was made as to whether the duplication was partial or complete. A partial duplication (2A) was one where both appendices shared a common Y-shaped base on a single cecum; in contrast, there could be 2 completely separate appendices, each with its own cecum (2C). A complete duplication of the appendix on a single cecum (2B) was subdivided into the following 4 types: 2 appendices symmetrically placed on either side of the ileocecal valve (B1 or avian type); 1 appendix arose from the cecum as usual, and the other from the cecum in the tenia coli (B2 or tenia coli cecum type); and where 1 appendix arose from the cecum as usual, and the duplicate arose from either the hepatic (B3) or splenic (B4) flexure along the tenia coli. In the triplex appendix category (2D), there was a complete triplication of the appendix on the cecum.<sup>[10]</sup>

Precisely classifying and recognizing any anomaly of the appendix is very important to the surgeon, because it is closely related to legal disputes. The patient may have thought that their appendicitis was completely cured, but because the surgeon missed a duplicate appendix, appendicitis may recur, leading to questions regarding whether an appendectomy was even performed.<sup>[12]</sup> If a horseshoe anomaly is not recognized, a stump perforation may potentially occur if the other appendiceal stump sections were not treated properly. From our clinical observations, there seem to be more postoperative complications



**Figure 2.** Horseshoe-shaped appendix with sagittal disposal, intraoperative aspects (arrow indicates the appendiceal stump).

**Table 1****Reported cases of horseshoe appendix.**

Author, yr	Age, yr	Sex	Period of detection	Open or laparoscopy	Diagnosis	Operation	Type	Other anomalies
Mesko (1989) <sup>[3]</sup>	33	Male	Intraoperative	Open	Sigmoid diverticulitis	Hartmann operation and appendectomy	Frontal	None
DasGupta (1999) <sup>[4]</sup>	48	Male	Intraoperative	Laparoscopic	Cecal perforation	Interval appendectomy and simple suturing	Frontal	None
Calota (2010) <sup>[5]</sup>	43	Female	Intraoperative	Open	Appendicitis	Appendectomy	Frontal	None
Oruc (2013) <sup>[6]</sup>	64	Female	Intraoperative	Open	Appendicitis	Appendectomy	Frontal	None
Singh (2016) <sup>[7]</sup>	4	Male	Intraoperative	Open	Appendicitis	Appendectomy	Sagittal	None
Takabatake (2016) <sup>[8]</sup>	78	Male	Postoperative	Laparoscopic	Adenoma in colon	Ileocecectomy	Frontal	None
Our case	33	Male	Intraoperative	Laparoscopic	Appendicitis	Appendectomy	Sagittal	None

**Table 2****Simplified classification system proposed by Calota<sup>[5]</sup>.**

## Number anomalies

1. Congenital agenesis
2. Multifarious appendices
  - A. Partial duplication
  - B. Duplex appendix on a single cecum
    - B1. Avian type
    - B2. Taenia coli cecum type
    - B3. Taenia coli hepatic flexure type
    - B4. Taenia coli splenic flexure type
  - C. Duplex appendix on a 2 cecum
  - D. Triplex appendix

## Shape anomalies

1. Horseshoe appendix
  - Frontal disposal of mesoappendix
  - Sagittal disposal of mesoappendix

among appendectomy cases when the surgeon had trouble confirming the normal anatomy during the procedure, and our case report is a reminder for considering the existence of an appendiceal anomaly.

An appendiceal anomaly is rarely seen during an appendectomy or other abdominal surgery, but it is very important to be able to both recognize and categorize one should it exist. While the horseshoe anomaly is an extremely rare anatomical malformation among all the known appendiceal anomalies, our case report hopefully reminds surgeons that sometimes even a routine procedure can reveal the unusual. After successfully recognizing the horseshoe appendiceal anomaly, it is important to know that 2 stump treatments are required to complete the surgery successfully.

**Author contributions**

Supervision: Gibong Chae.

Writing – original draft: Sang-Ji Choi.

Writing – review and editing: Gibong Chae, Sung-Bae Park, Seong Kweon Hong, Yang Hee Kim, Suk-Bae Moon, Song-Yi Kim, Hwansoo Kim.

Sang-Ji Choi orcid: 0000-0002-0757-4061.

**References**

- [1] Ferris M, Quan S, Kaplan BS, et al. The global incidence of appendicitis: a systematic review of population-based studies. *Ann Surg* 2017;266:237–41.
- [2] Masoomi H, Mills S, Dolich MO, et al. Comparison of outcomes of laparoscopic versus open appendectomy in adults: data from the Nationwide Inpatient Sample (NIS), 2006–2008. *J Gastrointest Surg* 2011;15:2226–31.
- [3] Mesko TW, Lugo R, Breitholtz T. Horseshoe anomaly of the appendix: a previously undescribed entity. *Surgery* 1989;106:563–6.
- [4] DasGupta R, Reber PU, Patel AG. Horseshoe appendicitis. *Eur J Surg* 1999;165:1095–6.
- [5] Calota F, Vasile I, Mogoanta S, et al. Horseshoe appendix: an extremely rare anomaly. *Chirurgia* 2010;105:271–4.
- [6] Oruc C, Isik O, Ureyen O, et al. An extremely rare appendiceal anomaly: horseshoe appendicitis. *TJTES* 2013;19:385–6.
- [7] Singh Ch G, Nyuwi KT, Rangaswamy R, et al. Horseshoe appendix: an extremely rare appendiceal anomaly. *J Clin Diagn Res* 2016;10:PD25–6.
- [8] Takabatake K, Ikeda J, Furuke H, et al. A case of a horseshoe appendix. *Surg Case Rep* 2016;2:140.
- [9] Cave AJ. Appendix vermiformis duplex. *J Anat* 1936;70:283–92.
- [10] Wallbridge PH. Double appendix. *Br J Surg* 1962;50:346–7.
- [11] Biermann R, Borsky D, Gogora M. Double appendicitis – a rare pathologic entity. *Der Chirurg* 1993;64:1059–61.
- [12] Maizels G. Duplication of the vermiform appendix. *S Afr Med J* 1966;40:1123–5.