

# Comparable Clinical and Radiologic Outcomes Between an Anatomic Tunnel and a Low Tibial Tunnel in Remnant-Preserving Posterior Cruciate Ligament Reconstruction

Kyoung Ho Yoon,\* MD, Jung-Suk Kim,\* MD, Jae-Young Park,\* MD, Soo Yeon Park,<sup>†</sup> PhD, Raymond Yeak Dieu Kiat,<sup>‡</sup> MD, and Sang-Gyun Kim,<sup>§||</sup> MD

*Investigation performed at the Department of Orthopaedic Surgery, Kyung Hee University Hospital, Seoul, Republic of Korea*

**Background:** There is currently no consensus on the optimal placement of the tibial tunnel for remnant-preserving posterior cruciate ligament (PCL) reconstruction.

**Purpose/Hypothesis:** The purpose of this study was to compare the clinical and radiologic outcomes of remnant-preserving PCL reconstruction using anatomic versus low tibial tunnels. We hypothesized that the outcomes of low tibial tunnel placement would be superior to those of anatomic tibial tunnel placement at the 2-year follow-up after remnant-preserving PCL reconstruction.

**Study Design:** Cohort study; Level of evidence, 3.

**Methods:** We retrospectively reviewed the data for patients who underwent remnant-preserving PCL reconstruction between March 2011 and January 2018 with a minimum follow-up of 2 years (N = 63). On the basis of the tibial tunnel position on postoperative computed tomography, the patients were divided into those with anatomic placement (group A; n = 31) and those with low tunnel placement (group L; n = 32). Clinical scores (International Knee Documentation Committee subjective score, Lysholm score, and Tegner activity level), range of motion, complications, and stability test outcomes at follow-up were compared between the 2 groups. Graft signal on 1-year follow-up magnetic resonance imaging scans was compared between 22 patients in group A and 17 patients in group L.

**Results:** There were no significant differences between groups regarding clinical scores or incidence of complications, no between-group differences in posterior drawer test results, and no side-to-side difference on Telos stress radiographs ( $5.2 \pm 2.9$  mm in group A vs  $5.1 \pm 2.8$  mm in group L;  $P = .900$ ). Postoperative 1-year follow-up magnetic resonance imaging scans showed excellent graft healing in both groups, with no significant difference between them.

**Conclusion:** The clinical and radiologic outcomes and complication rate were comparable between anatomic tunnel placement and low tibial tunnel placement at 2-year follow-up after remnant-preserving PCL reconstruction. The findings of this study suggest that both tibial tunnel positions are clinically feasible for remnant-preserving PCL reconstruction.

**Keywords:** knee; posterior cruciate ligament; remnant preservation; tibial tunnel; clinical outcome; side-to-side difference

With advances in surgical techniques, posterior cruciate ligament (PCL) reconstruction has become widely used as an effective treatment for patients with PCL insufficiency. Clinical studies have reported satisfactory clinical outcomes of PCL reconstruction, even at long-term follow-up.<sup>25,31</sup> However, consensus is lacking as to which is the better surgical technique regarding graft choice, number of graft bundles, technique for creating tibial tunnel, and fixation methods.<sup>2,17,19,24,26</sup>

Interest has increased in the remnant-preserving technique for PCL reconstruction.<sup>4,5,16</sup> Previous clinical studies have reported excellent outcomes of PCL reconstruction with remnant preservation.<sup>12,14,18,27</sup> This technique has several advantages. For example, the PCL remnant is helpful for revascularization of grafts, thereby promoting graft healing.<sup>10</sup> The mechanoreceptors in remnant fibers also preserve proprioception.<sup>5,14,15</sup> Moreover, several authors have demonstrated that the PCL remnant works like a soft tissue cushion to prevent the “killer-turn” effect at the tunnel orifice.<sup>11,19</sup>

In the remnant-preserving technique for PCL reconstruction, the tibial tunnels are located at the distal lateral

The Orthopaedic Journal of Sports Medicine, 9(2), 2325967120985153  
DOI: 10.1177/2325967120985153  
© The Author(s) 2021

This open-access article is published and distributed under the Creative Commons Attribution - NonCommercial - No Derivatives License (<https://creativecommons.org/licenses/by-nc-nd/4.0/>), which permits the noncommercial use, distribution, and reproduction of the article in any medium, provided the original author and source are credited. You may not alter, transform, or build upon this article without the permission of the Author(s). For article reuse guidelines, please visit SAGE's website at <http://www.sagepub.com/journals-permissions>.

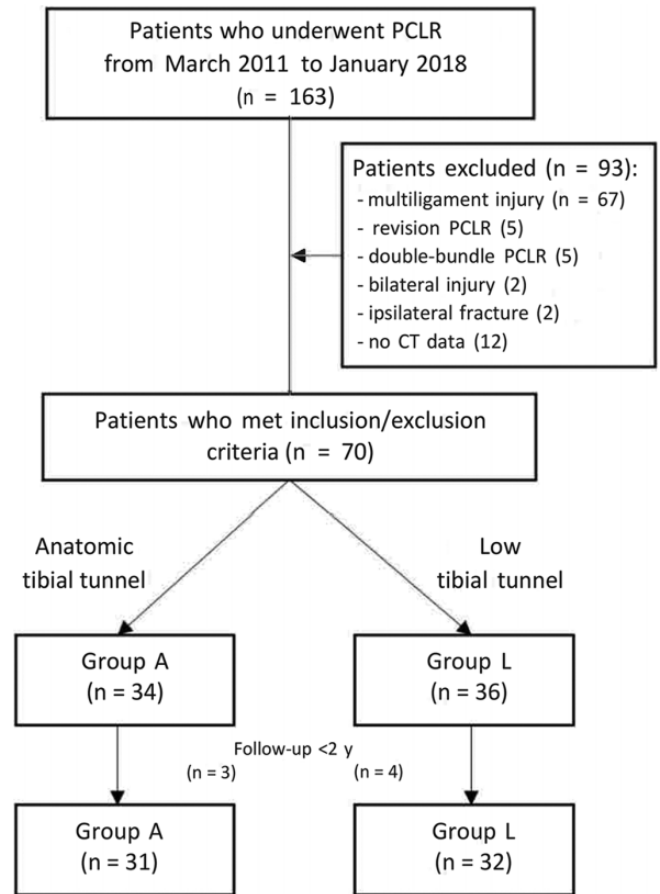
portion of the PCL tibial attachment to avoid damage to the PCL remnant. However, the positions of the tibial tunnels differ slightly among studies. Ahn and Lee<sup>1</sup> and Lee et al<sup>15</sup> created the tibial tunnel at the distal lateral portion of the PCL tibial attachment. More specifically, the tunnel was located within the PCL fossa (above the “champagne glass drop-off”).<sup>1,15</sup> Alternatively, Fanelli<sup>6</sup> recommended creating the tibial tunnel on the inferior lateral part of the PCL fossa (below the champagne glass drop-off). Although both tibial tunnel placements have shown excellent clinical outcomes in previous studies, few studies have compared the clinical outcomes between the anatomic tibial tunnel (above the champagne glass drop-off) and low tibial tunnel (below the champagne glass drop-off) placements. Therefore, the effect of different tibial tunnel positions on the clinical outcomes of remnant-preserving PCL reconstruction is not clear.

The purpose of this study was to compare the clinical and radiologic outcomes of remnant-preserving PCL reconstructions using anatomic and low tibial tunnels. We hypothesized that the 2-year follow-up outcomes would be superior for low tibial tunnel placement compared with anatomic tibial tunnel placement.

## METHODS

After obtaining institutional review board approval, we retrospectively reviewed patients who underwent PCL reconstruction between March 2011 and January 2018. Patients who underwent remnant-preserving single-bundle PCL reconstruction were included in this study. The exclusion criteria were as follows: (1) revision PCL reconstruction, (2) double-bundle PCL reconstruction, (3) bilateral PCL injury, (4) concomitant ipsilateral fracture around the knee, (5) insufficient computed tomography (CT) data, and (6) multi-ligamentous injury requiring combined ligament surgery. A total of 70 patients met the inclusion criteria of the study. Of the 70 patients, 7 were lost to follow-up before the end of the 2-year follow-up period and were thus excluded. Ultimately, 63 patients were enrolled in the study (Figure 1).

For the subgroup analysis, the position of the tibial tunnel was evaluated. Until December 2014, the target point of the tibial tunnel was lower than the champagne glass drop-off for all patients who underwent primary single-bundle PCL reconstruction. Thereafter, it was changed to the anatomic (above the champagne glass drop-off) position. However, the final decision on grouping by tibial tunnel position was made by reviewing the postoperative CT scan as described in the following paragraphs.



**Figure 1.** Flowchart of patient enrollment in this study. CT, computed tomography; PCLR, posterior cruciate ligament reconstruction.

## Evaluation of Tibial Tunnel Position on 3-Dimensional CT

At 2 days after PCL reconstruction, postoperative CT scans were taken for all the patients, except those who refused it. The collimation was  $64 \times 0.625$  mm. The tube parameters were 120 kVp and 150 mA. The acquisition matrix was  $512 \times 512$  pixels. The field of view was 140 mm, and the slice thickness was 2.5 mm. The obtained image data sets were imported into 3-dimensional (3D) software (Aquaris; Tera-Recon) for analysis. The software program produces 3D reconstruction images for evaluating the tibial tunnel position.

<sup>||</sup>Address correspondence to Sang-Gyun Kim, MD, Department of Orthopaedic Surgery, Korea University Ansan Hospital, 123 Jeokgeum-ro, Danwon-Gu, Ansan-si, Gyeonggi-do, Republic of Korea (email: mup81@hotmail.com).

<sup>\*</sup>Department of Orthopaedic Surgery, Kyung Hee University Hospital, Seoul, Republic of Korea.

<sup>†</sup>Department of Physical Education, Graduate School of Education, Yongin University, Yongin-si, Gyeonggi-do, Republic of Korea.

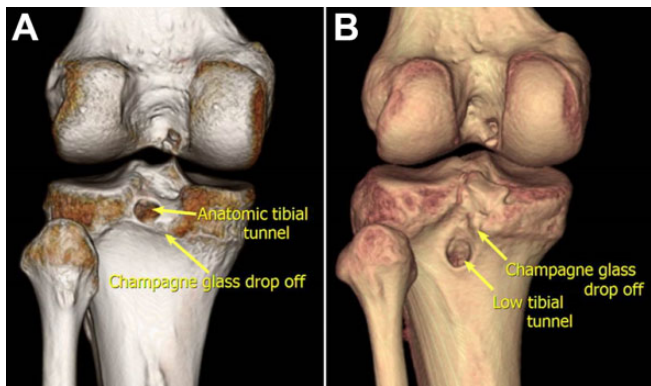
<sup>‡</sup>Department of Orthopaedics, Faculty of Medicine and Health Sciences, Universiti Putra Malaysia, Selangor, Malaysia.

<sup>§</sup>Department of Orthopaedic Surgery, Korea University Ansan Hospital, Ansan-si, Gyeonggi-do, Republic of Korea.

Final revision submitted August 21, 2020; accepted September 10, 2020.

The authors declared that there are no conflicts of interest in the authorship and publication of this contribution. AOSSM checks author disclosures against the Open Payments Database (OPD). AOSSM has not conducted an independent investigation on the OPD and disclaims any liability or responsibility relating thereto.

Ethical approval for this study was obtained from Kyung Hee University Hospital (file No. KHUH 2020-02-021).



**Figure 2.** Three-dimensional computed tomography images showing the position of the tibial tunnel. (A) Anatomic tibial tunnel, in which the center of the tibial tunnel is above the champagne glass drop-off. (B) Low tibial tunnel, in which the center of the tibial tunnel is below the champagne glass drop-off.

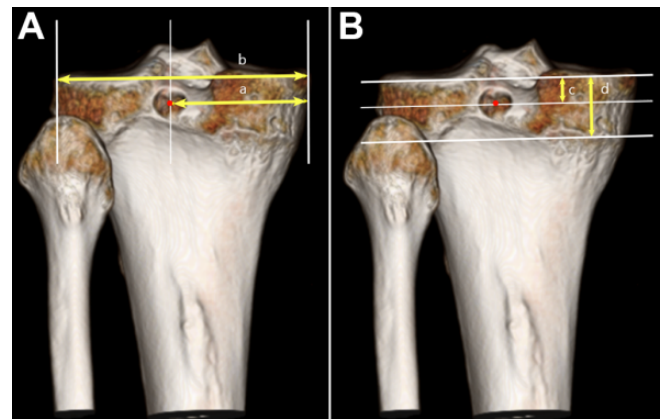
For the grouping by tibial tunnel position, the posterior view of the 3D reconstruction image was reviewed to identify the location of the center of the tunnel on the 3D CT scan. The patients were classified into the anatomic group (group A) and low tunnel group (group L) if the center of the tibial tunnel was above and below the champagne glass drop-off, respectively (Figure 2).

The positions of the tibial tunnels were evaluated in the medial-to-lateral and proximal-to-distal directions of the proximal tibia, as previously described by Shin et al.<sup>23</sup> In the medial-to-lateral direction, the absolute distance was measured from the medial margin of the tibial plateau to the center of the tibial tunnel aperture. Similarly, the tunnel position in the proximal-to-distal direction of the proximal tibia was measured as the absolute distance from the articular surface to the center of the tibial tunnel aperture. To standardize measurements of different-sized knees, the relative percentages were calculated, with the absolute medial-to-lateral distance divided by the proximal tibial plateau width and the absolute proximal-to-distal distance divided by the distance between the articular surface and the medial flare of the proximal tibia (Figure 3). All measurements were performed using the ruler tool contained in the Picture Archiving and Communication System (PACS) software Version 5025 (PI View STAR; Infinitt).

### Surgical Technique

All arthroscopic PCL reconstruction procedures were performed by a single experienced surgeon (K.H.Y.) using the single-bundle reconstruction technique as described in previous studies.<sup>30,31</sup> A fresh-frozen Achilles tendon allograft was used in all cases. The bony portion for the tibial tunnel was designed to be cylindrical, with 10-mm diameter and 25-mm length. The tendinous portion was fashioned to be 10 mm in diameter.

The tibial tunnel was prepared under fluoroscopic and arthroscopic visualization via the posterior transseptal



**Figure 3.** Evaluation of the tibial tunnel position in the medial-to-lateral and proximal-to-distal directions of the proximal tibia on 3-dimensional computed tomography scan of the right knee. (A) The tibial tunnel position in the medial-to-lateral dimension was calculated as a percentage by dividing the distance from the medial border of the tibial plateau to the tibial tunnel aperture center, *a*, by the total width of the tibial plateau, *b*. (B) The tibial tunnel position in the proximal-to-distal direction was calculated as a percentage by dividing from the lowest line of the tibial plateau to the center of the tibial tunnel aperture, *c*, by the distance between the articular surface and medial flare of the proximal tibia, *d*.

portal. An Acuflex PCL tibial guide (Smith & Nephew) was introduced through the anteromedial portal and advanced to the target point of the tibial tunnel. Until December 2014, the target point of the tibial tunnel was 5 to 10 mm below the champagne glass drop-off. Thereafter, it shifted to the lateral and distal corners of the original PCL tibial footprint (PCL fossa). The targeted tibial tunnel position in the medial-to-lateral dimension was the same in both periods. The guide pin was overdrilled using a 10-mm-diameter cannulated reamer, with care taken not to damage the PCL remnant.

To prepare the femoral tunnel, the Acuflex PCL femoral guide (Smith & Nephew) was introduced through the anteromedial portal and was positioned between the medial arch point and trochlear point, 7 mm proximal to the articular cartilage. Then, guide pins were inserted from outside to inside, and femoral tunnels were made by overdrilling using a 10-mm-diameter cannulated reamer, with care not to damage the PCL remnant.

After the graft was passed from the tibia to the femur, we ensured that the bone block made a tight press fit with the tibial tunnel. This bone block was fixed using an 8-mm metal interference screw (Titanium Interference Screws; Zimmer Biomet). Primary femoral fixation was performed using bioabsorbable interference screws (Biosure HA Interference Screw; Smith & Nephew). Staples or 6.5-mm cancellous screws with a spiked washer were also used for double fixation. Fixation was performed with the knee flexed to 90° and maximal anterior tibial translation.

## Postoperative Rehabilitation

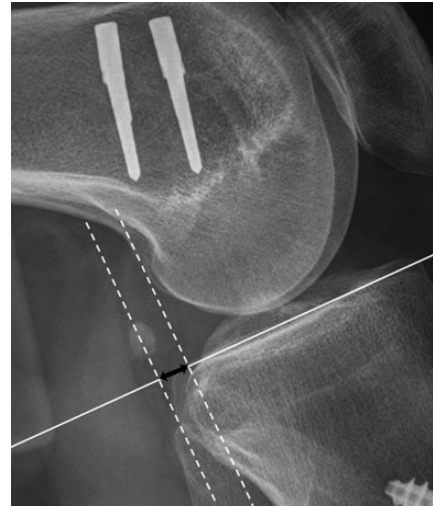Knee joint motion was limited by applying a long leg splint for 3 weeks after the surgery. We aimed for patients to obtain 90° of flexion by the sixth week and 135° by the third month. Weightbearing was not permitted during the first 3 weeks; tolerable weightbearing was permitted thereafter. Full weightbearing was allowed at the sixth week, and patients wore the brace until the third month. Sports activity was allowed 1 year postoperatively.

## Clinical Outcomes, Complications, and Stability Tests

Clinical outcomes and stability tests were evaluated preoperatively and at the 2-year follow-up. Clinical outcomes were assessed using 3 clinical scores (International Knee Documentation Committee [IKDC] subjective score, Lysholm score, and Tegner activity level) and range of motion (ROM). A questionnaire for clinical scores was completed, and ROM of the knee joint was measured using a goniometer when the patients visited the outpatient clinic after PCL reconstruction.

Postoperative complications, such as graft failure, recurrent hemarthrosis, vascular or nerve injury, infection, and stiffness, were compared between the groups. Graft failure was defined when any 1 of the following criteria was met: (1) the need for additional surgery (revision PCL reconstruction, high tibial osteotomy, or arthroplasty) because of unrelieved symptoms, (2) complete graft tear observed on magnetic resonance imaging (MRI) scans, and (3) grade III instability observed on stress radiographs (side-to-side difference [STSD], >10 mm).<sup>31</sup> Patients with >5° loss of full extension and <120° of knee flexion at the 2-year follow-up were considered to have stiffness.<sup>22</sup>

Stability of the knee joint was evaluated using the posterior drawer test and the STSD on Telos stress radiographs. Posterior drawer tests were performed by 1 senior surgeon (K.H.Y.) who was blinded to the group allocations. The STSDs in posterior tibial translation were measured on Telos stress radiographs taken at approximately 90° of knee flexion with a 134-N posterior load applied to the proximal tibia at the level of the tibial tubercle. To analyze the stress radiographs taken using the Telos unit, the fixed landmarks were defined using the femoral and tibial condyles to determine the tibial displacement relative to the femur. Initially, a line was drawn across the tibial plateau, and then perpendicular lines were drawn tangential to the most posterior contours of the femoral and tibial condyles (regardless of the medial or lateral condyle), respectively. The distance between these 2 points was measured to determine the skeletal displacement of the knee (Figure 4).<sup>13</sup> The STSD was calculated as the difference in the posterior tibial translations between the normal and abnormal sides. Two clinical fellows (J.-S.K., J.-Y.P.) blinded to the group allocations independently measured the STSD twice at a 2-week interval, and the inter- and intraobserver reliabilities were assessed.



**Figure 4.** Measurement of posterior tibial translation on the Telos stress radiograph. The white horizontal line was drawn across the tibial plateau, and then dotted lines were drawn tangential to the most posterior contours of the femoral and tibial condyles. The black double arrow indicates posterior tibial translation.

## Graft Signal on 1-Year Follow-up MRI Scans

All patients who had remnant-preserving PCL reconstruction were recommended to undergo postoperative MRI to evaluate the status of the graft at 1-year follow-up. Postoperative MRI was performed in 22 patients (71.0%) of group A and 17 patients (53.1%) of group L. MRI was performed using a 3.0-T system (Achieva; Philips) with a specific 8-channel SENSE-Knee coil. Proton density (PD)-weighted fat-suppression axial, T2-weighted spin-echo sagittal, PD-weighted spin-echo sagittal, and PD-weighted fat-suppression coronal MRI scans were obtained routinely during all knee examinations at our hospital.

The 4-level classification system of Howell et al<sup>9</sup> was used to evaluate the graft signal, in which grade I represents a homogeneously low signal intensity within the entire graft segment, grade II indicates at least 50% of normal-appearing ligament signal, grade III indicates that the graft segment exhibits <50% normal-appearing ligament signal, and grade IV indicates a diffuse increase in signal intensity with abnormal-appearing strands of ligament (Figure 5).

## Statistical Analysis

All statistical analyses were performed using SPSS Version 21.0 (IBM SPSS Statistics; IBM Corp). Quantitative variables were presented as mean and SD or median and interquartile range. The chi-square test and Fisher exact test were used to compare qualitative variables. Quantitative variables were compared using the independent *t* test for normally distributed continuous variables or the Mann-Whitney *U* test for nonnormally distributed data. A *P* value <.05 was considered indicative of statistical significance.



Intraobserver and interobserver reliabilities were determined by calculating the intraclass correlation coefficient (ICC) for posterior tibial displacement measurements. An ICC of <0.40 was considered poor, whereas ICCs of 0.40 to 0.59, 0.60 to 0.74, and 0.75 to 1.00 were considered fair, good, and excellent, respectively.<sup>7</sup>

A power analysis was performed to determine the sample size required to demonstrate statistically significant and clinically relevant differences. We defined a clinically relevant difference between group A and group L as 1.5 mm in posterior tibial translation on Telos stress radiographs.<sup>13,31</sup> When the SD was set at 2.0 mm as obtained from the pilot

study, the effect size was 0.75, and >58 patients (29 patients per group) were required to obtain ≥80% power.

RESULTS

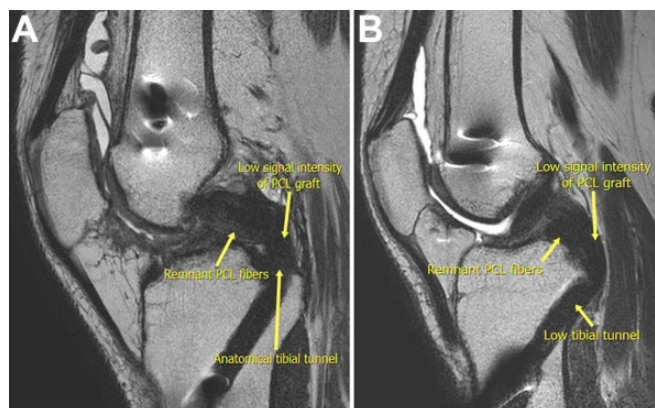
Based on the tibial tunnel position on 3D CT scan, 31 patients who had anatomic tibial tunnel placement (above the champagne glass drop-off) were classified as group A, whereas 32 patients who had low tibial tunnel placement (below the champagne glass drop-off) were classified as group L. The preoperative demographic data of enrolled patients are summarized in Table 1.

Tibial Tunnel Position on 3D CT Scan

The position of the tibial tunnel in the proximal-to-distal dimension was significantly higher in group A than in group L (48.1% ± 11.2% vs 108.8% ± 15.8%; *P* < .001). However, the tibial tunnel position in the medial-to-lateral dimension was not statistically significant between the groups (51.1% ± 3.5% in group A vs 51.1% ± 4.0% in group L) (Table 2).

Clinical Outcomes, Complications, and Stability Tests

At the 2-year follow-up, clinical scores and ranges of motion were not significantly different between the 2 groups (Table 3). There were 2 patients with graft failure in group A (6.5%) and 3 patients with graft failure in group L (9.4%). In group A, 2 patients had an STSD of >10 mm. In group L, 1 patient had a complete graft tear on MRI scan, and 2 patients had an STSD of >10 mm. No patients had >5° loss to full



**Figure 5.** T2-weighted sagittal magnetic resonance imaging scans at 1-year follow-up showing low signal intensity of the posterior cruciate ligament (PCL) graft and tibial tunnel position. (A) Anatomic tibial tunnel. (B) Low tibial tunnel.

**TABLE 1**  
Preoperative Demographic, Radiologic, and Clinical Data Between the Study Groups<sup>a</sup>

	Group A (n = 31)	Group L (n = 32)	P Value (test)
<b>Demographic data</b>			
Age at surgery, y	34.0 ± 16.3 (17 to 65)	39.4 ± 15.6 (16 to 66)	.180 (MWT)
Sex, male:female, n	25:6	21:11	.179 (CST)
BMI	24.7 ± 2.7 (18.9 to 30.5)	24.2 ± 2.9 (19.9 to 34.0)	.205 (MWT)
Injured side, right:left, n	14:17	17:15	.527 (CST)
Combined chondral injury, n (%)	4 (12.9)	7 (21.9)	.348 (CST)
Combined meniscal injury, n (%)	9 (29.0)	11 (34.4)	.649 (CST)
Time from injury to surgery, mo	16.4 ± 22.7 (0 to 96)	12.3 ± 22.4 (0 to 119)	.479 (MWT)
<b>Radiologic data</b>			
Hip-knee-ankle angle, deg	1.5 ± 2.2 (-2.7 to 6.9)	1.6 ± 2.6 (-4.5 to 5.4)	.601 (MWT)
K-L grade, 0:1:2:3:4, n	25:5:1:0:0	24:7:1:0:0	.845 (CST)
STSD, mm	10.7 ± 2.6 (5.3 to 16.1)	10.4 ± 2.9 (4.9 to 15.9)	.735 (MWT)
<b>Clinical data</b>			
IKDC subjective score	57.4 ± 14.2 (16.1 to 86.2)	53.0 ± 14.7 (19.5 to 87.4)	.147 (MWT)
Lysholm score	60.2 ± 18.1 (11.0 to 95.0)	56.6 ± 17.0 (24.0 to 90.0)	.410 (MWT)
Tegner activity score	4.4 ± 1.4 (2.0 to 8.0)	3.6 ± 1.5 (1.0 to 6.0)	.057 (MWT)
Limit of extension, deg	0.8 ± 2.9 (0.0 to 15.0)	0.8 ± 3.6 (0.0 to 20.0)	.639 (MWT)
Further flexion, deg	134.7 ± 12.7 (100 to 150)	136.6 ± 14.4 (90 to 150)	.407 (MWT)
Total range of motion, deg	133.9 ± 13.6 (100 to 150)	135.8 ± 17.0 (70 to 150)	.318 (MWT)

<sup>a</sup>Data are presented as mean ± SD (range) unless otherwise indicated. BMI, body mass index; CST, chi-square test; IKDC, International Knee Documentation Committee; K-L, Kellgren-Lawrence; MWT, Mann-Whitney *U* test; STSD, side-to-side difference.

TABLE 2  
Comparison of Tibial Tunnel Position on 3-Dimensional Computed Tomography Scans Between the Study Groups<sup>a</sup>

	Group A (n = 31)	Group L (n = 32)	P Value <sup>b</sup>
ML total, mm	75.2 ± 5.3 (64.8-88.4)	72.4 ± 6.4 (51.1-82.7)	.122
ML distance, mm	38.4 ± 2.9 (32.7-44.0)	36.9 ± 3.4 (31.2-44.6)	.068
ML percentage	51.1 ± 3.5 (44.9-58.1)	51.1 ± 4.0 (42.4-61.1)	.891
PD total, mm	17.9 ± 1.8 (14.3-21.6)	17.1 ± 2.4 (10.4-20.9)	.155
PD distance, mm	8.9 ± 2.3 (4.8-13.9)	18.6 ± 3.5 (12.4-25.2)	<.001
PD percentage	48.1 ± 11.2 (27.5-70.9)	108.8 ± 15.8 (80.0-143.2)	<.001

<sup>a</sup>Data are presented as mean ± SD (range). Bolded P values indicate statistically significant difference between groups ( $P < .05$ ). ML, medial to lateral; PD, proximal to distal.

<sup>b</sup>All P values were determined using the Mann-Whitney U test.

TABLE 3  
Comparison of Postoperative Clinical Scores and Ranges of Motion Between the Study Groups<sup>a</sup>

	Group A (n = 31)	Group L (n = 32)	P Value (test)
Postoperative clinical scores			
IKDC subjective	75.4 ± 11.2 (47.1-94.3)	72.5 ± 12.0 (47.1-96.6)	.466 (MWT)
Lysholm	79.2 ± 11.7 (45.0-98.0)	75.1 ± 13.5 (41.0-100.0)	.196 (MWT)
Tegner	5.5 ± 1.7 (3.0-9.0)	5.2 ± 1.5 (3.0-8.0)	.802 (MWT)
Postoperative range of motion, deg			
Limit of extension	0.1 ± 0.5 (0.0-3.0)	0.3 ± 1.2 (0.0-5.0)	.065 (MWT)
Further flexion	134.2 ± 10.2 (100-150)	132.8 ± 111.8 (100-150)	.507 (MWT)
Total range of motion	134.2 ± 10.2 (100-150)	132.4 ± 11.9 (100-150)	.434 (MWT)
Complications, n (%)	5 (16.1)	5 (15.6)	.956 (CST)
Graft failure	2 (6.5)	3 (9.4)	.668 (CST)
Recurrent hemarthrosis	0 (0.0)	0 (0.0)	NA
Vascular or nerve injury	0 (0.0)	0 (0.0)	NA
Infection	0 (0.0)	0 (0.0)	NA
Stiffness	3 (9.7)	2 (6.3)	.615 (CST)

<sup>a</sup>Data are presented as mean ± SD (range) unless otherwise indicated. CST, chi-square test; IKDC, International Knee Documentation Committee; MWT, Mann-Whitney U test; NA, not applicable.

TABLE 4  
Comparison of Postoperative Stability Tests Between the Study Groups<sup>a</sup>

	Group A (n = 31)	Group L (n = 32)	P Value (test)
Posterior drawer test, grade 0:1:2:3	15:15:1:0	20:10:1:1	.440 (CST)
STSD by Telos radiography, mm	5.2 ± 2.9 (0.0-13.0)	5.1 ± 2.8 (0.0-11.5)	.900 (MWT)

<sup>a</sup>Data are presented as No. or as mean ± SD (range). CST, chi-square test; MWT, Mann-Whitney U test; STSD, side-to-side difference.

extension, but 3 patients in group A and 2 patients in group L had <120° of knee flexion at the 2-year follow-up. However, no other complications were observed in either group, such as recurrent hemarthrosis, vascular or nerve injury, and infection. The incidence of postoperative complications was not statistically significant between groups (Table 3).

We found no statistically significant differences in stability test results of posterior drawer tests and STSD on Telos stress radiographs (Table 4). The STSDs on Telos stress radiograph were 5.2 ± 2.9 mm in group A and 5.1 ± 2.8 mm in group L ( $P = .900$ ). All ICC values for intra- and interobserver reliabilities were >0.8.

#### Graft Signal on 1-Year Follow-Up MRI Scans

Among the 39 patients who had 1-year follow-up MRI scans, 25 patients (64.1%) showed a graft signal of grade I, and 7 patients (17.9%) showed a graft signal of grade II. The 7 remaining patients (17.9%) had poor graft signals of grade III or IV. In group A, 90.9% had graft signals of grade I or II, and only 9.1% had graft signals of grade III or IV. Alternatively, in group L, 70.6% had graft signals of grade I or II, and 29.4% had graft signals of grade III or IV. However, these differences were not statistically significant (Table 5).

TABLE 5  
Comparison of Graft Signal on 1-Year Follow-up MRI Scans  
Between the Study Groups<sup>a</sup>

	Group A (n = 22)	Group L (n = 17)	P Value (test)
Grade of graft signal on MRI			.387 (CST)
Grade I	15 (68.2)	10 (58.8)	
Grade II	5 (22.7)	2 (11.8)	
Grade III	1 (4.5)	2 (11.8)	
Grade IV	1 (4.5)	3 (17.6)	

<sup>a</sup>Values are presented as n (%). CST, chi-square test; MRI, magnetic resonance imaging.

## DISCUSSION

The most important finding of this study was that the clinical and stability test outcomes were not significantly different between patients with anatomic tibial tunnels and patients with low tibial tunnels. The STSD on Telos stress radiographs, the primary outcome of this study, showed no intergroup difference at the 2-year follow-up. As well, we found no significant differences in clinical scores, ROM, and posterior drawer test results between the 2 groups. Graft signal on 1-year follow-up MRI scans also showed no significant difference between the groups. To our knowledge, this is the first study that compares clinical outcomes of remnant-preserving PCL reconstruction using the anatomic and low tibial tunnels. Based on our findings, the clinical and radiologic outcomes of low tibial tunnels were similar to those of anatomic tibial tunnels at the 2-year follow-up.

Previous clinical studies have reported satisfactory clinical outcomes after anatomic PCL reconstruction with remnant preservation. Lee et al<sup>16</sup> demonstrated that arthroscopic anatomic PCL reconstruction with remnant preservation showed high rates of return to sports and high patient satisfaction. The mean IKDC subjective score was  $88.7 \pm 14.1$ , and the mean Lysholm score was  $89.4 \pm 12.3$  at the minimum 2-year follow-up. A recent systematic review revealed that all clinical studies showed satisfactory outcomes with improvements in patient-reported outcomes and stability after remnant-preserving PCL reconstruction.<sup>26</sup> The findings of these clinical studies are consistent with the outcomes of our study. Our study showed satisfactory clinical outcomes and posterior stability, regardless of the tibial tunnel position. Moreover, the graft signal on postoperative MRI scans showed excellent graft healing in both groups.

Fanelli<sup>6</sup> introduced a modified tibial tunnel placement in the inferior lateral part of the PCL fossa (the "Fanelli tunnel") to reduce the killer-turn effect. Recent biomechanical studies have shown the effect of the Fanelli tunnel on graft stress and laxity of PCL reconstruction. Wang et al<sup>29</sup> evaluated peak graft stress using a 3D finite element model. In that study, low tibial tunnel placement in the Fanelli area (10 mm inferior and 5 mm lateral to the

PCL anatomic insertion) reduced the peak stress of the graft. Another study by Wang et al<sup>28</sup> compared the biomechanical results of PCL reconstruction between the anatomic tibial tunnel and low tibial tunnel using 3D-printed tibial models. Those investigators demonstrated that low tibial tunnel PCL reconstruction significantly reduced stress concentration and graft abrasion compared with anatomic PCL reconstruction and that low tibial tunnel placement may be a better choice for the reduction of the killer-turn effect during transtibial PCL reconstruction.

Based on the results of previous biomechanical studies, we hypothesized that a low tibial tunnel would have better clinical and radiologic outcomes than an anatomic tibial tunnel. However, clinical and radiologic outcomes did not show a significant difference between the 2 groups studied here. One possible explanation for the discrepancy between the outcomes of the biomechanical studies and the current clinical study is that the biomechanical experiments were not conducted under physiological conditions. In other words, they did not consider the functional effect of PCL remnant. The functional advantage of PCL remnant, which is well established in the literature, may affect clinical and radiologic outcomes.

Another possible reason for the discrepancy among results is that the 2 tibial tunnel positions in this study displayed no difference in the medial and lateral directions. Previous biomechanical studies have shown that anterior and posterior tibial tunnel position is less important than is medial and lateral placement for laxity control.<sup>3,8,20,21</sup> Galloway et al<sup>8</sup> compared the laxity of 5 different tibial graft placements and reported no significant difference in anteroposterior laxity between the more anterior and posterior tunnel placements. However, a significant difference in laxity was found between the medial and lateral placements from 30° to 60° of knee flexion. Bomberg et al<sup>3</sup> showed that the tibial attachment variation in the sagittal plane had minor effects on graft isometry.

The current study has several limitations. First, this study has a retrospective, nonrandomized design. Second, although many factors, such as combined chondral and meniscal injuries, need to be considered before PCL reconstruction, we excluded them and focused only on the tibial tunnel position. However, other independent variables that could affect the outcomes of PCL reconstruction were compared, and because no significant difference was observed between the groups, it was possible to conduct this comparative study. Third, the size of the sample was relatively small. However, we performed a power analysis to calculate an appropriate sample size and determined that a sample of 63 patients could achieve statistical significance with >80% power. Fourth, postoperative MRI scans were obtained in only 61.9% of patients. Given the possibility of selection bias and type II error, it is not possible to determine which tibial tunnel placement had better graft signal on postoperative MRI scans in this study. Instead, it could be interpreted that both groups showed excellent graft signal on MRI scans after surgery. Fifth, this study presented relatively short-term clinical outcomes. Mid- to

long-term clinical studies are required to investigate the survival of grafts and late complications, such as osteoarthritis progression.

## CONCLUSION

The clinical and radiologic outcomes and incidence of complications were comparable between anatomic and low tibial tunnel placements at the 2-year follow-up after remnant-preserving PCL reconstruction. The findings of this study suggest that both tibial tunnel placements are clinically feasible for remnant-preserving PCL reconstruction.

## REFERENCES

- Ahn JH, Lee SH. Anatomic graft passage in remnant-preserving posterior cruciate ligament reconstruction. *Arthrosc Tech*. 2014;3(5):e579-e582.
- Belk JW, Kraeutler MJ, Purcell JM, McCarty EC. Autograft versus allograft for posterior cruciate ligament reconstruction: an updated systematic review and meta-analysis. *Am J Sports Med*. 2018;46(7):1752-1757.
- Bomberg B, Acker J, Boyle J, Zarins B. The effect of posterior cruciate ligament loss and reconstruction on the knee. *Am J Knee Surg*. 1990;3(2):85-96.
- Chernchujit B, Samart S, Na Nakorn P. Remnant-preserving posterior cruciate ligament reconstruction: arthroscopic transseptal, rod and pulley technique. *Arthrosc Tech*. 2017;6(1):e15-e20.
- Eguchi A, Adachi N, Nakamae A, Usman M, Deie M, Ochi M. Proprioceptive function after isolated single-bundle posterior cruciate ligament reconstruction with remnant preservation for chronic posterior cruciate ligament injuries. *Orthop Traumatol Surg Res*. 2014;100(3):303-308.
- Fanelli GC. Arthroscopic transtibial tunnel posterior cruciate ligament reconstruction. *Oper Tech Sports Med*. 2015;23(4):289-297.
- Fleiss JL. *Design and Analysis of Clinical Experiments*. John Wiley & Sons; 2011.
- Galloway MT, Grood ES, Mehalik JN, Levy M, Saddler SC, Noyes FR. Posterior cruciate ligament reconstruction: an in vitro study of femoral and tibial graft. *Am J Sports Med*. 1996;24:437-445.
- Howell SM, Clark JA, Farley TE. Serial magnetic resonance study assessing the effects of impingement on the MR image of the patellar tendon graft. *Arthroscopy*. 1992;8(3):350-358.
- Jarvis DL, Waterman BR. Editorial commentary: stump sparing or footprint exposing? Management of the tibial remnant during posterior cruciate ligament reconstruction. *Arthroscopy*. 2019;35(9):2669-2670.
- Jung Y-B. Recent evolution of cruciate ligament surgery of the knee. *Clin Orthop Surg*. 2012;4(2):103-106.
- Jung Y-B, Jung H-J, Song K-S, Kim JY, Lee HJ, Lee J-S. Remnant posterior cruciate ligament-augmenting stent procedure for injuries in the acute or subacute stage. *Arthroscopy*. 2010;26(2):223-229.
- Kim SG, Kim SH, Choi WS, Bae JH. Supine lateral radiographs at 90° of knee flexion have a similar diagnostic accuracy for chronic posterior cruciate ligament injuries as stress radiographs. *Knee Surg Sports Traumatol Arthrosc*. 2019;27(8):2433-2439.
- Lee DC, Shon OJ, Kwack BH, Lee SJ. Proprioception and clinical results of anterolateral single-bundle posterior cruciate ligament reconstruction with remnant preservation. *Knee Surg Relat Res*. 2013;25(3):126-132.
- Lee DW, Choi HW, Kim JG. Arthroscopic posterior cruciate ligament reconstruction with remnant preservation using a posterior transseptal portal. *Arthrosc Tech*. 2017;6(5):e1465-e1469.
- Lee DW, Kim JG, Yang SJ, Cho SI. Return to sports and clinical outcomes after arthroscopic anatomic posterior cruciate ligament reconstruction with remnant preservation. *Arthroscopy*. 2019;35(9):2658-2668.
- Lee D-Y, Park Y-J. Single-bundle versus double-bundle posterior cruciate ligament reconstruction: a meta-analysis of randomized controlled trials. *Knee Surg Relat Res*. 2017;29(4):246.
- Lee SH, Jung YB, Lee HJ, Jung HJ, Kim SH. Remnant preservation is helpful to obtain good clinical results in posterior cruciate ligament reconstruction: comparison of clinical results of three techniques. *Clin Orthop Surg*. 2013;5(4):278-286.
- Lee YS, Jung YB. Posterior cruciate ligament: focus on conflicting issues. *Clin Orthop Surg*. 2013;5(4):256-262.
- Markolf KL, Feeley BT, Jackson SR, McAllister DR. Where should the femoral tunnel of a posterior cruciate ligament reconstruction be placed to best restore anteroposterior laxity and ligament forces? *Am J Sports Med*. 2006;34(4):604-611.
- Nicodeme J-D, Löcherbach C, Jolles B. Tibial tunnel placement in posterior cruciate ligament reconstruction: a systematic review. *Knee Surg Sports Traumatol Arthrosc*. 2014;22(7):1556-1562.
- Robertson GA, Coleman SG, Keating JF. Knee stiffness following anterior cruciate ligament reconstruction: the incidence and associated factors of knee stiffness following anterior cruciate ligament reconstruction. *Knee*. 2009;16(4):245-247.
- Shin YS, Han SB, Hwang YK, Suh DW, Lee DH. Tibial tunnel aperture location during single-bundle posterior cruciate ligament reconstruction: comparison of tibial guide positions. *Arthroscopy*. 2015;31(5):874-881.
- Shin Y-S, Kim H-J, Lee D-H. No clinically important difference in knee scores or instability between transtibial and inlay techniques for PCL reconstruction: a systematic review. *Clin Orthop Relat Res*. 2017;475(4):1239-1248.
- Song E-K, Park H-W, Ahn Y-S, Seon J-K. Transtibial versus tibial inlay techniques for posterior cruciate ligament reconstruction: long-term follow-up study. *Am J Sports Med*. 2014;42(12):2964-2971.
- Song J-G, Kim H-J, Han JH, et al. Clinical outcome of posterior cruciate ligament reconstruction with and without remnant preservation. *Arthroscopy*. 2015;31(9):1796-1806.
- Wang C-J, Chan Y-S, Weng L-H. Posterior cruciate ligament reconstruction using hamstring tendon graft with remnant augmentation. *Arthroscopy*. 2005;21(11):1401.
- Wang Z, Xiong Y, Chen G, et al. Modified tibial tunnel placement for single-bundle posterior cruciate ligament reconstruction reduces the "killer turn" in a biomechanical model. *Medicine (Baltimore)*. 2019;98(52):e18439.
- Wang Z, Xiong Y, Li Q, et al. Evaluation of tibial tunnel placement in single case posterior cruciate ligament reconstruction: reducing the graft peak stress may increase posterior tibial translation. *BMC Musculoskelet Disord*. 2019;20(1):1-8.
- Yoon KH, Bae DK, Song SJ, Cho HJ, Lee JH. A prospective randomized study comparing arthroscopic single-bundle and double-bundle posterior cruciate ligament reconstructions preserving remnant fibers. *Am J Sports Med*. 2011;39(3):474-480.
- Yoon KH, Kim EJ, Kwon YB, Kim S-G. Minimum 10-year results of single-versus double-bundle posterior cruciate ligament reconstruction: clinical, radiologic, and survivorship outcomes. *Am J Sports Med*. 2019;47(4):822-827.