

## LETTER TO THE EDITOR

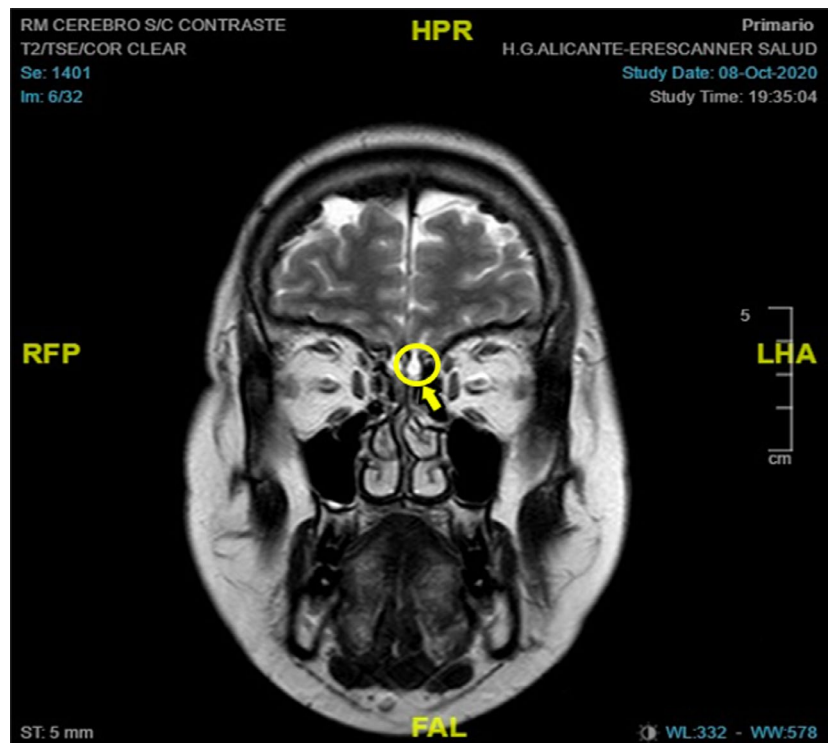
## Meningitis due to cerebrospinal fluid leak after nasal swab testing for COVID-19

A 41-year-old woman presented to the emergency department, in October 2020, with holocraneal headache worsened by position changes and fever up to 37.7°C that started 12 h. She had no medical history of cephalgia, visual loss or traumatic brain injury, or other secondary causes of cerebrospinal fluid (CSF) fistula. The patient had completed a nasal reverse transcription polymerase chain reaction (RT-PCR) COVID-19 testing in March 2020 which came back negative. One week after, she developed unilateral continuous rhinorrhoea with metallic taste. She was then diagnosed of allergic rhinitis by her general practitioner, who prescribed antihistaminics and a short-term antibiotherapy (amoxicillin-clavulanic), with no resolution of the symptoms. In July 2020, a nasal drainage tested positive for  $\beta$ 2-transferrin and head computed tomography was performed identifying a CSF fistula at the lamina cribrosa.

Once at the emergency department, physical examination revealed subtle neck stiffness, with no papillary oedema or other neurological signs. There were no signs of encephalopathy at any time. A blood test revealed elevation of inflammatory markers with leukocytosis (13,850/l) and C-reactive protein (101.3 mg/l).

Lumbar puncture revealed turbid CSF with a leukocyte count of 5480/ $\mu$ l, with predominance of polymorphonuclear cells (85%), 720 red cells/ $\mu$ l, proteins 776 mg/dl (normal value 12.00–60.00 mg/dl), lactic acid 10.3 mmol/l (normal value 0.00–2.30 mg/dl) and glucose 67 mg/dl (normal value 45.00–80.00 mg/dl). CSF antigens of neurotropic virus and bacteria were negative, and there was no growth in the germ culture. Head magnetic resonance imaging (MRI) was also performed identifying the presence of a left-side frontonasal CSF fistula leaking into superior ethmoidal cells, with no other pathological findings (Figure 1).

Empirical treatment with cefotaxime, vancomycin and dexamethasone was started for 14 days, and antipneumococcal and haemophilus vaccine was administered. The finding of CSF fistula was discussed with Neurosurgery Department. At the fifth day of antibiotics the rhinorrhoea stopped, and considering this as a sign of leak closure we opted for a conservative nonsurgical treatment. The patient had a good recovery: both headache and fever disappeared in the first 24 h and septic parameters in blood test normalized after 5 days; the patient is waiting for MRI control.



**FIGURE 1** High-resolution magnetic resonance imaging (T2 sequence) in the coronal plane in October 2020 after development of iatrogenic CSF leak. The yellow arrowhead indicates a left-side frontonasal CSF fistula leaking into superior ethmoidal cells

See commentary by J. Pernecky et al. on page 3552

## CONCLUSION

Cerebrospinal fluid fistulas appear as a result of the rupture between barriers from the nasal cavity and paranasal sinuses from the subarachnoid spaces. The reported iatrogenic CSF leaks from intranasal procedures or surgical trauma at the cribriform plate represent up to 16% of the secondary causes of CSF fistula, and contrast-enhanced MR cisternography is the gold standard for the diagnosis.[1] Recently, the first iatrogenic CSF leak after a nasal swab for COVID-19 in a patient with idiopathic intracranial hypertension and a skull base defect has been reported,[2] but meningitis was not described in that patient. Persistent rhinorrhoea is unlikely to close spontaneously and the risk of infection increases significantly. The global risk of meningitis before surgical treatment is about 30.6%.[3] The inflammation of the meninges and the form of granulation tissue can favour the closing of the fistula.[4]

The RT-PCR test is the gold standard for the diagnosis of COVID-19 disease, and in Spain about 16.2 million tests have been performed.[5] A technique with more sensitivity in the diagnosis of SARS-CoV-2 infection is RT-PCR of a sample from the nasopharyngeal area. Epistaxis occurring immediately or shortly following the removal of the swab is the most frequently reported adverse effect of the technique.[6] From the million RT-PCR tests run around the world this is the second case reported of CSF leak due to swab test of COVID-19, and the first one with meningitis. As the number of daily COVID-19 nasal and nasopharyngeal swab specimen collection procedures increases, we should be aware of CSF leaks as a possible meningitis cause in our patients. The use of minimally invasive techniques such as RT-PCR of COVID-19 is not exempt from risks and it is necessary a proper formation for the correct procedure of these techniques.

## ACKNOWLEDGEMENTS

The authors would like to sincerely thank the patient for giving permission to publish their case.

## CONFLICT OF INTEREST

All the authors declares that have no conflict of interest.

## AUTHOR CONTRIBUTIONS

Enrique Valdeolivas-Urbelz: writing original draft (equal); writing review and editing (equal). Marta Torregrosa-Ortiz: writing original

draft (equal); writing review and editing (equal). Jorge Alom Poveda: writing original draft (equal); writing review and editing (equal).

## DATA AVAILABILITY STATEMENT

Data sharing is not applicable to this article as no new data were created or analyzed in this study.

Francisco Jose Alberola-Amores 

Enrique Valdeolivas-Urbelz

Marta Torregrosa-Ortiz

María Álvarez-Sauco

Jorge Alom-Poveda


*Hospital General Universitario de Elche, Elche, Spain*

## Correspondence

Francisco Jose Alberola-Amores, Hospital General Universitario de Elche, Elche, Spain.

Email: cu.alberola@gmail.com

## ORCID

Francisco Jose Alberola-Amores  <https://orcid.org/0000-0002-3613-791X>

## REFERENCES

1. Zubillaga Rodríguez I, Fernández Alen JA, Sánchez Aniceto G, Montalvo Moreno JJ. Fístula de líquido cefalorraquídeo recidivante postraumática asociada a meningocele esfenoidal. Técnica abierta-endoscópica. *Rev Esp de Cirug Oral y Maxilofac.* 2012;34(4):172-179.
2. Sullivan CB, Schwalje AT, Jensen M, et al. Cerebrospinal fluid leak after nasal swab testing for coronavirus disease 2019. *JAMA Otolaryngol Head Neck Surg.* 2020;146(12):1179. <https://doi.org/10.1001/jamaoto.2020.3579>
3. Eljamel MS, Pidgeon CN, Toland J. MRI cisternography and the localization of CSF fistulae. *Br J Neurosurg.* 1994;8:433-437.
4. Fandiño J. Fístula de líquido cefalorraquídeo y meningitis por estreptococo equisimilis 16 años después de un traumatismo craneoencefálico. *Neurocirugía.* 2002;13(4):316-320.
5. Ministerio de sanidad. Mscbs. [internet]. [consultado 15 Nov 2020]. Disponible en: [https://www.mscbs.gob.es/profesionales/saludPublica/ccayes/alertasActual/nCov/documentos/COVID-19\\_pruebas\\_diagnosticas\\_12\\_11\\_2020.pdf](https://www.mscbs.gob.es/profesionales/saludPublica/ccayes/alertasActual/nCov/documentos/COVID-19_pruebas_diagnosticas_12_11_2020.pdf). Accessed on November 15, 2020.
6. Gupta K, Bellino PM, Charness ME. Adverse effects of nasopharyngeal swabs: three-dimensional printed versus commercial swabs. *Infect Control Hosp Epidemiol.* 2020;1:1. <https://doi.org/10.1017/ice.2020.297>