

Advantages of Combined PET-CT in Mediastinal Staging in Patients with Non-small Cell Lung Carcinoma

Nermina Beslic¹, Amera Sadija¹, Renata Milardovic¹, Timur Ceric², Sejla Ceric¹, Adnan Beganovic³, Spomenka Kristic⁴, and Semra Cavaljuga⁵

¹Clinic for Nuclear Medicine, University Clinical Centre, Sarajevo, Bosnia and Herzegovina

²Clinic for Oncology, University Clinical Centre, Sarajevo, Bosnia and Herzegovina

³Department of Medical Physics and Radiation Safety, University Clinical Centre, Sarajevo, Bosnia and Herzegovina

⁴Clinic for Radiology, University Clinical Centre, Sarajevo, Bosnia and Herzegovina

⁵Medical Faculty, University in Sarajevo, Bosnia and Herzegovina

Corresponding author: ass. prof. Nermina Beslic, MD, PhD. Clinic for Nuclear Medicine, University Clinical Centre, Bolnicka bb Sarajevo, Bosnia and Herzegovina. Tel: +387 61 745 882. ORCID ID: orcid.org/0000-0001-9656-6604. E-mail: nerminabeslic@gmail.com;

doi: 10.5455/aim.2016.24.99-102

ACTA INFORM MED. 2016 APR; 24(2): 99-102

Received: JAN 13, 2016 • Accepted: MAR 05, 2016

© 2016 Nermina Beslic, Amera Sadija, Renata Milardovic, Timur Ceric, Sejla Ceric, Adnan Beganovic, Spomenka Kristic, Semra Cavaljuga

This is an Open Access article distributed under the terms of the Creative Commons Attribution Non-Commercial License (<http://creativecommons.org/licenses/by-nc/4.0/>) which permits unrestricted non-commercial use, distribution, and reproduction in any medium, provided the original work is properly cited.

ABSTRACT

Introduction: Precise mediastinal lymph node staging in patients with non-small cell lung carcinoma (NSCLC) provides important prognostic information and it is obligatory in treatment strategy planning. 18Fluoro-deoxy-glucose (18F-FDG) positron emission tomography - computerized tomography (PET-CT) based on detection of metabolic activity showed superiority in preoperative staging of lung carcinoma. **Materials and Methods:** Total number of 26 patients diagnosed with NSCLC were included in this retrospective, cross-sectional study. Status of mediastinal lymph nodes was assessed in all patients comparing contrast enhanced CT and 18F-FDG PET-CT findings. **Discussion:** We found in our study that 50% of patients had different N stage on contrast enhanced CT comparing to 18F-FDG PET-CT findings. Among the total number of patients which had different nodal status on PET-CT comparing to CT alone, we found in our study that 54% of patients had change in further therapy protocol after PET-CT change of nodal stage. **Conclusion:** Combined PET-CT which offers advantages of both modalities is excellent method for nodal (N) staging, so it is recommended in initial staging in patients with NSCLC. PET-CT used preoperatively for mediastinal nodal staging has significant impact on further therapy planning and also has an consequential impact on health system savings.

Key words: NSCLC, mediastinal lymph nodes, CT, PET-CT.

1. INTRODUCTION

For patients diagnosed with non-small cell lung carcinoma the possibility of a surgical cure as the best option, is dependent upon the extent of disease, particularly mediastinal staging. Some data are that patients with metastases to the mediastinal lymph nodes have an average 5 year survival rate of cc 10% as compared with a survival rate of 50% in patients without mediastinal metastases (1). The status of mediastinal lymph nodes will strongly determine whether surgical resection of lung cancer is an option at all. The potential surgical cure can also cause certain mortality and morbidity and if disease is so extensive these surgical procedures could be considered futile. So accurate staging of mediastinal lymph nodes provides important prognostic information and is obligatory in determining treatment strategy (2).

Based on adequate mediastinal lymph node staging, individual treatment plans can be selected in order to achieve the best prognosis and also to be the

best cost-effective option (3).

Many studies shown that contrast enhanced CT as currently standard method for diagnosis and staging of NSCLC, did not show correlation between the presence of mediastinal metastases and nodal size which is main CT determinant for detection of metastatic disease (4).

The new approach obtained with hybrid diagnostic modality - positron emission tomography in combination with computerized tomography (PET-CT) using radio pharmaceutical 18fluoro-deoxy-glucose (18F FDG) is entirely different from CT in the detection of nodal metastasis. PET-CT is based on metabolic activity, and has shown superiority in nodal staging as more sensitive and specific diagnostic tool (5).

18F-FDG PET-CT is a value based diagnostic tool for many oncology patients providing adequate staging, therapy response assessment, as well as directing patient management and prognosis (6-11).

18F-FDG PET-CT is a highly sensitive, specific and accurate diagnostic imaging modality for preoperative staging of lung cancer comparing to conventional diagnostic imaging (12).

In ACCP evidence-based practice guidelines for noninvasive staging of NSCLC, the pooled sensitivity and specificity of CT scan for identifying mediastinal lymph node metastasis were 51% and 85%, respectively, while for PET-CT scan, the pooled estimates of sensitivity and specificity for detection of mediastinal metastasis were much higher 74% and 85%, respectively (13).

The use of PET-CT for preoperative staging of NSCLC especially staging of mediastinal lymph nodes also reduced both the total number of thoracotomies as well as the number of futile thoracotomies (14).

2. PATIENTS AND METHODS

Total number of 26 patients were diagnosed with non-small cell lung carcinoma in the period of February 2014 till March 2015, and all of them were included in this study.

This study is retrospective, cross-sectional, with inclusion of all patients which undergo PET-CT study during this certain period. Mediastinal lymph node stage was assessed in all patients comparing CT and PET-CT findings.

Contrast enhanced CT of thorax was performed in all patients 1-3 months before PET-CT scan. CT findings were analyzed and study was interpreted as positive based on shape and size of mediastinal lymph nodes.

PET-CT findings were analyzed and study was interpreted as negative when there is no abnormal accumulation of FDG. Every focus of increased FDG accumulation was recorded and classified as malignant, equivocal or benign based on shape, size and intensity of accumulation. Malignant accumulation of FDG was defined as focal accumulation with intensity greater than intensity of FDG accumulation in mediastinum, not related to physiological or benign processes. Any other area of increased FDG accumulation which could not be objectively characterized was defined as equivocal.

Statistical analysis

Descriptive statistic is used for obtaining main characteristics. Our investigation was planned to be conducted as an estimation of validity for specific diagnostic modality measuring sensitivity, specificity, positive predictive value (PPV) and negative predictive value (NPV) firstly for conventional diagnostic tool (contrast enhanced CT) and then for PET-CT. Nevertheless, mediastinoscopy, which in this case should be used as gold standard, is not performed routinely in University Clinical Center (UCC) in Sarajevo, where investigation was conducted.

This was the reason that we could not precisely validate PET-CT as a new diagnostic imaging modality. We used well known criteria for interpretation of conventional and newly-introduced hybrid diagnostic modality.

3. RESULTS

Among the total number of patients included in this study, there were 15 men (57, 7%) and 11 women (42, 3%). Based on histological type of non-small cell lung carcinoma distribution of patients was as follows: 14 (53,8%) patients had adenocarcinoma, 8 (30,8%) patients had squamocellular carcinoma

and 4 (15,4%) patients had large cell non-differentiated lung carcinoma as presented on Chart 1.

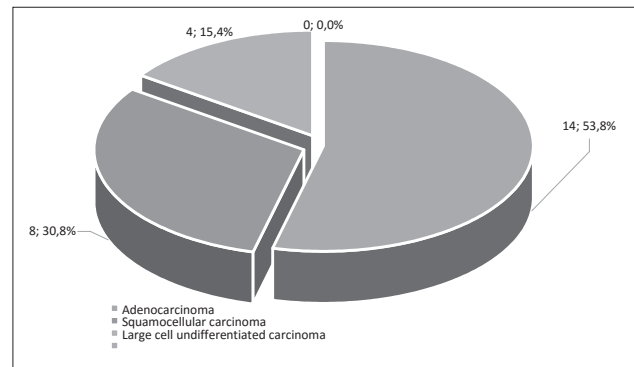


Chart 1. Patient distribution based on histological type of non-small cell lung carcinoma (n=26)

Results based on PET-CT and CT findings analysis are presented in Table 1.

	CT	PET-CT
N0	5	7
N1	7	4
N2	10	8
N3	4	7
Total	26	26

Table 1. Results of nodal stage diagnosis with CT comparing to findings acquired by PET-CT in all patients (n=26)

There was no difference in nodal (N) stage in 13 (50%) patients on CT findings versus PET-CT findings.

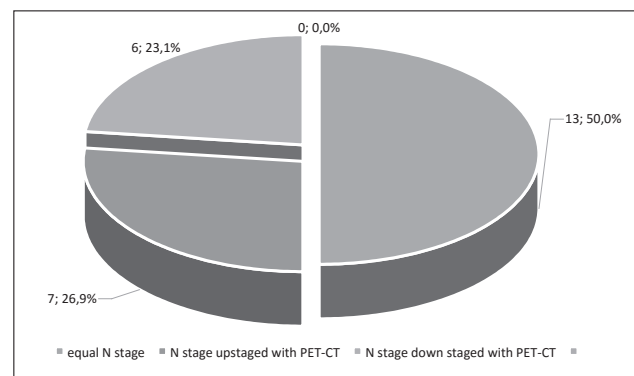


Chart 2. Distribution of nodal stage in patients (n=26) acquired by CT and PET-CT findings

N stage CT	PET-CT	Impact on treatment option
N stage- upstaged		
N0 1 patient	change in N3	Futile operation avoided
N1 2 patients	change in N2	No impact
N2 4 patients	change in N3	Futile operation avoided
N3 -	-	-
Total 7		
N stage- down staged		
N0 -	-	-
N1 3 patients	change in N0	No impact
N2 1 patient	change in N1	No impact
N3 2 patients	change in N1/N2	Operative treatment included
Total 6		

Table 2. Impact on treatment options in patients according to change of N stage with PET-CT comparing to CT findings (n=13)

Different nodal (N) stage on PET-CT findings comparing to CT findings had 13 (50%) patients: 7 (26,9%) of them were upstaged with PET-CT, and 6 (23,1%) patients were down staged with PET-CT (Chart 2).

Among total number of 13 patients which had different nodal stage on PET-CT finding comparing to CT finding, 7 patients (54%) had change in treatment strategy based on change in nodal status with PET-CT scanning (Table 2).

4. DISCUSSION

We found in our study that 50% of patients had different N stage on contrast enhanced CT comparing to 18F FDG PET-CT. Analyzing total number of patients (n=26) 26,9% of patients had upstaged N status after PET-CT study comparing to CT, and in 23,1% of patients PET-CT down staged status of mediastinal lymph nodes. In the study published in Journal of Nuclear Medicine in 2012., Gregory DL et al also found discrepancy in staging of NSCLC on PET-CT findings and conventional imaging (CT) in 51% patients, so 41% of patients were upstaged and only 9% of patients were down staged after PET-CT scan (15).

Among total number of patients which had different nodal stage on PET-CT comparing to CT (n=13) in our study, 54% of patients had change in treatment strategy due to changes in nodal status after PET-CT scan what also was found in study by Gregory DL et al from 2012 where significant impact on patient management (change in treatment modality) was observed in 42% of patients. It is also proved in this study that overall survival is strongly determined with PET-CT guided treatment option ($p < 0.0001$) (16).

In the study published in The New England Journal of Medicine in 2009 authors Fischer et al announced that PET-CT in preoperative staging of NSCLC has reduced total number of thoracotomies, as well as number of futile thoracotomies, comparing to the group of patients who had only conventional staging (17).

Some studies as that published by Steinert et al found that PET-CT is superior than CT for nodal staging with sensitivity of PET-CT of 89% and 57% for CT which suggest very important difference in further patient management (18).

In the study of Mona A. El-Hariri from 2012, integrated PET-CT appeared to be better than CT alone in mediastinal lymph node staging. Accuracy, sensitivity, specificity, PPV and NPV for detection of malignant lymph nodes was 88%, 89%, 88%, 73% and 100% for PET-CT versus 73%, 78%, 71%, 50% and 94% for CT alone (19).

We could not perform validation of diagnostic procedure in our study measuring sensitivity, specificity, PPV and NPV due to gold standard data insufficiency.

In meta analysis on performance of positron emission tomography and computerized tomography for mediastinal lymph node staging in patients with NSCLC published in 2003 by Gould et al, 39 studies met the inclusion criteria.

The authors constructed summary receiver operating characteristic curves for CT and FDG-PET-CT and they reveal that PET-CT was more accurate than CT for identifying lymph node metastases ($P < 0.001$). Median sensitivity and specificity for CT were lower than for PET-CT: 61% (interquartile range, 50% to 71%) and 79% (interquartile range, 66% to 89%), respectively for CT. Median sensitivity and

specificity for PET-CT were 85% (interquartile range, 67% to 91%) and 90% (interquartile range, 82% to 96%), respectively (20).

5. CONCLUSION

At the end we can conclude that precise staging of NSCLC preoperative, is obligatory in treatment strategy planning. CT alone as currently noninvasive test of choice has its limitations, so it is recommended to combine both diagnostic modalities in one scanning. Combined PET-CT which offers advantages of both modalities is excellent method for nodal (N) staging, and as such is strongly recommended in initial staging in patients with NSCLC. PET-CT used preoperative for determining N stage has a significant impact on further treatment planning, and with this we can also comment on considerable savings for health system.

Mediastinoscopy as gold standard which lacked in this study should be initiated in University Clinical Center, whereby it would be possible to determine mediastinal lymph node stage, and patients would not be exposed to futile thoracotomies. Also, costs rationalization would be accomplished. In the case of introduction of mediastinoscopy we could precisely validate diagnostic modalities, all for the sake of best therapy option for patients with non-small cell lung carcinoma.

- **Author's contribution:** Nermina Beslic gave contribution to the design of the study, to acquisition of the data, to analysis and interpretation of data and also she critically revised the article for important intellectual content of the final version. Amera Sadija contributed in drafting the article, conception of the topic, in the acquisition and interpretation of data, in analysis of data and critical revising. Renata Milardovic contributed in acquisition of data and analysis of literature. Timur Ceric contributed in designing the study and selecting the patients. Sejla Ceric contributed in analysis and interpretation of data. Adnan Beganovic contributed to analysis of the data. Spomenka Kristic contributed to drafting the article and interpretation of the data. Semra Cavaljuga substantially contributed in revising the article for final approval, in concept of the article and analysis of data.
- **Conflict of interest:** none declared.

REFERENCES

1. Dwamena BA, Sonnad SS, Angobaldo JO, Wahl RL. Metastases from Non-Small Cell Lung Cancer: Mediastinal Staging in the 1990s-Meta analytic Comparison of PET and CT. *Radiology*. 1999; 213: 530-36.
2. El-Hariri MA, Gouhar GK, Refat AM. Integrated PET/CT in the preoperative staging of lung cancer: A prospective comparison of CT, PET and integrated PET/CT. *The Egyptian Journal of Radiology and Nuclear Medicine*. 2012; 43(4): 613-21
3. Søgaard R, Fischer BMB, Mortensen J, Højgaard L, Lassen U. Preoperative staging of lung cancer with PET/CT: cost-effectiveness evaluation alongside a randomized controlled trial. *European Journal of Nuclear Medicine and Molecular Imaging*. 2011; 38(5): 802-9.
4. Verschakelen JA, De Wever W, Bogaert J. Role of computed tomography in lung cancer staging. 2004. *Current Opinion in Pulmonary Medicine*. 2004; 10(4): 248-55.
5. Kligerman S, Digumarthy S. Staging of non small cell lung cancer using integrated PET/CT. *AJR Am J Roentgenol*. 2009;

- 193(5): 1203-11.
6. Davison J, Mercier G, Russo G, Subramaniam RM. PET-based primary tumor volumetric parameters and survival of patients with non-small cell lung carcinoma. *AJR Am J Roentgenol.* 2013; 200: 635-40.
 7. Romesser PB, Qureshi MM, Shah BA, et al. Superior prognostic utility of gross and metabolic tumor volume compared to standardized uptake value using PET/CT in head and neck squamous cell carcinoma patients treated with intensitymodulated radiotherapy. *Ann Nucl Med.* 2012; 26(7): 527-34.
 8. Dibble EH, Karantanis D, Mercier G, Peller PJ, Kachnic LA, Subramaniam RM. PET/CT of cancer patients: part 1, pancreatic neoplasms. *AJR Am J Roentgenol.* 2012; 199(5): 952-67.
 9. Jackson T, Chung MK, Mercier G, Ozonoff A, Subramaniam RM. FDG PET/CT interobserver agreement in head and neck cancer: FDG and CT measurements of the primary tumor site. *Nucl Med Commun.* 2012; 33(3): 305-12.
 10. Agarwal A, Chirindel A, Shah BA, Subramaniam RM. Evolving role of FDG PET/CT in multiple myeloma imaging and management. *AJR Am J Roentgenol.* 2013; 200: 884-90.
 11. Charles Marcus, Vasavi Paidpally, Alexander Antoniou, Atif Zaheer, Richard L. Wahl 1, Rathan M. Subramaniam. 18F-FDG PET/CT and Lung Cancer: Value of Fourth and Subsequent Posttherapy Follow-up Scans for Patient Management. *The J Nucl Med.* 2015; 56(2): 204.
 12. Pieterman RM, van Putten JW, Meuzelaar JJ, et al. Preoperative staging of non-small-cell lung cancer with positron emission tomography. *N Engl J. Med.* 2000; 343(4): 254-61.
 13. Silvestri GA, Gould MK, Margolis ML, Tanoue LT, McCrory D, Toloza E, Detterbeck F, Noninvasive staging of non-small cell lung cancer: ACCP evidence-based clinical practice guidelines (2nd edition). *Chest.* 2007; 132(3): 178S-201S.
 14. Fischer B, Lassen U, Mortensen J. et al., Preoperative staging of lung cancer with combined PET-CT, *N Engl J Med,* 2009; 361(1): 32-39.
 15. Gregory DL, Hicks RJ, Hogg A. Et al., Effect of PET/CT on management of patients with non-small lung cancer: results of a prospective study with 5-year survival data, *J Nucl Med.* 2012; 53(7): 1007-15.
 16. Gregory DL, Hicks RJ, Hogg A. Et al., Effect of PET/CT on management of patients with non-small lung cancer: results of a prospective study with 5-year survival data *J Nucl Med.* 2012; 53(7): 1007-15.
 17. Fischer B, Lassen U, Mortensen J. et al., Preoperative staging of lung cancer with combined PET-CT, *N Engl J Med.* 2009; 361(1): 32-39.
 18. Steinert HC, Hauser M, Allemann F, Engel H. et al. Non-small cell lung cancer: nodal staging with FDG PET versus CT with correlative lymph node mapping and sampling. *Radiology.* 1997; 202(2): 441-6.
 19. El-Hariri MA, Gouhar GK, Refat AM. Integrated PET/CT in the preoperative staging of lung cancer: A prospective comparison of CT, PET and integrated PET/CT. *The Egyptian Journal of Radiology and Nuclear Medicine.* 2012; 43(4): 613-21.
 20. Gould MK, Kuschner WG, Rydzak CE, Courtney C. Maclean, BA et al. Test Performance of Positron Emission Tomography and Computed Tomography for Mediastinal Staging in Patients with Non-Small-Cell Lung Cancer. A Meta-Analysis. *Ann Intern Med.* 2003; 139(11): 879-92.