

Olaparib Treatment in a Patient with Advanced Gallbladder Cancer Harboring *BRCA1* Mutation

Xiaofen Li¹
Limin Gao²
Meng Qiu¹
Dan Cao¹

¹Department of Abdominal Oncology, West China Hospital, Sichuan University, Chengdu, Sichuan, People's Republic of China; ²Department of Pathology, West China Hospital, Sichuan University, Chengdu, Sichuan, People's Republic of China

Abstract: Gallbladder cancer is a highly aggressive malignancy with an extremely poor prognosis. Germline *BRCA1* mutation in gallbladder cancer is very rare. Herein, we present a case of a 73-year-old Asian patient diagnosed with lymph nodes and peritoneal metastases just two months after surgery for primary gallbladder cancer. The patient had a past history of early-stage breast cancer and received a left radical mastectomy 27 years ago. Next-generation sequencing (NGS) was performed as the patient refused to receive systemic chemotherapy. According to NGS result of germline *BRCA1* mutation, the patient was administered first-line Olaparib and obtained a progression-free survival of about 6 months. Furthermore, we briefly summarized the current targeted treatment of gallbladder cancer. To the best of our knowledge, this is the first report of germline *BRCA1* p. S451Lfs*20 mutation and first-line Olaparib treatment in a metastatic gallbladder cancer patient. As a highly heterogeneous and aggressive malignancy, we suggest making clinical decisions according to a precision medicine concept based on gene sequencing in advanced gallbladder cancer.

Keywords: gallbladder cancer, *BRCA1* mutation, Olaparib

Introduction

Gallbladder cancer, the most common type of biliary tract cancers (BTCs), is a relatively rare but highly aggressive malignancy.^{1,2} Around the world, the incidence of gallbladder cancer varies by geography and ethnicity, with the highest incidence observed in South America.^{3,4} It is well known that the prognosis of gallbladder cancer is extremely poor, with a 5-year survival rate of less than 5%.^{2,4,5}

Although with limited effectiveness, the current standard treatment for advanced BTCs is systemic chemotherapy.⁶ The large Phase 3 study, ABC-02 trial, demonstrated improved survival outcome with the combination of gemcitabine and cisplatin over gemcitabine alone in the first-line setting (PFS, 8.0 vs 5.0 months, $p < 0.001$); (OS, 11.7 vs 8.1 months, $p < 0.001$).⁷ In recent decades, rapid progress in gene sequencing has identified promising molecular targets in BTCs. Nearly 40% of BTC cases have potentially targetable driver gene alterations, such as *FGFR*, *IDH1/2*, *PIK3CA*, *NTRK*, *ERBB2*, *BRAF*, and so on, with *ERBB2* the most frequent gene mutation in gallbladder cancer.^{8,9} With the rapid development of gene sequencing, molecularly oriented precision medicine has achieved great progress and clinical trials assessing agents targeting *FGFR*, *IDH1* and so on are ongoing.^{9,10} Recently, pemigatinib, a small-molecule *FGFR* inhibitor, has been approved as the first targeted agent to treat chemotherapy-refractory advanced iCCA based on a Phase 2 study (FIGHT-202 trial).¹¹ However, so far only data from large-scale Phase 3 trials on first-line treatment of targeted agents has been published.

Correspondence: Dan Cao; Meng Qiu
Department of Abdominal Oncology,
West China Hospital, Sichuan University,
Chengdu, Sichuan, People's Republic of
China
Tel +86-28-85422589
Fax +86-28-85423609
Email caodan@wchscu.cn;
qiumeng@wchscu.cn

Herein, we report on a female gallbladder cancer patient harboring germline *BRCA1* gene mutation, who received first-line Olaparib and got an optimal prognosis.

Case Presentation

A 73-year-old Chinese female patient was admitted to our hospital in November 2019, complaining of upper abdominal pain for over 2 months. Physical examination presented mild right upper quadrant tenderness. The patient had a history of left radical mastectomy because of early-stage breast cancer 27 years ago, without postoperative treatment. And there was no special family history. Abdominal enhanced computed tomography (CT) showed gallstones and a thickened wall of gallbladder fundus, with enlargement of lymph nodes around the main portal vein. Thoracic CT suggested no obvious abnormality. After routine preoperative examinations, radical cholecystectomy and regional lymphadenectomy were performed on November 15, 2019. Postoperative pathological diagnosis confirmed moderately differentiated adenocarcinoma from the gallbladder (Figure 1), invading the whole layer, involving peripheral fibrofatty tissue and liver parenchyma, with immunohistochemistry (IHC) staining of CK7 (+), CK19 (+), MOC-31 (small partly +), CEA (+), SATB-2 (-), CDX-2 (small partly +) and MIB-1 (+, about 20%). Incisal edges of the distal common bile duct and right hepatic artery were detected for residue cancer cells. The liver incisal edge was negative. Two lymph nodes involving the para-right hepatic artery and posterior pancreatic head lymph nodes were found to be metastatic. The postoperative stage was pT4N1M0, stage IVA. After discussion with her family, the patient refused postoperative chemotherapy.

About two months after surgery, routine postoperative CT imaging on January 10, 2020 revealed peritoneal nodules and enlarged lymph nodes in the ligamentum hepatogastricum and

mesentery regions, which indicated metastases. The patient refused chemotherapy again and accepted the suggestion of a gene test. Next-generation sequencing (NGS) of the operative specimen and plasma were performed and showed germline mutation (c.1352_1364del, p. S451Lfs*20) in *BRCA1* and somatic mutation in *TP53* (exon7 p. E258G) and *MUTYH* (exon13 p. E420*) genes (3D Medicines Shanghai, China). Tissue-based tumor mutational burden (TMB) was 6.15. Microsatellite status was stable (MSS) and the IHC result of programmed death-ligand 1 (PD-L1) was negative. No meaningful mutations were found in other genes, including the mismatch repair gene (*MMR*), *ERBB2*, *IDH1/2* and *FGFR1/2*. It is worth mentioning that the patient's family members also received gene sequencing using blood samples. As she had no siblings and her parents were dead, her only daughter and daughter's son received gene sequencing. The results showed that her daughter has the same germline mutation of *BRCA1*, while her grandson harbors no germline mutation.

Given that *BRCA1* mutation was proven to be a predictor of the Olaparib effect, we prescribed Olaparib 300mg every 12 hours as a first-line treatment on January 20, 2020. Unfortunately, grade 4 anemia occurred after taking Olaparib for about 1 month and was treated with a blood transfusion. The Olaparib dose was then decreased to 150mg every 12 hours and no severe adverse reaction was found. About three months after Olaparib administration, a CT scan revealed significant shrinkage of the peritoneal nodules (Figure 2), with the largest diameter decreasing from 1.58 cm to 0.98 cm, which indicated a partial response (PR) according to the Response Evaluation Criteria in Solid Tumors (RECIST) 1.1.¹² After taking Olaparib for 6 months, on July 31, 2020 an abdominal CT scan showed a new lesion in the remnant liver and enlarged peritoneal nodules, which meant progressed disease (PD).

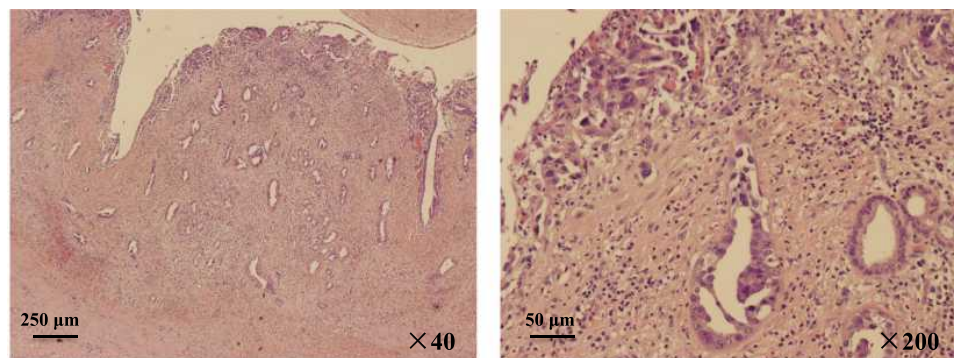


Figure 1 Representative postoperative pathological images of gallbladder mass (hematoxylin and eosin stain).

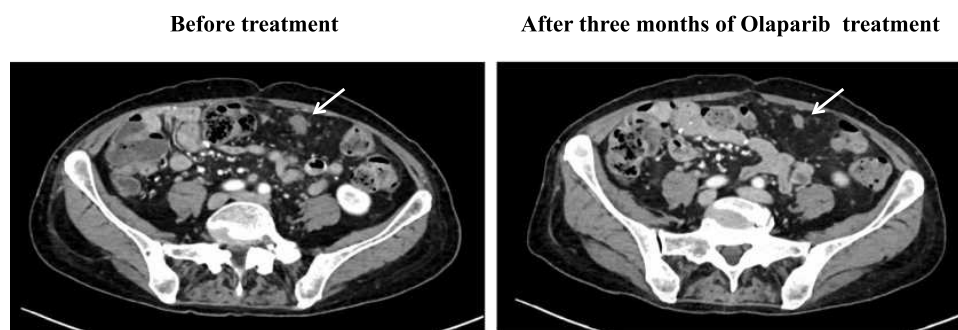


Figure 2 CT images of peritoneal metastasis before and after Olaparib treatment (white arrows: peritoneal metastases).

Considering the dosage of Olaparib was not enough, we suggested to the patient that the Olaparib dosage be reinstated at 300mg every 12 hours. But after careful discussion with her family, our patient decided to stop anti-tumor treatment and obtained a progression-free survival (PFS) of about 6 months. At the most recent follow-up, on March 8, 2021, she was alive and receiving the best supportive care at the local hospital.

Discussion

Biliary tract cancers (BTCs), originating from the epithelium of bile ducts and the gallbladder, are characterized by high aggressiveness, advanced disease at presentation and a poor prognosis. Based on anatomical location, BTCs are classified into intrahepatic cholangiocarcinoma (iCCA), extrahepatic cholangiocarcinoma (eCCA) and gallbladder cancer. Surgery is the only curative treatment approach for BTCs. However, most patients develop distant metastases after surgical resection, suggesting the importance of adjuvant chemotherapy.⁶ A meta-analysis including 10 retrospective studies showed that, compared to resection alone, adjuvant chemotherapy may prolong OS significantly (HR=0.42; 95% CI 0.22–0.80) in patients with gallbladder cancer.¹³ The large randomized Phase 3 trial, the BILCAP study, proved that adjuvant capecitabine was associated with improved recurrence-free survival (25.9 vs 17.4 months, HR=0.70, 95% CI 0.54–0.92, $p=0.0093$) and OS (53 vs 36 months, HR=0.75, 95% CI 0.58–0.97, $p=0.028$), compared to observation, in the per-protocol analysis.¹⁴ Thus, we suggested that our patient receive adjuvant treatment after surgery, as her postoperative stage was pT4N1M0. But our patient refused. This was one of the main reasons for distant metastases just two months after surgery.

In general, about half of BTCs have driver gene alterations, which vary considerably based on anatomical location.^{8,15,16} It has been reported that the most common altered genes in gallbladder cancer are *TP53* (59%), *CDKN2A/B* (19%),

ARID1A (13%) and *ERBB2* (16%).¹⁵ *BRCA1/2* gene mutations are very rare in gallbladder cancer. A study investigating the molecular profile of 1292 patients with BTCs showed that, in gallbladder cancer cases, *BRCA1* mutated in 0.3% and *BRCA2* mutated in 3.8%.¹⁷

BRCA genes are found to be directly associated with hereditary breast cancer, consisting of *BRCA1* and 2.¹⁸ The proteins encoded by *BRCA1/2* play an important role in the repair of double-strand DNA breaks via homologous recombination. Thus, *BRCA1/2* mutated cells have defects in double-strand DNA break repair. Olaparib, an oral poly ADP-ribose polymerase (PARP) inhibitor, can effectively suppress cell repair of single-strand DNA breaks. For tumor cells with *BRCA1/2* mutations, use of Olaparib leads to repair defects in both double-strand and single-strand DNA breaks, resulting in cell death. Clinical trials have shown the effectiveness of Olaparib in breast cancer, ovarian cancer and pancreatic cancer with germline *BRCA1/2* mutations.^{19–21} In 2017, a large Phase 3 trial, the OlympiAD study, published its results in the *New England Journal of Medicine*, which proved a significant benefit of Olaparib monotherapy over standard therapy in patients with HER2-negative metastatic breast cancer and a germline *BRCA* mutation.¹⁹ Later, the SOLO1 study and the POLO study showed the significant effectiveness of Olaparib maintenance therapy among metastatic ovarian cancer and pancreatic cancer patients with a germline *BRCA* mutation.^{20,21} However, as for *BRCA* mutated gallbladder cancer, there is no clinical trial studying the efficacy of Olaparib. To the best of our knowledge, only one case report has been published about *BRCA1* mutated gallbladder cancer treated with Olaparib.²² In that case report, by Xie et al, the patient harbored the *BRCA1* Q858* mutation and obtained a PFS of 3 months after Olaparib administration. The mutation site of our patient (p. S451Lfs*20) is different from the similar published case. Besides, our patient got a better outcome, with a PFS about 6 months.

What is noteworthy is that our patient had grade 4 anemia after taking Olaparib for one month and then received a reduced dose. In the large randomized trials on Olaparib in breast cancer and pancreatic cancer, anemia was the most common grade 3 or higher adverse event, occurring in 11–16% of patients, and often leading to dose reduction.^{19,21} Therefore, we suggest closely monitoring complete blood count whilst taking Olaparib and giving timely treatment for anemia.

In conclusion, the patient in our case suffered highly aggressive gallbladder cancer with a germline *BRCA1* mutation. She responded well to first-line Olaparib and obtained an optimal quality of living. To our knowledge, this is the first report of germline *BRCA1* p. S451Lfs*20 mutation and first-line Olaparib usage in a metastatic gallbladder cancer patient. As a highly heterogeneous malignancy, we recommend gene sequencing in advanced gallbladder cancer and making treatment strategy decisions based on the precision medicine concept.

Abbreviations

NGS, next-generation sequencing; BTC, biliary tract cancer; CT, computed tomography; IHC, immunohistochemistry; TMB, tumor mutational burden; MSS, microsatellite stable; PD-L1, programmed death-ligand 1; *MMR*, mismatch repair gene; PR, partial response; RECIST, Response Evaluation Criteria in Solid Tumors; PD, progressed disease; PFS, progression-free survival; iCCA, intrahepatic cholangiocarcinoma; eCCA, extrahepatic cholangiocarcinoma; OS, overall survival; HR, hazard ratio; CI, confidence interval; PARP, poly ADP-ribose polymerase.

Ethical Approval

Informed written consent was obtained from the patient for publication of this report and any accompanying images. This case report was approved by the West China Hospital, Sichuan University Ethic Committee for Clinical Investigation.

Disclosure

The authors declare that they have no conflicts of interest.

References

- Lazcano-Ponce EC, Miquel JF, Munoz N, et al. Epidemiology and molecular pathology of gallbladder cancer. *CA Cancer J Clin*. 2001;51:349–364. doi:10.3322/canjclin.51.6.349
- Hundal R, Shaffer EA. Gallbladder cancer: epidemiology and outcome. *Clin Epidemiol*. 2014;6:99–109. doi:10.2147/CLEP.S37357
- Narayan RR, Creasy JM, Goldman DA, et al. Regional differences in gallbladder cancer pathogenesis: insights from a multi-institutional comparison of tumor mutations. *Cancer*. 2019;125(4):575–585. doi:10.1002/cncr.31850
- Hori M, Saito E. Gallbladder cancer incidence rates in the world from the Cancer Incidence in Five Continents XI. *Jpn J Clin Oncol*. 2018;48(9):866–867. doi:10.1093/jjco/hyy119
- Shukla SK, Singh G, Shahi KS, et al. Staging, treatment, and future approaches of gallbladder carcinoma. *J Gastrointest Cancer*. 2018;49(1):9–15. doi:10.1007/s12029-017-0036-5
- National Comprehensive Cancer Network. NCCN clinical practice guidelines in oncology: hepatobiliary cancers. version 5; 2020. Accessed from: www.nccn.org. Accessed August 4, 2020.
- Valle J, Wasan H, Palmer DH, et al. Cisplatin plus gemcitabine versus gemcitabine for biliary tract cancer. *N Engl J Med*. 2010;362(14):1273–1281. doi:10.1056/NEJMoa0908721
- Nakamura H, Arai Y, Totoki Y, et al. Genomic spectra of biliary tract cancer. *Nat Genet*. 2015;47(9):1003–1010. doi:10.1038/ng.3375
- Chakrabarti S, Kamgar M, Mahipal A. Targeted therapies in advanced biliary tract cancer: an evolving paradigm. *Cancers (Basel)*. 2020;12(8):2039. doi:10.3390/cancers12082039
- Tella SH, Kommalapati A, Borad MJ, et al. Second-line therapies in advanced biliary tract cancers. *Lancet Oncol*. 2020;21(1):e29–e41. doi:10.1016/S1470-2045(19)30733-8
- Abou-Alfa GK, Sahai V, Hollebecque A, et al. Pemigatinib for previously treated, locally advanced or metastatic cholangiocarcinoma: a multicentre, open-label, phase 2 study. *Lancet Oncol*. 2020;21(5):671–684. doi:10.1016/S1470-2045(20)30109-1
- Eisenhauer EA, Therasse P, Bogaerts J, et al. New response evaluation criteria in solid tumours: revised RECIST guideline (version 1.1). *Eur J Cancer*. 2009;45(2):228–247. doi:10.1016/j.ejca.2008.10.026
- Ma N, Cheng H, Qin B, Zhong R, Wang B. Adjuvant therapy in the treatment of gallbladder cancer: a meta-analysis. *BMC Cancer*. 2015;15:615. doi:10.1186/s12885-015-1617-y
- Primrose JN, Fox RP, Palmer DH, et al. Capecitabine compared with observation in resected biliary tract cancer (BILCAP): a randomised, controlled, multicentre, phase 3 study. *Lancet Oncol*. 2019;20(5):663–673. doi:10.1016/S1470-2045(18)30915-X
- Javle M, Bekaii-Saab T, Jain A, et al. Biliary cancer: utility of next-generation sequencing for clinical management. *Cancer*. 2016;122(24):3838–3847. doi:10.1002/cncr.30254
- Okamura R, Kurzrock R, Mallory RJ, et al. Comprehensive genomic landscape and precision therapeutic approach in biliary tract cancers. *Int J Cancer*. 2020;148(3):702–712.
- Spizzo G, Puccini A, Xiu J, et al. Molecular profile of BRCA-mutated biliary tract cancers. *ESMO Open*. 2020;5(3):e000682. doi:10.1136/esmoopen-2020-000682
- Walsh CS. Two decades beyond BRCA1/2: homologous recombination, hereditary cancer risk and a target for ovarian cancer therapy. *Gynecol Oncol*. 2015;137(2):343–350. doi:10.1016/j.ygyno.2015.02.017
- Robson M, Im S-A, Senkus E, et al. Olaparib for metastatic breast cancer in patients with a germline BRCA mutation. *N Engl J Med*. 2017;377(6):523–533. doi:10.1056/NEJMoa1706450
- Moore K, Colombo N, Scambia G, et al. Maintenance olaparib in patients with newly diagnosed advanced ovarian cancer. *N Engl J Med*. 2018;379(26):2495–2505. doi:10.1056/NEJMoa1810858
- Golan T, Hammel P, Reni M, et al. Maintenance olaparib for germline BRCA -mutated metastatic pancreatic cancer. *N Engl J Med*. 2019;381(4):317–327. doi:10.1056/NEJMoa1903387
- Xie Y, Jiang Y, Yang X-B, et al. Response of BRCA1 -mutated gallbladder cancer to olaparib: a case report. *World J Gastroenterol*. 2016;22(46):10254–10259. doi:10.3748/wjg.v22.i46.10254

OncoTargets and Therapy

Dovepress

Publish your work in this journal

OncoTargets and Therapy is an international, peer-reviewed, open access journal focusing on the pathological basis of all cancers, potential targets for therapy and treatment protocols employed to improve the management of cancer patients. The journal also focuses on the impact of management programs and new therapeutic

agents and protocols on patient perspectives such as quality of life, adherence and satisfaction. The manuscript management system is completely online and includes a very quick and fair peer-review system, which is all easy to use. Visit <http://www.dovepress.com/testimonials.php> to read real quotes from published authors.

Submit your manuscript here: <https://www.dovepress.com/oncotargets-and-therapy-journal>