



EDITORIAL COMMENT

Anti-phospholipase A2 receptor antibody and spontaneous remission in membranous nephropathy

Montserrat Diaz¹, Irene Agraz² and Maria Jose Soler²

¹Nephrology Department, Hospital Universitari Fundació Puigvert, Universitat Autònoma de Barcelona, Barcelona, Spain and ²Nephrology Department, Hospital Universitari Vall d'Hebron, Universitat Autònoma de Barcelona, Barcelona, Spain

Correspondence and offprint requests to: Maria Jose Soler; E-mail: mjsoler01@gmail.com

ABSTRACT

Membranous nephropathy (MN) is one of the most common causes of nephrotic syndrome in native kidney biopsies from adults. In 2009, antibodies to the M-type receptor of phospholipase A2 (anti-PLA2R) were identified in idiopathic MN patients, both within the kidney and in the circulation. The clinical course of idiopathic MN is variable and ranges from spontaneous remission to end-stage renal disease. Clinical variables such as proteinuria levels, patient sex, age and renal function at diagnosis have been associated with renal MN progression. In this editorial, we update the importance of anti-PLA2R levels as a prognostic marker in idiopathic MN at the diagnosis of the disease.

Keywords: anti-phospholipase A2 receptor antibody, end-stage kidney disease, membranous nephropathy, spontaneous remission

Membranous nephropathy (MN) is one of the most common causes of nephrotic syndrome in native kidney biopsies from adults. MN is uncommon in children and when diagnosed, the disease is normally secondary and is associated with another pathology such as autoimmune diseases [1]. The term MN describes the histologic pattern identified on kidney biopsy. The thickened appearance of the glomerular basement membrane resulting in the name 'membranous' is a consequence of the antibody/antigen deposits that accumulate below the epithelial cell, the podocyte. The deposits and the extracellular matrix form the characteristically named spikes, observed by Jones' silver stain. The deposits themselves result in the fine granular capillary loop pattern seen on immunofluorescence and the subepithelial electron dense deposits observed by electron microscopy [2].

MN can be idiopathic MN (IMN) or primary, when a cause is not identified (IMN), which accounts around 80% of cases, or secondary MN (SMN) forms can be seen in the setting of autoimmune disease, neoplasia, infection and after being exposed to

some therapeutic agents [3]. In 2009, a seminal renal research by Beck and colleagues first found that the antibodies to the M-type receptor of phospholipase A2 (anti-PLA2R) were present in IMN patients, both within the kidney (located on the podocyte membrane) and in the circulation [4]. Interestingly, these antibodies were not found in other glomerular diseases such as focal segmental glomerulosclerosis and minimal change glomerulonephritis. Anti-PLA2R antibodies are most often of the Immunoglobulin G4 (IgG4) subclass and co-localized with IgG4 in the fine granular pattern that is typical of MN [4]. Interestingly, the discovery of PLA2R allowed for retrospective diagnosis of PLA2R-related MN in archived renal biopsies [5].

Studies from Hofstra and colleagues demonstrated in a European patient cohort that the levels of circulating anti-PLA2R revealed a strong correlation with clinical disease activity. Their results suggest that the low or absent anti-PLA2R levels after IMN treatment may indicate the remission of immunologic activity, becoming a useful tool for monitoring disease activity and subsequently predicting MN recovery and relapse.

Received: 26.5.2018; Editorial decision: 31.7.2018

© The Author(s) 2018. Published by Oxford University Press on behalf of ERA-EDTA.

This is an Open Access article distributed under the terms of the Creative Commons Attribution Non-Commercial License (<http://creativecommons.org/licenses/by-nc/4.0/>), which permits non-commercial re-use, distribution, and reproduction in any medium, provided the original work is properly cited. For commercial re-use, please contact journals.permissions@oup.com

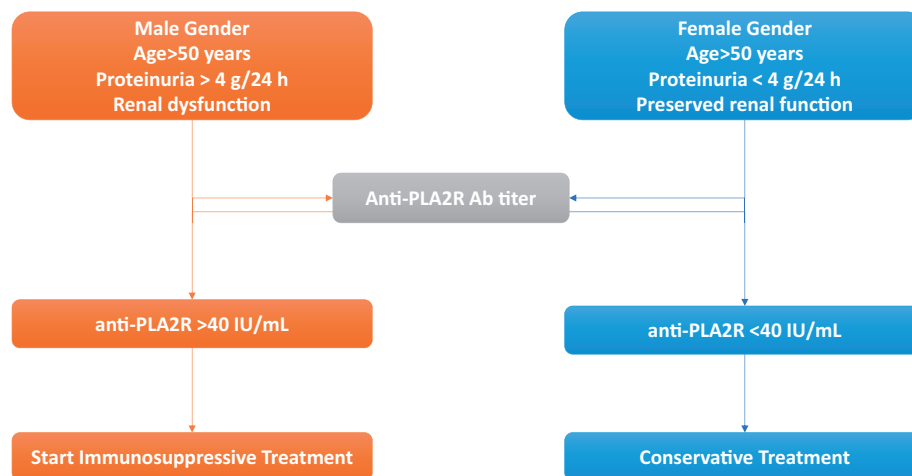


FIGURE 1: Proposed therapeutic algorithm of PLA2R-associated IMN at diagnosis.

However, some studies suggest that anti-PLA2R levels may be different depending on the ethnicity; in this sense, in a Japanese cohort with IMN observed a lower rate of anti-PLA2R-positive patients [6].

The clinical course of MN presented a wider spectrum, from spontaneous recovery, which accounts for 30–40% of patients to massive proteinuria that progresses to chronic kidney disease (CKD) [1]. At diagnosis, the nephrologist needs to detect patients with IMN at risk for CKD progression, giving that the identification of patients who will benefit of immunosuppressive treatment. Proteinuria >8 g/day, male sex, >50 years of age, and renal dysfunction at presentation were classically identified as a risk factors for CKD progression in IMN. In the current study by the Quintana group in a Spanish cohort of IMN [7], the authors demonstrated that complete remission was not observed in IMN patients with anti-PLA2R >40 IU/mL and was less frequently observed in patients with proteinuria >8 g/day. In addition, patients with high antibody levels had higher risk for developing end-stage renal disease (ESRD), and the necessity of renal replacement therapy was lower in patients with negative anti-PLA2R during the follow-up. Interestingly, their study reinforces the important role of anti-PLA2R in the clinical prediction of the IMN course at the diagnosis and suggests that patients with high anti-PLA2R levels (>40 IU/mL) and high proteinuria (>4 g/day) could benefit from immunosuppressive treatment, whereas patients with low anti-PLA2R levels (<40 IU/mL) and low proteinuria (<4 g/day) could benefit from a longer period of follow-up with conservative treatment [7] (see suggested treatment algorithm, Figure 1). In concordance with their results, other studies and a recent meta-analysis also demonstrated that IMN patients with anti-PLA2R at renal biopsy presented high spontaneous remission rate with conservative treatment [8, 9]. In the current study, Rodas and colleagues [7] took a step forward and demonstrated that the levels of anti-PLA2R are clearly related to the IMN prognostic and subsequently may help to detect patients at risk for CKD progression.

In 2014, a second IgG-specific antibody for thrombospondin type-1 domain-containing 7A (THSD7A) was identified in adult IMN. Around 2.5–5% of IMN patients presented anti-THSD7A, corresponding to 8–14% of patients with negative anti-PLA2R [10]. Of note, the presence of anti-THSD7A in MN patients has been associated in 21% of patients with a malignant tumour such as endometrial carcinoma and gallbladder carcinoma. Interestingly, the carcinomatous cells also revealed increased THSD7A protein expression, and the chemotherapy treatment

decreased anti-THSD7A and proteinuria in those patients with secondary MN. Thus, the increase of anti-THSD7A may be an immune mechanism response against the increase of THSD7A protein within the malignant cells. As a consequence, some authors recommend that when THSD7A-associated MN is diagnosed, an aggressive screening for cancer to diagnose secondary MN should be performed [11].

Classically, the gold standard for MN diagnosis has been the kidney biopsy. However, the recent discoveries in the last decade suggest for the first time that kidney biopsy may not be required in PLA2R-associated MN. This new approach for MN diagnosis is based on the high specificity of the PLA2R antibody (Ab), which reaches $\sim 100\%$ [12], and may be of great interest in patients with relative contraindications for kidney biopsy such as single kidney or bleeding disorder patients. Recently, PLA2R-associated MN has also been detected in patients with secondary MN, mainly in hepatitis and sarcoidosis patients, indicating that further studies are needed to elucidate new markers of IMN [13].

In conclusion, the study by Rodas *et al.* demonstrates the important role of anti-PLA2R as a tool to predict IMN course and prognosis early on, at the moment of diagnosis. The authors suggest that the anti-PLA2R and proteinuria levels may clearly help to detect patients at risk for ESRD progression (who will benefit from immunosuppressive treatment) and spontaneous remission patients (who will benefit from conservative therapy) [7]. Anti-PLA2R levels <40 IU/mL at MN diagnosis may become a useful tool for detecting patients who will benefit from conservative treatment, and subsequently avoid the secondary effects of immunosuppressive treatment in those patients.

FUNDING

The authors are current recipients of research grants from the FONDO DE INVESTIGACIÓN SANITARIA-FEDER, ISCIII, P114/00557, P117/00257 and REDINREN, RD16/0009/0030.

CONFLICT OF INTEREST STATEMENT

None declared.

REFERENCES

1. Couser WG. Primary membranous nephropathy. *Clin J Am Soc Nephrol* 2017; 12: 983–997

2. Menon S, Valentini RP. Membranous nephropathy in children: clinical presentation and therapeutic approach. *Pediatr Nephrol* 2010; 25: 1419–1428
3. El-Husseini A, Saxon D, Jennings S et al. Idiopathic membranous nephropathy: diagnostic and therapeutic challenges. *Am J Nephrol* 2016; 43: 65–70
4. Beck LH, Bonegio RGB, Lambeau G et al. M-type phospholipase A₂ receptor as target antigen in idiopathic membranous nephropathy. *N Engl J Med* 2009; 361: 11–21
5. Ronco P, Debiec H. Membranous nephropathy: a fairy tale for immunopathologists, nephrologists and patients. *Mol Immunol* 2015; 68: 57–62
6. Akiyama S, Akiyama M, Imai E et al. Prevalence of anti-phospholipase A2 receptor antibodies in Japanese patients with membranous nephropathy. *Clin Exp Nephrol* 2015; 19: 653–660
7. Rodas LM, Matas-García A, Barros X et al. Antiphospholipase 2 receptor antibody levels to predict complete spontaneous remission in primary membranous nephropathy. *Clin Kidney J* 2019; 12: 36–41
8. Hill PA, McRae JL, Dwyer KM. PLA2R and membranous nephropathy: a 3 year prospective Australian study. *Nephrology* 2016; 21: 397–403
9. Wu W, Shang J, Tao C et al. The prognostic value of phospholipase A2 receptor autoantibodies on spontaneous remission for patients with idiopathic membranous nephropathy. *Medicine* 2018; 97: e11018
10. Tomas NM, Beck LH, Meyer-Schwesinger C et al. Thrombospondin type-1 domain-containing 7A in idiopathic membranous nephropathy. *N Engl J Med* 2014; 371: 2277–2287
11. De Vriese AS, Glassock RJ, Nath KA et al. A proposal for a serology-based approach to membranous nephropathy. *J Am Soc Nephrol* 2017; 28: 421–430
12. Du Y, Li J, He F et al. The diagnosis accuracy of PLA2R-AB in the diagnosis of idiopathic membranous nephropathy: a meta-analysis. *PLoS ONE* 2014; 9: e104936
13. Larsen CP, Messias NC, Silva FG et al. Determination of primary versus secondary membranous glomerulopathy utilizing phospholipase A2 receptor staining in renal biopsies. *Mod Pathol* 2013; 26: 709–715