

CASE REPORT

doi: 10.5455/medarch.2020.74.309-311

MED ARCH. 2020 AUG; 74(4): 309-311

RECEIVED: JUL 15, 2020 | ACCEPTED: AUG 05, 2020

Department of Cardiology, General Hospital of Veroia, Veroia, Greece

Corresponding author: Dr Ioannis

Vogiatzis. 3a Stougiannaki str, Panorama.

55236 Thessaloniki, Greece. Tel.

00302310345709/6944276230. E-mail:

ivogia@hotmail.gr. ORCID ID: <http://www.orcid.org/0000-0002-6269-0292>.

Transesophageal Overdrive Pacing in a Patient with Atrial Tachycardia and β -Thalassemia Major. A Challenging Simplicity

Konstantinos Koutsampasopoulos, Maria Pliatsika, Ioannis Vogiatzis

ABSTRACT

Introduction: Transesophageal overdrive pacing is an accepted method for the diagnosis and treatment of supraventricular tachycardias, although is not used frequently in clinical practice. **Case report:** A 47 years old woman is reported with a medical history of β -Thalassemia Major admitted to our hospital with atrial tachycardia of recent onset and successfully converted using a transesophageal overdrive atrial pacing. **Conclusion:** Transesophageal overdrive atrial pacing is a low cost, simple and safe procedure that can be performed at the bedside, especially in patients, as those with β -Thalassemia Major, whose health status makes difficult the usage of medicines that could possibly aggravate their general health status.

Keywords: Transesophageal overdrive pacing, atrial tachycardia, β -Thalassemia Major.

1. INTRODUCTION

Rhythm disturbances are not rare in patients with β -Thalassemia Major (TM) (1). On the other hand transesophageal overdrive pacing is an accepted method for the diagnosis and treatment of supraventricular tachycardias, although is not used frequently in clinical practice (2). A case of a β -Thalassemia Major patient is reported who presented to hospital with a recent onset atrial tachycardia and was successfully managed using transesophageal overdrive pacing. To our knowledge this is the first case described in the literature.

2. CASE REPORT

A 47 years old woman was admitted to our hospital complaining of chest pain and palpitations of recent onset. She had a medical history of β -Thalassemia Major (TM-Cooley disease) and of atrial tachycardia treated with metoprolol 50mg bid plus verapamil 60 mg bid. Her blood pressure was 110/70 mmHg and on her electrocardiogram (ECG) a regular narrow complex tachycardia of about 180 beats per minute (bpm), with a long RP interval (Figure 1), was noticed. Adenosine administration revealed an atrial rate of about 150 bpm with a barely normal P wave morphology and an isoelectric segment between consecutive P waves.

Her last hospitalization was 3 years ago when atrial tachycardia was converted with an overdrive atrial pacing via a transvenous temporary pacing wire. It was a very difficult and unpleasant experience that she did not want to repeat. Intravenous administration of esmolol and verapamil failed to restore sinus rhythm and a transesophageal overdrive atrial pacing was decided to convert the arrhythmia.

A specially designed bipolar electrode was used to effect bipolar pacing via esophagus (Figure 2). The electrode was inserted via the right nare to esophagus while the patient was swallowing. The distal tip of the catheter was connected to the V1 ECG lead. Forty-five cm from nares the atrial and ventricular dynamics were record equal in V1 lead of the surface ECG (Figure 3). The tips of the catheter were connected to a programmed cardiac stimulator, designed for transesophageal pacing and pacing from this point, using 10 mA pacing current and pulse width 5 ms, was applied for 5 seconds. The patient restored sinus rhythm immediately after interrupting pacing and the patient's discomfort lasted only 5 seconds (Figure 4). Two hours later the patient exited from the hospital.

© 2020 Konstantinos, Koutsampasopoulos, Maria Pliatsika, Ioannis Vogiatzisi

This is an Open Access article distributed under the terms of the Creative Commons Attribution Non-Commercial License (<http://creativecommons.org/licenses/by-nc/4.0/>) which permits unrestricted non-commercial use, distribution, and reproduction in any medium, provided the original work is properly cited.

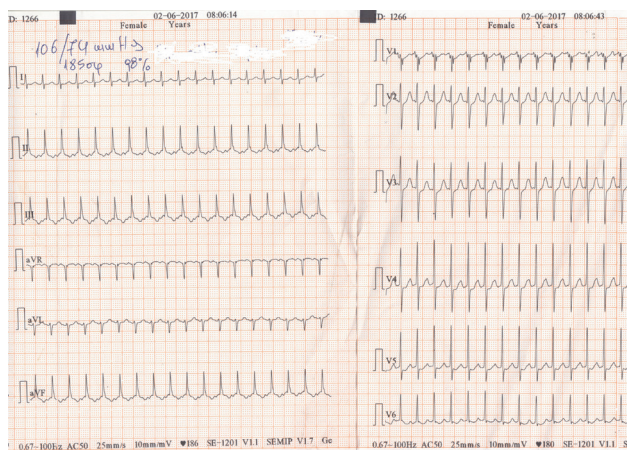


Figure 1. Patient's ECG showing a regular narrow complex tachycardia of about 180 beats per minute (bpm) with a long RP interval.

This case report was approved by the Ethical Committee of hospital (33/2019) and the patient was given written informed consent.

3. DISCUSSION

Atrial fibrillation is the most common arrhythmia in TM patients, but Atrial Tachycardia (AT) and chaotic atrial rhythm are rhythm disorders that also have been observed (3). Triggered activity and reentrant arrhythmia are the proposed underline mechanisms for the development of AT in patients with TM (4). Atrial tachycardia appears particularly in the presence of significant cardiac iron loading (5). Iron deposition in working heart muscle tends to affect the conduction system of the heart (1). Chronic volume overload and the proarrhythmic atrial effect of high cardiac output caused by chronic anemia are alternative explanations for the development of atrial arrhythmias in patients with TM (1). Ventricular arrhythmias and sudden death can also occur and they are more specific for iron cardiotoxicity, as severe iron overload cause a higher degree of QT and JT dispersion and predisposes to iron-mediated repolarization abnormalities and torsade de pointes (6).

In differential diagnosis Focal AT, Multifocal atrial tachycardia (MAT) and Sinus node reentry tachycardia are included. Focal Atrial tachycardia most often presents as a regular narrow complex tachycardia with an atrial rhythm at a rate between 100 and 250 bpm with abnormal P wave appearance and a long or short RP interval. Irregularity is seen at onset (“warm-up”) and termination (“warm-down”) of AT. AT originates from a localized atrial site outside of the sinus node either in the right or left atrium (7). On the other hand MAT is an irregular rhythm characterized by three distinct P-wave morphologies at different rates. Sinus node reentry tachycardia is a specific type of focal AT that is due to microreentry arising from the sinus node complex, characterized by abrupt onset and termination (7).

Focal AT is relatively uncommon, accounting for 10% of paroxysmal supraventricular tachycardia. Focal AT is mostly paroxysmal and self-limiting, but may be presented as incessant AT causing tachycardia-mediated cardiomyopathy (8). Acute management of AT is guided by the symptoms and includes intravenous beta-block-

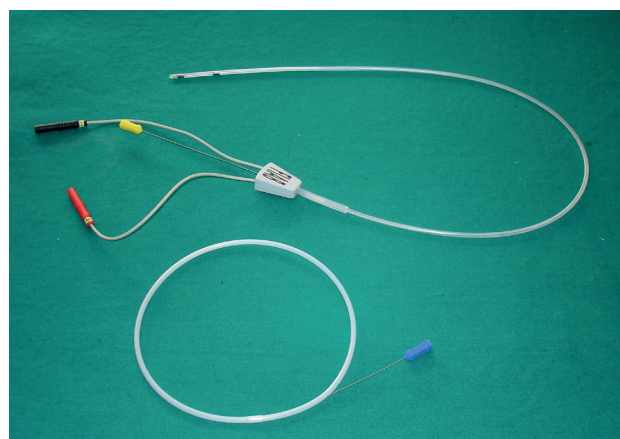


Figure 2. A bipolar transesoophageal electrode inserted via a nare of the patient.

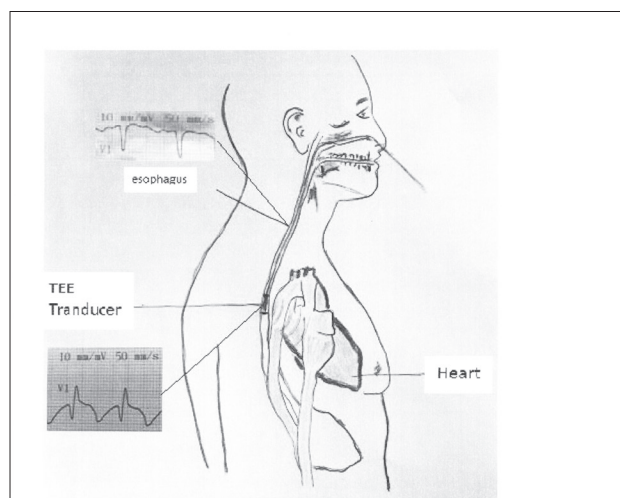


Figure 3. Surface ECG when bipolar electrode was located in esophagus and when was located behind the left atrial of the heart, forty-five cm from nares. Pacing started when the record of the atrial and the ventricular dynamics were equal in V1 lead of the surface ECG.

ers (class I, level of evidence C), non-dihydropyridine calcium channel blockers (class I, level of evidence C) in hemodynamically stable patients and synchronized cardioversion in patients with hemodynamically unstable focal AT (class I, level of evidence C). Adenosine can be useful either restore sinus rhythm or to diagnose the tachycardia mechanism in patients with suspected focal AT (class IIa, level of evidence B). Intravenous amiodarone may be reasonable either to restore sinus rhythm or to slow the ventricular rate in hemodynamically stable patients (class IIb, level of evidence C). Ibutilide may also be reasonable in the acute setting to restore sinus rhythm in hemodynamically stable patients (class IIb, level of evidence C) (9). Transesophageal overdrive atrial pacing is not proposed by these guidelines, probably due to absence of randomize control trials to support this method.

Overdrive atrial pacing has been used for converting atrial flutter (10) junctional tachycardia (11) and atrial tachycardia (12). Transesophageal pacing can also be used for the diagnosis of bradyarrhythmias, as sick sinus syndrome and for electrophysiological studies of atrioventricular nodal and infranodal conduction (13).

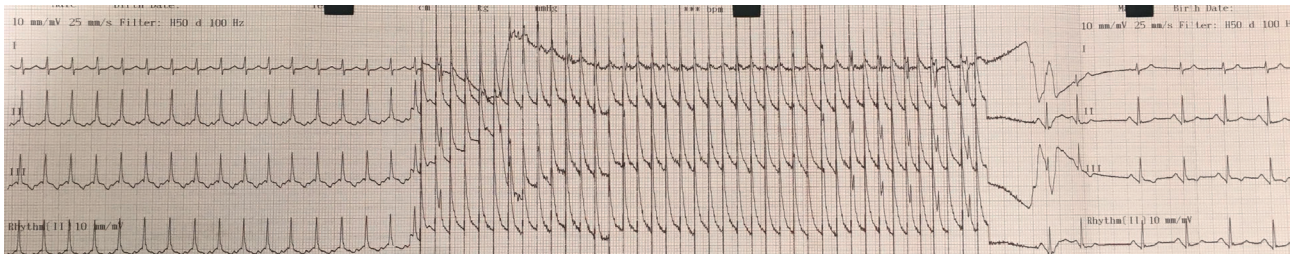


Figure 4. Transesophageal overdrive pacing using 10 mA pacing current and pulse width 5 ms for 5 seconds pacing. The patient restored to sinus rhythm immediately after interrupting pacing.

Transesophageal overdrive atrial pacing is a low cost, simple and safe procedure that can be performed at the bedside. It lacks the complications of transvenous pacing (pneumothorax, hemothorax, bleeding and probably fluoroscopy) and the need of sedation in electrical cardioversion (2). In transesophageal overdrive atrial pacing patients complains for chest discomfort which last only 5-10 seconds and usually is well tolerated (2). Lesion of the esophageal mucosa is an extremely rare complication, but the initiation of malignant ventricular arrhythmias although rare, is a severe complication, caused by prolonged atrial pacing at rapid rates (14).

In this case, after the failure of esmolol and verapamil to restore sinus rhythm, a transesophageal overdrive atrial pacing was decided to be tried, before performing an electrical cardioversion. No complications were observed and the patient exited two hours later.

4. CONCLUSION

Transesophageal overdrive atrial pacing is a low cost, simple and safe procedure that can be performed at the bedside, especially in patients whose health state makes difficult the usage of medicines that could possibly aggravate their general health status.

- **Acknowledgments:** The authors would like to thank Dr Athina Kotsani, Director of ERL Department of Hospital of Veroia, for her valuable contribution to Figure 3 designing.
- **Author's contribution:** All authors were included in all phases of preparation this case report. Final proof reading was made by the third author.
- **Conflict of interest:** The authors report no conflict of interest.
- **Financial support and sponsorship:** Nil.

5. REFERENCES

1. Pennell DJ, Udelson JE, Arai AE, Bozkurt B, Cohen AR, Galanello R, et al. Cardiovascular function and treatment in β -thalassemia major: a consensus statement from the American Heart Association. *Circulation*. 2013; 128 (3): 281-308. doi: 10.1161/CIR.0b013e31829b2be6.
2. Santini M, Ansalone G, Cacciatore G, Turitto G. Transesophageal pacing. *Pacing Clin Electrophysiol*. 1990; 13: 1298-1323.
3. Kaye SB, Owen M. Cardiac arrhythmias in thalassaemia major: evaluation of chelation treatment using ambulatory monitoring. *Br Med J*. 1978; 1: 342-346.
4. Lekawanvijit S, Chattapakorn N. Iron overload thalassaemic cardiomyopathy: iron status assessment and mechanisms of mechanical and electrical disturbance due to iron toxicity. *Can J Cardiol*. 2009; 25: 213-218.
5. ngle MA, Erlandson M, Smith CH. Late cardiac complications of chronic, severe, refractory anemia with hemochromatosis. *Circulation*. 1964; 30: 698-705.
6. usso V, Rago A, Pannone B, Papa AA, Di Meo F, Mayer MC, et al. Dispersion of repolarization and beta-thalassemia major: the prognostic role of QT and JT dispersion for identifying the high-risk patients for sudden death. *Eur J Haematol*. 2011; 86: 324-331.
7. Blomström-Lundqvist C, Scheinman MM, Aliot EM, Alpert JS, Calkins H, Camm AJ, et al. ACC/AHA/ESC guidelines for the management of patients with supraventricular arrhythmias—executive summary: a report of the American College of Cardiology/American Heart Association Task Force on Practice Guidelines and the European Society of Cardiology Committee for Practice Guidelines (Writing Committee to Develop Guidelines for the Management of Patients With Supraventricular Arrhythmias). *Circulation*. 2003; 108: 1871-1909.
8. Medi C, Kalman JM, Haqqani H, Vohra JK, Morton JB, Sparks PB, et al. Tachycardia-mediated cardiomyopathy secondary to focal atrial tachycardia: long-term outcome after catheter ablation. *J Am Coll Cardiol*. 2009; 53: 1791-1797.
9. Page RL, Joglar JA, Caldwell MA, Calkins H, Conti JB, Deal BJ, et al. 2015 ACC/AHA/HRS guideline for the management of adult patients with supraventricular tachycardia: Executive summary. *Heart Rhythm*. 2016; 13(4): e92-135. doi: 10.1016/j.hrthm.2015.09.018.
10. Peters RW, Shorofsky SR, Pelini M, Olsovsky M, Gold MR. Overdrive atrial pacing for conversion of atrial flutter: comparison of postoperative with nonpostoperative patients. *Am Heart J*. 1999; 137: 100-103.
11. Fan R, Tardos JG, Almasry I, Barbera S, Rashba EJ, Iwai S. Novel use of atrial overdrive pacing to rapidly differentiate junctional tachycardia from atrioventricular nodal reentrant tachycardia. *Heart Rhythm*. 2011; 8: 840-844.
12. Ragonese P, Drago F, Guccione P, Santilli A, Silveti MS, Agostino DA. Permanent overdrive atrial pacing in the chronic management of recurrent postoperative atrial reentrant tachycardia in patients with complex congenital heart disease. *Pacing Clin Electrophysiol*. 1997; 20: 2917-2923.
13. Aykan HH, Özer S, Karagöz T, Akin A, Gülgün M, Alehan D, et al. Comparison of Transesophageal and Intracardiac Electrophysiologic Studies for the Diagnosis of Childhood Supraventricular Tachycardias. *Pediatr Cardiol*. 2015; 36: 1429-1435.
14. Favale S, Di Biase M, Rizzo U, Minafra F, Rizzon P. Ventricular fibrillation induced by transesophageal atrial pacing in hypertrophic cardiomyopathy. *Eur Heart J*. 1987; 8: 912-916.