

Level of headaches after surgical aneurysm clipping decreases significantly faster compared to endovascular coiled patients

Athanasios K. Petridis, Jan F. Cornelius, Marcel A. Kamp, Sina Falahati, Igor Fischer, Hans Jakob Steiger

Department of Neurosurgery, University Hospital Duesseldorf, Heinrich Heine University Duesseldorf, Germany

Abstract

In incidental aneurysms, endovascular treatment can lead to post-procedural headaches. We studied the difference of surgical *clipping* vs. endovascular *coiling* in concern to post-procedural headaches in patients with ruptured aneurysms. Sixty-seven patients with aneurysmal subarachnoid haemorrhage were treated in our department from September 1st 2015 - September 1st 2016. 43 Patients were included in the study and the rest was excluded because of late recovery or high-grade subarachnoid bleedings. Twenty-two were surgical treated and twenty-one were interventional treated. We compared the post-procedural headaches at the time points of 24 h, 21 days, and 3 months after treatment using the visual analog scale (VAS) for pain. After surgical clipping the headache score decreased for 8.8 points in the VAS, whereas the endovascular treated population showed a decrease of headaches of 3.3 points. This difference was highly statistical significant and remained significant even after 3 weeks where the pain score for the surgically treated patients was 0.68 and for the endovascular treated 1.8. After 3 months the pain was less than 1 for both groups with surgically treated patients scoring 0.1 and endovascular treated patients 0.9 (not significant). Clipping is relieving the headaches of patients with aneurysm rupture faster and more effective than endovascular coiling. This effect stays significant for at least 3 weeks and plays a crucial role in stress relieve during the acute and subacute ICU care of such patients.

Introduction

There is still controversy about occurrence of post-procedural headaches and

coil-embolization of intracranial non-ruptured aneurysms. There are studies indicating a relief of headache after coil-embolization¹ and others showing an increase of headache after the procedure, at least for a short time.² However, there are no studies evaluating the severity of headaches of endovascular vs surgical treatment in ruptured aneurysms. In the present study we aimed to compare the incidence of post-procedural headaches as assessed by the visual analog scale (VAS) after surgical clipping or interventional coiling in patients with aneurysmal subarachnoid haemorrhage (aSAH) of WFNS grades 1-3.

Ethical approval

All procedures performed in studies involving human participants were in accordance with the ethical standards of the institutional and/or national research committee and with the 1964 Helsinki declaration and its later amendments or comparable ethical standards. For this type of study formal consent is not required.

Materials and Methods

Study design

For the retrospective study there was no approval needed as given by the Physicians Chamber of Nordrhein.

Participants

Inclusion criteria of our present retrospective analysis were: i) patients with aneurysmal subarachnoid haemorrhage suffering from WFNS grade 1-3; ii) extubation of the patient at maximum 12 hours after aneurysm occlusion; iii) full orientation regarding time and situation; iv) reliable answering to questions without any aphasic disturbances; v) treatment between September 1st 2015 and September 1st 2016. Patients with non-aneurysmal or high-grade SAH, comatose, confused or aphasic patients were excluded.

Standard treatment

After confirmation of an aneurysmal SAH by native computed tomography and CT-angiography, patients were admitted to the neuro intensive care unit (NICU) and treated according to the AHA- and institutional guidelines.³ All patients with a GCS < 12 received an external ventricular drainage (EVD) but most of these patients had a WFNS score of > 3 and where excluded from the study. Digital subtraction angiography was performed for aneurysm visualization and confirmation. Aneurysm was

Correspondence: Athanasios K. Petridis, Department of Neurosurgery, University Hospital Duesseldorf, Moorenstr 5, 40225 Duesseldorf, Germany.
Tel.: +49.211.8107439.
E-mail: opticedisc@aol.com

Key words: Headache; aneurysm; subarachnoid haemorrhage; surgical clipping; endovascular coiling.

Conflict of interest: the authors declare no potential conflict of interest.

Received for publication: 31 December 2016.
Accepted for publication: 28 February 2017.

This work is licensed under a Creative Commons Attribution NonCommercial 4.0 License (CC BY-NC 4.0).

©Copyright A.K. Petridis et al., 2017
Licensee PAGEPress, Italy
Clinics and Practice 2017; 7:936
doi:10.4081/cp.2017.936

repaired either by microsurgical or endovascular technique within 24 hours after admission. After the procedure, patients in both groups were treated in the same manner, were transferred to the ICU and – if possible – were extubated. Prophylactic treatment with dihydropyridine L-type calcium channel antagonists was started and all patients underwent serial perfusion computed tomography (PCT) during their stay on the NICU.

Standard pain medication was paracetamol (3x1 g), metamizole (3x1 g) and – only if required – piritramide (3 mg i.v.).

Variables

Headache was assessed by the visual analog scale (VAS; no pain: 0, to maximal pain: 10), which was the main study parameter. The pain scores were recorded for the initial headache at aneurysm rupture, 24 h (N=43), 21 days (N=43), 3 months (N=19) and 6 months (N=3) after surgery. For the 24 h time point patients were asked 3 times a day in fixed time points and the mean VAS score was calculated in order to minimize any immediate effect of analgesics which could have possibly given to the patient at the time point of assessment of the VAS. At the same time, dosage and specific analgesia was recorded. Other parameters were age, gender, aneurysm location, vasospasms, ischemia.

Cerebral vasospasms were defined as transcranial Doppler mean velocity of MCA > 120 cm/sec, a Lindegaard Index of >4.5 or clinical deterioration.

Statistical analysis

We have tested whether pain perception differs between patients who received clipping and those who received coiling therapy using a two-sided Mann-Whitney-Wilcoxon test. Due to lack of feedback we could not test the difference at follow-up of 6 months. All statistical analysis was performed using the R statistical computing package, R version 3.2.2 as released on 2015-08-14 (<https://r-project.org/>).

Descriptive statistics including mean and standard deviation (SD) were calculated for all continuous variables.

Results

Totally, 43 patients out of 67 patients with aneurysmal subarachnoid haemorrhage fulfilled the inclusion criteria. The mean WFNS grade was 1.95 (surgical group 1.95 ± 0.8 ; endovascular group 1.95 ± 0.9). There was no statistical difference in the WFNS grades of the clipped or the coiled patient group. Also there was no difference in the fisher grades. Comorbidities of patients between the 2 groups was not significantly different either. The groups seem to be homogenous.

The mean age was 58.4 ± 10.4 years in the surgically treated group and 56.8 ± 9.6 years in the endovascular group. The female:male ratio was insignificantly different with a f : m ratio of 1.6:1 in the surgically clipped population and 3.2:1 in the endovascular coiled population.

As expected, the aneurysm location in the two groups differs significantly. Medial cerebral artery aneurysms (MCA) were treated exclusively by surgical clipping (N=10). 8 anterior communicating artery aneurysms (AcomA) were clipped and 6 were coiled, whereas 3 posterior communicating artery aneurysms (PcomA) were clipped and 5 endovascularly treated. One pericallosal artery aneurysm was treated by surgery and 3 were treated endovascular. All the aneurysms of the posterior circulation (N=6) were coiled.

In the surgically clipped group, the pain decreased from initially 9.9 ± 0.29 before surgery to 1.09 ± 1.96 24 h after surgery. In the endovascular group the pain decreased from initially 9.14 ± 1.68 to 5.6 ± 2.07 in the same time point. This difference of VAS score decrease of 8.8 ± 2.03 points in the surgical group vs 3.38 ± 2.67 points in the endovascular group immediately after treatment was highly statistical significant at a $P < 0.001$ (Figure 1). Twenty-one days after aneurysm treatment the VAS score was 0.68 ± 1.46 in the *clipped* group and

1.8 ± 1.99 in the *coiled* group with a p value of < 0.05 . Three months after treatment the pain score was 0.11 ± 0.33 in the surgical population and 0.9 ± 1.91 in the endovascular population. The pain score at this time point was not significantly different between the two groups.

Subgroup analysis of posterior vs anterior circulation aneurysms provided the same results as the whole group since all posterior circulation aneurysms were coiled (Figure 2).

Another subgroup analysis of anterior circulation aneurysms only showed that patients with surgically treated aneurysms

recovered significantly faster than endovascular treated patients (Figure 3). To exclude the possibility of bias caused by a hydrocephalic state in the coiling group, which could lead to a higher level of headaches, we evaluated the number of patients with development of hydrocephalus. N=9 patients suffered of hydrocephalus. Four patients were in the surgically treated group and 5 in the endovascular group. The patient number of hydrocephalus was almost similar between the 2 groups and can be excluded as a confounder.

Analgesia as a confounder?

We calculated the dosages of analgesia

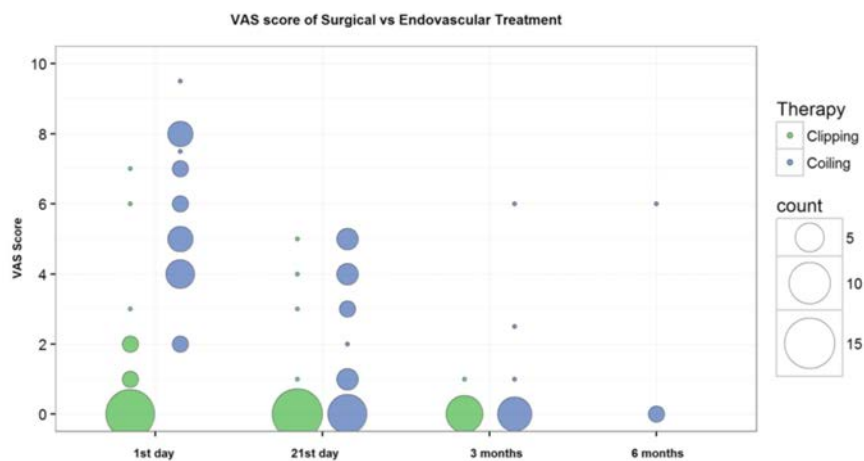


Figure 1. Effects of surgical clipping vs endovascular coiling on cessation of headaches in patients with aSAH. Initially both groups had a pain score of > 9 . 24 hours after treatment the pain decreased dramatically in the surgically treated patients whereas in the coil-embolized group there were still significant headaches ($p < 0.001$). After 21 days this effect is less obvious but still significant ($p < 0.05$). After 3 months the difference between the 2 groups is not significant and the patients have a VAS score of less than 1.

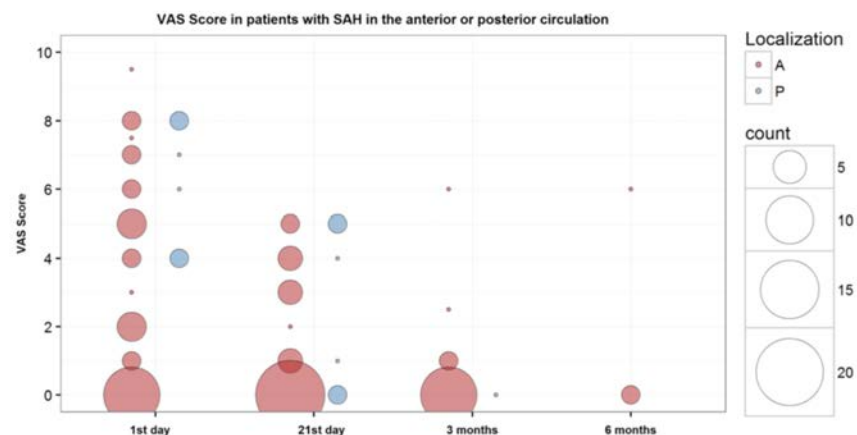


Figure 2. VAS scores in the subgroup of patients with SAH in the anterior vs posterior circulation. When the patient population was divided in anterior circulation and posterior circulation SAH there is still a highly significant cessation of headaches in the anterior circulation group. The posterior circulation group was treated exclusively endovascularly.

in the first 24 h for every patient. Almost every patient in the endovascular group received more analgesics as in the surgical group.

We treated the patients with novaminsulfon, paracetamol, dipidolor boluses of 7.5 mg and Sufentanol i.v.

The surgically treated patients received a mean of 2.7 g novaminsulfon \pm 0.65 (median: 3) and the endovascular treated patients received 2.66 \pm 0.79 g novaminsulfon (median: 3). The difference in the dosage was not significant. For dipidolor the surgically treated patients received 10.7 \pm 5.9 mg (median 7.5 mg, 1 bolus) and the endovascular treated patients 21.87 \pm 11.28 mg (median 22.5 mg, 3 boluses). The endovascular treated patients received significantly more dipidolor ($P < 0.05$). The dosage of sufentanol i.v. was in both groups similar with 366.6 \pm 265 μ g (median: 340) in the surgical group and 386 \pm 337 μ g (median: 380) in the endovascular group. Paracetamol was also not significantly different with 1.25 \pm 0.5 g (median: 1) in the surgical group and 1.71 \pm 0.95 g (median: 1) in the endovascular group.

Discussion

There seems to be a benefit of *clipping* vs *coiling* concerning post-procedural headaches, which can be observed immediately after surgery, remains significant even after 3 weeks and subsides after 3 months. Especially with coil embolization there are

a number of studies indicating an increase of headaches immediately after the endovascular intervention of incidental aneurysms, which seems to subside after 3 months.² These results are in perfect accordance to our study concerning ruptured aneurysms. Another study shows a 55.6% incidence of newly developed headaches in patients after endovascular procedure.² A possible mechanism of post-coiling headaches could be local thrombotic events and the dilation of the vessel wall which leads to endothelial inflammation.^{2,4,5} The intracranial arteries (especially the proximal portions) are highly innervated by sensory nerves that could be activated by these inflammatory processes as well as by structural changes of the vessel walls caused by embolization and coil packing.^{2,6-8} Coil packing seems to play a crucial role in the development of post-coiling headaches. A coil attenuation of more than 25% was identified as a risk factor for post-coiling headache.⁹

We did not observe residual headaches in surgically clipped patients. Application of a surgical clip does not apply any additional pressure to the aneurysm wall, neither causes any inflammation during thrombotic embolization and the absence of these phenomena could explain why we did observe such a significant difference in the headache cessation of the surgically treated group compared to the endovascular group. On the other hand more aneurysms in the clipped group were MCA aneurysms and there is a possibility that the innervation of the more distally located vessel is different than the

vessels, which are closer to the circle of Willis. But even the AcomA-aneurysms, which were surgically treated, showed an immediate alleviation of headaches after the procedure. The prevalence of craniotomy related headaches which varies from 0-50% has to be kept in mind concerning the long term effects of aneurysm treatment in the clipped group.^{2,10,11} Nevertheless, the long term effects of surgery vs endovascular coil embolization in concern of post-procedural headaches should be a subject of further clinical study.

However, our present analysis is limited because of its retrospective character and the measure of the pain with the semi-objective VAS as well as the limited number of patients. The retrospective study can lead to imbalances in the 2 populations but the two groups were as homogenous as possible for a retrospective study.

Other kinds of pain, like temporomandibular joint pain, which can appear after surgery were not assessed in the study. The main reason of not including this complain in the study was that the first 3 weeks after the bleeding it was less of a concern to the patients and at 3 months, patients were not having any complain in this area.

Conclusions

To our knowledge this is the first study evaluating the immediate effects of post-procedural headaches in surgically clipped vs endovascular-coiled patients with ruptured aneurysms of WFNS grades 1-3. It could be shown that after clipping the headaches almost disappeared after 24 h and do not reappear during the follow up period of 3 months whereas after coil-embolization, headaches were still present in the first 3 weeks and disappeared after 3 months.

References

1. Gu DQ, Duan CZ, Li XF, et al. Effect of endovascular treatment on headache in elderly patients with unruptured intracranial aneurysms. *AJNR Am J Neuroradiol* 2013;34:1227-31.
2. Choi KS, Lee JH, Yi HJ, et al. Incidence and risk factors of postoperative headache after endovascular coil embolization of unruptured intracranial aneurysms. *Acta Neurochir* 2014;156:1281-7.
3. Bederson JB, Connolly ES Jr, Batjer HH, et al. American Heart Association. Guidelines for the management of

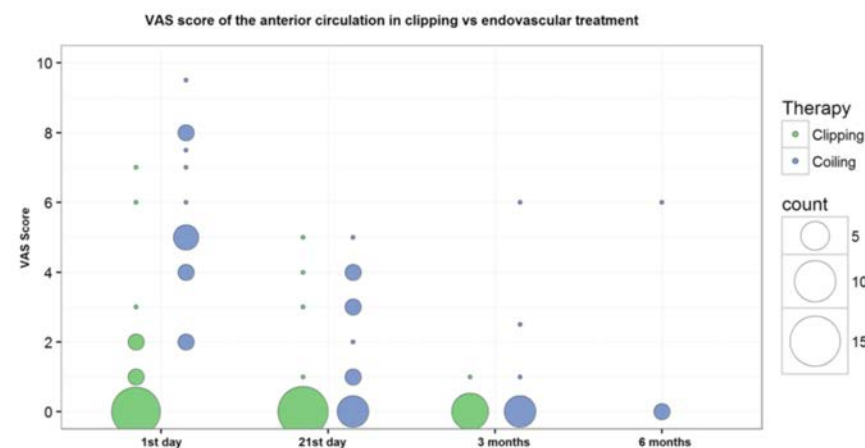


Figure 3. VAS scores in the subgroup of anterior circulation SAH. When the subgroup of anterior circulation SAH was analysed there is still a highly statistical decrease of headaches in the N=22 surgically clipped patients vs the N=14 endovascular treated patients in the first 24 hrs ($p < 0.001$) which lasts for the first 3 weeks.

- aneurysmal subarachnoid hemorrhage: a statement for healthcare professionals from a special writing group of the Stroke Council, American Heart Association. *Stroke* 2009;40:994-1025.
4. Murayama Y, Vinuela F, Tateshima S, et al. Bioabsorbable polymeric material coil for embolization of intracranial aneurysms: a preliminary experimental study. *J Neurosurg* 2001;94:454-63.
 5. Thornton J, Dovey Z, Alazzaz A, et al. Surgery following endovascular coiling of intracranial aneurysms. *Surg Neurol* 2000;54:352-60.
 6. Keller JT, Beduk A, Saunders MC. Origin of fibers innervating the basilar artery of the cat. *Neurosci Lett* 1985;58:263-8.
 7. Mayberg M, Langer RS, Zervas NT, Moskowitz MA. Perivascular meningeal projections from cat trigeminal ganglia: possible pathway for vascular headaches in man. *Science* 1981;213:228-30.
 8. O'Connor TP, van der Kooy D. Pattern of intracranial and extracranial projections of trigeminal ganglion cells. *J Neurosci* 1986;6:2200-7.
 9. Hwang G, Jeong EA, Sohn JH, et al. The characteristics and risk factors of headache development after the coil embolization of an unruptured aneurysm. *AJNR Am J Neuroradiol* 2012;33:1676-8.
 10. Baldwin RL. Headache prevention in retrosigmoid vestibular nerve section. *South Med J* 1996;89:375-9.
 11. Jackson CG, McGrew BM, Forest JA, et al. Comparison of postoperative headache after retrosigmoid approach: vestibular nerve section vs vestibular schwannoma resection. *Am J Otol* 2000;21:412-6.