

Fetal Bovine Collagen Matrix in the Treatment of a Full Thickness Burn Wound: A Case Report With Long-Term Follow-Up

Amy L. Strong, PhD, MPH,* Danielle K. Bennett, NP,† Elizabeth B. Spreen, RN,† Dhaval V. Advharyu, MD,† Jeffrey C. Littleton, MD,† Ernest J. Mencer, MD†

The treatment of full thickness skin wounds commonly associated with large burns continues to represent a challenging clinical entity. The current treatment for large TBSA burns is split thickness autologous skin grafting; however, this treatment often results in poor textural durability, hypertrophic scarring, and fibrotic contractures. In this case report, we describe our experience and long-term follow-up results after the application of fetal bovine collagen (FBC) matrix (PriMatrix, TEI Biosciences, Boston, MA) to burn wounds clinically assessed as full thickness that healed without the need for subsequent skin grafting. The patient presented with 25% TBSA burns and was debrided and covered with FBC on postburn day 7. By postoperative day 12, the patient had large areas of reepithelialization distributed throughout the wound bed. By postoperative day 26, the patient had significantly more areas of wound closure and was discharged. Reepithelialization and repigmentation continued, and long-term follow-up after 26 months demonstrated complete reepithelialization and nearly complete repigmentation, without the appearance of contractures or hypertrophic scarring. This case report highlights the use of FBC as a scaffold capable of dermal regeneration and spontaneous reepithelialization with an excellent long-term functional and cosmetic outcome. (*J Burn Care Res* 2016;37:e292–e297)

Advances in intensive and supportive care have reduced the morbidity and mortality associated with large TBSA burns. Much of this success has been attributed to early surgical intervention to debride eschar from wounds and provide sufficient wound coverage.¹ Surgical debridement to remove necrotic tissue from burn wounds can result in challenging defects that are unable to be closed primarily.² While autologous skin grafting remains the accepted standard for the coverage of burns, it is not always possible to perform split thickness skin grafting

(STSG). This results in compromised functionality and appearance.

Fetal bovine collagen (FBC; PriMatrix, TEI Biosciences, Boston, MA) is a dermal repair scaffold intended for the management of partial and full thickness wounds. This matrix is intended to augment the dermal component of a STSG and improve the durability, functionality, and aesthetic outcomes of the reconstruction. The FBC matrix is particularly rich in type III collagen, a collagen that is active in developing and healing tissues.^{3,4} On implantation, FBC has been shown to provide an ideal matrix capable of cellular repopulation and revascularization, facilitating the regeneration of histologically healthy dermis.^{5,6} Recent clinical reports have demonstrated successful reconstruction of surgical or traumatic full thickness skin wounds after the implantation of FBC and subsequent placement of a STSG.^{7,8}

Likewise, we have observed excellent outcomes after the application of FBC on deep partial-thickness and full-thickness wounds with subsequent application of STSGs. In this case report, however, we describe a unique finding of a 25% TBSA burn wound that was clinically excised to full thickness, treated with FBC, and achieved wound closure without the need for a subsequent STSG. This case demonstrates the reconstitution

*From the *Center for Stem Cell Research and Regenerative Medicine, Tulane University, School of Medicine, New Orleans, Louisiana; and †Baton Rouge General Medical Center, Baton Rouge, Louisiana.*

E.J.M. receives honoraria from TEI Biosciences.

Address correspondence to Ernest J. Mencer, MD, Regional Burn Center, Baton Rouge General Medical Center, 3600 Florida Boulevard, Baton Rouge, Louisiana 70806. E-mail: etmencer@cox.net

Copyright © 2014 by the American Burn Association. This is an open-access article distributed under the terms of the Creative Commons Attribution-Non Commercial-No Derivatives License 4.0 (CCBY-NC-ND), where it is permissible to download and share the work provided it is properly cited. The work cannot be changed in any way or used commercially.

1559-047X/2014

DOI: 10.1097/BCR.0000000000000221

and revascularization of FBC and highlights the capacity of the generated tissue to support spontaneous reepithelialization from the epidermal cells remaining after debridement. Long-term outcomes demonstrate excellent durability, functionality, and appearance of the spontaneously reepithelialized wound.

CASE REPORT

A 48-year-old woman presented with hot grease burns to her lower extremities. The patient had a 25% TBSA burn, which included a mixture of second-degree, deep second-degree, and third-degree burns involving the anterior aspect of the right lower extremity, the medial aspect of the left lower extremity, and the dorsum of both feet (Figure 1A).

Wound Care and Surgical Techniques

The patient was admitted to the hospital to manage the burn wounds. The wounds were initially treated

with Silvadene. After 5 days, the patient's burns demonstrated progression from second-degree burns to deeper second-degree and third-degree burns (Figure 1B). Seven days postinjury, the patient underwent tangential excision of necrotic tissue of her lower extremities, which led to wounds clinically assessed to require FBC matrix and subsequent STSG based on our burn treatment protocol. A total of 1100 cm² and 2400 cm² of FBC was meshed 3:1 and 4:1 and applied to the debrided areas of the left and right lower extremity, respectively. The FBC was secured in place with skin staples and thrombin glue. The wounds were dressed with bridal veil, Xeroform, Softsorb soaked in an antibiotic solution containing Neosporin G.U. Irrigant and Bacitracin, Kerlix rolls, and Ace bandages.

The patient's postoperative course was benign, and during her first dressing change (3 days postoperatively), the FBC was noted to be intact and in the early stages of engraftment (Figure 2A). Subsequent to this, the patient received daily wound care and physical therapy. Postoperative evaluation after 10 days

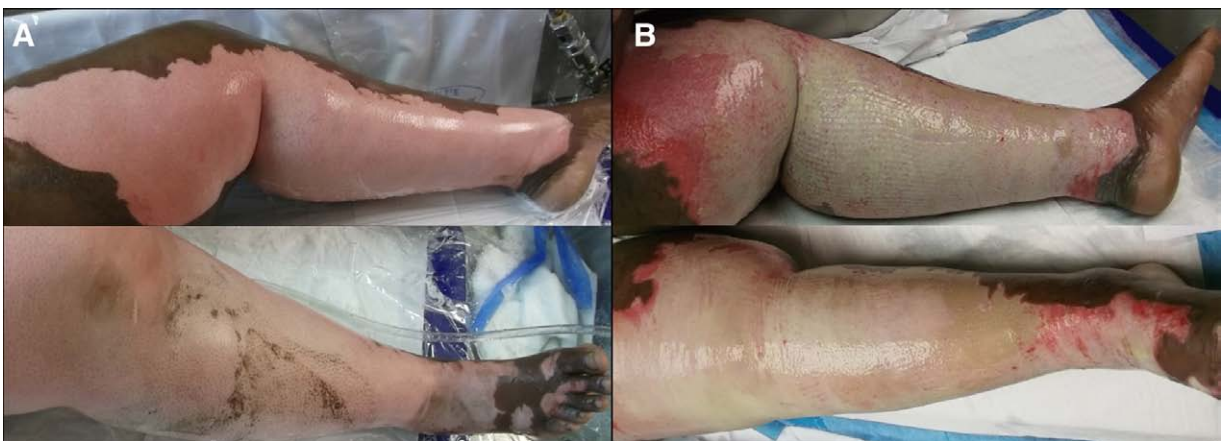

Figure 1. Evaluation of bilateral thigh burns. A. Initial appearance of patient's legs at presentation. B. Patient's burns demonstrate conversion of second-degree burns to third-degree burns after 5 days.

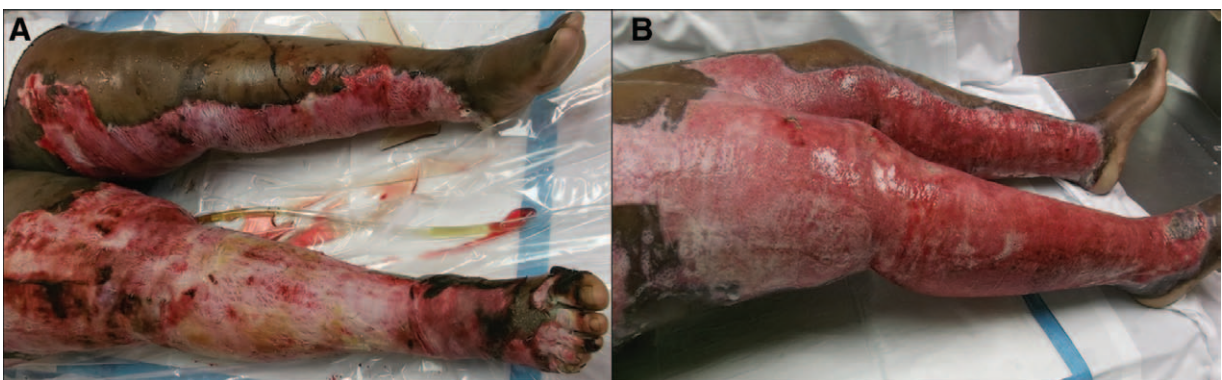


Figure 2. Postoperative evaluation of burn wounds. A. After 3 days, FBC was adherent to wound bed with granulation tissue beginning to fill the interstices of the FBC. B. After 10 days, initial appearance of wound reepithelialization was visible. FBC, fetal bovine collagen.

demonstrated tissue regeneration (Figure 2B), and the wounds were deemed suitable for skin grafting. When the patient was taken to the operating room 2 days later for skin grafting, islands of reepithelialization were noted in the center of the wound bed covering areas where FBC was applied. Skin grafting was not performed to allow the wounds to further reepithelialize. Punch biopsies were taken at this time in an effort to elucidate pertinent microscopic activity.

Histological Analysis

Two punch biopsies were taken 12 days post-FBC application as noted in Figures 3 and 4. Biopsies were placed in 10% buffered formalin and processed by Strata Pathology Services (Lexington, MA). Hematoxylin and eosin (H&E; Polyscientific, Bay Shore, NY) staining was

performed to assess the dermis. To distinguish between human dermal collagen fibers and bovine collagen fibers, tissue sections were stained with an antibody specific to bovine collagen type I and a fluorescein isothiocyanate conjugated secondary antibody (Millipore, Billerica, MA). A fluorescent cellular counterstain was used to visualize nuclei within tissue sections (Hoeschst 34580, Life Technologies, Grand Island, NY). Keratinocytes were identified using antibodies to cytokeratin 5, a fibrous structural protein, and p63, an essential transcription factor for epithelial development and proliferation. p63 has also been shown to be expressed on keratinocyte stem cells.⁹ CD31a was used to evaluate endothelial cell borders, and Ki-67 was used as a cellular marker for proliferation. All human antibodies were purchased from Biocare Medical (Concord, CA).

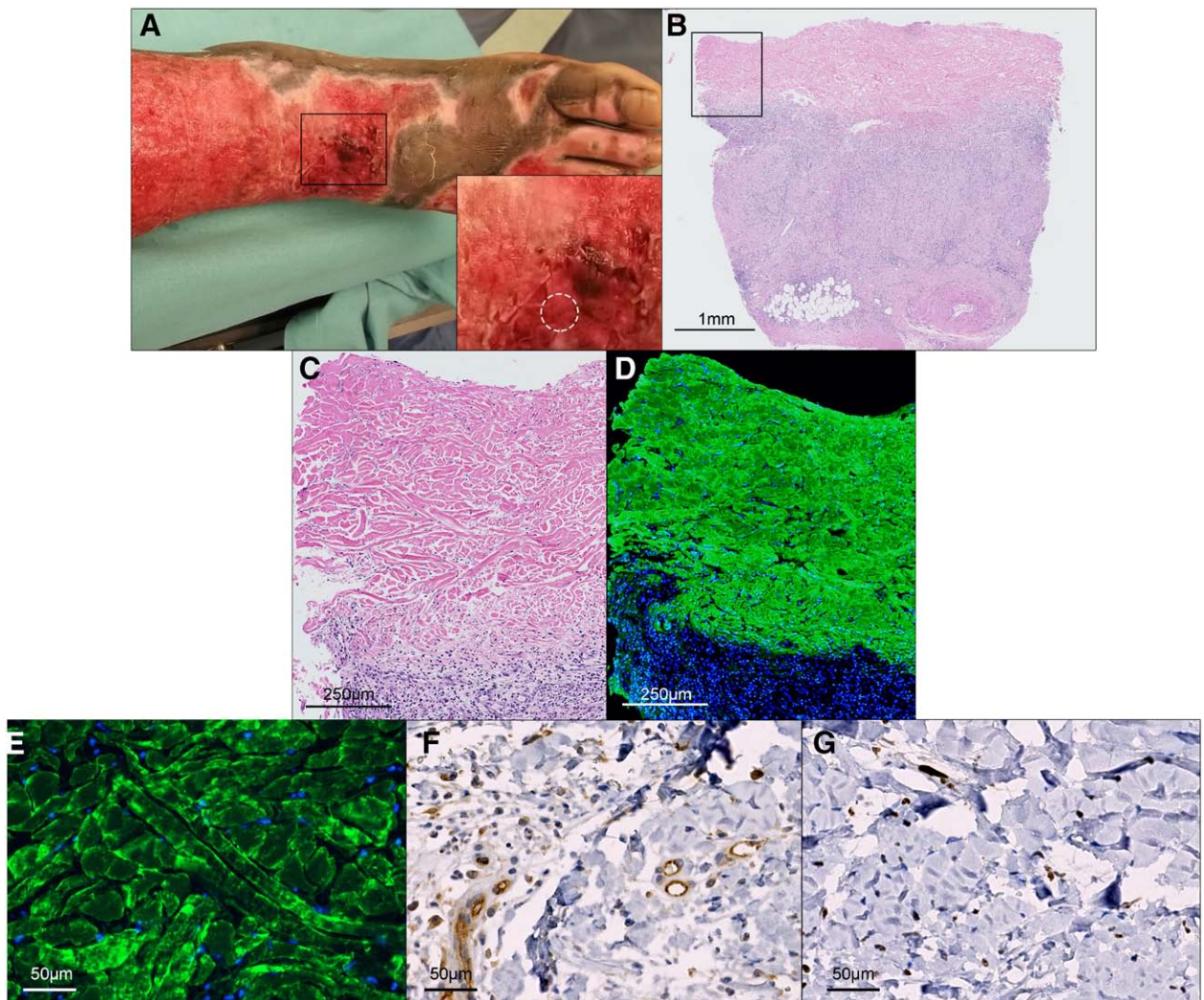


Figure 3. Biopsy 1 following treatment of burn wounds with FBC matrix after 12 days. Representative images of right foot biopsy demonstrating FBC engraftment and revascularization, without reepithelialization. A. A punch biopsy was taken from the right leg as indicated in A1 by the dotted circle. Tissue was processed and stained with (B, C) H&E, (D, E) bovine collagen type I (green) and hematoxylin to color cellular nuclei (blue), (F) CD31a, (G) Ki-67. FBC, fetal bovine collagen; H&E, hematoxylin and eosin.

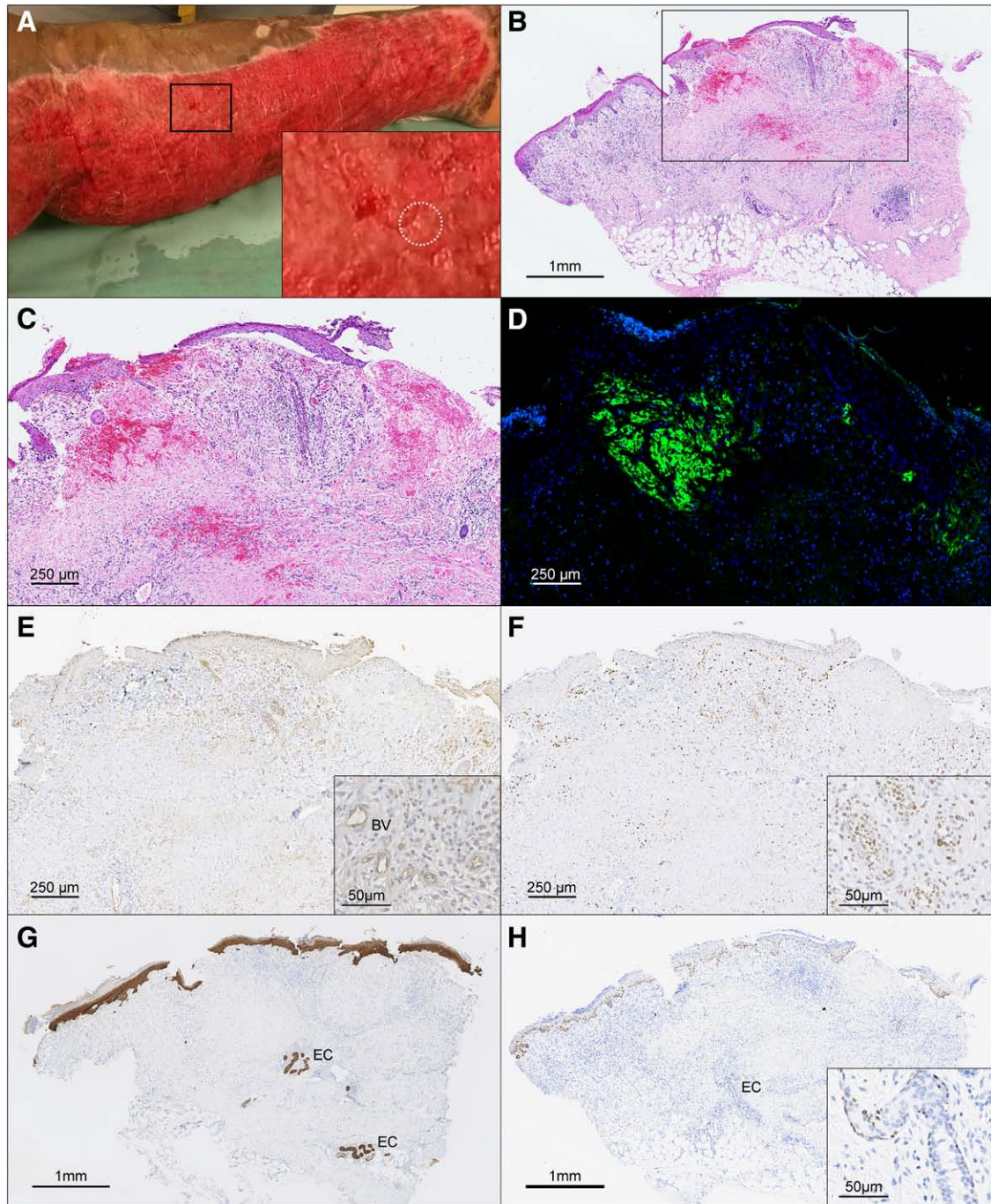


Figure 4. Biopsy 2 after treatment with FBC matrix after 12 days. Representative images of left leg biopsy showing FBC incorporation, revascularization, and reepithelialization. A. A punch biopsy was taken from the left leg as denoted by the dotted circle. Tissue was processed and stained with (B, C) H&E, (D) bovine collagen type I (green) and hematoxylin to color cellular nuclei (blue), (E) CD31a, (F) Ki-67, (G) CK5, and (H) p63. Insets in E, F, and H highlight positive staining. *BV*, blood vessels; *EC*, epidermal cells; *FBC*, fetal bovine collagen; *H&E*, hematoxylin and eosin.

Biopsy 1. H&E staining of the biopsy obtained from the right lower extremity demonstrated a full thickness wound containing dermal collagen fibers (Figure 3A–E). Immunohistochemical staining of serial sections from this biopsy revealed the presence of

bovine collagen type I repopulated with the patient's cells (Figure 3E). The thickness of this tissue was approximately 1 mm and contained histotypic dermal collagen fibers populated with cells at a similar density to that of uninjured human dermis. Proliferating

cells and vasculature were found in the FBC, suggesting the repopulation of the dermis with the patient's cells (Figure 4F, G). These results represent the early stages of wound healing after FBC application.

Biopsy 2. The biopsy obtained from the left lower extremity revealed islands of reepithelialization that could be seen clinically as well as histologically (Figure 4A–C). H&E staining indicated the biopsy contained irregular mixtures of regions with remnants of dermal and epidermal components (Figure 4C, D). Immunohistochemical staining of serial sections from this biopsy revealed the presence of a 0.75-mm thick region of bovine collagen type I (Figure 4D). Proliferating cells and vasculature were found throughout the biopsied tissue (Figure 4E, F). A stratified squamous epithelium was present on top of the bovine collagen dermal fibers as well as within the interstices of the FBC (Figure 4H, I). Approximately 1 mm and 2 mm from the surface of the wound, small clusters of keratinocytes were detected adjacent to adipocytes visible by cytokeratin 5 staining. A percentage of the epidermal cells also stained positive for p63 (Figure 4). This biopsy demonstrated the capacity for the FBC to be repopulated and revascularized with the patient's own cells and provided a supportive environment for epidermal cell migration and reepithelialization.

Long-Term Follow-Up

During the next few days, wounds covered with FBC continued to undergo reepithelialization, and as a result, on postoperative day 18, a final decision was made not to perform skin grafting. On postoperative day 26, significant reepithelialization of her wounds was observable (Figure 5A), and the patient was discharged on postoperative day 30.

Long-term follow-up of the patient after discharge was uneventful. On postoperative day 53, the patient displayed additional reepithelialization and repigmentation (Figure 5B). Examination of the patient's skin on postoperative day 80 and day 102 revealed complete wound closure and additional repigmentation (Figure 5C, D). Subsequent follow-up of the patient after 6 months, 9 months, 12 months, and 26 months revealed healthy, soft, and supple skin, without any visible signs of hypertrophy or fibrosis (Figure 5E–H). The patient also had full range of motion without signs of contracture.

DISCUSSION

In this case study, we report on a patient with a 25% TBSA burn treated with FBC matrix postexcision that healed without subsequent autologous

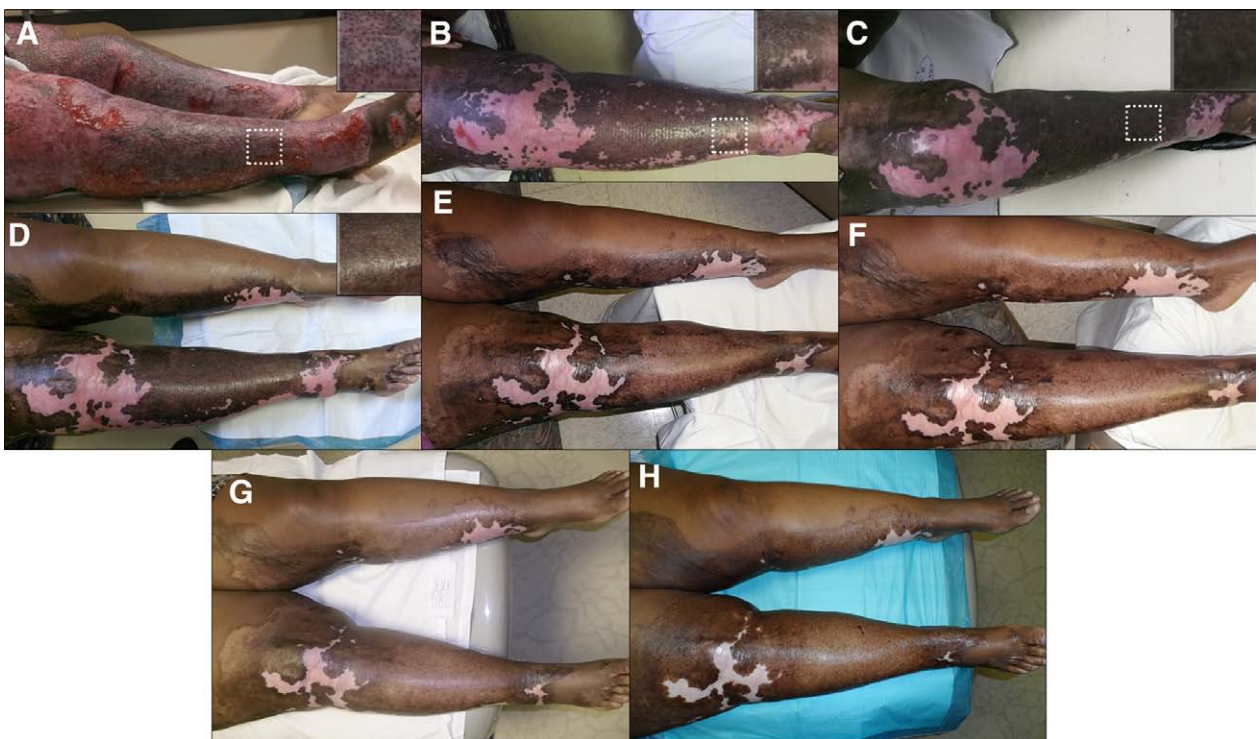

Figure 5. Long-term follow-up of patient after application of FBC. A. After 26 days, (B) 53 days, (C) 80 days, (D) 102 days, (E) 6 months, (F) 9 months, (G) 12 months, (H) 26 months after FBC application. Skin was soft and supple with no observable hypertrophic scarring. *FBC*, fetal bovine collagen.

skin grafting. Long-term evaluation after 26 months post-FBC application indicated healthy skin, without any visible signs of disfigurement. Moreover, repigmentation was visible over 85% of the treated areas.

Immunohistological analysis of biopsies obtained 12 days post-FBC application demonstrated that the FBC was capable of generating a dermal component approximately 0.75 mm to 1 mm in thickness with the capacity to support reepithelialization. Additionally, it was noted that the wound bed contained a mixture of full thickness and deep partial thickness zones. Staining for human keratinocyte markers indicated small islands of remaining epidermal cells found adjacent to the deep reticular dermis. Keratinocytes located next to the intradermal epithelial structures are hypothesized to have migrated through the FBC matrix and contribute to the reepithelialization of the wound. Although biopsies were not obtained at later time points, it can be inferred that a fully stratified layer of keratinocytes formed and that a basement membrane was established between the epidermal and dermal components of the skin, based on the continued durability of the skin and the lack of recidivism observed during follow-up.

The results from this case demonstrate a potential treatment strategy to reduce the amount of donor skin needed to reconstruct wounds during surgical intervention, especially wounds with indeterminate depth. The burn injury may be excised, treated with FBC to regenerate dermal tissue, and reassessed to determine areas requiring skin grafting based on the amount of reepithelialization. If reepithelialization is not noted within 2 to 3 weeks, there is no delay in treatment regimen, and autologous skin grafting can proceed over the newly generated dermal tissue as originally planned. However, if areas of reepithelialization are visible, close monitoring of the rate of

reepithelialization is necessary to determine whether the reepithelialization may result in the closure of the wound without STSG.

Long-term follow-up indicated excellent functional and cosmetic outcomes for an injury of this extent and size that healed without autologous grafting. Consistent with previous reports that use FBC, the outcomes of this study suggest that the regenerated dermal tissue aided by the FBC contributed to the durability, functionality, and appearance of the healed wound.⁶ In summary, these results encourage further use of FBC to treat patients with deep partial thickness and full thickness burns for possible wound coverage.

REFERENCES

1. Kasten KR, Makley AT, Kagan RJ. Update on the critical care management of severe burns. *J Intensive Care Med* 2011;26:223–36.
2. Strauss NH, Brietstein RJ. Surgical debridement to remove necrotic tissue from burn wounds can result in challenging defects that are unable to be closed primarily. *Wounds* 2012;24:327–34.
3. Smith LT, Holbrook KA, Madri JA. Collagen types I, III, and V in human embryonic and fetal skin. *Am J Anat* 1986;175:507–21.
4. Ramshaw JA. Distribution of type III collagen in bovine skin of various ages. *Connect Tissue Res* 1986;14:307–14.
5. Rennert RC, Sorkin M, Garg RK, et al. Cellular response to a novel fetal acellular collagen matrix: implications for tissue regeneration. *Int J Biomater* 2013;2013:527957.
6. Kohanzadeh S, Martin MS, Lugo LM, et al. Primatrix as an alternative to flap reconstruction. *Plast Reconstr Surg* 2013;132:92.
7. Hayn E. Successful treatment of complex traumatic and surgical wounds with a foetal bovine dermal matrix. *Int Wound J* 2013;11:675–80.
8. Neill J, James K, Lineaweaver W. Utilizing biologic assimilation of bovine fetal collagen in staged skin grafting. *Ann Plast Surg* 2012;68:451–6.
9. Pellegrini G, Dellambra E, Golisano O, et al. p63 identifies keratinocyte stem cells. *Proc Natl Acad Sci U S A* 2001;98:3156–61.