



Sialidosis type II: Expansion of phenotypic spectrum and identification of a common mutation in seven patients

Veronica Arora^a, Nitika Setia^a, Ashwin Dalal^b, Maria Celestina Vanaja^b, Deepti Gupta^a, Tinku Razdan^c, Shubha R. Phadke^d, Renu Saxena^a, Anshu Rohtagi^e, Ishwar C. Verma^a, Ratna Dua Puri^{a,*}

^a Institute of Medical Genetics and Genomics, Sir Ganga Ram Hospital, New Delhi 110060, India

^b Diagnostics Division, Centre for DNA Fingerprinting and Diagnostics, Hyderabad, India

^c Department of Ophthalmology, Sir Ganga Ram Hospital, New Delhi 110060, India

^d Department of Medical Genetics, Sanjay Gandhi Post Graduate Institute of Medical Sciences, Lucknow, India

^e Department of Neurology, Sir Ganga Ram Hospital, New Delhi 110060, India

ARTICLE INFO

Keywords:

Common mutation
Bull's eye maculopathy
Sialidosis type II
NEU1
Polypheny
North India

ABSTRACT

Sialidosis, an autosomal recessive disorder, is characterized by progressive lysosomal storage of sialylated glycopeptides and oligosaccharides. It occurs as a result of biallelic mutations in the *NEU1* gene. Sialidosis is traditionally classified as a milder, late-onset type I and a severe early-onset type II disease. The presence of a cherry-red spot is a well-established ophthalmological clue to the disorder. We present a clinical-radiological report of seven unrelated patients with molecularly confirmed sialidosis type II. To the best of our knowledge, This is the largest reported series of patients with Sialidosis type II. A novel, previously unreported ophthalmic phenotype of bulls-eye maculopathy, is described. All seven phenotypically heterogeneous patients had the same pathogenic variant (c.679G > A; p.Gly227Arg) at a homozygous level in the *NEU1* gene. We propose that this is a common mutation in north Indians for this rare disorder. We also observed an overlap of symptoms and a continuum of phenotypes in type I and II Sialidosis.

1. Introduction

Sialidosis, (MIM#256550), also known as mucopolipidosis 1 [ML1] is a rare autosomal recessive disorder characterized by progressive lysosomal storage of sialylated glycopeptides and oligosaccharides as a result of deficiency of the enzyme, neuraminidase [1]. Its incidence is reported to be 0.04 in 100,000 (www.orpha.net). Type I is the milder 'normosomatic' type or the cherry red spot-myoclonus syndrome. Sialidosis type II is a severe form with earlier onset, referred to as the 'dysmorphic' type. Type II is further classified into congenital, infantile, and juvenile forms [2]. Ophthalmological clues play a vital role in the diagnosis of several lysosomal storage disorders, including sialidosis. Cherry red spot is the most distinctive ocular manifestation of sialidosis, but other signs such as nystagmus and cataract have also been described [3]. These reflect the deposition of sialylated glycoproteins in the retina or lens.

The clinical features of sialidosis (coarse facies, hepatosplenomegaly) have an overlap with the many lysosomal storage disorders. These

must be excluded in the patients based on clinical, biochemical, and enzymatic studies. In sialidosis, pathogenic variants are described in almost all exons of *NEU1*, but more commonly observed in exons 4 and 5 [4], exhibiting the tendency of variant clustering.

We present seven molecularly confirmed cases of sialidosis type 2, from six unrelated families originating from the northern part of India. All patients were identified to have a common homozygous mutation in exon 4 of the *NEU1* gene. We also report a novel ophthalmological sign in one patient.

2. Materials and methods

2.1. Clinical and laboratory investigations

The case records of seven patients from six unrelated families referred to the Lysosomal Storage Disorders Clinic from January 2000 through December 2017 were examined. A detailed phenotype as per the proforma was compiled for all patients. The clinical data and

* Corresponding author at: Ganga Ram Institute of Post Graduate Medical Education & Research, Institute of Medical Genetics and Genomics, Sir Ganga Ram Hospital, New Delhi 110060, India.

E-mail address: ratnadpuri@yahoo.com (R.D. Puri).

<https://doi.org/10.1016/j.ymgmr.2019.100561>

Received 12 September 2019; Received in revised form 25 December 2019; Accepted 25 December 2019

2214-4269/© 2020 The Authors. Published by Elsevier Inc. This is an open access article under the CC BY-NC-ND license (<http://creativecommons.org/licenses/by-nc-nd/4.0/>).

relevant investigations such as liver function tests, renal function tests, magnetic resonance imaging (MRI), radiographs, and photographs of the fundus were collated and correlated with the clinical presentation. Patients with incomplete data were recalled and re-examined.

2.2. Genetic analysis of *NEU1* gene

Written informed consent was obtained from the families to perform the genetic study. Blood samples were obtained from affected probands and their parents. Genomic DNA was extracted from peripheral blood leukocytes by the phenol-chloroform method. Next-generation sequencing was performed on DNA samples using Illumina HiSeq platform for around 8500 clinically relevant genes. The reads obtained were analyzed for *NEU1* gene. Standard bioinformatics pipeline, including base calling, alignment of reads to GRCh37/hg19 genome assembly, primary filtering out of low-quality reads and probable artefacts, and subsequent annotation of variants, was applied on raw data files. Variants found in the *NEU1* gene were further evaluated and validated by Sanger sequencing. Probands from all six families were homozygous for the previously reported (Table 2) variant in exon 4 of *NEU1* gene (c.679 G > A; p.Gly227Arg).

2.3. Validation of *NEU1* gene variant by sanger sequencing

Genomic DNA samples of the affected proband and the parents from all six families were subjected to PCR amplification for exon 4 of *NEU1* gene using primers sequences designed by primer3 software (<https://www.yeastgenome.org/primer3>) (*NEU1*- Exon 4 - F:5'- TGAGCCCCTA GAGTCTCCTT-3' and *NEU1*-Exon5-R:5'- ATGATGTTCTGAGGGCAGG-3'). PCR products were checked for quality on agarose and purified using MicroAmp purification plate and sequenced by dideoxynucleotide termination methodology using the BigDye terminator v3.1 cycle sequencing kit (Applied Biosystems by Thermo Fisher Scientific, USA) on ABI 3500 Genetic Analyzer (Applied Biosystems by Thermo Fisher Scientific, USA). Chromatograms obtained after sequencing were analyzed using the Chromas Pro software (Technelysium.com.au) and matched to the wild type *NEU1* gene sequence (Accession No: NM_000434) to check for the presence of the variant.

2.4. Protein structure prediction for the *NEU1* variant

For the variant identified in the *NEU1* gene, we used the software HOPE (bmcbioinformatics.biomedcentral.com) [(5)], which is an online web service with user-friendly interface for submission of sequences and variants. HOPE collects structural information from a series of sources, including calculations on the 3D protein structure, sequence annotations in UniProt, and prediction from the RefPro software.

3. Results

3.1. Clinical features

The total number of affected children in this series was seven from six families (male = 6, female = 1). Patient characteristics are presented in Table 1. The antenatal and perinatal periods were uneventful for all the patients. Consanguinity was present in two families (F1, F3), the parents being first cousins. Four of the six families (F1, F2, F3, F6) had more than one affected child of whom molecular confirmation was obtained in only F6 (P6, P7). Intrafamilial variability in the clinical symptoms was observed in family 6. Amongst the two siblings of family 6, the male was more severely affected with severe intellectual disability (ID), contractures, and scoliosis while the affected sister had mild coarse facies, mild ID, and no contractures. The mean age at the recognition of symptoms by parents was year nine months, and the mean age at diagnosis was 6.5 years, indicating a significant delay in the diagnosis. Presenting complaints included developmental delay

with coarse facies in 6/7 patients with seizures (P2, P4) and contractures (P4, P6) in two patients each.

3.2. Developmental delay

Global developmental delay was the most common reason for referral in this cohort. On evaluation, it was present in all seven patients. The cognitive domain was found to be most affected, followed by speech, and fine and gross motor milestones. Patients 4 and 6 were most severely delayed, with an IQ of 44 and 51, respectively. The most well-preserved intellect was present in patient 7. She was homozygous for the common pathogenic variant in this series and came to medical attention due to her affected sibling (P6). The average age of attainment of first meaningful words was 25 months. Motor milestones were less affected with an age of achieving independent ambulation at 19 months — the motor development co-existent with ataxia in patients 1 and 4.

3.3. Coarse facies

The human phenotype ontology defines coarse features as the absence of a fine and sharp appearance of brows, nose, lips, mouth, and chin, usually because of rounded and heavy features or thickened skin with or without thickening of subcutaneous and bony tissues. The various lysosomal storage disorders are known to demonstrate coarseness due to the accumulation of the respective substrate in the soft tissues. In our cohort, coarseness was identified in all patients, though to varying degrees (Fig. 1). The most striking facial dysmorphism was identified in patient 6 with thick eyebrows, hypertelorism, thickened skin of the face, short prominent philtrum, and thick lips.

3.4. Ataxia

Patients 1 and 4 had ataxia. On examination, the cerebellar signs were present, and Romberg was negative. MRI brain of both of these patients revealed cerebellar atrophy, with diffuse involvement of the spinal cord in patient 4.

3.5. Organomegaly

The accumulation of sialated glycopeptides and oligosaccharides in the liver and the spleen leads to their enlargement. Hepatomegaly was present in patients 2,3,4, and 6. The spleen was enlarged in patients 2 and 4. Splenomegaly in these patients was also accompanied by microcytic, hypochromic anemia, and increased levels of lactate dehydrogenase. The organomegaly caused respiratory discomfort in patient four while sleeping.

3.6. Hearing loss (HL)

HL was present in four out of seven patients. Two had mild (patient 1, 2), one moderate (P4), and one severe (P 6). Two patients had conductive, and one patient each had a sensorineural and mixed type of hearing loss.

3.7. Skeletal involvement

Dysostosis multiplex and kyphoscoliosis were the skeletal anomalies identified in this cohort.

Dysostosis was identified in patients 3, 4, 5 and 7 (Fig. 2). The severe kyphoscoliotic deformity was noted in patient 4 on the MRI study of the spine.

3.8. Ophthalmological involvement

Bilateral cherry-red spots were identified in all but patient 4. He had a distinct finding of bull's eye maculopathy (Fig. 3).

Table 1

Clinical profile of the cohort of patients with sialidosis type II. Abbreviations: DD- development, M: Male, F: female, y: year.

Family/Patient number	F1/P1	F2/P2	F3/P3	F4/P4	F5/P5	F6/P6	F6/P7	Summary statistics
Affected sibling	+	+	+	-	-	+		
Consanguinity	+	-	+	-	-	-	-	2/7
Sex	M	M	M	M	M	M	F	
Age at recognition	5 M	1Y	1.6y	1.2y	1.5y	3y	6y	1.9 y
Age at diagnosis	4.5Y	6y	4y	11y	3y	6y	8y	6.5y
Presenting complaint	DD	DD, seizures	DD, Coarse facies	DD, seizures	DD, Coarse facies	DD, Contractures	DD, coarseness	
Developmental delay	++	++	+	+++	++	+++	+	7/7
Ataxia	+	-	-	+	-	-	-	2/7
Seizures	-	+	+	-	-	-	-	2/7
Hearing loss	+	+	-	++	-	+++	-	4/7
Coarseness	+	+	+	+	+	+	+	7/7
Contractures	+	+	+	++	-	-	-	4/7
Short stature	++	+	+	+	++	+	+	7/7
Scoliosis	-	+	-	+	-	+	Mild+	5/7
Hepatomegaly	-	+	+	+	-	+	-	4/7
Splenomegaly	-	+	-	+	-	-	-	2/7
Cherry red spot	+	+	+	-	+	+	+	6/7
Dysostosis	-	-	+	+	+	-	+	4/7
Additional findings	Hernia			Bull's eye maculopathy	Nephrosialidosis. Single kidney, cerebral atrophy			

3.9. Genetic testing

A missense pathogenic variation in the exon 4 of the *NEU1* gene (c.679G > A; p.Gly227Arg) was identified in all the seven patients. All the probands were homozygous and parents were heterozygous for the variant.

3.10. Effect of the mutation on protein structure

The structure of the wild type and mutant type residues was studied to gauge the mechanism of disease for this [5]. The mutant residue arginine is bigger than the wild-type residue, glycine which is also more hydrophobic than the mutant residue. Glycine is the most flexible of all residues. This flexibility might be necessary for protein function. Mutation of glycine can abolish this function. Neither arginine residue nor another residue type with similar properties was observed at this position in other homologous sequences. Based on conservation scores this mutation is probably damaging to the protein. The mutated residue is located in a domain that is important for the activity of the protein and in contact with another domain that is also important for the activity. It

is possible that this interaction is essential for the correct function of the protein and the interaction is disturbed by the mutation. There is a difference in charge between the wild-type, neutral residue and the mutant amino acid with a positive charge.

The mutant residue also introduces a charge in a buried residue which can lead to protein folding problems. Arginine is bigger than glycine and probably will not fit. The torsion angles for arginine are unusual. The Only glycine is flexible enough to make these torsion angles, mutation into another residue will force the local backbone into an incorrect conformation and will disturb the local structure.

We analyzed the mutation also in the protein folding prediction software PSIPRED.

which showed a disturbance in the secondary structure of the protein due to the variation (Fig. 4). The variant is pathogenic according to the modified ACMG criteria [6].

As per the model, there is a disturbance in the secondary structure (Fig. 5) of the protein (marked in green)It is seen in the figure as the formation of the second strand (yellow bars) starts one amino acid later in comparison to the original strand. Similarly, the next two strands are misfolded as well. Therefore, the introduction of arginine at position

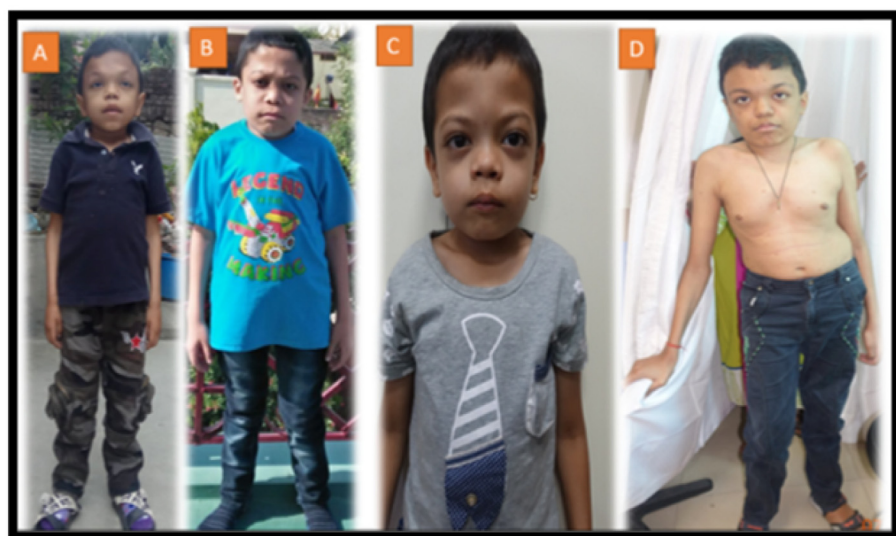

Fig. 1. Patients 1, 2, 3, 4 at ages 4.5 years, 6 years, 3 years and 11 years, respectively. Note the presence of hypertelorism, prominent supraorbital ridges, depressed and broad nasal bridge, bushy eyebrows, long prominent philtrum and prognathism (coarse facies) in all the patients. (D) Severe kyphoscoliosis was present in patient 4.

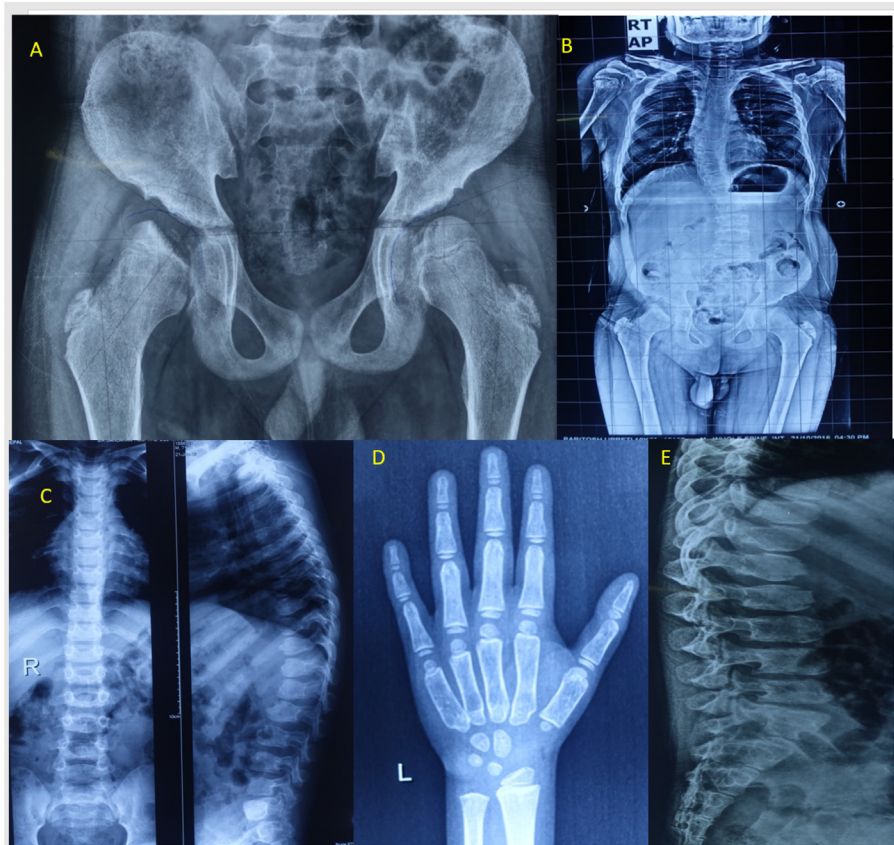

Fig. 2. Dysostosis multiplex in patient 4 (A,B,C) and patient 3 (D,E).

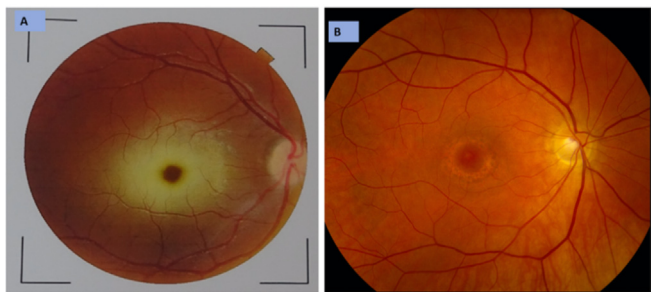


Fig. 3. a) Cherry red spot b) Bull's eye maculopathy.

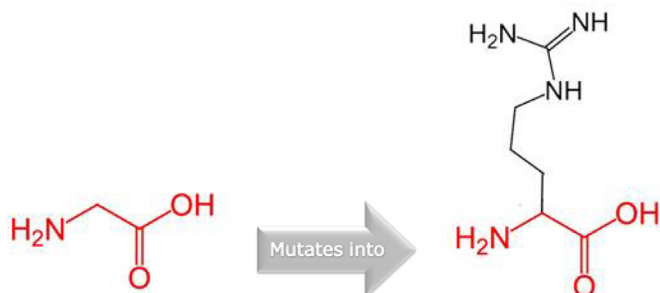


Fig. 4. Schematic structures of the original (left) and the mutant (right) amino acid. The backbone, which is the same for each amino acid, is coloured red. The side chain, unique for each amino acid, is coloured black.

227 instead of glycine, disturbs the secondary structure of the protein.

4. Discussion

We describe the clinical and molecular profile of seven new patients of sialidosis type II, infantile/juvenile type. This a rare disorder with less than twenty patients of type II described worldwide [4]. To the best of our knowledge, this is the largest series for the type II disorder. All the seven patients in this cohort have a common geographical origin and the same mutation suggesting that this may be a common mutation in North India. Further, with a novel finding of bull's eye maculopathy, we expand the phenotypic spectrum of this rare disorder.

Bonten et al. [2] described a genotype-phenotype correlation based on residual protein activity. The mutation, c.679G > A; p.Gly227Arg, reported in our patients, lies within the important β N (second strand of the third sheet) repeat region of the sialidase molecule. This mutation is predicted to produce a severe phenotype. The misfolded mutant protein is retained in the pre-lysosomal compartment with impaired lysosomal targeting and resulting lack of enzyme activity [7]. By studying the effect of this variant on the protein it is clear that arginine leads to the formation of a bulky side chain and disrupted protein function of that domain (Fig. 6).

However, in spite of the severe nature of the mutation, there is extensive phenotypic variability in the current cohort as well as in previous studies (Table 2), consistent with polyphony which is the presence of different phenotypes due to a single mutation [8]. The onset of disease ranged from 5 months to 6 years in the current study. One patient had nephrosialidosis while two others had cerebellar involvement. Though all patients were classified as type 2 sialidosis, the severity markedly varied amongst the families as well as affected siblings (patients 6 and 7). This is divergent to the theory of one mutation one phenotype and implies other possible mechanisms, including modifier

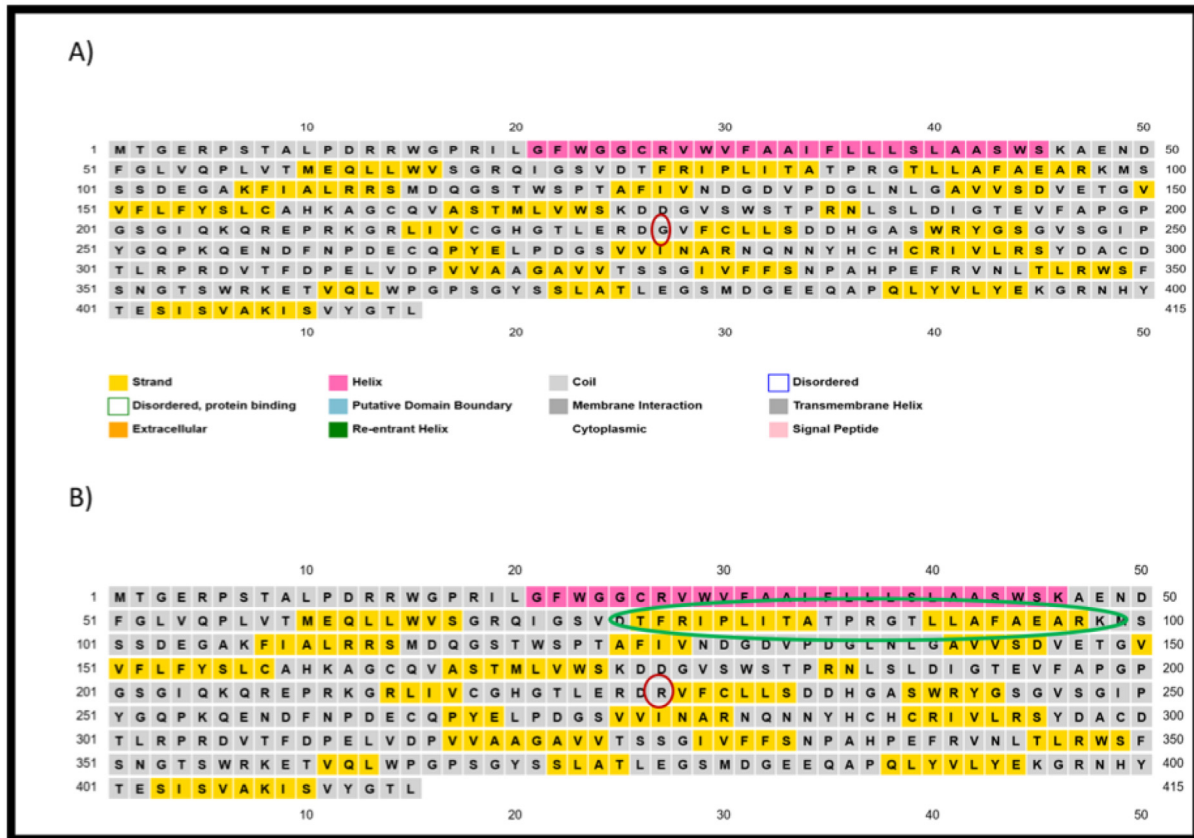

Fig. 5. (A) above shows the annotation chart of protein NEU1, while the position of interest, glycine at position 227, is marked in red. As per the chart, this glycine is a part of one of the coils in the secondary structure of the protein. (B) Arginine at position 227 instead of wild type glycine (marked in red) is present.

genes, environmental influences and epigenetic effects. This is supported by Rodríguez et al. [9] who described clinical variability in three patients of sialidosis with the same mutation. He suggested that the phenotypic expression of a mammalian enzyme activity often depends on several different genes and not only those coding its amino acid sequence. There is extra space between words in many places please delete this.

The reported phenotypes of patients with sialidosis type 1 describe overlapping features with those in the current cohort of type II sialidosis including myoclonic seizures, cherry-red spots and coarse facies. This blurs the demarcations into watertight compartments. The later age of onset and rather maintained cognition in patients of sialidosis type 1 is a more consistent differentiating factor.

Missense mutations are the most common mechanism of disease in patients with Sialidosis, though all kinds of variations are reported. Although the variant identified in this study is previously described in other populations (Table 2), we propose that this may be a common mutation in the northern part of India as it was present in all our patients. It is supported by the fact that there have been other founder variants in this gene, implying a tendency of variant clustering at a particular locus. Two variants c.928G > A and c.808C > T were found in patients of Dutch and Spanish ancestry, respectively, suggesting a common mutation [2] [7]. Further, this theory is strengthened by the fact that the other four patients reported from India who carry a different variant are from the southern part of the country [10] [11].

Ophthalmological manifestations are an important clue to the

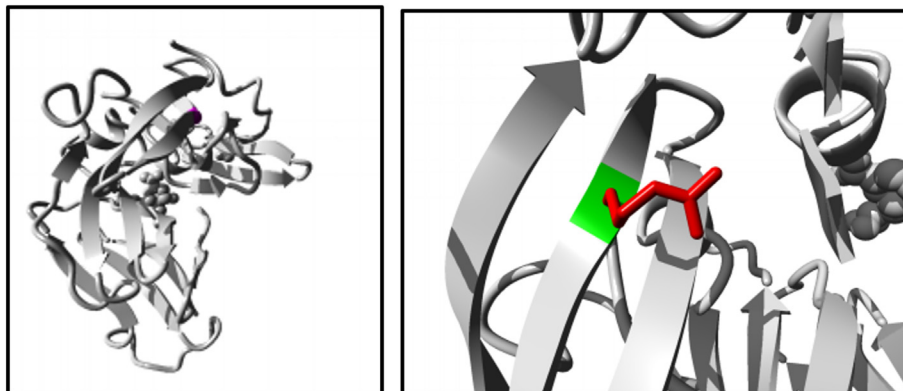


Fig. 6. (left) above shows the complete protein for NEU1 coloured in grey. (right) is a closeup of the region with the mutation. Protein is coloured in grey, the wild type residue is green and the mutant residue, arginine is shown in red with the side chain hanging out. [5].

Table 2
Previously reported patients with the same variant as in the present cohort.

No. of patients	Origin	Clinical phenotype	Reference	Year	Number of patients	Origin	Clinical phenotype	Reference	Year
2	Caucasian (1 from Mexico and other from the USA)	Homo Type 1 sialidosis /type 2	Lukong et al. [7], 2000	2000	2	1 Italian and another Greek	Homo Italian patient had type 2 sialidosis while Greek patient had type 1 sialidosis	Bonten et al. [18], 2000	2000
1	Italian	Homo Type 2 sialidosis	aciotti et al. [19], 2009	2009	3 siblings	Italian	Comp Hetero Type 2 sialidosis	Canafolia et al. [20], 2014	2014
2	sisters	Comp Hetero Type 1	Schene et al. [21], 2015	2015	2 sisters	Netherlands	Comp Hetero Type 1	Schene et al. [21], 2015	2015
1	East Asian	Comp Hetero Type 1 sialidosis	Mohammaf [22] et al., 2018	2018	1	East Asian	Comp Hetero Type 1 sialidosis	Mohammaf [22] et al., 2018	2018
7	North Indian	Homo All with type 2	This study		7	North Indian	Homo All with type 2	This study	

diagnosis of Sialidosis. Cherry red spot is the most common ocular finding that occurs as a result of storage in the ganglionic cells of the retina at the macula, where these cells are several layers thick. Cataract and nystagmus have also been reported [3]. A novel finding of bull's eye maculopathy (BEM) was present in patient 4, which has not previously been described. BEM is characterized by the presence of a central red spot surrounded by a ring of atrophic pigment epithelial mottling. This is caused by the destruction of macular rods and cones with sparing of the foveal cones. BEM has been described with many disorders, including inherited rod-cone dystrophies, Leigh's disease, cat eye syndrome and as a complication of treatment of mucopolysaccharidosis [12] [13] [14] [15]. Retinal pigmentary epithelium migrates into the areas of destructed photoreceptors, causing pigment laden cells to be detected in the outer nuclear and outer plexiform layers. Hydroxychloroquine retinopathy, which is the classical cause of bull's eye, is caused by the deposition of unmodified hydroxychloroquine salts within the retinal layers [16] [17]. We can extend the same theory to the accumulation of sialic acid in the retinal epithelium and subsequent loss of the photoreceptors, thus causing maculopathy. In our patient none of the disorders described to be associated with bull's eye maculopathy was present and we thus attribute the finding to the disease pathology.

5. Conclusion

we report seven new patients to form six families with sialidosis type II with a common homozygous pathogenic variant in NEU1 gene. Bull's eye maculopathy is a novel feature and expands the ophthalmologic spectrum of sialidosis. Existence of a common mutation in the north Indian population is proposed. This forms the basis for further studies including haplotype analysis and population studies.

Funding sources

This research project was supported by a research grant from the Indian Council of Medical Research (ICMR) (54/5/2008-BMS).

Acknowledgements

We would like to thank the patients and their families for agreeing to be a part of the research.

References

- [1] S. Franceschetti, L. Canafoglia, Sialidoses, *Epileptic Disord* 18 (S2) (2016 Sep 1) 89–93 Internet. cited 2019 Jul 3. Available from <http://www.ncbi.nlm.nih.gov/pubmed/27621198>.
- [2] E.J. Bonten, W.F. Arts, M. Beck, A. Covanis, M.A. Donati, R. Parini, et al., Novel mutations in lysosomal neuraminidase identify functional domains and determine clinical severity in sialidosis, *Hum. Mol. Genet.* 9 (18) (2000 Nov 1) 2715–2725 Internet. [cited 2019 Jul 3]. Available from: <https://academic.oup.com/hmg/article-lookup/doi/10.1093/hmg/9.18.2715>.
- [3] I. Sobral, M. da L. Cachulo, J. Figueira, R. Silva, Sialidosis type I: ophthalmological findings, *Case Rep.* 2014 (2014 Oct 16) Internet. cited 2019 Jul 3. bcr2014205871. Available from <http://www.ncbi.nlm.nih.gov/pubmed/25323282>.
- [4] A. Khan, C. Sergi, Sialidosis: a review of morphology and molecular biology of a rare pediatric disorder, *Diagnostics (Basel, Switzerland)* 8 (2) (2018 Apr 25) [Internet]. cited 2019 Jun 23. Available from <http://www.ncbi.nlm.nih.gov/pubmed/29693572>.
- [5] H. Venselaar, T.A. te Beek, R.K. Kuipers, M.L. Hekkelman, G. Vriend, Protein structure analysis of mutations causing inheritable diseases. An e-science approach with life scientist friendly interfaces, *BMC Bioinformatics* 11 (1) (2010 Dec 8) 548 Internet. cited 2019 Jul 7. Available from <https://bmcbioinformatics.biomedcentral.com/articles/10.1186/1471-2105-11-548>.
- [6] S. Richards, N. Aziz, S. Bale, D. Bick, S. Das, J. Gastier-Foster, et al., Standards and guidelines for the interpretation of sequence variants: a joint consensus recommendation of the American College of Medical Genetics and Genomics and the Association for Molecular Pathology, *Genet Med.* 17 (5) (2015 May) 405–424 Internet. cited 2019 Jun 16. Available from <http://www.ncbi.nlm.nih.gov/pubmed/25741868>.
- [7] K.E. Lukong, Characterization of the sialidase molecular defects in sialidosis patients suggests the structural organization of the lysosomal multienzyme complex,

- Hum. Mol. Genet. 9 (7) (2000 Apr) 1075–1085 Internet. 12 [cited 2019 Jun 23]. Available from: <https://academic.oup.com/hmg/article-lookup/doi/10.1093/hmg/9.7.1075>.
- [8] D.L. Rimoin, R.E. Pyeritz, B.R. Korf, Emery and Rimoin's essential medical genetics. 626 p, (2019).
- [9] G. Rodríguez Criado, A.V. Pshchetsky, A. Rodríguez Becerra, I. Gómez de Terreros, Clinical variability of type II sialidosis by C808T mutation, Am. J. Med Genet Part A 116A (4) (2003 Feb 1) 368–371 Internet. cited 2019 Jun 23. Available from <http://doi.wiley.com/10.1002/ajmg.a.10710>.
- [10] S.K. Bhoi, M. Jha, S. Naik, G.D. Palo, Sialidosis Type 1: giant SSEP and novel mutation, Indian J. Pediatr. 86 (8) (2019 Aug 2) 760–761 Internet. [cited 2019 Aug 5]. Available from <http://www.ncbi.nlm.nih.gov/pubmed/30941624>.
- [11] V.K. Gowda, V.M. Srinivasan, N. Benakappa, A. Benakappa, Sialidosis type 1 with a novel mutation in the neuraminidase-1 (NEU1) Gene, Indian J. Pediatr. 84 (5) (2017 May 31) 403–404 Internet. cited 2019 Aug 5. Available from <http://link.springer.com/10.1007/s12098-016-2286-9>.
- [12] F. Nasser, A. Kurtenbach, S. Kohl, C. Obermaier, K. Stingl, E. Zrenner, Retinal dystrophies with bull's-eye maculopathy along with negative ERGs, Doc. Ophthalmol. 139 (2019 Apr 3) 45–57 Internet. [cited 2019 Jul 3]; Available from <http://www.ncbi.nlm.nih.gov/pubmed/30945053>.
- [13] H.G. Mack, R.C.A. Symons, G. de Jong, Bull's eye maculopathy and subfoveal deposition in two mucopolysaccharidosis type I patients on long-term enzyme replacement therapy, Am J Ophthalmol Case Rep. 9 (2018 Mar) 1–6 Internet. cited 2019 Jul 3. Available from <http://www.ncbi.nlm.nih.gov/pubmed/29468207>.
- [14] H. Steffen, M. Blandfort, J. Müller-Navia, F.G. Holz, Bull's eye maculopathy in cat-eye syndrome, Retina 22 (2) (2002 Apr) 223–225 Internet. cited 2019 Jul 3. Available from <http://www.ncbi.nlm.nih.gov/pubmed/11927860>.
- [15] P.W. Laird, B.G. Mohny, D.L. Renaud, Bull's-eye maculopathy in an infant with Leigh disease, Am J. Ophthalmol. 142 (1) (2006 Jul) 186–187 Internet. cited 2019 Jul 3. Available from <http://www.ncbi.nlm.nih.gov/pubmed/16815282>.
- [16] Y.S. Modi, R.P. Singh, Bull's-eye maculopathy associated with hydroxychloroquine, N. Engl. J. Med. 380 (17) (2019 Apr 25) 1656 Internet. cited 2019 Jul 3. Available from <http://www.ncbi.nlm.nih.gov/pubmed/31018071>.
- [17] T.S. Oluleye, Y. Babalola, M. Ijaluola, Chloroquine retinopathy: pattern of presentation in Ibadan, sub-Sahara Africa, Eye 30 (1) (2016 Jan 2) 64–67 Internet. cited 2019 Jul 3. Available from <http://www.nature.com/articles/eye2015185>.
- [18] E. Bonten, A. van der Spoel, M. Fornerod, G. Grosveld, A. d'Azzo, Characterization of human lysosomal neuraminidase defines the molecular basis of the metabolic storage disorder sialidosis, Genes Dev. 10 (24) (1996 Dec 15) 3156–3169 Internet. cited 2019 Jun 23. Available from <http://www.genesdev.org/cgi/doi/10.1101/gad.10.24.3156>.
- [19] A. Caciotti, M. Rocco, M. Filocamo, S. Grossi, F. Traverso, A. d'Azzo, et al., Type II sialidosis: review of the clinical spectrum and identification of a new splicing defect with chitotriosidase assessment in two patients, J. Neurol. 256 (11) (2009 Nov 1) 1911–1915 Internet. cited 2019 Jun 23. Available from <http://link.springer.com/10.1007/s00415-009-5213-4>.
- [20] L. Canafoglia, A. Robbiano, D. Pareyson, F. Panzica, L. Nanetti, A.R. Giovagnoli, et al., Expanding sialidosis spectrum by genome-wide screening: NEU1 mutations in adult-onset myoclonus, Neurology 82 (22) (2014 Jun 3) 2003–2006 Internet. cited 2019 Jun 23. Available from <http://www.neurology.org/cgi/doi/10.1212/WNL.0000000000000482>.
- [21] I.F. Schene, V. Kalinina Ayuso, M. de Sain-van der Velden, K.L.I. van Gassen, I. Cuppen, P.M. van Hasselt, et al., Pitfalls in diagnosing neuraminidase deficiency: psychosomatics and normal sialic acid excretion, JIMD Rep 25 (2016) 9–13 [Internet]. cited 2019 Jul 4. Available from <http://www.ncbi.nlm.nih.gov/pubmed/26141460>.
- [22] T. Gambin, Z.C. Akdemir, B. Yuan, S. Gu, T. Chiang, C.M.B. Carvalho, et al., Homozygous and hemizygous CNV detection from exome sequencing data in a Mendelian disease cohort, Nucleic Acids Res. 45 (4) (2017) 1633–1648 Internet. cited 2019 Jun 6. Available from <http://www.ncbi.nlm.nih.gov/pubmed/27980096>.