

Treatment protocol based on assessment of clot quality during endovascular thrombectomy for acute ischemic stroke using the Trevo stent retriever

Kojiro Ishikawa, Tomotaka Ohshima, Masahiro Nishihori, Tasuku Imai, Shunsaku Goto, Taiki Yamamoto, Toshihisa Nishizawa, Shinji Shimato and Kyoza Kato

Department of Neurosurgery, Kariya Toyota General Hospital, Kariya, Japan

ABSTRACT

The optional endovascular approach for acute ischemic stroke is unclear. The Trevo stent retriever can be used as first-line treatment for fast mechanical recanalization. The authors developed a treatment protocol for acute ischemic stroke based on the assessment of clot quality during clot removal with the Trevo. This prospective single-center study included all patients admitted for acute ischemic stroke between July 2014 and February 2015, who underwent emergency endovascular treatment. According to the protocol, the Trevo was used for first-line treatment. Immediately after the Trevo was deployed, the stent delivery wire was pushed to open the stent by force (ACAPT technique). Clot quality was assessed on the basis of the perfusion status after deployment of the Trevo; continued occlusion or immediate reopening either reoccluded or maintained after the stent retriever had been in place for 5 min. If there was no obvious clot removal after the first pass with the Trevo, according to the quality of the clot, either a second pass was performed or another endovascular device was selected. Twelve consecutive patients with acute major cerebral artery occlusion were analyzed. Thrombolysis in cerebral infarction score 2b and 3 was achieved in 11 patients (91.7%) and 9 (75%) had a good clinical outcome after 90 days based on a modified Rankin scale score ≤ 2 . Symptomatic intracranial hemorrhage occurred in 1 patient (8.3%). The overall mortality rate was 8.3%. Endovascular thrombectomy using the Trevo stent retriever for first-line treatment is feasible and effective.

Key Words: acute ischemic stroke; endovascular clot retrieval; thrombus

This is an Open Access article distributed under the Creative Commons Attribution-NonCommercial-NoDerivatives 4.0 International License. To view the details of this license, please visit (<http://creativecommons.org/licenses/by-nc-nd/4.0/>).

INTRODUCTION

Fast recanalization is the most effective treatment for acute ischemic stroke due to major cerebral artery occlusion.¹⁾ Although intravenous thrombolysis (IVT) with recombinant tissue plasminogen activator (rt-PA) is the first-line treatment for acute ischemic stroke, isolated IVT often fails.²⁾ Endovascular approaches for acute ischemic stroke continue to evolve. Mechanical thrombectomy using stent retrieval devices result in immediate restoration of cerebral blood flow. This approach is associated with faster and higher rates of recanalization compared with previous devices.³⁻⁵⁾ However, the optimal selection and sequence of endovascular devices or other methods

Received: March 2, 2016; accepted: May 2, 2016

Corresponding author: Tomotaka Ohshima, MD

Department of Neurosurgery, Kariya Toyota General Hospital, 5-15 Sumiyoshi-cho, Kariya 448-8505, Japan

Phone: +81-566-21-2450, Fax: +81-566-22-2493, E-mail address: tomotaka.oshima@toyota-kai.or.jp

to treat patients with acute stroke is unclear. We report our treatment protocol and experience with the Trevo stent retriever for first-line treatment of acute ischemic stroke. The protocol enables the operator to assess the clot quality during the procedure and determine the next treatment step when no obvious clot removal is achieved after a first pass with the Trevo stent retriever.

METHODS

Patients

This prospective single-center study included 12 consecutive patients admitted to our hospital for acute ischemic stroke between July 2014 and February 2015, who underwent emergency endovascular treatment. All patients were physically examined and a medical history was obtained. A National Institutes of Health Stroke Scale (NIHSS) score was assigned for each patient.⁶⁾ When indicated, patients were treated using IVT with rt-PA (0.6 mg/kg; recommended dose in Japan) before the endovascular procedure. If patients improved after the infusion, no further intervention was offered and the patient was managed medically. Patients with basilar, carotid, or middle cerebral artery (MCA) occlusions and a large mismatch with a core infarct depicted on magnetic resonance imaging (MRI) were offered endovascular treatment. Informed consent was obtained from all patients or their representative. Our local ethics committee approved the study protocol.

Endovascular Procedure

All endovascular treatments were performed under local anesthesia. Access was achieved using a percutaneous transfemoral technique. In cases of anterior circulation stroke, 8 French guiding catheters with a balloon (Optimo; Tokai Medical Products, Aichi, Japan) were placed in the cervical internal carotid artery (ICA), and 4 French intermediate catheters (Fubuki; Asahi Intecc, Aichi, Japan) were coaxially advanced proximal to the clot. In cases of posterior circulation stroke, 6 French guiding catheters were advanced in the vertebral artery. After controlled angiography, a Trevo 18 microcatheter (Stryker, Kalamazoo, Michigan, USA) was navigated distal to the thrombus with a Chikai 14 microguidewire (Asahi Intecc). A selective angiogram was obtained distal to the clot to evaluate the distal vasculature and to verify the correct position of the microcatheter. The Trevo stent retriever (Stryker) was advanced through the microcatheter distal to the clot and deployed. An angiogram was performed to evaluate the correct deployment and expansion of the stent. Immediately after the deployment of the Trevo stent retriever, the stent delivery wire was pushed to open the stent by force. The appropriate degree of the pushing wire was confirmed when the proximal marker on the stent was distally shifted at the distance indicated by 2 markers. We named this technique Aggressive Capture for fast reperfusion by Trevo (ACAPT; Fig. 1). The method of pushing by 2 marker based on the *in vitro* experience (Fig. 2). A summary of the treatment protocol and strategy is shown in Figure 3. The clot quality was assessed after deployment of the Trevo stent retriever on the basis of continued occlusion or reopening either maintained or reoccluded after the stent retriever had been in place for 5 min. If no obvious clot removal was achieved after one pass, another endovascular device was selected according to the quality of the clot. Softer clots are easier to retrieve. For super hard clots or clots associated with existing atheromatous stenosis, percutaneous transluminal angioplasty (PTA) was selected rather than another endovascular procedure. Remaining or dropped clots were retrieved with repeated use of the Trevo stent retriever or with the Penumbra system (Penumbra Inc, Alameda, California, USA) because the clots had already been detached from the wall of the vessels.

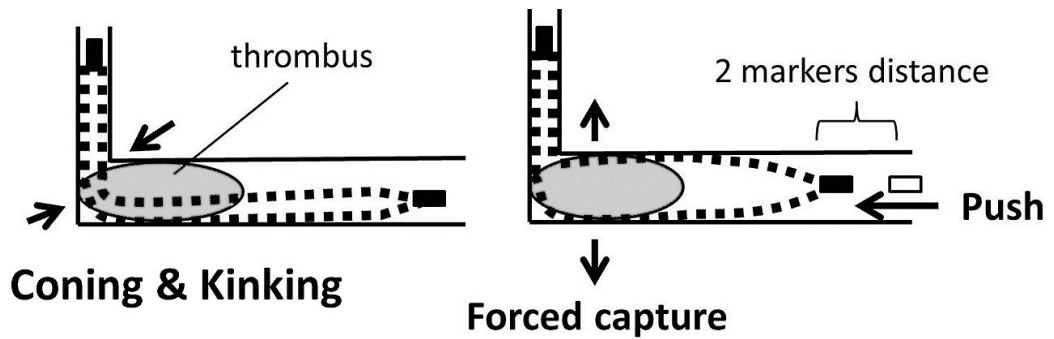


Fig. 1 Schema showing the Aggressive CAPture for fast rePerfusion by Trevo (ACAPT) technique for a thrombus in an artery with a right-angle bend. When the proximal stent marker is distally shifted by a distance of 2 markers, kinking or coning of the stent is overcome and the stent is opened by force.

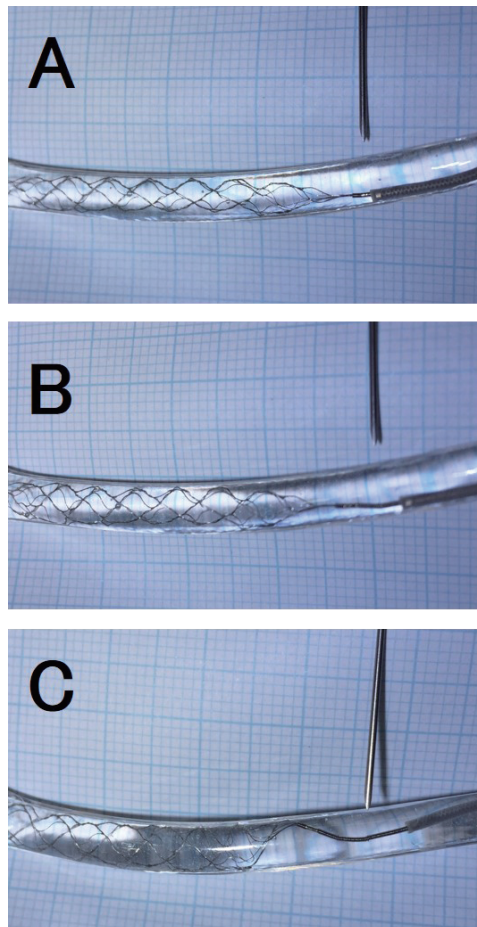


Fig. 2 Photographs of in vitro study showing. A vessel model is made by silicone with 3-mm in diameter. (A) Just after deployment of the Trevo stent. (B) After pushing by a distance of 2 markers, whole stent is markedly dilated against the vessel model. (C) After pushing by a distance of 4 markers, the proximal of the stent is bent.

Table 1 Summary of cases treated with a Trevo

	age sex	location	Af	NIHSS	pre GCS	iv rt-PA	device	P to R time (minutes)	TICI	complication	Day1 GCS	Day90 mRS
Case 1	75/M	M1 distal	(-)	18	4, 2, 6	(+)	T	30	3	none	4, 5, 6	0
Case 2	73/F	BA trunk	(+)	31	1, 1, 4	(+)	T	60	2B	none	1, 1, 2	6
Case 3	58/M	M1 proximal	(-)	19	4, 1, 6	(+)	T, G	110	2B	none	4, 3, 6	2
Case 4	72/M	M1 proximal	(-)	16	4, 4, 6	(-)	T	50	3	minor SAH	4, 5, 6	0
Case 5	76/M	M1 distal	(+)	11	3, 4, 6	(+)	T, G	45	2B	none	4, 4, 6	1
Case 6	79/F	M1 distal	(+)	15	4, 3, 6	(+)	T	40	2B	none	4, 5, 6	1
Case 7	77/F	M1 proximal	(-)	20	4, 2, 6	(-)	T, P	60	2B	minor SAH	4, 2, 5	2
Case 8	65/M	M1 proximal	(+)	30	4, 1, 3	(+)	T, P	90	2B	major SAH	2, 1, 5	4
Case 9	77/M	M1 proximal	(+)	19	4, 3, 6	(-)	T	35	3	none	4, 5, 6	0
Case 10	85/F	M1 proximal	(+)	27	2, 1, 1	(+)	T, P	45	2B	none	4, 1, 5	2
Case 11	70/F	ICA terminal	(-)	4	4, 4, 6	(-)	T	50	3	none	4, 5, 6	1
Case 12	79/F	M1 proximal	(+)	15	4, 4, 6	(+)	T	70	2A	minor SAH	3, 4, 6	3

BA, basilar artery; G, Gateway; GCS, Glasgow Coma Scale; ICA, internal carotid artery; iv, intravenous; M1, middle cerebral artery; mRS, modified Rankin Scale; NIHSS, National Institutes of Health Stroke Scale; P, Penumbra; P to R, puncture to recanalization; rt-PA, recombinant tissue plasminogen activator; T, Trevo; TICI, thrombolysis in cerebral infarction score

Outcome Measures

Successful recanalization was defined to be a thrombolysis in cerebral infarction (TICI) score of 2b to 3. Good long-term clinical outcome was defined to be a modified Rankin Scale (mRS) score ≤ 2 at 90 days.

RESULTS

Twelve consecutive patients admitted to our hospital with acute major cerebral artery occlusion between July 2014 and February 2015 were treated with the Trevo stent retriever. Details of the patient characteristics and outcomes are summarized in Table 1. Successful recanalization was achieved in 11 patients (91.7%), and 9 patients (75%) had a good clinical outcome on assessment 90 days after the procedure. Total intracranial hemorrhage occurred in 4 patients, although in 3 of those patients the hemorrhage was asymptomatic subtle extravasation. One patient died; this resulted in an overall mortality rate of 8.3%.

REPRESENTATIVE CASES

Case 5

A 76-year-old man was admitted to our emergency department 2.5 h after onset of acute right-sided hemiparesis and slurred speech. His NIHSS score at admission was 11. Diffusion MRI revealed a minor acute infarction in the left cerebral hemisphere. A magnetic resonance angiogram showed left MCA occlusion. Immediate IVT with rt-PA was initiated; however, it was not successful. An emergency cranial angiogram showed persistent left MCA occlusion (Fig. 4A). According to our protocol (Fig. 3), rescue endovascular treatment was scheduled. A Trevo stent retriever was deployed from the M2 segment of MCA to the terminal of ICA (Fig. 4B) and ACAPT technique was performed. Temporary recanalization was not achieved and partial recanalization was observed after stent retrieval (Fig. 4C). Based on this outcome, the clot

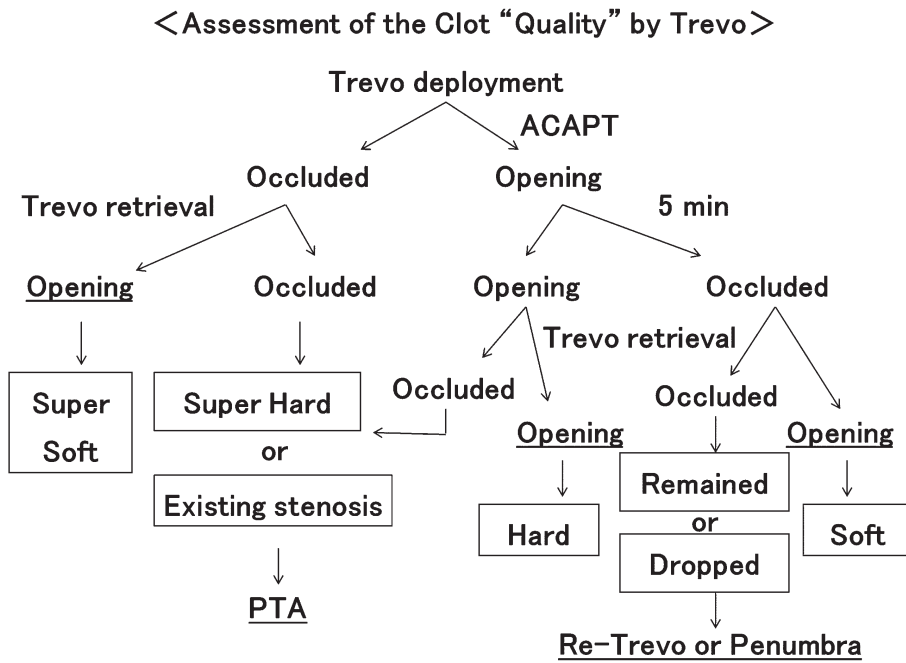


Fig. 3 A flow chart demonstrating the protocol based on evaluation of clot quality. ACAPT = Aggressive CAPture for fast rePerfusion by Trevo technique; PTA = percutaneous transluminal angioplasty.

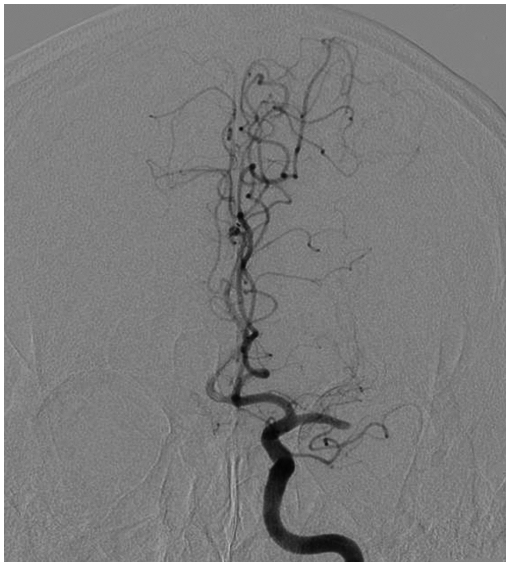

Fig. 4 (A)

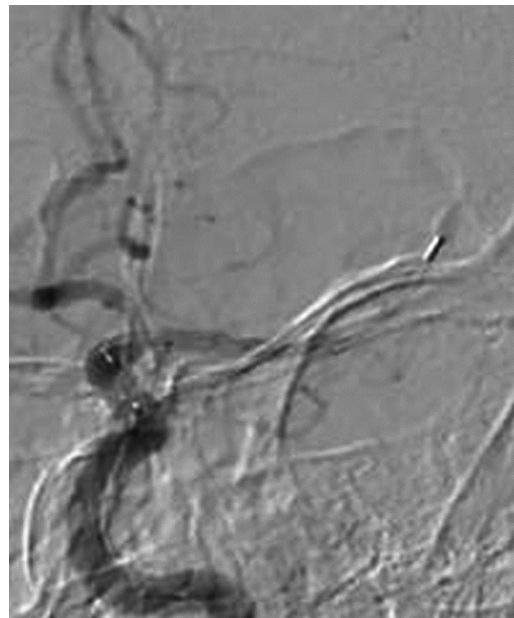


Fig. 4 (B)

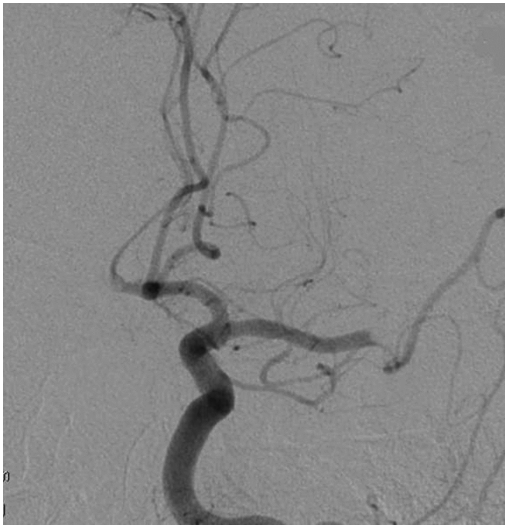
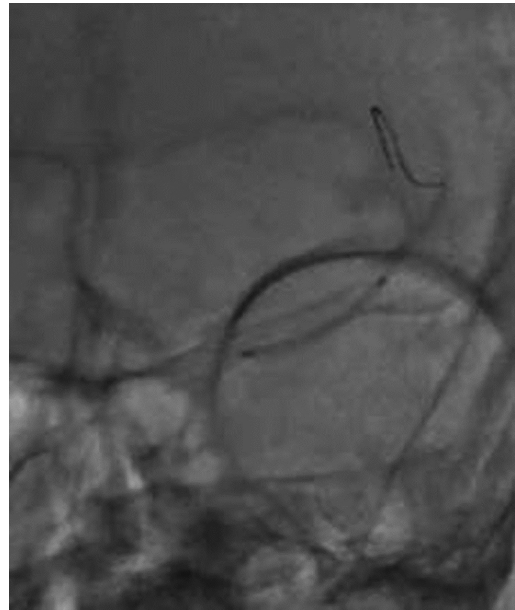
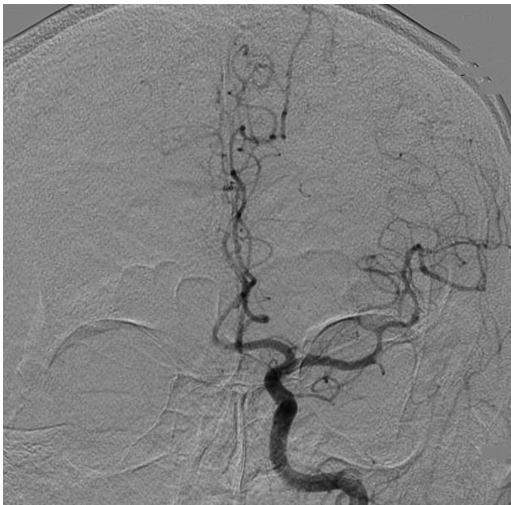**Fig. 4 (C)****Fig. 4 (D)****Fig. 4 (E)**

Fig. 4 (A) Diagnostic cerebral angiography shows a complete occlusion of the left middle cerebral artery. (B) The Trevo stent retriever is deployed; however, angiography shows no temporary recanalization. (C) After retrieval of the Trevo stent retriever angiography shows partial recanalization. (D) Angioplasty with a Gateway Monorail 2.0 × 20 mm dilatation balloon catheter is performed. (E) Post-procedure angiography shows successful recanalization of the left middle cerebral artery.

was assessed to be super hard, and PTA was selected to be the follow-up procedure. After the angioplasty using a Gateway Monorail 2.0 × 20 mm dilatation balloon catheter (Stryker), the main trunk of the left MCA was reopened (Fig. 4D and E). The total time between femoral access and arterial recanalization was 45 min. The patient's hemiparesis dramatically improved after the procedure. The NIHSS score improved to 3 points at discharge and the mRS score was 1 on follow-up examination 90 days after the procedure.

Case 10

An 85-year-old woman was transferred to our emergency department 3.0 h after the onset of acute right-sided hemiplegia and global aphasia. Her NIHSS score on admission was 27. A computed tomography (CT) scan showed hyperdensity of the left MCA without associated ischemic changes. IVT with rt-PA was performed; however, there was no change in the neurological score at the end of the infusion. MR imaging was contraindicated because she had an implanted pacemaker. Therefore, we performed endovascular treatment. Emergency cranial angiogram revealed left MCA occlusion (Fig. 5A). According to our protocol, a Trevo stent retriever was deployed from the M2 segment of MCA to the terminal of ICA and ACAPT technique was performed. Temporary recanalization was observed (Fig. 5B). After the Trevo stent retriever was maintained in place for 5 min, a repeat angiogram revealed re-occlusion with stent expansion and clot integration (Fig. 5C). Then, the Trevo stent retriever was retrieved under flow arrest. However, follow-up angiogram showed no evidence of recanalization (Fig. 5D). According to our protocol (Fig. 3), these findings suggested remaining or dropped clot. Because the clot had already been detached from the wall of the vessel, they could be easily aspirated with the Penumbra system, and recanalization was achieved after aspiration with the Penumbra 4 Max (Fig. 5E). The total

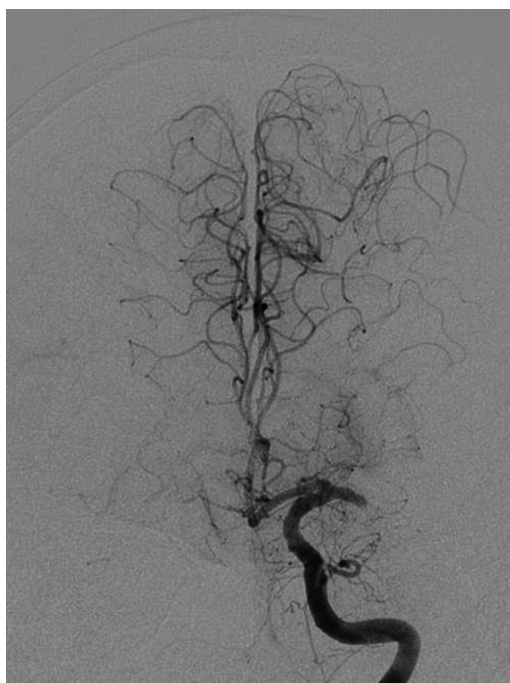


Fig. 5 (A)

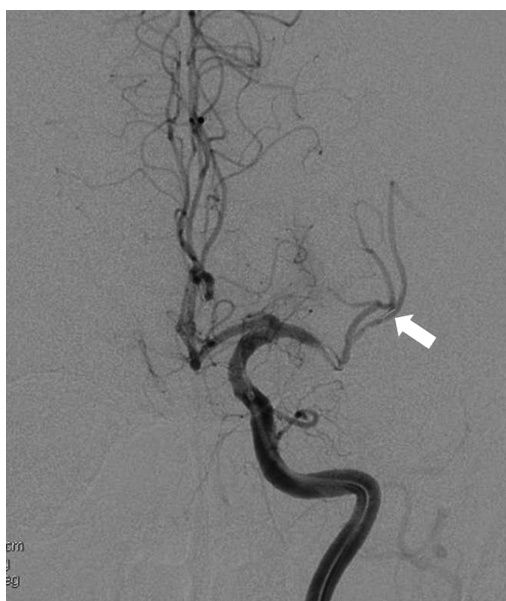

Fig. 5 (B)

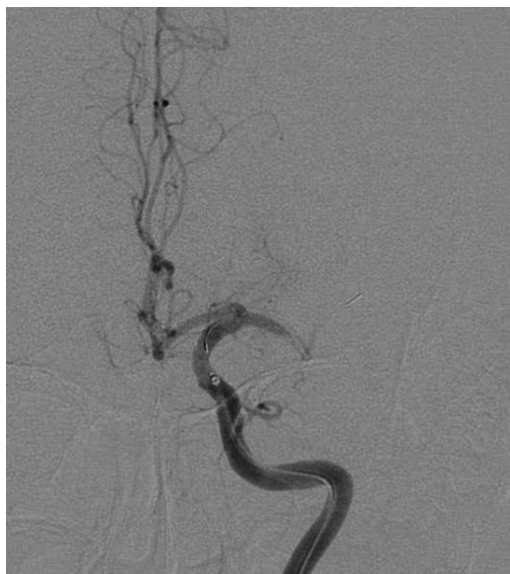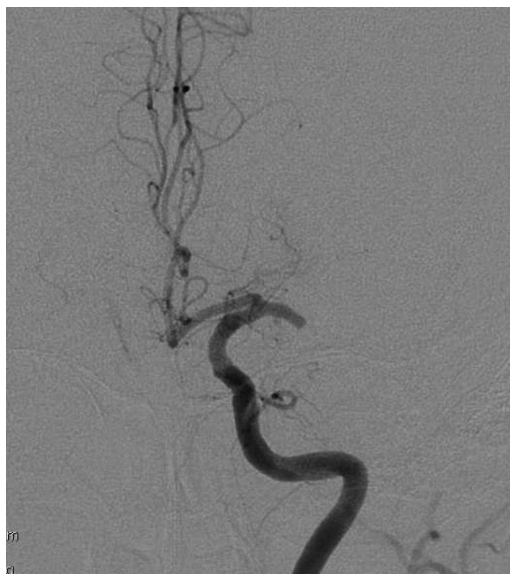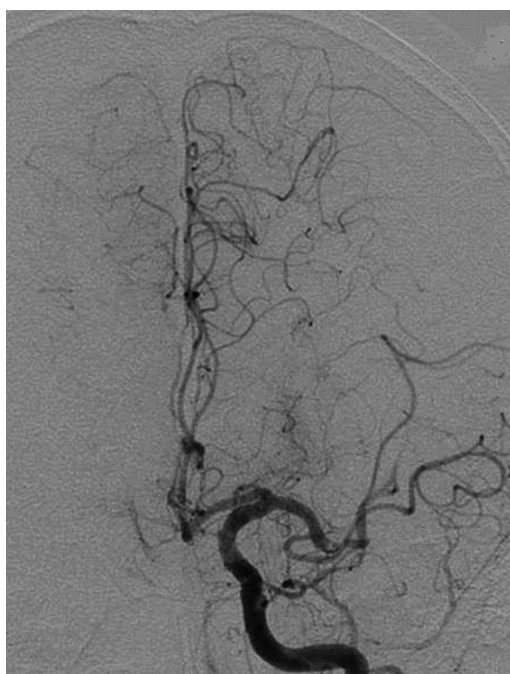
**Fig. 5 (C)****Fig. 5 (D)****Fig. 5 (E)**

Fig. 5 (A) Initial cerebral angiography shows a complete occlusion of the left middle cerebral artery. (B) The Trevo stent retriever is deployed and angiography shows temporary recanalization. Arrow indicates the distal tip of the Trevo stent retriever. (C) Five min after deployment of the Trevo stent retriever angiography shows re-occlusion as expected. (D) After retrieval of the Trevo stent retriever angiography shows unexpected re-occlusion. (E) After clot aspiration with the Penumbra system angiography shows successful recanalization of the left middle cerebral artery.

time between femoral access and permanent recanalization was 45 min. The patient's symptoms improved after the procedure. The NIHSS score improved to 10 points at discharge and the mRS score was 2 on follow-up examination 90 days after the procedure.

DISCUSSION

Fast recanalization is the most effective treatment for acute ischemic stroke secondary to major cerebral artery occlusion.¹⁾ IVT with rt-PA is the first-line treatment for acute ischemic stroke; however, major artery occlusions are successfully reopened by isolated IVT in less than half of all cases.²⁾ Therefore, endovascular approaches for acute ischemic stroke have been developed. The use of stent retrieval devices for mechanical thrombectomy rapidly restores cerebral blood flow and results in fast and high rates of recanalization compared with previous devices.³⁻⁵⁾ However, the appropriate selection and sequence of endovascular devices or other treatment for patients with acute stroke is unclear. We report our treatment protocol and experience with the Trevo stent retriever as a first-line treatment for acute ischemic stroke.

Saving Time

Immediately after deployment of the Trevo stent retriever, the stent delivery wire is pushed to open the stent as quickly as possible. This ACAPT technique (Fig. 1) potentially saves time in terms of establishing reperfusion. A clot usually lodges at bends and narrow points of an artery. Closed-cell stents such as the Trevo stent retriever may be kinked or bent at these points. We suggest that a tight stent can be forced to expand by pushing the delivery wire. The desired extent of the pushing process is established by distally shifting the proximal stent marker at a distance of 2 markers. This degree of force will retain the distal marker of the Trevo stent retriever and, based on in vitro tests, will not crush the device. This technique cannot be performed with the Solitaire FR revascularization device (ev3 Inc, Irvin, CA, USA) because of insufficient strength around the junction.⁷⁾ If temporary reopening achieved after the initial Trevo stent retriever deployment, definitive brain rescue can be achieved in a less hurried manner.

Quality of the Clot

Evaluation of the quality of the clot is very important for strategies to treat ischemic stroke. To date, clot quality was assessed on the basis of the degree of hardness detected by a microguidewire while passing into the clot. More definite assessment of clot quality is possible using the Trevo stent retriever. The perfusion status immediately after deployment of the Trevo stent retriever and after the device has been in place for 5min can be used to assess the quality of the clot. This information is helpful to select the next device or treatment method if the first pass with the Trevo stent retriever is not successful. Super hard clots and clots associated with existing atheromatous stenosis are difficult to recanalize, despite the repeated use of the Trevo stent retriever. In such cases immediate follow-up management with a method such as PTA is necessary for fast recanalization. However, remaining or dropped clots can be retrieved with repeat use of the Trevo stent retriever or the Penumbra system, because the clots have already been detached from the blood vessel walls. Our protocol helps to select the appropriate treatment tailored to each emergency situation.

Current Trials

A recent multicenter, prospective, randomized trial of 196 patients found that the Trevo stent retriever was effective and safe.⁸⁾ The recanalization rate (TICI score 2b and 3) was 58.7%, and

good long-term clinical outcome (mRS score 0–2) was achieved in 32.6% of patients. Although the current series of 12 patients was very small to evaluate statistically, the recanalization rate of 91.7% and good long-term clinical outcome in 75% of patients were acceptable. Post procedural subarachnoid hemorrhage occurred in 4 patients (33.3%) and was symptomatic only in 1 case (8.3%). A similar rate of intracranial hemorrhage was reported in a recently published trial of the Trevo stent retriever 32% of 50 cases.⁹⁾ In a trial of the Solitaire FR revascularization device 15% of 101 patients developed symptomatic intracranial hemorrhage.¹⁰⁾ The recanalization rate and clinical outcome based on mRS scores in the current study support the effectiveness of our protocol using the Trevo stent retriever for first-line treatment of acute ischemic stroke.

Limitations

The limitations of this study are the small sample size and single-center clinical setting. The recanalization rate and clinical outcome were good and compared well with large-scale studies; however, we did not have sufficient statistical power to determine whether our protocol truly influenced the outcome. Despite these limitations, we think that this series represents a significant contribution to clinical information on acute stroke intervention.

In this series, there was no case of far distal embolism, for example, the M2 or M3 division of MCA. Because procedure-related subarachnoid hemorrhage occurred in 4 patients in our M1 occlusion cases, distal MCA occlusion cases should be excluded, with the Trevo stent retriever as the first-line.

CONCLUSION

Endovascular thrombectomy using the Trevo stent retriever for first-line treatment of acute ischemic stroke is feasible and effective. The ACAPT technique and assessment of the quality of clot potentially decrease the delay between the start of the procedure and successful reperfusion. Large-scale, multicenter trials are necessary for further evaluation.

ACKNOWLEDGEMENTS

The authors have no personal financial or institutional interest in any of the drugs, materials, or devices in the article.

REFERENCES

- 1) Rha JH, Saver JL. The impact of recanalization on ischemic stroke outcome: a meta-analysis. *Stroke*, 2007; 38: 967–973.
- 2) Riedal CH, Zimmermann P, Jensen-Kondering U, Stingele R, Deuschl G, Jansen O. The importance of size: successful recanalization by intravenous thrombolysis in acute anterior stroke depends on thrombus length. *Stroke*, 2011; 42: 1775–1777.
- 3) Nogueira RG, Lutsep HL, Gupta R, Jovin TG, Albers GW, Walker GA, *et al.* Trevo versus Merci retrievers for thrombectomy revascularization of large vessel occlusions in acute ischemic stroke (TREVO 2): a randomized trial. *Lancet*, 2012; 380: 1231–1240.
- 4) Serrone JC, Jimenez L, Ringer AJ. The role of endovascular therapy in the treatment of acute ischemic stroke. *Neurosurgery*, 2014; 74: 133–141.
- 5) Binning MJ, Adel JG, Maxwell CR, Liebman K, Hakma Z, Diaz C, *et al.* Early postmarket experience after US Food and Drug Administration approval with the Trevo device for thrombectomy for acute ischemic stroke. *Neurosurgery*, 2014; 75: 584–589.

Assessment of clot quality using Trevo

- 6) Bruno A, Saha C, Williams LS. Using change in the National Institutes of Health Stroke Scale to measure treatment effect in acute stroke trials. *Stroke*, 2006; 37: 920–921.
- 7) Kwon HJ, Chueh JY, Puri AS, Koh HS. Early detachment of the Solitaire stent during thrombectomy retrieval: an in vitro investigation. *J Neurointerv Surg*, 2015; 7: 114–117.
- 8) Berkhemer OA, Fransen PS, Beumer D, van den Berg LA, Lingsma HF, Yoo AJ, *et al*. A randomized trial of intraarterial treatment for acute ischemic stroke. *N Eng J Med*, 2015; 372: 11–20.
- 9) Broussalis E, Trinka E, Wallner A, Hitzl W, Killer M. Thrombectomy in patients with large cerebral artery occlusion: a single-center experience with a new stent retriever. *Vasc Endovascular Surg*, 2014; 48: 144–152.
- 10) Mokin M, Dumont TM, Veznedaroglu E, Binning MJ, Liebman KM, Fessler RD 2nd, *et al*. Solitaire flow restoration thrombectomy for acute ischemic stroke: retrospective multicenter analysis of early postmarket experience after FDA approval. *Neurosurgery*, 2013; 73: 19–26.