

Available online at www.sciencedirect.com

journal homepage: www.elsevier.com/locate/radcr

Case Report

Primary bilateral ovarian artery embolization for uterine leiomyomatosis in the setting of a rare anatomic variant - hypoplastic uterine arteries [☆]

Merve Ozen, MD^{a,*}, Shezaan Momin, MD^b, Charles Ben Myers, DO^a, Mark Hoffman, MD^c, Driss Raissi, MD^a

^a Department of Radiology, University of Kentucky College of Medicine, 800 Rose Street, Room HX-318, Lexington, KY

^b Paul L. Foster School of Medicine, Texas Tech University Health Sciences Center, 5001 El Paso Drive, El Paso, TX

^c Department of Obstetrics & Gynecology, University of Kentucky College of Medicine, 125 E Maxwell St Suite 140, Lexington, KY

ARTICLE INFO

Article history:

Received 19 May 2021

Revised 26 May 2021

Accepted 28 May 2021

Keywords:

Fibroid

UFE

Embolization

ABSTRACT

We present the case of a 50-year-old female who underwent bilateral ovarian artery embolization for uterine fibroids in the setting of hypoplastic uterine arteries. Ovarian artery embolization is usually conducted during uterine artery embolization for fibroids to increase the procedure success when ovarian feeders are seen. The bilateral ovarian artery embolization is rarely performed due to fears of amenorrhea and early menopause from decreased blood supply to both ovaries. According to our knowledge, this the first case report describing primary bilateral ovarian artery embolization in the setting of a rare anatomic variant-hypoplastic uterine arteries. The patient had complete resolution of symptoms from her uterine fibroids after treatment with bilateral ovarian artery embolization with no ovarian failure findings on the follow-up.

© 2021 The Authors. Published by Elsevier Inc. on behalf of University of Washington.

This is an open access article under the CC BY-NC-ND license

(<http://creativecommons.org/licenses/by-nc-nd/4.0/>)

Introduction

Uterine artery embolization is an established therapy for the management of symptomatic uterine fibroids. While the procedure reduces total leiomyoma volume and decreases or eliminates clinical symptoms, the procedure's failure rate stands at 9.4% [[1]]. One cause of treatment failure is persistent

blood supply to the fibroid from utero-ovarian anastomosis branches. Although various studies have described successful unilateral ovarian artery embolization for the treatment of symptomatic uterine fibroids, to the best of our knowledge, primary bilateral ovarian artery embolization (BOAE) in the setting of hypoplastic uterine arteries has not been described in the literature. In this report, we aim to illustrate the technical feasibility and outcome of a patient with the rare variant of hypoplastic uterine arteries treated with BOAE and for

[☆] The Institutional Review Board approval number: Case reports are exempt from institutional review board approval at the originating institution.

* Corresponding author.

E-mail address: merve.ozen@uky.edu (M. Ozen).

<https://doi.org/10.1016/j.radcr.2021.05.069>

1930-0433/© 2021 The Authors. Published by Elsevier Inc. on behalf of University of Washington. This is an open access article under the CC BY-NC-ND license (<http://creativecommons.org/licenses/by-nc-nd/4.0/>)

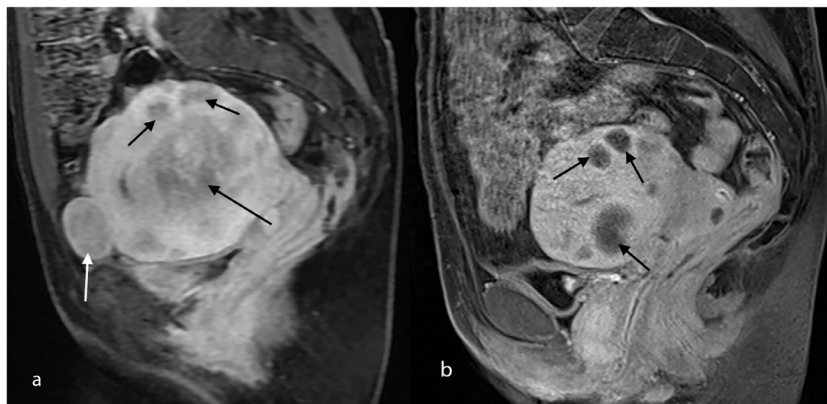

Fig. 1 – (A) Pre-embolization sagittal T1 weighted (W) Fat-Saturated (FS) post-contrast image through the pelvis demonstrates numerous intramural (black arrows) and subserosal (white arrow) enhancing fibroids. (B) Post-embolization sagittal T1-W FS post-contrast image through the pelvis demonstrates multiple intramural non-enhancing treated fibroids (black arrows).

symptomatic uterine fibroids. Case reports are exempt from institutional review board approval at the originating institution.

Case report

A 50-year-old woman with a 16-year history of menorrhagia, dysmenorrhea, and anemia secondary to uterine fibroids presented to our multidisciplinary fibroid clinic. Upon evaluating clinical and MRI (magnetic resonance imaging) findings (Fig. 1A), we discussed medical, interventional, and surgical options with the patient and the gynecologist, and a decision was made to perform uterine fibroid embolization (UFE). Informed consent was obtained for the procedure. Initial pelvic aortogram demonstrated bilateral hypertrophic ovarian arteries feeding the enlarged fibromatous uterus. Bilateral uterine arteries were diminutive on the angiogram. (Fig. 2). Endovascular embolization of both ovarian arteries was performed with 500 to 700 microns and 700 to 900 microns of Embosphere microspheres (Merit Medical Systems, Inc, South Jordan, Utah) using a 2.4-French Progreat microcatheter (Terumo Medical Corporation, Somerset, New Jersey) through a 4-French (F) Mickelson catheter (Cook, Inc, Bloomington, Indiana) until near stasis.

At the six-week clinic follow-up, no early complications were observed, and the patient was satisfied with the procedure. MRI was obtained as part of the six-month follow-up, which showed decreased uterine and fibroids size with no residual fibroid enhancement (Fig. 1B). During the six-month clinic visit, she reported having regular periods for three cycles with no pelvic pain and heavy bleeding. She denied ovarian failure symptoms. On the MRI, both ovaries revealed no evidence of infarction. The pre-procedure hemoglobin level of 4.5 g/dL increased to 11.9 g/dL. At 9-months, she decided to have a hysterectomy due to a fibroid expulsion and desire not to have menstruations anymore. The gynecologist performed total laparoscopic hysterectomy and salpingo-oophorectomy. Histopathologic assessment of the post-surgical specimen

demonstrated embolization material within blood vessels adjacent to a leiomyoma with ischemic-type necrosis consistent with embolization (Fig. 3).

Discussion

Bilateral OAE is rarely discussed in the literature to treat uterine fibroids with collateral supply from the ovarian artery. One fear clinicians have in performing bilateral OAE is ovarian failure resulting from infarction. There is also conflicting literature with Razavi et al., concluding that ovarian artery embolization should only be performed unilaterally [2]. On the contrary, a case series by Barth et al. noted that three patients treated with bilateral OAE in addition to uterine artery embolization retained ovarian function after the procedure [3]. In this report, bilateral OAE did not cause early menopause after the procedure while still achieving complete clinical success.

There are two case reports in the literature describing bilateral hypoplastic/absent uterine artery variant which was found during uterine artery embolization attempt. In these cases, embolization was not performed due to fear of causing early menopause. In our case, we decided to perform the embolization despite the rare variant anatomy due to patient long history of anemia and initial decision to avoid hysterectomy [4].

From a technical standpoint, 500 to 700 microns and 700 to 900 microns Embospheres proved to be adequate in achieving near stasis of blood flow during bilateral ovarian artery embolization. It was further confirmed after histologic staining, which showed embolization material within one of the fibroids. Despite embolic material seen in the ovary on histology (Fig. 3B), the patient did not exhibit any ovarian failure symptoms after the procedure. MRI and histopathology findings supported that both ovaries were still viable. One may deduce from this report that the same-sized Embospheres typically used for uterine artery embolizations can also be used in bilateral ovarian artery embolizations. However, Verret et al. reported that either 700 or 900-micron Embosphere (CeloNova

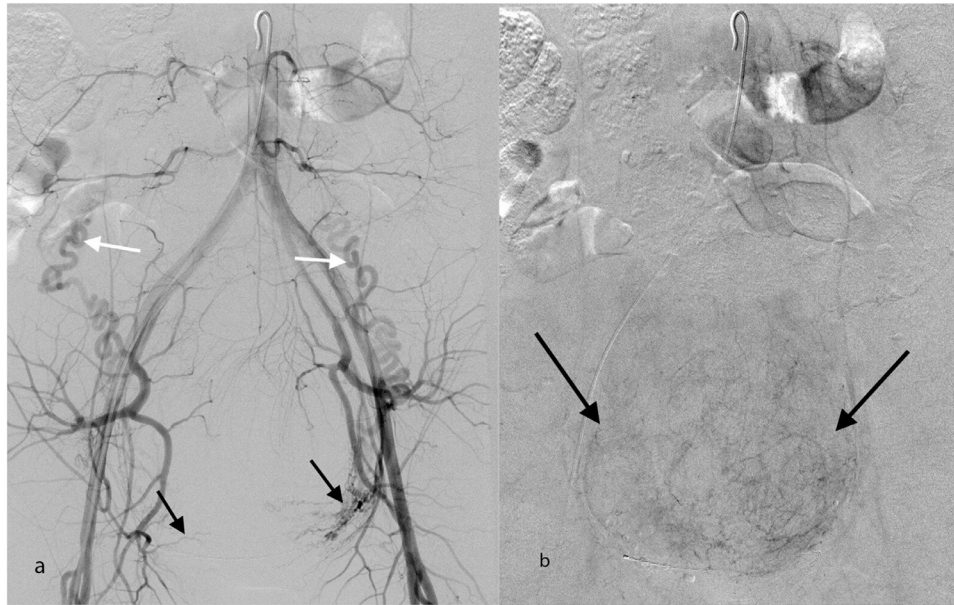


Fig. 2 – (A) Digital subtraction aortogram demonstrates enlarged tortuous ovarian arteries (white arrows) and hypoplastic uterine arteries (black arrows). (B) Delayed phase image from digital subtraction aortogram shows opacification of the fibromatous uterus (black arrows).

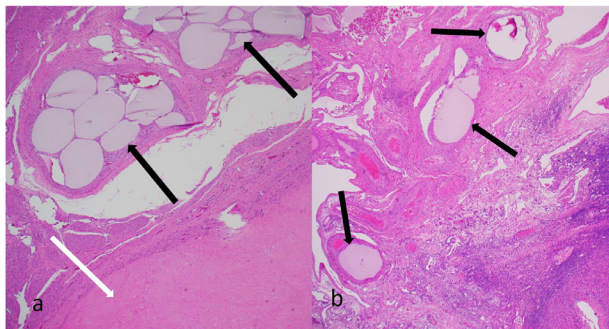


Fig. 3 – (A) Histopathologic images of the embolized uterine fibroid. Original magnification $\times 4$. Hematoxylin and eosin. Embolization material (black arrows) within the arteries adjacent to a leiomyoma with ischemic-type necrosis (white arrow). (B) Original magnification $\times 4$. Hematoxylin and eosin. Embolization material (arrows) within the hilum of the ovary.

Biosciences, Newnan, Georgia) occluded significantly more distally than 700 to 900 micron Embospheres in sheep models. However, this report indicates that 700 to 900 micron Embospheres can adequately embolize the distal blood flow to the fibromatous uterus without compromising ovarian function [5].

In conclusion, fibromatous uterus with bilateral primary blood supply from the ovarian arteries can be considered

for bilateral ovarian artery embolization in selected patients. Long term follow-up will be needed to establish long term safety.

Declaration of Competing Interest

None.

REFERENCES

- [1] Huang JY, Kafy S, Dugas A, Valenti D, Tulandi T, et al. Failure of uterine fibroid embolization. *Fertil Steril* 2006;85(1):30–5.
- [2] Razavi MK, Wolanske KA, Hwang GL, Sze DY, Kee ST, Dake MD. Angiographic classification of ovarian artery-to-uterine artery anastomoses: initial observations in uterine fibroid embolization. *Radiology* 2002;224:707–12.
- [3] Barth MM, Spies JB. Ovarian artery embolization supplementing uterine embolization for leiomyomata. *J Vasc Interv Radiol* 2003;14:1177–82.
- [4] Liapis K, Tasis N, Tsouknidas I, Tsakotos G, Skandalakis P, Vlasik K, Filippou D. Anatomic variations of the Uterine Artery. Review of the literature and their clinical significance. *Turk J Obstet Gynecol* 2020;17(1):58–62. doi:10.4274/tjod.galenos.2020.33427.
- [5] Verret V, Ghegediban SH, Wassef M, Pelage JP, Golzarian J, Laurent A. The Arterial distribution of embosphere microspheres in sheep kidney and uterus embolization models. *J Vasc Interv Radiol* 2011;22(2):220–8.