

Intraosseous Pleomorphic Adenoma of the Mandible

Leila Aghaghazvini^{1,2,*}; Shirin Aghaghazvini²

¹Department of Radiology, Shariati Hospital, Tehran University of Medical Sciences, Tehran, Iran

²Advanced Diagnostic and Interventional Radiology Research Center (ADIR), Imam Khomeini Hospital, Tehran University of Medical Sciences, Tehran, Iran

*Corresponding author: Leila Aghaghazvini, Department of Radiology, Shariati Hospital, Tehran University of Medical Sciences, Tehran, Iran

Received: July 5, 2012; Revised: August 4, 2013; Accepted: August 7, 2013

Keywords: Salivary Gland; Orthopantomogram; Pleomorphic Adenoma; Mandible

Dear Editor,

Salivary gland tumors consist of about 3% of all head and neck tumors. Benign tumors (mainly pleomorphic adenoma) are the most common type. About 80% of them occur in the parotid glands. Carcinomas are rare and more common in the smaller salivary glands (1, 2). Benign salivary gland tumors rarely develop in the jaw bones. They arise from either the ectopic salivary tissue or minor salivary glands that are implanted in the bones. Ex pleomorphic adenomas within the mandible are extremely rare and only a few cases have been reported to date (3, 4).

We present a rare case of intraosseous pleomorphic adenoma of the mandible mimicking a radicular cyst or a brown tumor with unusual presentation in a 38-year-old man with low socio-economic status and poor hygiene. He presented with a rapid enlargement of the left mandible during two months. He also had mild pain and paresthesia of the mental region. On physical examination, a bony non-tender mass lesion about 20 × 15 mm in size was detected in the left para-symphysial portion of the mandible. Multiple teeth caries and destruction were detected. On the orthopantomogram, there was a lobulated irregular border lytic lesion in the left parasymphyseal portion of the mandibular body with erosion of the overlying teeth roots. In addition, there were many other destroyed and caried teeth together with destruction of a few laminae duras. Regarding imaging findings, large radicular cyst with periapical abscess was the first diagnosis. Brown tumor related to hyperparathyroidism and also other odontogenic cysts were our differential diagnoses.

The patient underwent surgery. A rubbery white-gray mass, 15 × 10 × 10 mm in size, was resected and sent for pathology. Pathology reported an infiltrative neoplasm exposed of epithelium with bland looking nuclei and acidophilic cytoplasm in a fibromyxoid stroma without necrosis. Pleomorphic adenoma was the diagnosis. There was no tumor recurrence during the one-year postopera-

tive follow-up. This is an interesting case not only for rarity but also for the sudden onset presentation of the lesion and unusual diagnosis in underlying jaw and dental disease (Figure 1).

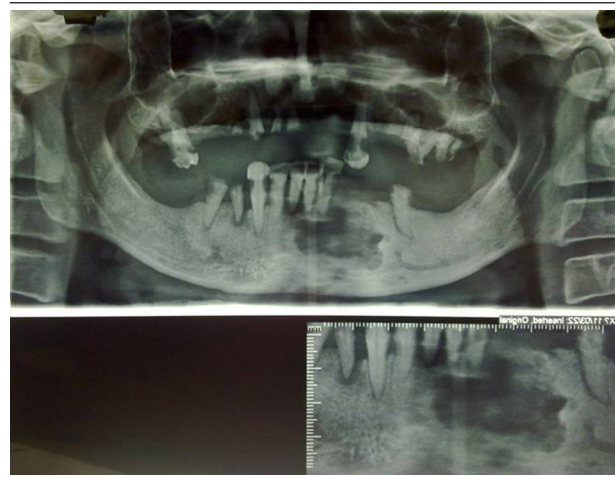


Figure 1. A 38-year-old man with rapid enlargement of the left mandible. A lobulated lytic bony lesion with a partially sclerotic border in the left parasymphyseal portion of the mandibular alveolar ridge accompanied with destruction of the overlying teeth roots and laminae duras. There is a notable lack of a few other teeth with caries of the remaining in the maxilla and mandible.

References

1. Stodulski D, Rzepko R, Kowalska B, Stankiewicz C. [Carcinoma ex pleomorphic adenoma of major salivary glands—a clinicopathologic review]. *Otolaryngol Pol.* 2007;**61**(5):687–93.
2. Mafee M. *Imaging of the Head and Neck.* 2 ed: Thieme; 2005.
3. Ojha J, Bhattacharyya I, Islam MN, Manhart S, Cohen DM. Intraosseous pleomorphic adenoma of the mandible: report of a case and review of the literature. *Oral Surg Oral Med Oral Pathol Oral Radiol Endod.* 2007;**104**(2):e21–6.
4. Zhao D, He H, Fang M, Liu M, Ji B, He Z. Primary central carcinoma ex pleomorphic adenoma of the mandible: report of a rare case and literature review. *Oral Surg Oral Med Oral Pathol Oral Radiol Endod.* 2011;**112**(2):e24–8.