

Quantitative evaluation of retinal artery occlusion using optical coherence tomography angiography

A case report

Xiaogang Wang, MD, PhD^a, Bin Sun, MD^a, Jie Wang, PhD^b, Yali Jia, PhD^b, David Huang, MD, PhD^b, Jing Dong, MS^{c,*}

Abstract

Rationale: Retinal artery occlusion (RAO) results in painless, catastrophic vision loss in a period of seconds. Optical coherence tomography angiography (OCTA) can image retinal microcirculation, which is helpful to evaluate treatment response during the follow-up period. Using a single case with central RAO, we report its retinal perfusion changes before and after treatment using OCTA.

Patient concerns: A 36-year-old Chinese man came to our clinic with a sudden, painless loss of vision (hand motion) in his left eye. A vasodilator (nicotinic acid) was used as the primary treatment. OCTA imaging and a visual field examination were performed to assess the retinal perfusion changes before and after treatment.

Diagnosis: Retinal artery occlusion was considered.

Interventions: This patient was treated with an inhaled oxygen-carbon dioxide mixture, nicotinic acid tablets (100 mg) taken orally twice a day, and intravenous infusion of nicotinic acid injections (60 mg) combined with 0.9% sodium chloride injections (100 ml) once a day for vasodilation.

Outcomes: After treatment and 9 months of follow-up, the vessel density of the left eye at the 9-month follow-up appointment was improved in all quadrants.

Lessons: Retinal edema and retinal atrophy were observed at the RAO onset and several months later, respectively. However, macular perfusion gradually increased after treatment. The timely administration of a vasodilator and the presence of the cilioretinal artery play important roles in the prevention of profound vision loss.

Abbreviations: DCP = deep capillary plexus, FA = fluorescein angiography, GCC = ganglion cell complex, ICP = intermediate capillary plexus, ILM = inner limiting membrane, INL = inner nuclear layer, IPL = inner plexiform layer, LV = loss variance, MD = mean defect, MS = mean sensitivity, OCTA = optical coherence tomography angiography, OMAG = optical coherence tomography-based microangiography, ONH = optic nerve head, PR = projection resolved, RAO = retinal artery occlusion, SSADA = split-spectrum amplitude-decorrelation angiography, SVC = superficial vascular complex, VF = visual field.

Keywords: case report, optical coherence tomography angiography, retinal artery occlusion

1. Introduction

Retinal artery occlusion (RAO), an emergency retinal vascular disorder, can result in profound vision loss. With the develop-

ment of the optical coherence tomographic angiography (OCTA) imaging technology, microcirculation in the optic nerve head (ONH) and the macula can be noninvasively and quickly

Editor: N/A.

Funding: This work was supported by the National Natural Science Foundation of China under Grant No. 81501544, National Institutes of Health Grants R01 EY023285, DP3 DK104397, R01 EY024544, P30 EY010572, and an unrestricted grant from Research to Prevent Blindness to Casey Eye Institute, Oregon Health & Science University (OHSU).

Competing interests: OHSU, YJ and DH have a significant financial interest in Optovue, Inc. DH also has a financial interest in Carl Zeiss Meditec. These potential conflicts of interest have been reviewed and managed by OHSU. Other authors do not have financial interest in the subject of this article.

Consent for publication: Written informed consent was obtained from the patient for publication of this case report and any accompanying images.

Ethics approval and consent to participate: The Institutional Review Board of the First Hospital of Shanxi Medical University approved this study, and the patient provided informed consent to participate. This study was performed in accordance with the tenets of the Declaration of Helsinki.

The authors have no conflicts of interest to disclose.

^a Shanxi Eye Hospital, Shanxi, PR China, ^b Casey Eye Institute, Oregon Health & Science University, Portland, OR, ^c The First Hospital of Shanxi Medical University, Shanxi, PR China.

* Correspondence: Jing Dong, Department of Ophthalmology, The First Hospital of Shanxi Medical University, No. 85 South Xinjian Road, Taiyuan 030001, China (e-mail: dongjing790610@163.com).

Copyright © 2018 the Author(s). Published by Wolters Kluwer Health, Inc.

This is an open access article distributed under the terms of the Creative Commons Attribution-Non Commercial-No Derivatives License 4.0 (CCBY-NC-ND), where it is permissible to download and share the work provided it is properly cited. The work cannot be changed in any way or used commercially without permission from the journal.

Medicine (2018) 97:40(e12652)

Received: 12 June 2018 / Accepted: 11 September 2018

<http://dx.doi.org/10.1097/MD.00000000000012652>

acquired without intravenous access. It can also evaluate the individual plexuses of the retinal and choroidal vasculature in 3-dimension, unlike the 2-dimensional projection that the fluorescein angiography (FA) is limited to.^[1–4] Moreover, OCTA is more amenable to quantification than FA due to the consistent and intrinsic contrast from blood flow.

Our previous study demonstrated that OCTA provided reliable measurements of macular perfusion.^[5] The purpose of this study was to demonstrate the capability of OCTA to objectively and accurately evaluate the retinal perfusion changes before and after treatment in a case of RAO.

2. Case presentation

2.1. Clinical details

A 36-year-old Chinese man with a 5-year history of hypertension presented with acute loss of vision in his left eye for 3 days, with no history of scalp tenderness or temporal headache. His blood pressure was 200/100 mm Hg; his best-corrected visual acuity was 16/20 in his right eye and hand motion in his left eye. Color fundus imaging revealed a diffusely whitening retina, with the exception of the tongue-shaped upper macula (Fig. 1A). RAO was diagnosed based on color fundus and FA (Fig. 1B) images.

The patient's serum homocysteine level was 54.5 $\mu\text{mol/L}$ (normal range, 6–15 $\mu\text{mol/L}$); all other hematology tests were normal. No abnormal carotid plaque was found on the bilateral carotid artery ultrasonography examination.

Enalapril folate tablets (10 mg) were taken orally once a day to treat hypertension. An inhaled oxygen–carbon dioxide mixture, nicotinic acid tablets (100 mg) taken orally twice a day, and intravenous infusion of nicotinic acid injections (60 mg) combined with 0.9% sodium chloride injections (100 ml) once a day for vasodilation, were used for approximately 2 weeks as emergency treatment.

Ten days after the RAO treatment, the patient's visual acuity was 20/20 in his right eye and 16/20 in his left eye. The color fundus and visual field (VF) showed much improvement compared to the disease onset. Treatment with enalapril folate tablets for hypertension was continued, and treatment with nicotinic acid tablets for RAO lasted approximately 3 months. At the patient's 9-month follow-up, his visual acuity was 20/20 in his

right eye and 20/20 in his left eye. Repeated color fundus, VF, and OCTA were performed for each eye.

2.2. Investigations

The patient underwent a comprehensive ophthalmologic examination, OCTA imaging (V.2015.1.0.90; Optovue, Fremont, CA), color fundus imaging (Topcon, Tokyo, Japan), and visual field (OCTOPUS 101, Haag-Streit Diagnostics, Koeniz, Switzerland) tests during his initial and follow-up visits. The OCTA system operated at an axial scan speed of 70 kHz using an 840-nm wavelength super-luminescent diode with a bandwidth of 45 nm. The 3×3 -mm and 4.5×4.5 -mm 3D OCTA scans centered on the fovea and ONH were captured for macular and ONH perfusion parameter measurements by the same operator (XGW). The projection-resolved OCTA (PR-OCTA) algorithm was applied to each volumetric OCTA scan to show the superficial vascular complex (SVC), intermediate capillary plexus (ICP), and deep capillary plexus (DCP). The SVC segmentation was from the inner 80% of the ganglion cell complex (GCC), which includes all structures between the inner limiting membrane (ILM) and inner plexiform layer/inner nuclear layer (IPL/INL) borders; the ICP was from the outer 20% of the GCC to the inner 50% of the INL; the DCP was from the outer 50% of the INL and the OPL.

We assume that the right eye OCTA data from the 9-month follow-up was a demonstration of normal baseline. The retinal thickness and perfusion changes in the left eye on the first visit and the 9-month visit were compared with the normal baseline. The 3×3 -mm mean retinal thickness and vessel density in the fovea and the superior, inferior, nasal, and temporal quadrants before and after treatment were compared (Fig. 2).

The left retina was thicker in all quadrants (from 6 μm to 39 μm) at the first visit than the right retina at the 9-month follow-up (Fig. 3A). After treatment and 9 months of follow-up, the left retina was thinner (from 11 to 110 μm) than that of the right retina, with the exception of the superior quadrant (7 μm thicker). Correspondingly, the vessel density of the left eye at the 9-month follow-up appointment was improved in all quadrants (from 6% to 19%). However, the vessel density of the left eye at 9 months was still lower than that of the right eye except in the fovea (Fig. 3B). We considered the mean sensitivity (MS), mean defect (MD), and loss variance (LV) to be indicators of general VF

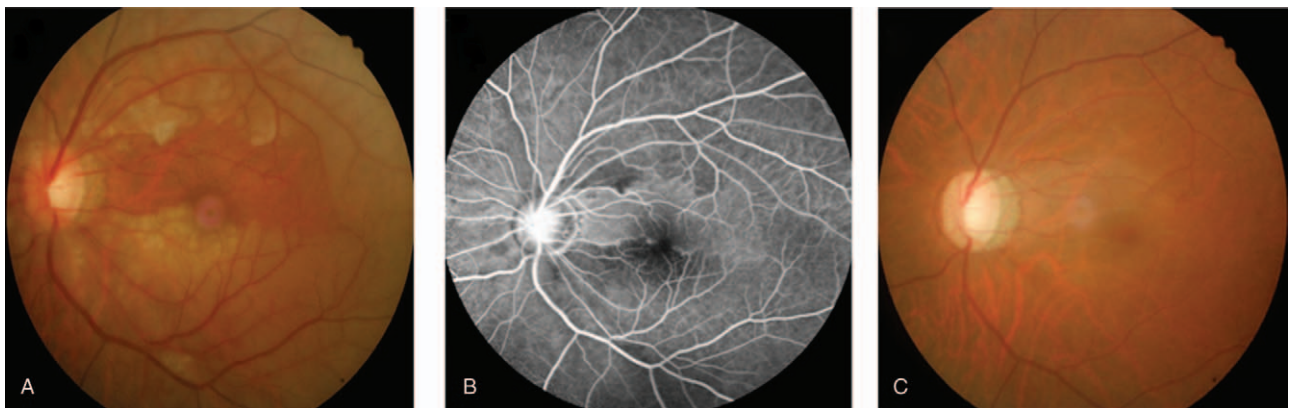

Figure 1. A color fundus photo at the first visit (A) revealed whole-retinal whitening, with the exception of a tongue-shaped zone. Fluorescein angiography (B) demonstrated capillary nonperfusion in the region with obstructed flow. A color fundus photo taken 9 months after treatment (C) demonstrated that the whitening of the original obstructed area had vanished and the tongue-shaped zone was clear.

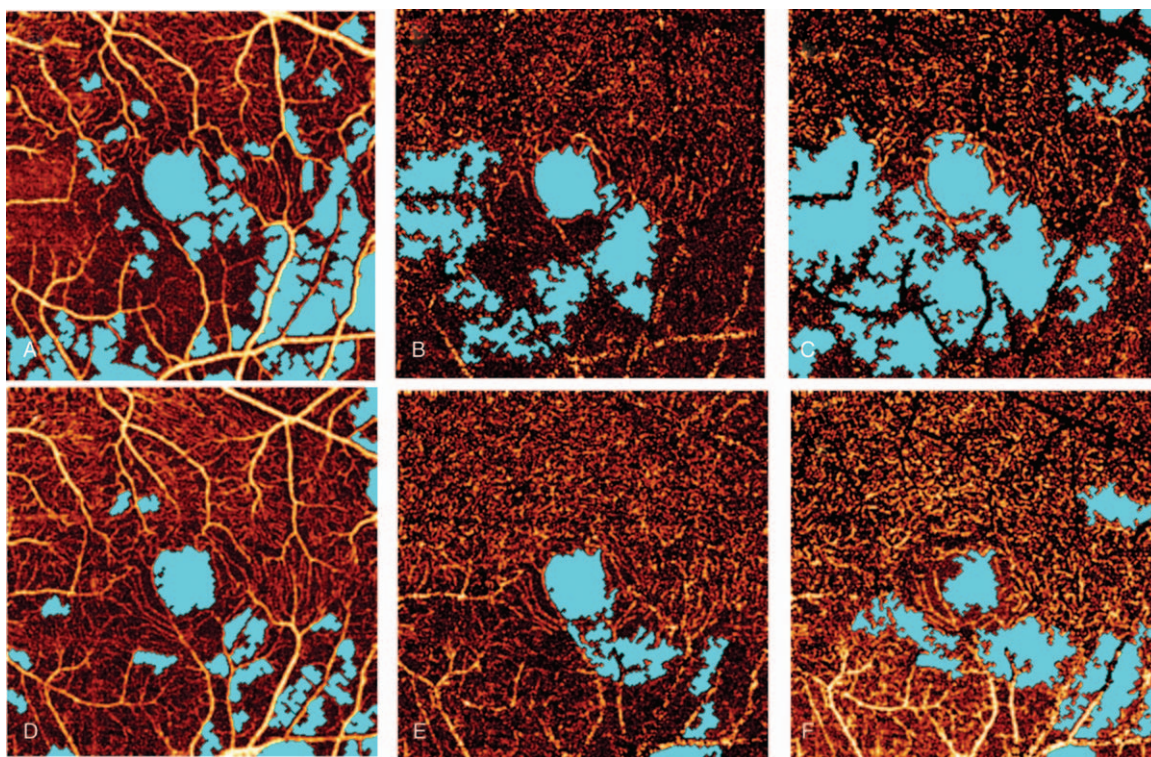


Figure 2. Baseline (first row) 3×3 -mm region centered on the fovea imaged using optical coherence tomography angiography (OCTA) with projection-resolution (PR) in the superficial ([A] vessel density, 53.79%), intermediate ([A] vessel density, 30.06%), and deep plexuses ([C] vessel density, 19.31%). The 9-month follow-up (second row) 3×3 -mm OCTA zone with PR in the superficial ([D] vessel density, 58.29%), intermediate ([A] vessel density, 34.49%), and deep plexuses ([F] vessel density, 25.96%). The ischemic areas were demonstrated using blue color.

sensitivity. For VF examination of the left eye, the MS, MD, and LV were improved, but were still lower than those of the right eye (Table 1).

3. Discussion

Compared to FA, the standard imaging modality of retinal vascular disease evaluation, OCTA can noninvasively provide qualitative and quantitative evaluation of retinal vasculature. Moreover, OCTA can provide superficial, intermediate, and deep retinal plexus information with individual segmentation. Based on previous studies, RAO results in retinal atrophy that progresses over time, and the structural changes stabilize after 5 months.^[6] The retinal atrophy was consistent with the obvious decreased retinal thickness in the ischemic area at the 9-month follow-up in this study. Moreover, the OCTA images and vessel density data in this study were similar to reports of the chronic phase of branch RAO, which demonstrated a marked decrease in retinal capillary density.^[7] For cases of RAO, the inner retinal damage, which results in retinal atrophy and attenuated retinal microcirculation, is permanent.^[8] This may explain why, even 9 months after treatment, the retinal vessel densities of the left eye were still lower than those of the relatively normal values of the right eye.

The split-spectrum amplitude-decorrelation angiography (SSADA) algorithm was used to evaluate retinal ischemia in this study. The PR-OCTA algorithm, by removing the projection artifacts and retaining the real blood vessel signals in the intermediate and deep plexus layers, provides more precise

quantitative evaluation of the deep layer and shows more details of deep plexus blood vessel information. As our previous paper demonstrated, this algorithm can reveal additional retinal vasculature information of the deep layer. Moreover, we can quantitatively measure the vessel density in each layer, which makes precise evaluation of individual vascular plexuses in multiple retinal diseases possible. Similar findings have been reported in previous studies using the optical coherence tomography-based microangiography (OMAG) algorithm; in this study, a more severe loss of retinal microvasculature was found in the intermediate and deep plexuses compared to the superficial plexus using the SSADA algorithm.^[6]

Nicotinic acid is often used to treat hyperlipidemia.^[9] It also has a vasodilatory effect, which is mediated by the release of endogenous prostaglandins.^[10,11] Cystoid macular edema was the primary side effect of the high-dose administration of nicotinic acid (> 1.5 g/day) for a period of more than 6 weeks.^[12] The safe and effective dose of an injection of 60 mg/day for 2 weeks and 200 mg/day tablets for 3 months were recommended in this study.

Based on previous reports, cilioretinal arteries were highly variable in number, location, and vessel caliber. Moreover, approximately 18.7% of patients' cilioretinal arteries contribute to macular perfusion.^[13] Fortunately, the cilioretinal artery of this patient's left eye supplied the upper fovea. Thus, he had more profound vision improvement in this eye after treatment. Compared to the perfused, tongue-shaped retina supplied by the cilioretinal artery, all 3 retinal capillary plexuses in the ischemic area were involved.

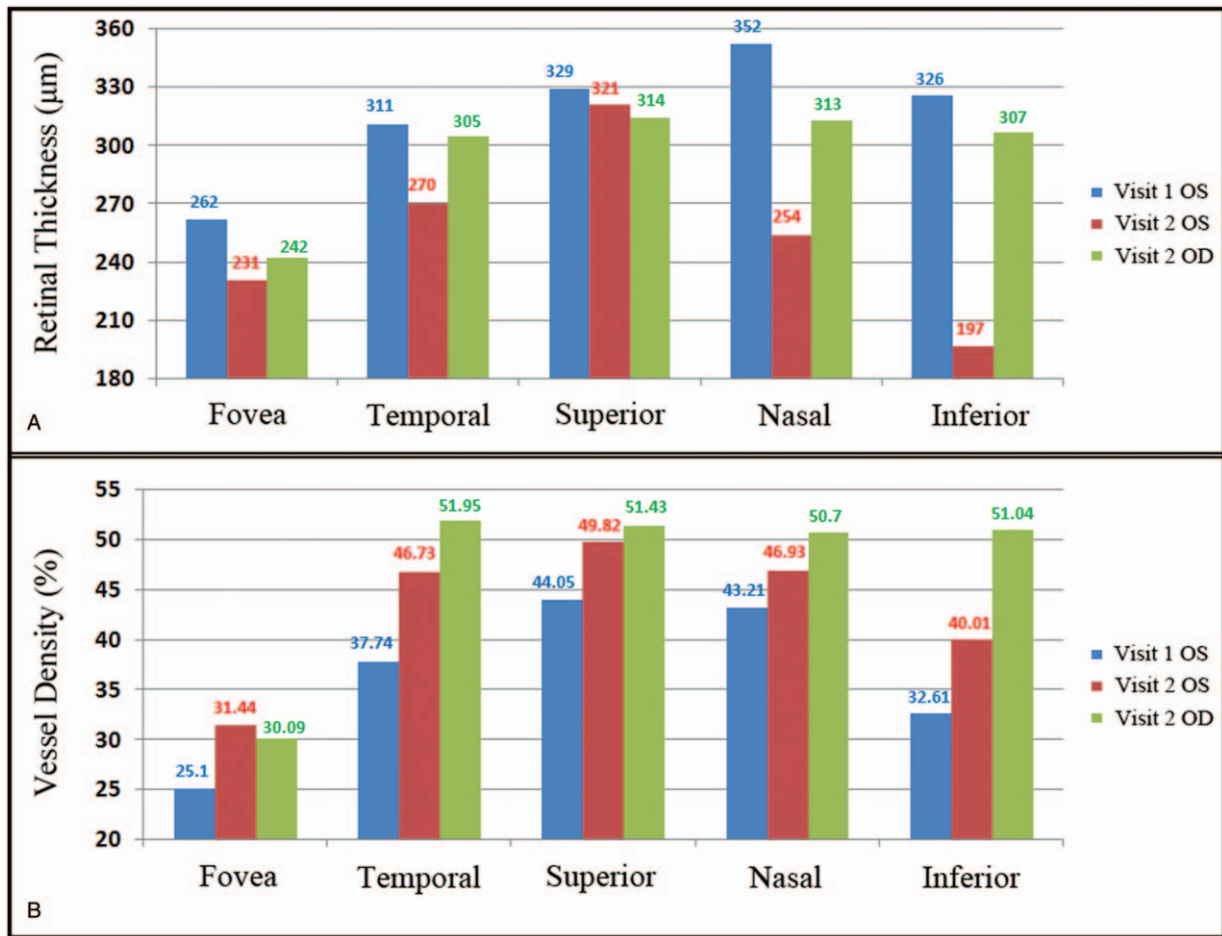


Figure 3. Retinal thickness (A) and macular perfusion (B) in different quadrants of a 3 × 3-mm region centered on the fovea were imaged using optical coherence tomography angiography (OCTA) at the first visit (visit 1) and 9 months after treatment (visit 2). Note: blue data are at onset in the left eye; red data are the left eye 9 months later; green data are the right eye 9 months later.

Table 1

Visual field parameters of both eyes before and after treatment.

	Right eye			Left eye		
	MS	MD	LV	MS	MD	LV
Baseline	21.1	7.6	22.8	5.8	22.9	63.0
9 months	28.3	0.5	4.6	19.3	9.4	18.3

LV=loss variance, MD=mean defect, MS=mean sensitivity.

4. Conclusions

OCTA provides quantitative and useful macular perfusion information for the follow-up of RAO treatment. Nicotinic acid treatment and the presence of cilioretinal arteries play important roles in the prevention of profound vision loss.

Author contributions

Conceptualization: Xiaogang Wang, Bin Sun, Yali Jia, David Huang, Jing Dong.

Data curation: Xiaogang Wang, Jie Wang, Yali Jia, David Huang, Jing Dong.

Formal analysis: Xiaogang Wang, Jing Dong.

Funding acquisition: Xiaogang Wang, Yali Jia, David Huang.

Investigation: Xiaogang Wang, Bin Sun, Yali Jia, David Huang, Jing Dong.

Methodology: Xiaogang Wang, Bin Sun, Jie Wang, Yali Jia, David Huang, Jing Dong.

Project administration: Xiaogang Wang, David Huang, Jing Dong.

Supervision: Xiaogang Wang, Bin Sun, Yali Jia, David Huang, Jing Dong.

Validation: Xiaogang Wang.

Visualization: Xiaogang Wang.

Writing – original draft: Xiaogang Wang.

Writing – review & editing: Xiaogang Wang, Bin Sun, Jie Wang, Yali Jia, David Huang, Jing Dong.
Xiaogang Wang: 0000-0001-7325-3314.

References

- [1] Coscas F, Glacet-Bernard A, Miere A, et al. Optical coherence tomography angiography in retinal vein occlusion: evaluation of superficial and deep capillary plexa. *Am J Ophthalmol* 2016;161:160.e1-2–71.e1-2.
- [2] Jia Y, Tan O, Tokayer J, et al. Split-spectrum amplitude-decorrelation angiography with optical coherence tomography. *Opt Express* 2012;20:4710–25.
- [3] Jia Y, Wei E, Wang X, et al. Optical coherence tomography angiography of optic disc perfusion in glaucoma. *Ophthalmology* 2014;121:1322–32.
- [4] Yu S, Pang CE, Gong Y, et al. The spectrum of superficial and deep capillary ischemia in retinal artery occlusion. *Am J Ophthalmol* 2015;159:53–63. e1-2.
- [5] Dong J, Jia YD, Wu Q, et al. Interchangeability and reliability of macular perfusion parameter measurements using optical coherence tomography angiography. *Br J Ophthalmol* 2017;101:1542–9.
- [6] Lee AY, Zhang Q, Baughman DM, et al. Evaluation of bilateral central retinal artery occlusions with optical coherence tomography-based microangiography: a case report. *J Med Case Rep* 2016;10:307.
- [7] Bonini Filho MA, Adhi M, de Carlo TE, et al. Optical coherence tomography angiography in retinal artery occlusion. *Retina* 2015;35:2339–46.
- [8] Bauman CR. Optical coherence tomography angiography of retinal artery occlusion. *Dev Ophthalmol* 2016;56:122–31.
- [9] Carlson LA. Nicotinic acid: the broad-spectrum lipid drug. A 50th anniversary review. *J Intern Med* 2005;258:94–114.
- [10] Morrow JD, Parsons WG3rd, Roberts LJ2nd. Release of markedly increased quantities of prostaglandin D2 in vivo in humans following the administration of nicotinic acid. *Prostaglandins* 1989;38:263–74.
- [11] Eklund B, Kaijser L, Nowak J, et al. Prostaglandins contribute to the vasodilation induced by nicotinic acid. *Prostaglandins* 1979;17:821–30.
- [12] Gass JD. Nicotinic acid maculopathy. *Am J Ophthalmol* 1973;76:500–10.
- [13] Justice JJr, Lehmann RP. Cilioretinal arteries A study based on review of stereo fundus photographs and fluorescein angiographic findings. *Arch Ophthalmol* 1976;94:1355–8.