

# A Woman with Posterior Heel Pain: Ultrasound Imaging for Os Trigonum Syndrome

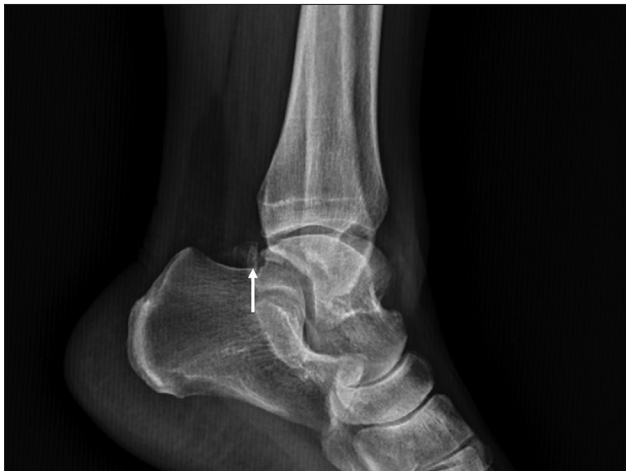Ting-Yu Lin<sup>1</sup>, Ke-Vin Chang<sup>2,3,4\*</sup>, Wei-Ting Wu<sup>2,3</sup>, Levent Özçakar<sup>5</sup>

<sup>1</sup>Department of Physical Medicine and Rehabilitation, Lo-Hsu Medical Foundation, Inc., Lotung Poh-Ai Hospital, Yilan City, Taiwan, <sup>2</sup>Department of Physical Medicine and Rehabilitation, College of Medicine, National Taiwan University Hospital, National Taiwan University, Taipei, Taiwan, <sup>3</sup>Department of Physical Medicine and Rehabilitation, National Taiwan University Hospital, Bei-Hu Branch, Taipei, Taiwan, <sup>4</sup>Center for Regional Anesthesia and Pain Medicine, Wang-Fang Hospital, Taipei Medical University, Taipei, Taiwan, <sup>5</sup>Department of Physical and Rehabilitation Medicine, Hacettepe University Medical School, Ankara, Turkey

## SECTION 2 – ANSWER

### Case

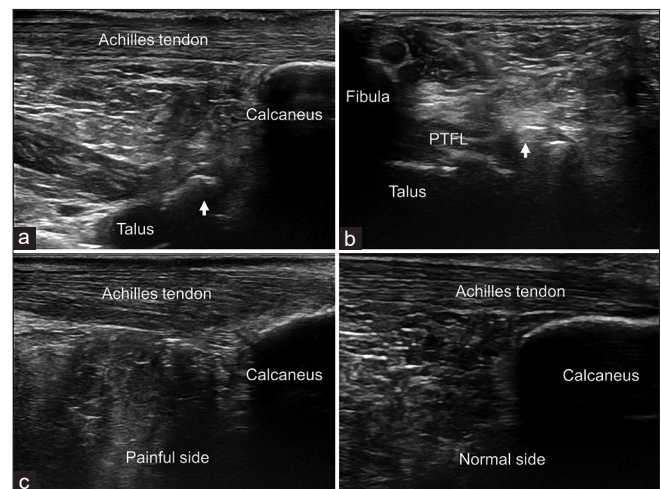
A 49-year-old female presented to the clinic with progressive left posterior heel pain for the past 1 month. The pain had worsened substantially during activity. She had a regular exercise habit of running twice per week. There was neither antecedent trauma nor any prior surgery of the affected limb. No history of rheumatic disease was reported, either. On physical examination, tenderness and mild swelling over the left hindfoot were noticed. There was no limitation of ankle range of motion and the Thompson test was negative on the affected side. Figure 1 shows the lateral radiograph of her left foot. An ultrasound examination was carried out and the images of the left foot are presented in Figure 2. What is the cause of her foot pain?



**Figure 1:** Lateral radiograph of the left foot shows the os trigonum (arrow) behind the talus

## INTERPRETATION

The lateral radiograph [Figure 1] and ultrasound imaging in the long-[Figure 2a] and short-[Figure 2b] axes of the left ankle showed a separate ossicle posterior to the talus. Comparative ultrasound images [Figure 2c] revealed evident thickening of the left Achilles tendon. Os trigonum syndrome with concomitant Achilles tendinopathy was diagnosed. Physiotherapy, oral anti-inflammatory treatment, and activity modification were given. At the follow-up



**Figure 2:** Ultrasound image of the os trigonum (arrows) in long-(a) and short-(b) axes. A side-to-side comparison shows thickened Achilles tendon on the painful side (c). PTFL: posterior talofibular ligament

**Address of correspondence:** Dr. Ke-Vin Chang,

Department of Physical Medicine and Rehabilitation, National Taiwan University Hospital, Bei Hu Branch, National Taiwan University College of Medicine, Taipei, Taiwan.  
E-mail: kvchang011@gmail.com

Received: 19-05-2022 Revised: 30-06-2022 Accepted: 04-07-2022 Available Online: 22-09-2022

### Access this article online

Quick Response Code:



Website:  
<https://journals.lww.com/jmut>

DOI:  
10.4103/jmu.jmu\_48\_22

This is an open access journal, and articles are distributed under the terms of the Creative Commons Attribution-NonCommercial-ShareAlike 4.0 License, which allows others to remix, tweak, and build upon the work non-commercially, as long as appropriate credit is given and the new creations are licensed under the identical terms.

For reprints contact: WKHLRPMedknow\_reprints@wolterskluwer.com

**How to cite this article:** Lin TY, Chang KV, Wu WT, Özçakar L. A woman with posterior heel pain: Ultrasound imaging for os trigonum syndrome. *J Med Ultrasound* 2024;32:188-9.

visit 2 weeks later, her pain was found to have improved gradually.

## DISCUSSION

Foot pain is a highly prevalent and potentially disabling complaint, affecting 14%–42% of people at any given time.<sup>[1]</sup> It can negatively impact functional ability, mental status, and quality of life and increase the risk of falls. Hindfoot pain accounts for approximately one-quarter of all foot pains. A U-shaped relationship between age and hindfoot pain was reported, with the highest prevalence among those aged 20–34 years and over 75.<sup>[2]</sup> Etiologies of posterior foot pain encompass ankle sprain, hindfoot malalignment, Achilles tendinopathy, enthesopathy, bursitis, gout, rheumatoid arthritis, ruptured gastrocnemius, os trigonum, calcaneal calcification, and more. These conditions are not exclusive to one another and may occur simultaneously or consequently. Therefore, discerning an accurate diagnosis is of immense importance to formulate an effective treatment.

The os trigonum is an accessory bone wedged among the tibia, talus, and calcaneus. It arises from a secondary ossification center of the talus that failed to fuse properly, or much less frequently, originates from a stress fracture of the Steida process.<sup>[3,4]</sup> Despite being quite a common variant (in 14% to 25% of the general population), it can become problematic in some cases.<sup>[4]</sup> Os trigonum syndrome, also known as talar compression or posterior ankle impingement syndrome, can be triggered by repetitive microtrauma or an acute injury. During forceful plantar flexion of the ankle, the extra ossicle gets pinched between the heel bones (the “nutcracker” mechanism) and irritates its surrounding tissues. The main clinical symptom is deep, posterior ankle pain that is exaggerated in the push-off phase. Stiffness and swelling can also be observed. In chronic impingement, restricted range of motion and weakness of the big toe may develop due to the flexor hallucis longus tenosynovitis.<sup>[5]</sup> The os trigonum can be identified in the lateral radiograph of the foot, i.e., a triangular shape with a size < 1 cm.<sup>[6]</sup> Computed tomography and magnetic resonance imaging are able to pick up more detailed bone and soft-tissue abnormalities, such as sclerosis, subchondral bone edema, and joint effusion.<sup>[7]</sup> The first-line conservative treatments comprise rest, nonsteroid anti-inflammatory drug, taping, and physiotherapy. Corticosteroid injections, both diagnostic and therapeutic, resolve the pain in majority of the patients. Concerning the refractory cases, surgical excision has yielded satisfactory clinical results.<sup>[8]</sup>

Ultrasound imaging can be used to investigate several soft-tissue pathologies associated with hindfoot pain. Sonographic evaluation is performed with the patient lying in a prone position with the foot hanging out of the examination table. The os trigonum is a bony protuberance at the anterior aspect of the Kager’s triangle. The examiner should look for adjacent fluid collection in the deep posterior ankle recess and changes of nearby muscle tendons, particularly tenosynovitis of the flexor hallucis longus. Dynamic ultrasound captures impingement of the flexor hallucis longus during big toe movement. While scanning for Achilles tendon abnormalities, a high-frequency linear transducer should navigate

from the myotendinous junction of gastrocnemius to the calcaneal insertion. Tendinopathy is visualized by decreased echogenicity, disordered fiber arrangement, secondary hypertrophy, and neovascularization.<sup>[9]</sup> Comparison of the tendon size with the unaffected side is a useful technique, for sure. Ossification (with posterior shadowing) within the tendon is indicative of calcific tendinopathy. Retrocalcaneal bursitis appears as a hypoechoic fluid-filled sac deep to the Achilles tendon with synovial hypertrophy and increased vascularity. Meanwhile, bone erosions, osteophyte formation, and joint effusions are hallmarks of arthritis.

Os trigonum is likely an underrecognized source of posterior heel pain. Musculoskeletal ultrasound is an efficient, portable, pain-free tool to assess for multiple differential diagnoses of this disease. Moreover, echo-guided injections can confirm the pain generator and provide safe and precise treatment.

## Declaration of patient consent

The authors certify that they have obtained all appropriate patient consent forms. In the form, the patient has given her consent for her images and other clinical information to be reported in the journal. The patient understands that her name and initials will not be published and due efforts will be made to conceal the identity, but anonymity cannot be guaranteed.

## Financial support and sponsorship

This work was funded by the National Taiwan University Hospital, Bei-Hu Branch; Ministry of Science and Technology (MOST 106-2314-B-002-180-MY3 and 109-2314-B-002-114-MY3); and the Taiwan Society of Ultrasound in Medicine.

## Conflicts of interest

Prof. Ke-Vin Chang, an editorial board member at *Journal of Medical Ultrasound*, had no role in the peer review process of or decision to publish this article. The other authors declared no conflicts of interest in writing this paper.

## REFERENCES

- Hawke F, Burns J. Understanding the nature and mechanism of foot pain. *J Foot Ankle Res* 2009;2:1.
- Hill CL, Gill TK, Menz HB, Taylor AW. Prevalence and correlates of foot pain in a population-based study: The North West Adelaide health study. *J Foot Ankle Res* 2008;1:2.
- Jones DM, Saltzman CL, El-Khoury G. The diagnosis of the os trigonum syndrome with a fluoroscopically controlled injection of local anesthetic. *Iowa Orthop J* 1999;19:122-6.
- Nault ML, Kocher MS, Micheli LJ. Os trigonum syndrome. *J Am Acad Orthop Surg* 2014;22:545-53.
- Rungprai C, Tennant JN, Phisitkul P. Disorders of the flexor hallucis longus and os trigonum. *Clin Sports Med* 2015;34:741-59.
- Karasick D, Schweitzer ME. The os trigonum syndrome: Imaging features. *AJR Am J Roentgenol* 1996;166:125-9.
- Aparisi Gómez MP, Aparisi F, Bartoloni A, Ferrando Fons MA, Battista G, Guglielmi G, et al. Anatomical variation in the ankle and foot: From incidental finding to indicator of pathology. Part I: Ankle and hindfoot. *Insights Imaging* 2019;10:74.
- Mouhsine E, Crevoisier X, Leyvraz PF, Akiki A, Dutoit M, Garofalo R. Post-traumatic overload or acute syndrome of the os trigonum: A possible cause of posterior ankle impingement. *Knee Surg Sports Traumatol Arthrosc* 2004;12:250-3.
- Mascarenhas S. A narrative review of the classification and use of diagnostic ultrasound for conditions of the Achilles tendon. *Diagnostics (Basel)* 2020;10:944.