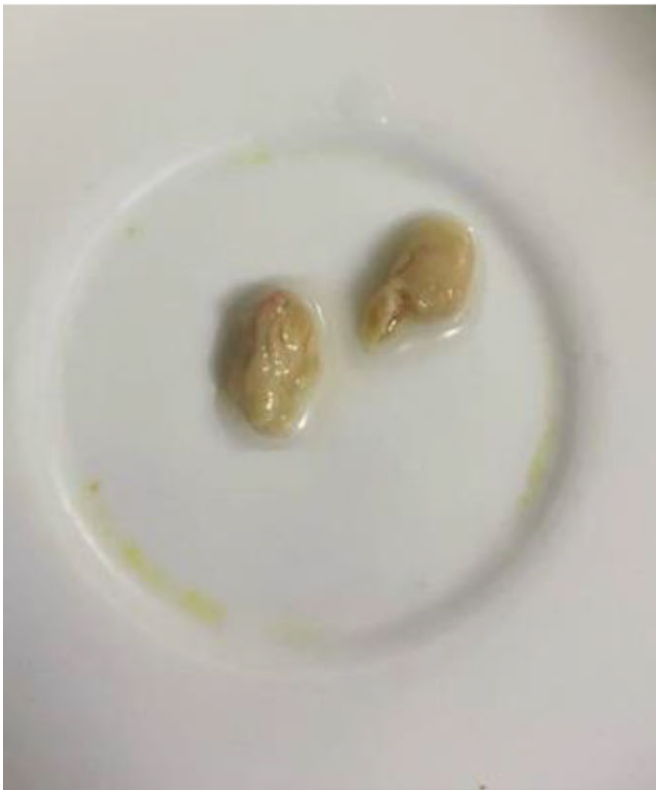

	Patient 1	Patient 2	Patient 3
Age/Sex	66/M	61/M	68/F
Diabetes	Yes	Yes	Yes
Temporal association with COVID	2 months	1 month	1 month
Severity of COVID	Mod/Severe	Severe	Severe
Organism	Candida Tropicalis	Aspergillus Flavus	Candida glabrata
Radiological features	B/L pyelonephritis (Rt>Lt) with Rt Hydroureteronephrosis	Rt Pyelonephritis with dilated PCS	B/L enlarged kidneys, multiple hypodense areas, extensive perinephric fat stranding, early forming abscess on LK lower pole



P135
Immunological correlation with clinicomycological aspects of fungal rhinosinusitis during COVID-19 pandemic

Mohan Vashista
 Vardhman Mahavir Medical College and Safdarjung College, New Delhi, India

Poster session 1, September 21, 2022, 12:30 PM - 1:30 PM

Background and Objectives: To determine the relation between disease spectrum, etiology, and immunological markers of fungal rhinosinusitis.

Material and Methods: Diagnostic nasal endoscopy was used for the collection of sinus and nasal tissue samples which were processed as per standard mycological procedure for microscopy, culture and histopathological examination (HPE). Enzyme-linked immunosorbent assay was used for total IgE, serum IL-6, IL-10, TNF- α levels detection.

Results: Out of 148 samples, 70% were diagnosed as FRS. COVID-19 infection 46.9% was the most common comorbid condition. Use of steroid therapy 46.9% was the most common predisposing factor. Nasal obstruction 62.2% was the most common clinical feature but headache (P -value .002) and eye discharge were statistically significant (P -value .005). KOH mount revealed findings in 84.69% patients in this study. Combination of KOH, HPE, and fungal culture revealed findings in 62.2% cases. *Rhizopus arrhizus* 27.6% was the most common isolate *Aspergillus flavus* and *Rhizopus arrhizus* were statistically significant (P -value .003, .026 respectively). IL-6 59.2% was the most common serological marker raised in this study. PNS imaging

revealed that 100% of the patients had single or multiple sinus involvement and maxillary sinus (P -value .038) was significantly associated. Acute invasive fungal rhinosinusitis 75.5% was the most common type of FRS. Mortality was 17.34% in this study.

Conclusion: FRS is an important emerging public health problem and a cause of mortality and morbidity, particularly in immunocompromised patients. Furthermore, in the current scenario of COVID-19 pandemic, FRS has become more fatal and an entity of immediate and grave concern than ever before.

P137
Remote inoculation mycosis: Rip Van Winkle wakes up

Rajeev Soman¹, Sourabh Chakraborty¹, Tarun Jeloka¹, Geethu Joe¹, Nandini Ramchandani¹, Harsimran Kaur²
¹Jupiter Hospital, Pune, Pune, India
²PGI, Chandigarh, Chandigarh, India

Poster session 2, September 22, 2022, 12:30 PM - 1:30 PM

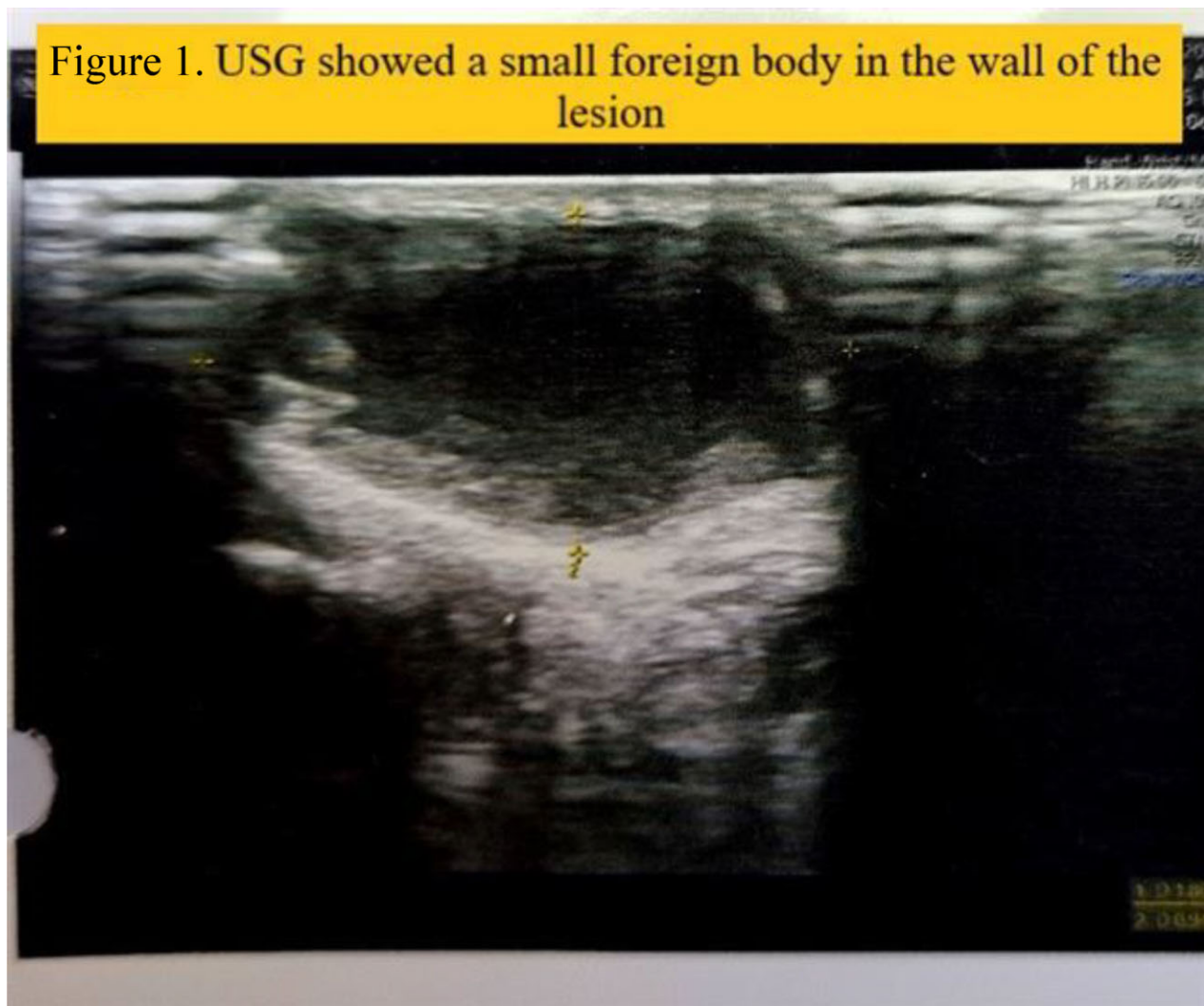
Objective: After immunosuppression, a remotely inoculated organism may be activated to produce clinical disease. We describe such a case with infection due to *Medicopsis romeroi*, a rare mold.

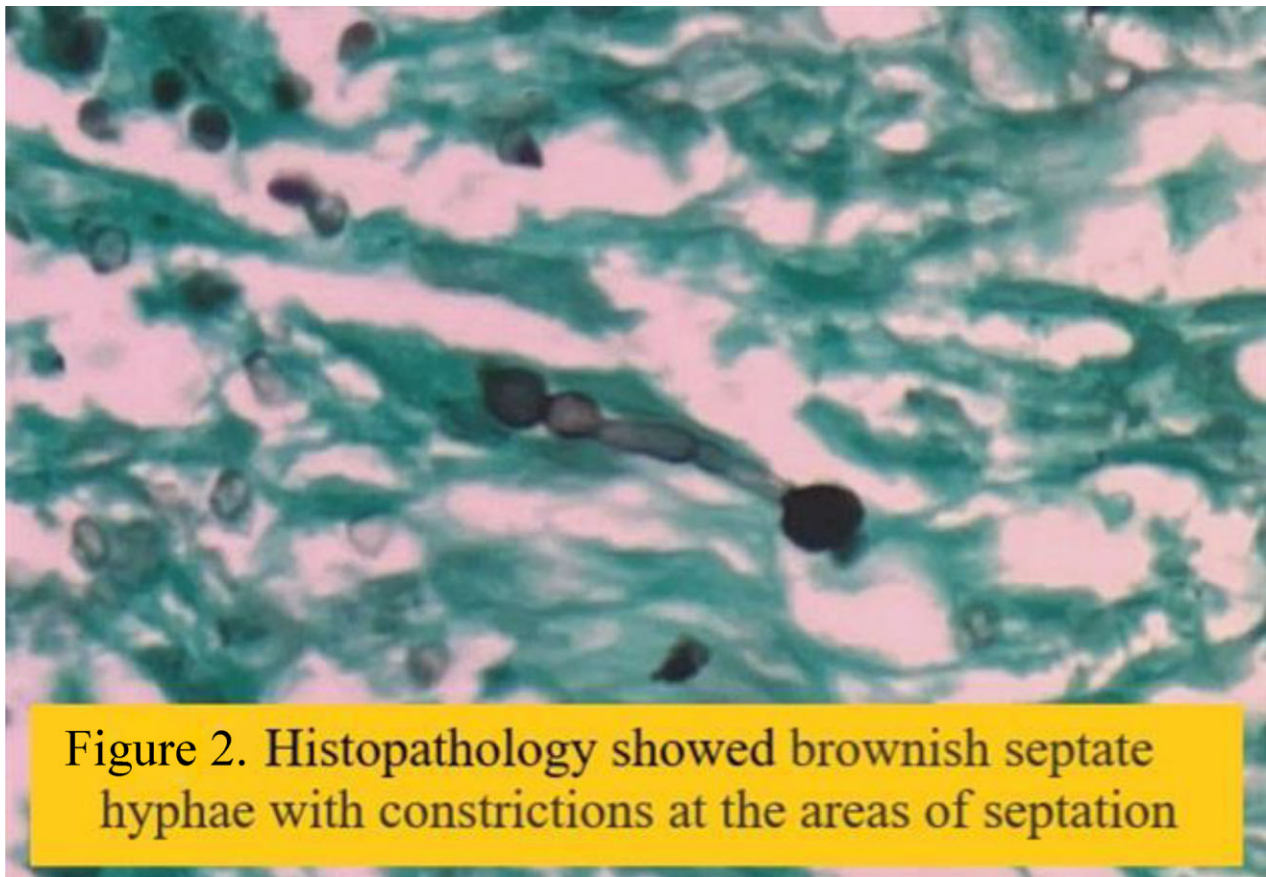
Patient and Methods: A 54-year-old male, diabetic, hypertensive, status post-live related donor renal transplantation, done in February 2021. The patient was on standard triple immunosuppressant regimen. He developed a painless nodule on his thumb

over 5 months which did not respond to multiple courses of antibiotics. The swelling was excised and sent for various tests. Review of USG after infectious disease referral, showed a small foreign body in the wall of the lesion (Fig. 1). On inquiry, a 3 mm wooden splinter in the lesion was noted during surgery and there was an injury at the same site, 20 years ago when the patient used to work on a farm. Organisms derived from soil or thorn injury including bacterial and fungal organisms were considered in the differential diagnosis. Bacterial organisms were considered less likely as there was no response to antibiotics.

Results: Histopathology showed brownish septate hyphae with constrictions at the areas of septations (Fig. 2). The excised tissue grew a dematiaceous mold. In Lactophenol Cotton Blue (LPCB) mount branched, septate hyphae with sparse conidia were seen. MALDI-TOF MS was unable to identify the mold. Sequencing identified it as *M. romeroi*. There are no ECOFFs or break points (BP) available for *M. romeroi*. Minimum inhibitory concentration (MIC) of Voriconazole (VCZ) is reportedly low and hence was chosen for treatment with an appropriate dose adjustment of Tacrolimus.

Conclusion: This case underscores that remote inoculation, when the patient was immunocompetent, could have introduced a mold, which remained latent and reactivated after immunosuppression. Sending excised tissue for appropriate tests is rewarding. *Medicopsis romeroi* is a rare mold with only 12 cases reported so far. It is difficult to identify except with sequencing. There is no standard guidance on treatment. Surgical excision along with prolonged treatment with one of the new azoles is beneficial.





P138

A decade of cat-transmitted sporotrichosis (CTS) in a tertiary hospital from Curitiba, southern Brazil (2011-21)

Regielli Cognialli, Fernanda Daros, Diésica Ferreira, Adriana Gabriel, Lili Lopuch, Franceline Cavassin, Bruno Lustosa, Vânia Vicente, Giovanni Breda, Izabella Santos-Weiss, Flávio Queiroz-Telles
Universidade Federal do Paraná, Curitiba, Brazil

Poster session 2, September 22, 2022, 12:30 PM - 1:30 PM

Objectives: This study aims to report the evolution of cat-transmitted sporotrichosis (CTS) and map the distribution of these cases within a tertiary hospital in Curitiba (state capital of Paraná, in southern Brazil).

Methods: We reviewed the medical records of 175 patients seen in a hospital service over a period of 10 years (2011-21). Proven CTS consists of patients that had clinical manifestations after contact with sick cats, microbiological, and/or histopathological evidence of sporotrichosis. CTS was considered probable when patients had clinical signs associated with contact with sick cats that had a microbiological diagnosis of sporotrichosis made by a veterinarian. The confirmed cases in set were submitted to molecular identification performed by sequencing the locus of calmodulin (CAL), determined by the use of primers 1 (5'-GAR TWC AAG GAG GCC TTC TC-3') and CL2A (5'-TTTT TTG CAT GAG TTG GAC-3'). The study was approved by the local Research Ethics Committee. Data analysis was performed using Statistical software for Windows (Version 8.0, StatSoft Inc., Tulsa, OK, USA).

Results: The diagnosis of proven sporotrichosis was established in 57 patients (32.6%) and the probable diagnosis was verified in 118 patients (67.4%). Among all 175 patients, 171 (98.3%) cases were reported as zoonotic transmission and only 4 (1.7%) as saprotonic (classical pathway). Molecular identification was performed in 35 isolates and in 97.0% ($n = 34$) of them, *Sporothrix brasiliensis* was the main etiological agent identified (Fig. 1). Most cases of sporotrichosis were diagnosed between 2019 to 2021 ($n = 105$, 60%). The incidence rate increased from 0.27 cases/100.000 patients in 2011 to 30.4 cases/100.000 patients in 2021 (until July) and was observed geographic expansion of human cases of CTS in Curitiba in the last decade (accumulated cases 2011-12, 2011-16, and 2011-21 July) (Fig. 2). Prevalence rate was 4.97 cases per 100 000 patients. The majority of the patients were from Curitiba ($n = 145$, 82.9%). Women were the most affected (63.4% women vs 36.6% men) with the average age of 40 years old (1-87 years old). A total of 12% ($n = 21$) of the patients were under 18 years old. The prevalence of CTS in patients at high risk of occupational exposure to the disease was 9.7% ($n = 17$), 9 being veterinarians, 5 veterinary students, 3 pet house workers, and 2 gardeners. The main clinical manifestation was lymphocutaneous ($n = 114$, 65.1%), followed by fixed cutaneous ($n = 43$, 24.6%), ocular ($n = 13$, 7.4%), and mixed forms ($n = 5$, 2.9%).

Conclusion: CTS is a public health issue that is aggravated due to the lack of national control programs, unknown prevalence of the disease, lack of knowledge of the population, and health professionals about the epidemic. Besides that, there are difficulties in handling sick cats, lack of diagnosis of human and veterinary cases, and poor access to free medication. In 2011, the first case of CTS was identified in Curitiba, Paraná, Brazil. In 10 years, there has been a significant increase in the number of new cases. Those evidence indicate the continuous dispersion of the disease out of epidemiological control.