

Glioblastoma Shortly after a Normal Conventional Brain Magnetic Resonance Imaging: A Report of Two Cases and Review of the Literature

Abstract

Glioblastoma (GB) is the most common malignant tumor of the brain. Most of these tumors are primary or *de novo* GBs that manifest rapidly with initial presentations such as headache, new-onset epileptic seizure, focal neurological deficits, and altered mental status. The typical radiological features of GB include strong contrast enhancement, central necrosis, and edema with mass effect. Herein, we describe two cases of primary GB – two women aged 60 and 51 years who were diagnosed with GB 3.5 and 4 months, respectively, after their initial admission. These patients presented with right-sided headaches, and their neurological examination was within the normal limits. Their initial radiological investigations revealed no suspicious lesions, either on T1-weighted or T2-weighted magnetic resonance (MR) images. The 60-year-old patient was readmitted with persistent headache, and her T1-weighted MR images revealed a well-demarcated mass lesion in the right temporal lobe with strong contrast enhancement. Moreover, the T2-weighted MR images revealed closed sulci and swollen midline structures because of edema. The 51-year-old patient was readmitted with persistent headache, and her MR image revealed a mass lesion with heterogeneous contrast enhancement and necrosis on T1-weighted images and hyperintense areas with severe edema on T2-weighted images. The patients underwent craniotomy and gross total tumor resection. Notably, in both cases, the lesions were pathologically diagnosed as GB. Therefore, it should be borne in mind that only persistent headache could be a sentinel sign of GB before it becomes radiologically visible, thereby emphasizing the need for follow-up imaging studies at short intervals.

Keywords: Cerebral imaging, diagnosis, glioblastoma, headache, magnetic resonance imaging, occult brain tumor

Introduction

Glioblastomas (GBs) are the most common malignant tumors of the brain with high mortality. Primary or *de novo* GBs are tumors with no evidence of a low-grade precursor tumor and are typically diagnosed in <3 months in 68% and <6 months in 86% of cases after the emergence of the first symptoms.^[1] Nevertheless, the presenting signs and symptoms of GBs manifest rapidly and exhibit differences owing to the tumor's location and expansion, displacement, or infiltrative destruction of the neural structures. These signs and symptoms include progressive and pulsating headaches, new-onset epileptic seizures, focal neurological deficits, and altered mental status.^[2] Magnetic resonance imaging (MRI) is the conventional noninvasive diagnostic tool for GBs.^[3] A typical GB exhibits central

necrosis, remarkable edema, mass effect, and a strong contrast enhancement indicating blood–brain barrier disruption on T1-weighted images, with a hyperintense appearance on T2-weighted images.

However, patients presenting with neurological symptoms, albeit with normal computed tomography (CT) or MRI findings, might be harboring occult brain tumors like GB.^[4] Notably, GBs can manifest variously. Notably, patients in whom the tumor was detected within days had exhibited acute neurological signs and symptoms, such as acute-onset transient hemiparesis,^[5] vomiting, headache, and seizure.^[6] Therefore, in patients with negative findings, the average time until a diagnosis could range from days^[5,6] to months.^[4,7]

This paper describes two cases of GBs diagnosed 3.5 and 4 months, respectively,

**Tayfun Hakan,
Erhan Çelikoglu**

Clinic of Neurosurgery, Fatih Sultan Mehmet Training and Research Hospital, Istanbul, Turkey

Address for correspondence:
Dr. Tayfun Hakan,
Clinic of Neurosurgery, Fatih Sultan Mehmet Training and Research Hospital, İçerenköy - Atasehir, 34752, Istanbul, Turkey.
E-mail: tayfunhakan@yahoo.com

This is an open access journal, and articles are distributed under the terms of the Creative Commons Attribution-NonCommercial-ShareAlike 4.0 License, which allows others to remix, tweak, and build upon the work non-commercially, as long as appropriate credit is given and the new creations are licensed under the identical terms.

For reprints contact: WKHLRPMedknow_reprints@wolterskluwer.com

How to cite this article: Hakan T, Çelikoglu E. Glioblastoma shortly after a normal conventional brain magnetic resonance imaging: A report of two cases and review of the literature. *Asian J Neurosurg* 2021;16:433-6.

Submitted: 23-Dec-2020 **Revised:** 07-Jan-2021
Accepted: 13-Mar-2021 **Published:** 28-May-2021

Access this article online

Website: www.asianjns.org

DOI: 10.4103/ajns.AJNS_553_20

Quick Response Code:



after an initial completely normal MRI imaging. Both patients presented with no neurological signs and symptoms even at their second admission, except for a headache.

Case Reports

Case 1

A 51-year-old woman presented with persistent right frontal headache. She was previously admitted to another medical center for her headache and discharged home with medication 4 months ago. Her initial cranial CT and magnetic resonance (MR) images were all within normal limits [Figure 1a-c]. Her neurological examination was unremarkable, but a mass lesion with heterogeneous contrast enhancement and necrosis was detected in the right frontal lobe on T1-weighted MR images of the patient. In addition, the T2-weighted images revealed hyperintense areas with severe edema [Figure 1d-f]. The patient underwent a right frontal craniotomy and gross total resection of the tumor, with a final pathological diagnosis of GB.

Case 2

A 60-year-old woman was admitted with a severe right-sided headache. She had a headache 3.5 months earlier and had undergone MR imaging with normal findings [Figure 2a and b]. The patient's neurological examination was within normal limits; however, she had an epileptic seizure just before the radiological examination. MR images revealed a well-demarcated mass lesion in the

right temporal lobe with strong contrast enhancement on T1-weighted images [Figure 2c]. In addition, the sulci were closed, and the midline structures were swollen because of edema in the right cerebral hemisphere. The patient underwent a right temporal craniotomy and gross total resection of the tumor, with a final pathological diagnosis of GB.

Discussion

The two cases presented herein reveal that even the most malignant and deadly brain tumors can remain occult on neuroimaging. Unfortunately, it took 3–4 months to detect brain tumors in these two women after their initial admissions, and a headache was still the only symptom in both patients at their second presentation. Notably, GBs are known to not exhibit any specific symptoms. However, any emergence of neurological deficit or onset of epileptic seizure should warrant an evaluation.^[4]

Several studies in the literature have described negative CT scan investigations at initial clinical presentations; however, a considerable number of these studies belong to the era with significantly lesser technological advancement.^[8-10] On the other hand, it is well known that the advent of MRI has not entirely improved the situation of delayed diagnosis of occult brain tumors,^[4,7] and there are insufficient data to determine the precise point of radiographic transformation of the tumors – from the last “negative” image to the first “positive” image.^[4] Typically, GBs might not be radiologically detected until they cause visible changes in the cerebral tissue or

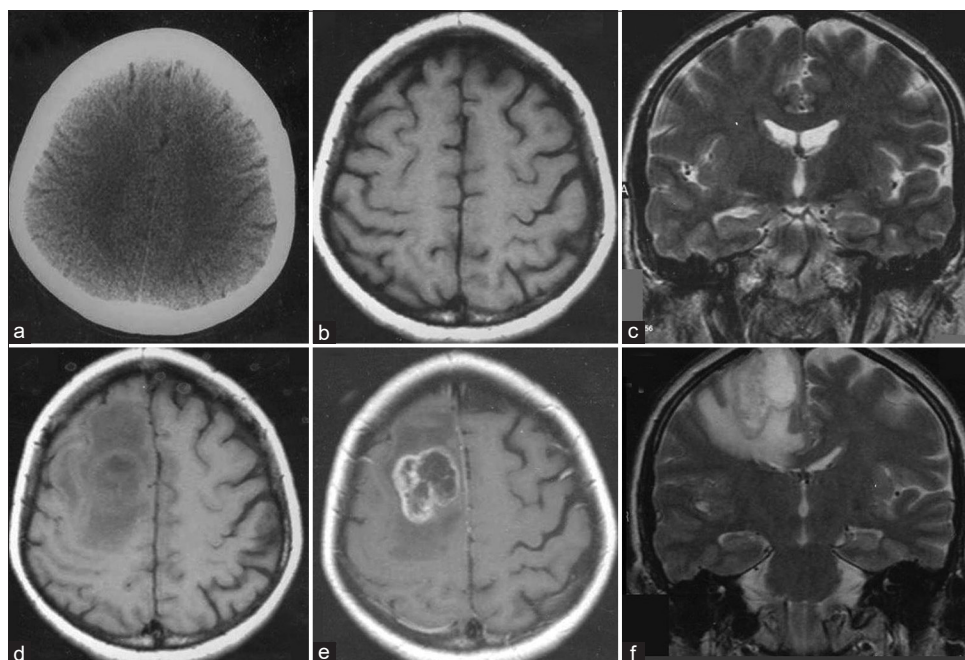


Figure 1: Case 1. Initial noncontrast axial computed tomography (a) and T1-weighted (b), and coronal T2-weighted magnetic resonance imaging (c) with no abnormality. Noncontrast T1-weighted magnetic resonance imaging demonstrated a mass lesion in the right frontal lobe (d), with heterogeneous contrast enhancement and necrosis on postcontrast axial T1-weighted magnetic resonance imaging (e) and hyperintense areas with strong edema on coronal T2-weighted magnetic resonance imaging (f) 4 months later

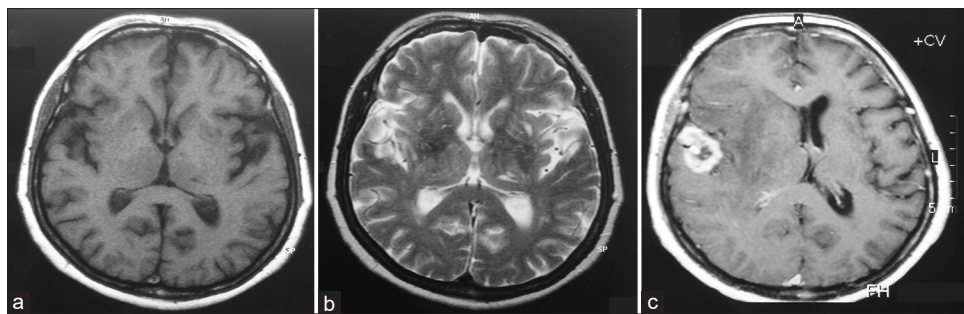


Figure 2: Case 2. Initial noncontrast axial T1-weighted (a) and T2-weighted magnetic resonance imaging (b) with no abnormality. A well-demarcated mass lesion in the right temporal lobe showing strong contrast enhancement on T1-weighted magnetic resonance imaging (c) 3.5 months later; the sulci were closed and midline structures were swollen because of edema in the right cerebral hemisphere

structural abnormalities.^[8] Therefore, most often, it is impossible to accurately diagnose occult tumors even though some clues are observed on MRI, such as poorly demarcated lesions; inhomogeneous hyperintensity on T2-weighted images with diffuse perilesional edema;^[11] hyperintensity involving the cortex, subcortical, or both on T2-weighted MRI images;^[3] subtle hyperintense areas;^[12] multiple nonenhancing abnormalities; and T2-weighted hyperintensity.^[7] Moreover, the radiological features of GB lesions are either not recognized or misdiagnosed as a demyelinating process, cerebral infarction,^[11,13,14] encephalitis,^[11,13] and venous thrombosis.^[13] Therefore, a mass exhibiting heterogeneous enhancement, central necrosis, and ill-defined, small isointense-to-hypointense lesions on T1-weighted and hyperintense lesion on T2-weighted images without edema and contrast enhancement should be considered typical for developing GBs.^[11,13]

It was reported that advanced MRI techniques to evaluate the physiological or metabolic properties of lesions, such as diffusion-weighted imaging (DWI) and perfusion-weighted imaging (PWI), and to measure cerebral blood volume, such as dynamic susceptibility contrast MRI, may help to locate the extremely small tumor nests that remain undetected.^[15,16] Although Ideguchi *et al.*^[13] found no abnormalities in the outcomes of DWI performed on a patient presenting with a headache in the left frontal lobe, Baehring *et al.*^[15] showed that increased signal intensity on DWI was very useful in identifying early stage of malignant gliomas. Furthermore, MR spectroscopy (MRS) and positron emission tomography (PET) with ¹¹C-methionine (MET) (MET-PET) are very valuable imaging techniques for patients with any identifiable or challenging lesions.^[16,17] Increased choline and reduced N-acetylaspartate levels detected and revealed MET uptake in the lesion in MRS and MET-PET, respectively, are important indicators for GBs.^[17] Currently, standard brain MR imaging protocols in most radiology centers include DWI but not PWI. It is clear that the use of modern supplementary MR sequences with PET and MET-PET may facilitate accurate and early diagnosis of these tumors, especially in suspicious or challenging cases.

Both cases presented here only had conventional MRI without advanced techniques, and no abnormal or suspicious radiological findings were detected until their second admission. The characteristic radiological appearance of brain malignancy was based on the findings of strong contrast enhancement and necrosis on T1-weighted images, and hyperintensity on T2-weighted images, and mass effect with edema on both. Nevertheless, GBs could have been detected earlier with repeated neuroimaging in both cases, and the patients could have been treated without any delay. Therefore, early diagnosis of GB is significant in that it provides a chance of timely treatment, including gross total resection, thereby prolonging the progression-free and overall survivals.^[18]

Therefore, new onset of seizures or a transient neurological deficit even in the absence of any other risk factor is recommended to be considered as glioma in patients, specifically those older than 40 years.^[9] Moreover, a single high-quality neuroimaging study performed in the emergency setting might be insufficient to detect all malignant primary brain tumors. Hence, it is advised that patients who present with new neurological symptoms should undergo repeat imaging studies even if they had normal radiological findings a short time before.^[4,7,13] Chittiboyna *et al.*^[4] reported that the seizures were crucial indicators of shorter time to imaging diagnosis and a worse tumor grade.

Conclusions

GBs might clinically reveal themselves before they emerge radiologically, even if they are not recognized. Therefore, it should be borne in mind that persistent headache could be the only sentinel sign of GBs before they become radiologically visible. Hence, follow-up imaging studies should be performed at short intervals to accurately diagnose the tumor and provide timely treatment to patients because even a single symptom-free moment can provide priceless peace of mind to these patients.

Acknowledgments

Preparation for publication of this article is partly supported by the Turkish Neurosurgical Society.

Declaration of patient consent

The authors certify that they have obtained all appropriate patient consent forms. In the form, the patients have given their consent for their images and other clinical information to be reported in the journal. The patients understand that their names and initials will not be published and due efforts will be made to conceal their identity, but anonymity cannot be guaranteed.

Financial support and sponsorship

Nil.

Conflicts of interest

There are no conflicts of interest.

References

- Ohgaki H, Kleihues P. Genetic pathways to primary and secondary glioblastoma. *Am J Pathol* 2007;170:1445-53.
- Weller M, van den Bent M, Tonn JC, Stupp R, Preusser M, Cohen-Jonathan-Moyal E, *et al.* European Association for Neuro-Oncology (EANO) guideline on the diagnosis and treatment of adult astrocytic and oligodendroglial gliomas. *Lancet Oncol* 2017;18:e315-29.
- Toh CH, Castillo M. Early-stage glioblastomas: MR imaging-based classification and imaging evidence of progressive growth. *AJNR Am J Neuroradiol* 2017;38:288-93.
- Chittiboina P, Connor DE, Caldito G, Quillin JW, Wilson JD, Nanda A. Occult tumors presenting with negative imaging: Analysis of the literature: A review. *J Neurosurg* 2021;116:1195-203.
- Schröter N, Lützen N, Doostkam S, Berger B. Glioblastoma evolving within 10 days following unremarkable computer tomography of the brain: A case report. *Int J Neurosci* 2020;1-4. doi: 10.1080/00207454.2020.1753730.
- Khalatbari MR, Hamidi M, Moharamzad Y. Glioblastoma multiforme with very rapid growth and long-term survival in children: Report of two cases and review of the literature. *Childs Nerv Syst* 2011;27:1347-52.
- Thaler PB, Li JY, Isakov Y, Black KS, Schulner M, Demopoulos A. Normal or non-diagnostic neuroimaging studies prior to the detection of malignant primary brain tumors. *J Clin Neurosci* 2012;19:411-4.
- Bolender NF, Cromwell LD, Graves V, Margolis MT, Kerber CW, Wendling L. Interval appearance of glioblastomas not evident in previous CT examinations. *J Comput Assist Tomogr* 1983;7:599-603.
- Hylton PD, Reichman OH. Clinical manifestation of glioma before computed tomographic appearance: The dilemma of a negative scan. *Neurosurgery* 1987;21:27-32.
- Tentler RL, Palacios E. False-negative computerized tomography in brain tumor. *JAMA* 1977;238:339-40.
- Wang H, Liu Z, Zhang Y, Hou F, Fu W, Lin J, *et al.* Additional diagnostic value of unenhanced computed tomography plus diffusion-weighted imaging combined with routine magnetic resonance imaging findings of early-stage glioblastoma. *Biomed Res Int* 2020;2020:1672736.
- Okamoto K, Ito J, Takahashi N, Ishikawa K, Furusawa T, Tokiguchi S, *et al.* MRI of high-grade astrocytic tumors: Early appearance and evolution. *Neuroradiology* 2002;44:395-402.
- Ideguchi M, Kajiwara K, Goto H, Sugimoto K, Nomura S, Ikeda E, *et al.* MRI findings and pathological features in early-stage glioblastoma. *J Neurooncol* 2015;123:289-97.
- Oyama H, Ando Y, Aoki S, Kito A, Maki H, Hattori K, *et al.* Glioblastoma detected at the initial stage in its developmental process - Case report. *Neurol Med Chir (Tokyo)* 2010;50:414-7.
- Baehring JM, Bi WL, Bannykh S, Piepmeyer JM, Fulbright RK. Diffusion MRI in the early diagnosis of malignant glioma. *J Neurooncol* 2007;82:221-5.
- Wen PY, Weller M, Lee EQ, Alexander BM, Barnholtz-Sloan JS, Barthel FP, *et al.* Glioblastoma in adults: A Society for Neuro-Oncology (SNO) and European Society of Neuro-Oncology (EANO) consensus review on current management and future directions. *Neuro Oncol* 2020;22:1073-113.
- Hishii M, Matsumoto T, Arai H. Diagnosis and treatment of early-stage glioblastoma. *Asian J Neurosurg* 2019;14:589-92.
- Sanai N, Polley MY, McDermott MW, Parsa AT, Berger MS. An extent of resection threshold for newly diagnosed glioblastomas. *J Neurosurg* 2011;115:3-8.