

PIK3CA mutation in non-metastatic triple-negative breast cancer as a potential biomarker of early relapse: A case report

Guillermo Arturo Valencia, Patricia Rioja, Zaida Morante, Jhajaira M Araujo, Heberth Daniel Vallejos, Henry Guerra, Henry L Gomez

ORCID number: Guillermo Arturo Valencia 0000-0002-4234-4448; Patricia Rioja 0000-0003-3141-7418; Zaida Morante 0000-0001-9725-9278; Jhajaira M Araujo 0000-0002-9639-8070; Heberth Daniel Vallejos 0000-0002-0517-0979; Henry Guerra 0000-0002-4894-5631; Henry L Gomez 0000-0003-2660-1843.

Author contributions: Valencia GA wrote the paper and collected data; All the authors analyzed the data and approve the final manuscript.

Informed consent statement: Informed written consent was obtained from the patient for publication of this manuscript, also the accompanying images.

Conflict-of-interest statement: The authors declare that they have no conflict of interest.

CARE Checklist (2016) statement: The authors have read the CARE Checklist (2016), and the manuscript was prepared and revised according to the CARE Checklist (2016).

Open-Access: This article is an open-access article that was selected by an in-house editor and fully peer-reviewed by external reviewers. It is distributed in accordance with the Creative Commons Attribution

Guillermo Arturo Valencia, Patricia Rioja, Zaida Morante, Henry L Gomez, Department of Medical Oncology, Instituto Nacional de Enfermedades Neoplásicas, Lima 15000, Peru

Jhajaira M Araujo, Escuela de Medicina Humana, Universidad Privada San Juan Bautista, Lima 15067, Peru

Heberth Daniel Vallejos, Department of Medical Oncology, Russian Scientific Center of Radiology and Radiotherapy, Konkovo 117485, Moscow, Russia

Henry Guerra, Department of Pathology, Instituto Nacional de Enfermedades Neoplásicas, Lima 15000, Peru

Corresponding author: Guillermo Arturo Valencia, MD, Medical Assistant, Department of Medical Oncology, Instituto Nacional de Enfermedades Neoplásicas, Angamos Este Avenue 2520, Surquillo, Lima 15000, Peru. guillermo.valencia.mesias@gmail.com

Abstract

BACKGROUND

Currently, the detection of PIK3CA mutations is of special interest in personalized medicine because it is frequently found in triple-negative breast cancer (TNBC). The PI3KCA mutation is an independent negative prognostic factor for survival in metastatic breast cancer, and its prognostic value in liquid biopsy as a biomarker of treatment and early relapse is under investigation, both for metastatic disease and neoadjuvant scenario with curative intent.

CASE SUMMARY

A 54-year-old female patient with TNBC clinical stage IIIA, who, after receiving neoadjuvant chemotherapy (based on anthracyclines and taxanes), surgery, radiotherapy, and adjuvant capecitabine, was detected with a PI3KCA mutation in tissue and peripheral blood (ctDNA in liquid biopsy). After 10 mo, the patient had disease relapse of left cervical node disease.

CONCLUSION

The detection of PIK3CA mutation in TNBC after neoadjuvant treatment might be associated with early relapse or rapid disease progression.

Key Words: Triple-negative breast cancer; PIK3CA mutation; Liquid biopsy; Early relapse;

NonCommercial (CC BY-NC 4.0) license, which permits others to distribute, remix, adapt, build upon this work non-commercially, and license their derivative works on different terms, provided the original work is properly cited and the use is non-commercial. See: <http://creativecommons.org/licenses/by-nc/4.0/>

Manuscript source: Unsolicited manuscript

Specialty type: Medicine, research and experimental

Country/Territory of origin: Peru

Peer-review report's scientific quality classification

Grade A (Excellent): 0
Grade B (Very good): 0
Grade C (Good): C
Grade D (Fair): D
Grade E (Poor): 0

Received: May 10, 2021

Peer-review started: May 10, 2021

First decision: June 5, 2021

Revised: June 18, 2021

Accepted: July 12, 2021

Article in press: July 12, 2021

Published online: August 24, 2021

P-Reviewer: Teragawa H

S-Editor: Wang LL

L-Editor: Filipodia

P-Editor: Yuan YY



Biomarker; Case report

©The Author(s) 2021. Published by Baishideng Publishing Group Inc. All rights reserved.

Core Tip: This case report evaluates the detection of a PIK3CA mutation in liquid biopsy and tumor tissue in a patient with locally-advanced triple-negative breast cancer after receiving conventional oncological therapy and its association with early relapse and progression disease. This case highlights the importance of detecting the PIK3CA mutation as a potential biomarker of early relapse. In addition, the PIK3CA mutation could lead to additional interventions to detect metastatic disease earlier in the follow-up. There is limited information of liquid biopsy studies after surgery. Furthermore, there is very limited data about trials of PIK3CA mutations in Peruvian patients with non-metastatic breast cancer.

Citation: Valencia GA, Rioja P, Morante Z, Araujo JM, Vallejos HD, Guerra H, Gomez HL. PIK3CA mutation in non-metastatic triple-negative breast cancer as a potential biomarker of early relapse: A case report. *World J Clin Oncol* 2021; 12(8): 702-711

URL: <https://www.wjgnet.com/2218-4333/full/v12/i8/702.htm>

DOI: <https://dx.doi.org/10.5306/wjco.v12.i8.702>

INTRODUCTION

Triple-negative breast cancer (TNBC) is a highly heterogeneous disease, with limited options of medical treatment. Currently, there is a great interest in the need to investigate the presence of predictive and/or prognostic biomarkers, as well as new personalized therapies. Despite the initial sensitivity to neoadjuvant chemotherapy, TNBC patients are more likely than other subtypes to develop relapse within the first 3 years after diagnosis, both distantly and locally, usually with visceral and brain metastases[1].

The phosphatidylinositol-3-kinase (PI3K)/AKT signaling pathway is activated in some cancers (including breast cancer) and is important not only as a biomarker, but also as a possible therapeutic target in TNBC. Large-scale genomic analyses have characterized the heterogeneous nature of this subtype, identifying a subgroup with activation of the PI3K/AKT pathway through somatic mutations in the PIK3CA gene, which induces tumorigenesis and angiogenesis[2]. PIK3CA mutations are found in a 28%-40% of patients with breast cancer, while in the luminal androgen receptor TNBC subtype (associated with high mutational load), it presents mutations enriched in PIK3CA up to a 55%[3-5]. The complexity of the PI3K pathway, as well as the presence of multiple mediators within the same signaling pathway, explain part of the resistance to treatment, as well as the risk of disease relapse. The PIK3CA mutation is considered an independent negative prognostic factor in advanced breast cancer. It can be detected using tumor tissue or liquid biopsy[6].

CASE PRESENTATION

Chief complaints

Fifty-four-year-old female patient, postmenopausal, with a family history of a maternal aunt with breast cancer (62 years).

History of present illness

Patient detected a tumor in her left breast of 3 years of evolution, without pain, without nipple involvement nor changes in color.

History of past illness

The patient has controlled hypertension and diabetes mellitus.

Physical examination

Clinical examination showed an Eastern Cooperative Oncology Group (ECOG) performance status of 1. Lymphatics: 6 cm left axillary conglomerate. Breasts: Two tumors in the left breast, one in R12 of 5.5 cm, at 2 cm from the nipple, the other in R2 of 2.5 cm, without skin involvement.

Imaging examinations

The mammography and breast ultrasound showed signs suggestive of left breast multicentric compromise associated with ipsilateral nodal involvement. The Breast Imaging-Reporting and Data System (BIRADS) score was 6.

Chest computer tomography (CT) showed signs suggestive of a malignant neoplastic process of the left breast associated with ipsilateral nodal involvement (Figure 1). Abdominal CT and bone scans were without metastatic lesions.

Pathology

The core biopsy of the left breast reported the following: The R12 lesion (Figure 2) corresponds to an infiltrating carcinoma of the breast, invasive ductal carcinoma not otherwise specified (NOS)/invasive breast carcinoma of no special type (NST) with lobular pattern infiltration areas, and histological grade noted high, lymphovascular invasion was present, but perineural invasion was not observed. Immunohistochemistry analysis determined that the tumor was negative for estrogen receptor (ER), progesterone receptor (PR), *cerbB2* (or human epidermal growth factor, HER2), positive for e-cadherin, and had 60% positive for *ki67* (Figure 3). The lesion in R2 corresponds to an infiltrating carcinoma of the breast, NOS/NST with areas of infiltration of lobular pattern, and histological grade noted that neither high, lymphovascular infiltration or perineural invasion were observed. Immunohistochemistry analysis had similar characteristics to those described in radius 12 (R12; clockwise), with negative staining for ER, PR, *cerbB2*, positive for e-cadherin, and 60% positive for *ki67*. In both lesions, significant intertumoral lymphocytic population less than 10% was not identified.

FINAL DIAGNOSIS

The final diagnosis was TNBC IIIA with left breast multicentric compromise.

TREATMENT

The patient began standard neoadjuvant therapy (NAT) (doxorubicin-cyclophosphamide for 4 courses, followed by weekly paclitaxel for 12 wk) reaching partial clinical response (R12: tumor 4 cm × 2 cm, R2: 1.5 cm tumor, left axillary node: 2 cm × 2 cm).

The patient underwent a modified radical mastectomy with radical axillary dissection. The biopsy indicated that R12 was an infiltrating ductal carcinoma, NOS/NST, histological grade III, with lymphovascular infiltration. The larger diameter of the invasive component showed the following: 40 mm × 32 mm, pT2 (Figure 4), free section borders, immunohistochemistry in relation to TNBC. In R2, a TNBC of similar characteristics to the pathology of R12 was reported, with a larger diameter of the invasive component of 6 mm × 4 mm. Macrometastases and extracapsular extension of lymph nodes 12 and 16 were detected, pN3a (Figure 5). The residual cancer burden group after neoadjuvant therapy (NAT) was III. In addition, tumor-infiltrating lymphocytes (TILs) were performed on residual tissue (post-neoadjuvant scenario), with a count of less than 10% (Figure 6). CD8 Lymphocyte staining showed a count of 40% (Figure 7).

Subsequently, the patient received external radiotherapy at a dose of 5000 cGy in 25 sessions at the level of the left rib cage and ipsilateral supraclavicular region, and continued with adjuvant capecitabine, completing 6 mo of treatment. She has continued with follow-up since May 2018 after negative images for the disease.

After surgery, she was included in two biomarker local studies. The first research study, called "Evaluation of prognostic markers of survival and predictive of treatment response in cancer population through the first platform in Peru for the detection and gene determination without amplification of DNA or RNA", carried out an analysis in tumor tissue with nCounter® Pan Cancer from a panel that included 770 genes,

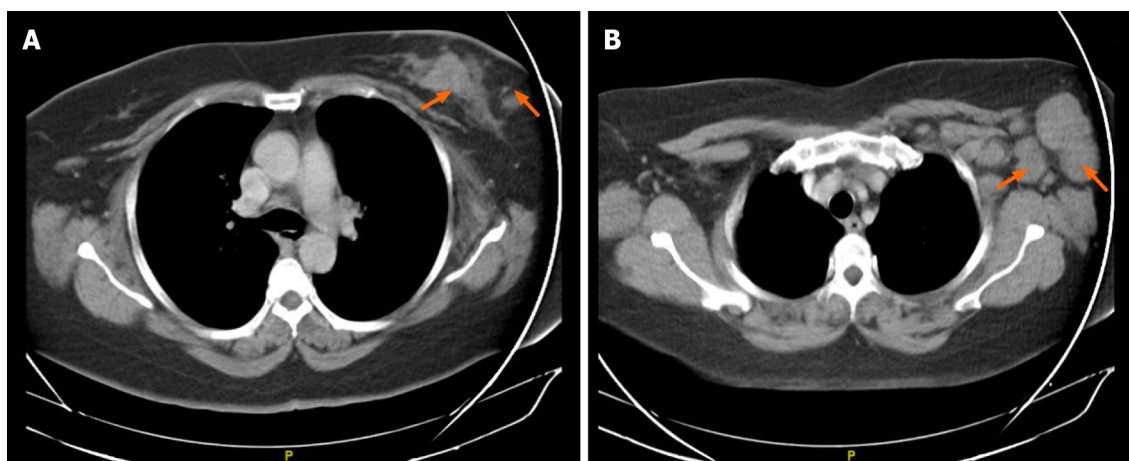


Figure 1 Chest computer tomography scan used as part of staging. A: Left breast with heterogeneous area on the left side suggestive of a 38 mm malignant neoformative neoplasm; B: Associated with ipsilateral nodal involvement.

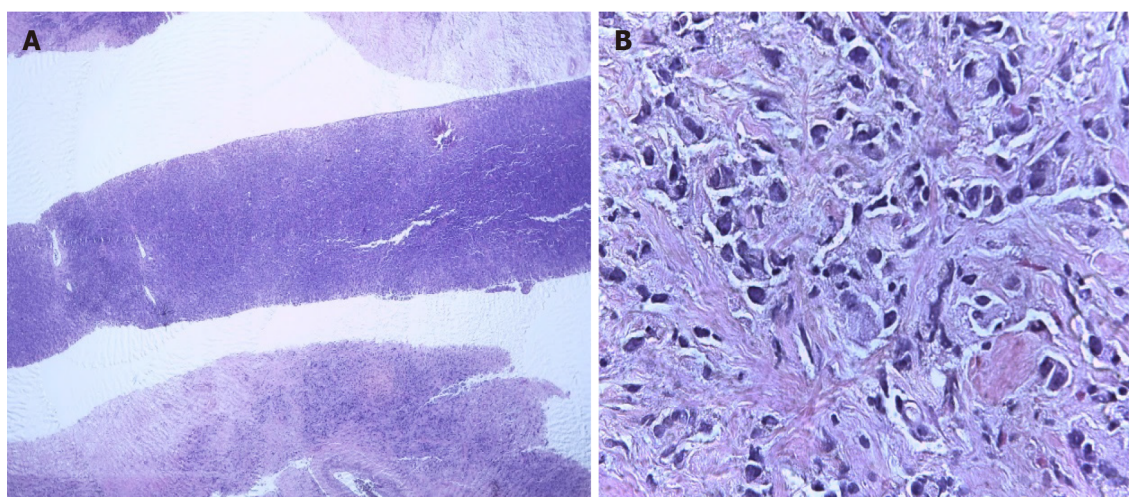


Figure 2 Core biopsy of the left breast. A: R12 tumor sample; B: Hematoxylin-eosin staining.

showed the presence of high “anergic” (exhausted) CD8 (Figure 8)[7].

The other study was conducted using a liquid biopsy and called: “Circulating tumor DNA as biomarkers in triple negative breast cancer”, resulted in the detection of PIK3CA H1047R (110 alpha), which was mutated, both in liquid biopsy (Figure 9) and in paraffin tissue (Figure 10)[8].

OUTCOME AND FOLLOW-UP

In March 2019, after a 10-mo disease-free interval, the patient’s disease relapsed with the presence of multiple lymphadenopathies in the left cervical region, the largest at 3 cm. Biopsy of the left cervical node indicated metastases of infiltrating primary breast carcinoma with an intermediate histological grade (Figure 11A), and immunohistochemistry analysis in relation to TNBC finding 60%-70% positive cells for ki67 (Figure 11B). However, chest and abdomen tomography without signs of visceral recurrence. Genetic counseling was requested, but the patient was negative for the BRCA mutation. The patient started chemotherapy with carboplatin-gemcitabine for 6 courses, reaching a complete clinical response and reassessment imaging without evidence of disease. She continued maintenance with gemcitabine.

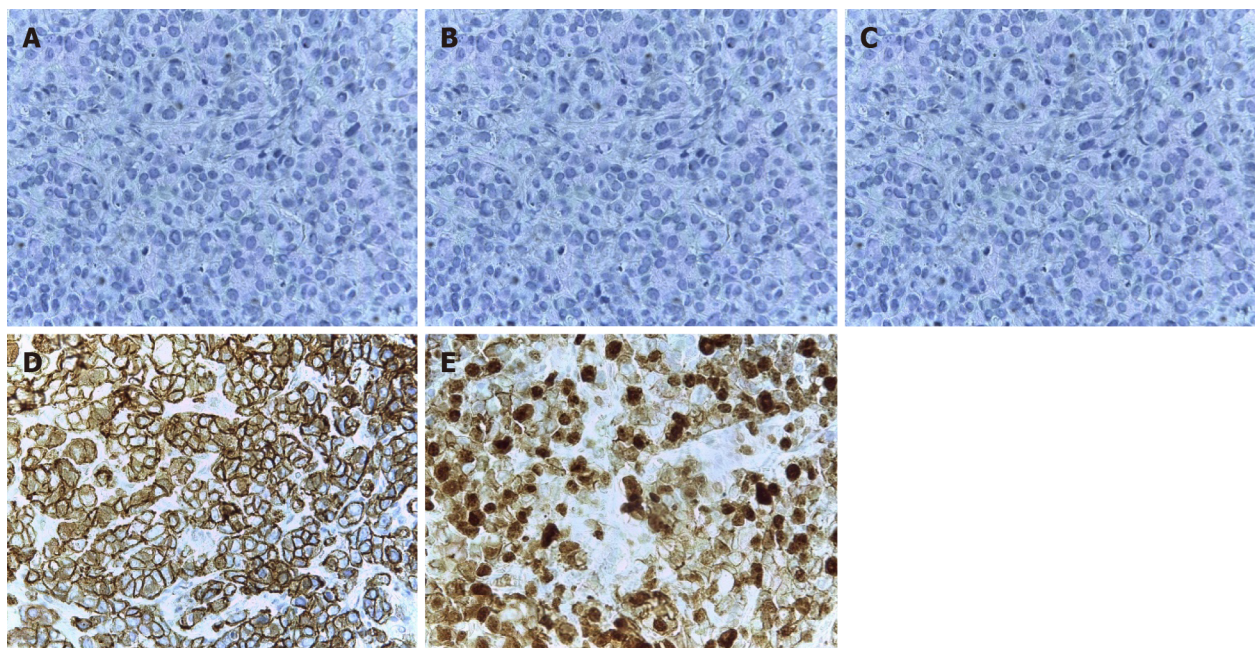


Figure 3 Immunohistochemistry of the R12 left breast. A: Estrogen receptor: Negative; B: Progesterone receptor: Negative; C: CerbB2: Negative; D: E-cadherin: Positive; E: Ki67: 60%.

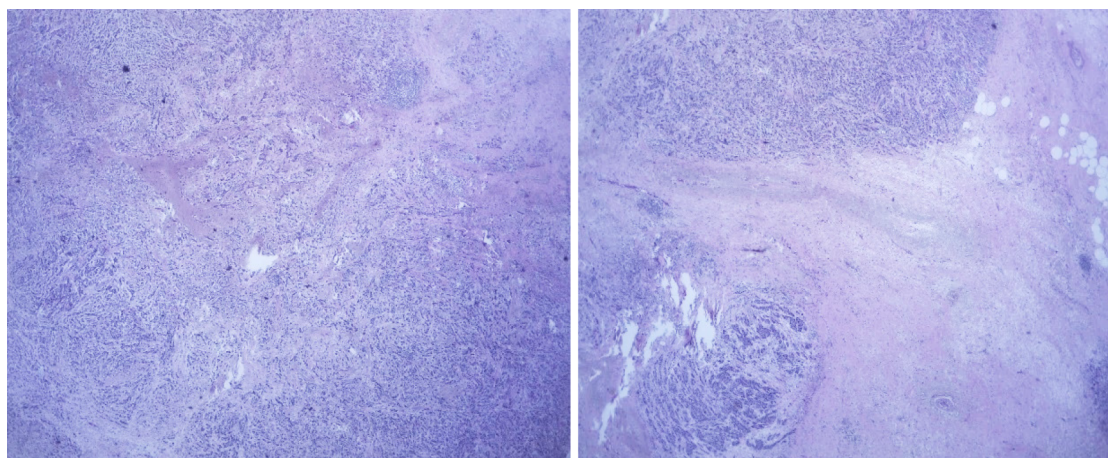


Figure 4 Surgical piece: R12 left breast tumor.

DISCUSSION

Patient with TNBC IIIA with left breast multicentric compromise, who, after receiving standard neoadjuvant treatment, followed by surgery, radiotherapy, and adjuvant capecitabine, presents cervical lymph node recurrence after a 10-mo disease-free interval. After surgery, she participated in 2 biomarker research studies, detecting the presence of a positive PIK3CA mutation in tumor tissue and peripheral blood (liquid biopsy).

The PI3K/AKT/mTOR pathway is an oncogenic intracellular pathway that regulates cell proliferation, metabolism, growth, survival, and apoptosis. The PIK3CA mutation, being the most common of the PI3K/AKT signaling pathway amplifications, is present in all molecular subtypes of breast cancer, and is detected in 20%-25% of all cases[2]. Although these individual mutations are rare, the combined activated mutations in PIK3CA and AKT1, with inactivating mutations in PTEN (a tumor suppressor gene that is inactivated when mutations are detected), occur in 25%-30% of metastatic TNBC (mTNBC)[2]. It has been determined that the PIK3CA mutation has an independent negative prognostic value of survival, as a systematic review has shown that patients with breast cancer and high levels of ctDNA after receiving neoadjuvant treatment have early disease relapse[9-11].

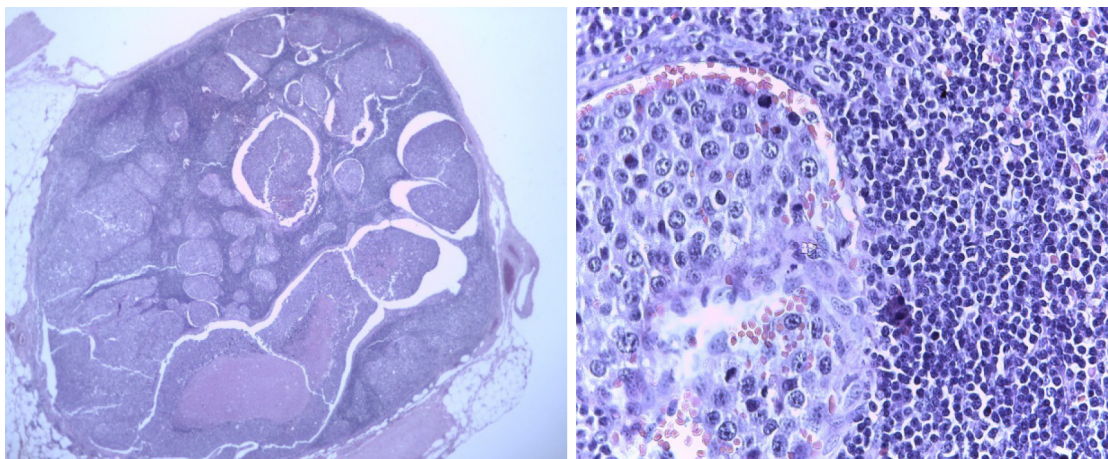


Figure 5 Surgical piece: Left axillary node.

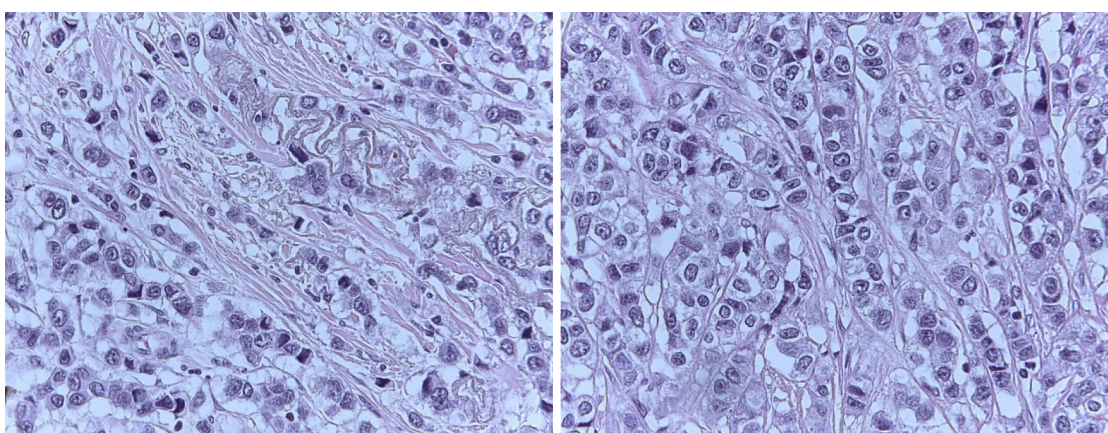


Figure 6 Tumor-infiltrating lymphocytes in residual tissue (post-neoadjuvant scenario): Less than 10%.

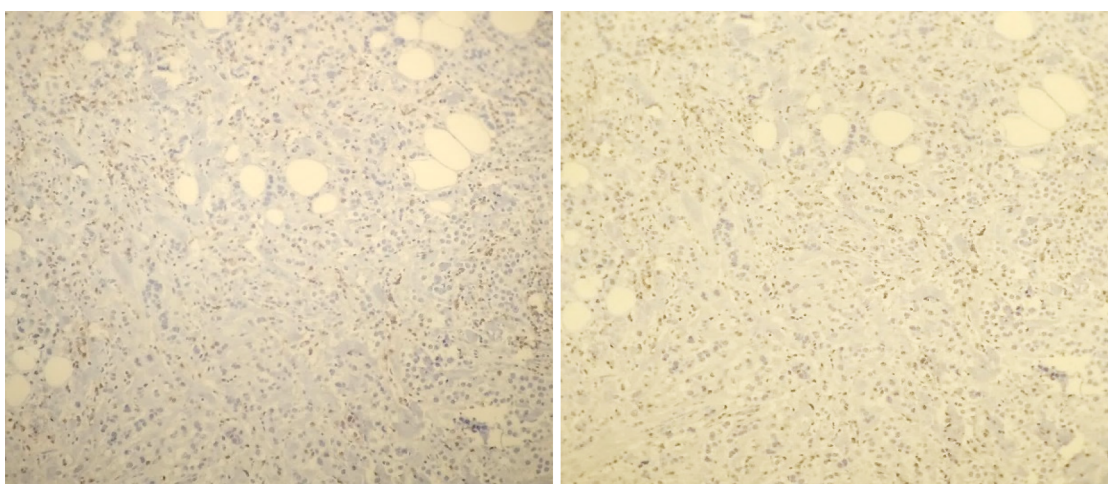


Figure 7 CD8 staining (× 10 magnification): 40%.

Liquid biopsy is being evaluated in breast cancer as a potential tool to capture tumor evolution in real time, to guide and monitor systemic treatment, as well as being a promising method to identify drug resistance mechanisms through the detection of genomic alterations[9,10]. ctDNA corresponds to a small fraction (0.01%-10%) of short cell-free DNA fragments from tumors and are detectable in body fluids (for example: Blood, saliva, or urine)[11]. In TNBC, there is evidence that evaluation of

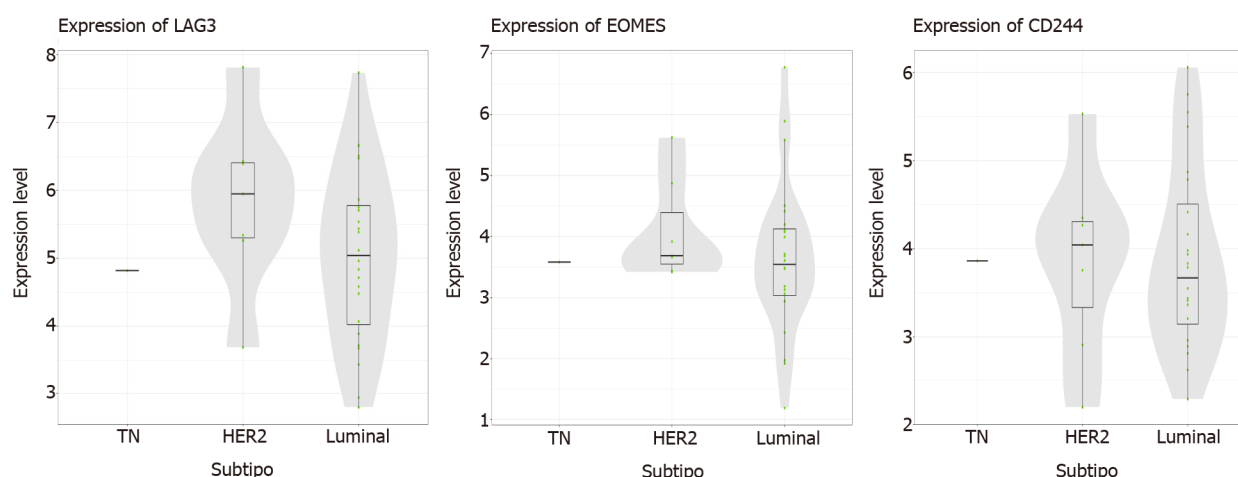


Figure 8 List of genes determining the presence of anergic CD8 cells (“exhausted”): “high” result, from the nCounter® PanCancer Immune Profiling Panel platform.

Liquid biopsy

PIK3CA E542K (110 alpha): no mutated
PIK3CA E545K (110 alpha): no mutated
PIK3CA H1047R (110 alpha): **mutated**

PIK3CA H1047R
(Puntos azules indican presencia de la mutación)
DE COPIAS = 0.687 copias/uL

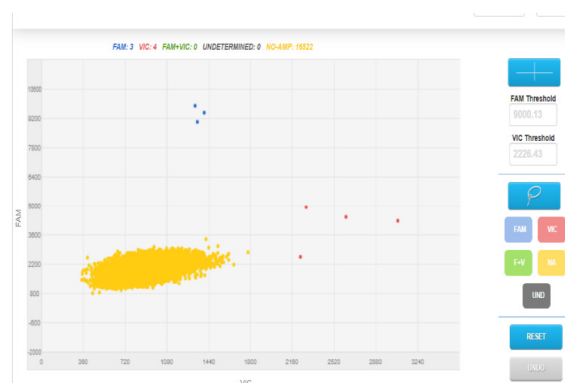


Figure 9 Liquid biopsy, PIK3CA 110 alpha result: Mutated.

Paraffined tissue

PIK3CA E542K (110 alpha): no mutated
PIK3CA E545K (110 alpha): no mutated
PIK3CA H1047R (110 alpha): **mutated**

PIK3CA H1047R (Curva de amplificación)
#Copias = 400 copias/uL
Fecha: 30/09/2017

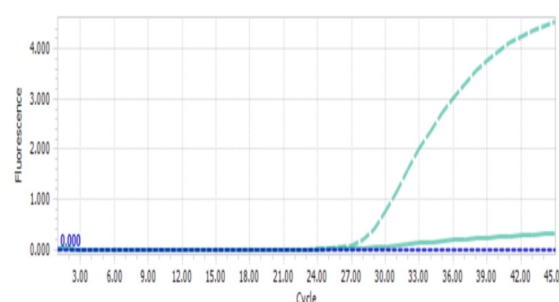


Figure 10 Paraffined tissue, PIK3CA 110 alpha result: Mutated.

mutated PIK3CA in circulating tumor DNA (ctDNA) using liquid biopsy has a potential prognostic value as a biomarker, including diagnosis and follow-up during treatment (response to NAT)[12,13]. Furthermore, in the early disease scenario (with curative intention), its value for monitoring during treatment has been demonstrated, as well as for detecting relapse and early metastasis, as happened in our patient[12, 13]. Some trials have demonstrated the potential of ctDNA in peripheral blood (both early and metastatic disease) for diagnosis, treatment, and prognosis[14]. There are currently no guidelines or regulatory approvals to monitor response in breast cancer patients[15].

Novel trials has shown that ctDNA has a prognostic value in TNBC, predicting minimal residual disease (MRD) and early relapse after neoadjuvant chemotherapy with curative intent with high specificity[16,17]. ctDNA detection is useful for mo-

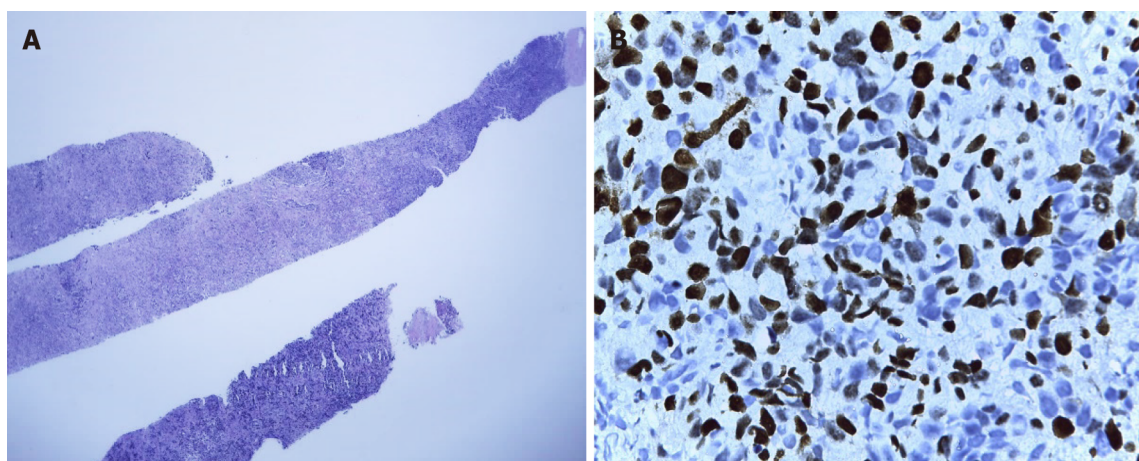


Figure 11 Biopsy of the left axillary node. A: Compatible with metastases of infiltrating primary breast carcinoma; B: Immunohistochemistry in relation to triple-negative breast cancer tumor (ki67: 60%-70%).

monitoring micrometastases or MRD after neoadjuvant chemotherapy and surgery with apparent curative intent in patients with early breast cancer either at a single point (post-surgery) or with serial plasma samples (during follow-up). Consistently, post-surgical levels of ctDNA were found to be predictive of poor prognosis and risk of relapse[16,17]. In one trial, detection of PIK3CA mutation using post-surgical ctDNA predicted disease relapse after 8.1 mo of follow-up[16]. Another trial demonstrated the ability of ctDNA to identify patients at risk of relapse [23/26 patients who relapsed (88.4%) had a history of ctDNA detection with a median time of 10.7 mo before clinical relapse][18]. These results regarding time to early relapse are very similar with our patient. Moreover, the BRE 12-158, a phase II trial presented at the San Antonio Breast Cancer Symposium 2019, showed that the presence of frequent mutations in breast cancer detected by ctDNA and circulating tumor cells are useful to predict recurrence after neoadjuvant chemotherapy in patients with early TNBC. ctDNA was detected in 64% of samples, and TP53 was the most frequent gene. ctDNA was associated with poor distant disease-free survival (DDFS): after 24 mo, the likelihood of DDFS was 25% worse in patients with positive ctDNA (56%) *vs* those with negative ctDNA (81%) (hazard ratio [HR]: 2.99, 95% confidence interval [CI]: 1.38-6.48, $P = 0.0055$). Women with positive ctDNA have 3 times the risk of developing distant disease recurrence compared to those with negative ctDNA (disease-free survival: HR: 2.67, 95%CI: 1.28-5.57, $P = 0.0069$). Furthermore, ctDNA-positive women had a 4.1-fold higher risk of death compared to ctDNA-negative women (overall survival: HR: 4.16, 95%CI: 1.66-10.42, $P = 0.0024$)[19].

Although there is a positive PIK3CA mutation result in this case report, to date, there are no standardized procedures for PIK3CA detection in breast cancer in Peru. Therefore, the application of ctDNA should be based on defined protocols to ensure reproducibility of results, due to mostly undetectable levels of ctDNA in early breast cancer[20]. Finally, it is not known whether the presence of the PIK3CA mutation in peripheral blood and tumor tissue confers a worse prognosis compared to having the mutation in 1 of the 2 samples evaluated (blood, tissue). These findings could increase the interval of control visits or earlier approaches for follow-up to detect local or distant relapse.

CONCLUSION

From the perspective of Personalized Medicine, it is important to characterize the genetic profile of tumors, either in liquid biopsy and/or tumor tissue, in order to detect potential biomarkers and subsequently new targeted therapies. In the case report, the detection of the PIK3CA mutation in a patient with locally advanced TNBC after neoadjuvant treatment and surgery may be associated with an early relapse of disease. Many trials have shown the value of detecting the PIK3CA mutation in liquid biopsy (ctDNA) in patients with TNBC as a potential biomarker for identifying early relapse and disease progression. The detection of PIK3CA mutations might help identify patients at risk of recurrence, and it could also generate closer therapeutic or

follow-up behaviors in order to detect micro metastatic disease/MRD and distant disease.

REFERENCES

- 1 **Khosravi-Shahi P**, Cabezon-Gutiérrez L, Aparicio Salcedo MI. State of art of advanced triple negative breast cancer. *Breast J* 2019; **25**: 967-970 [PMID: [31155832](#) DOI: [10.1111/tbj.13369](#)]
- 2 **Millis SZ**, Gatalica Z, Winkler J, Vranic S, Kimbrough J, Reddy S, O'Shaughnessy JA. Predictive Biomarker Profiling of > 6000 Breast Cancer Patients Shows Heterogeneity in TNBC, With Treatment Implications. *Clin Breast Cancer* 2015; **15**: 473-481.e3 [PMID: [26051240](#) DOI: [10.1016/j.clbc.2015.04.008](#)]
- 3 **Bareche Y**, Venet D, Ignatiadis M, Aftimos P, Piccart M, Rothe F, Sotiriou C. Unravelling triple-negative breast cancer molecular heterogeneity using an integrative multiomic analysis. *Ann Oncol* 2018; **29**: 895-902 [PMID: [29365031](#) DOI: [10.1093/annonc/mdy024](#)]
- 4 **Lehmann BD**, Bauer JA, Schafer JM, Pendleton CS, Tang L, Johnson KC, Chen X, Balko JM, Gómez H, Arteaga CL, Mills GB, Sanders ME, Pietenpol JA. PIK3CA mutations in androgen receptor-positive triple negative breast cancer confer sensitivity to the combination of PI3K and androgen receptor inhibitors. *Breast Cancer Res* 2014; **16**: 406 [PMID: [25103565](#) DOI: [10.1186/s13058-014-0406-x](#)]
- 5 **Jiang YZ**, Ma D, Suo C, Shi J, Xue M, Hu X, Xiao Y, Yu KD, Liu YR, Yu Y, Zheng Y, Li X, Zhang C, Hu P, Zhang J, Hua Q, Hou W, Ren L, Bao D, Li B, Yang J, Yao L, Zuo WJ, Zhao S, Gong Y, Ren YX, Zhao YX, Yang YS, Niu Z, Cao ZG, Stover DG, Verschraegen C, Kaklamani V, Daemen A, Benson JR, Takabe K, Bai F, Li DQ, Wang P, Shi L, Huang W, Shao ZM. Genomic and Transcriptomic Landscape of Triple-Negative Breast Cancers: Subtypes and Treatment Strategies. *Cancer Cell* 2019; **35**: 428-440.e5 [PMID: [30853353](#) DOI: [10.1016/j.ccell.2019.02.001](#)]
- 6 **Sobhani N**, Roviello G, Corona SP, Scaltriti M, Ianza A, Bortul M, Zancanati F, Generali D. The prognostic value of PI3K mutational status in breast cancer: A meta-analysis. *J Cell Biochem* 2018; **119**: 4287-4292 [PMID: [29345357](#) DOI: [10.1002/jcb.26687](#)]
- 7 **Castaneda C**. Evaluation of prognostic markers of survival and predictive of response to treatment in a population with cancer using the first platform in Peru for the detection and determination of gene expression without DNA or RNA amplification. INNOVATE- PERU EC-4-P-028-17. Executive Summaries of Research Project Grants. 2013-2018. Peru [Internet]. Available from: http://portal.concytec.gob.pe/images/publicaciones/informes/subvenciones_proyectos_fondecyt_resumenes_ejecutivos_2013-2018-2-350_merged.pdf
- 8 **Castaneda C**. Circulating tumor cells and circulating tumor DNA as biomarkers in triple-negative breast cancer. FONDECYT N198-2015. Executive Summaries of Research Project Grants. 2013-2018. Peru [Internet]. Available from: http://portal.concytec.gob.pe/images/publicaciones/informes/subvenciones_proyectos_fondecyt_resumenes_ejecutivos_2013-2018-2-350_merged.pdf
- 9 **Rossi G**, Ignatiadis M. Promises and Pitfalls of Using Liquid Biopsy for Precision Medicine. *Cancer Res* 2019; **79**: 2798-2804 [PMID: [31109952](#) DOI: [10.1158/0008-5472.CAN-18-3402](#)]
- 10 **Schiavon G**, Hrebien S, Garcia-Murillas I, Cutts RJ, Pearson A, Tarazona N, Fenwick K, Kozarewa I, Lopez-Knowles E, Ribas R, Nerurkar A, Osin P, Chandarlapaty S, Martin LA, Dowsett M, Smith IE, Turner NC. Analysis of ESR1 mutation in circulating tumor DNA demonstrates evolution during therapy for metastatic breast cancer. *Sci Transl Med* 2015; **7**: 313ra182 [PMID: [26560360](#) DOI: [10.1126/scitranslmed.aac7551](#)]
- 11 **Koo KM**, Mainwaring PN. The role of circulating tumor DNA testing in breast cancer liquid biopsies: getting ready for prime time. *Breast Cancer Manag* 2020; **9** [DOI: [10.2217/bmt-2020-0003](#)]
- 12 **Loibl S**, Majewski I, Guarneri V, Nekljudova V, Holmes E, Bria E, Denkert C, Schem C, Sotiriou C, Loi S, Untch M, Conte P, Bernards R, Piccart M, von Minckwitz G, Baselga J. PIK3CA mutations are associated with reduced pathological complete response rates in primary HER2-positive breast cancer: pooled analysis of 967 patients from five prospective trials investigating lapatinib and trastuzumab. *Ann Oncol* 2016; **27**: 1519-1525 [PMID: [27177864](#) DOI: [10.1093/annonc/mdw197](#)]
- 13 **Yang J**, Nie J, Ma X, Wei Y, Peng Y, Wei X. Targeting PI3K in cancer: mechanisms and advances in clinical trials. *Mol Cancer* 2019; **18**: 26 [PMID: [30782187](#) DOI: [10.1186/s12943-019-0954-x](#)]
- 14 **Diehl F**, Schmidt K, Choti MA, Romans K, Goodman S, Li M, Thornton K, Agrawal N, Sokoll L, Szabo SA, Kinzler KW, Vogelstein B, Diaz LA Jr. Circulating mutant DNA to assess tumor dynamics. *Nat Med* 2008; **14**: 985-990 [PMID: [18670422](#) DOI: [10.1038/nm.1789](#)]
- 15 **Chen YH**, Hancock BA, Solzak JP, Brinza D, Scafe C, Miller KD, Radovich M. Next-generation sequencing of circulating tumor DNA to predict recurrence in triple-negative breast cancer patients with residual disease after neoadjuvant chemotherapy. *NPJ Breast Cancer* 2017; **3**: 24 [PMID: [28685160](#) DOI: [10.1038/s41523-017-0028-4](#)]
- 16 **Garcia-Murillas I**, Schiavon G, Weigelt B, Ng C, Hrebien S, Cutts RJ, Cheang M, Osin P, Nerurkar A, Kozarewa I, Garrido JA, Dowsett M, Reis-Filho JS, Smith IE, Turner NC. Mutation tracking in circulating tumor DNA predicts relapse in early breast cancer. *Sci Transl Med* 2015; **7**: 302ra133 [PMID: [26311728](#) DOI: [10.1126/scitranslmed.aab0021](#)]
- 17 **Buono G**, Gerrata L, Bulfoni M, Provinciali N, Basile D, Giuliano M, Corvaja C, Arpino G, Del Mastro L, De Placido S, De Laurentiis M, Cristofanilli M, Puglisi F. Circulating tumor DNA analysis

- in breast cancer: Is it ready for prime-time? *Cancer Treat Rev* 2019; **73**: 73-83 [PMID: [30682661](#) DOI: [10.1016/j.ctrv.2019.01.004](#)]
- 18 **Zhao W**, Qiu Y, Kong D. Class I phosphatidylinositol 3-kinase inhibitors for cancer therapy. *Acta Pharm Sin B* 2017; **7**: 27-37 [PMID: [28119806](#) DOI: [10.1016/j.apsb.2016.07.006](#)]
 - 19 **Radovich M**. Detection of circulating tumor DNA (ctDNA) after neoadjuvant chemotherapy is significantly associated with disease recurrence in early-stage triple-negative breast cancer (TNBC): Preplanned correlative results from clinical trial BRE12-158. Presented at the San Antonio Breast Cancer Symposium, San Antonio, Texas; December 10-14, 2019. Abstract: GS5-02 [Internet]. Available from: <https://clinicaltrials.gov/ct2/show/NCT02101385>
 - 20 **Benesova L**, Belsanova B, Suchanek S, Kopeckova M, Minarikova P, Lipska L, Levy M, Visokai V, Zavoral M, Minarik M. Mutation-based detection and monitoring of cell-free tumor DNA in peripheral blood of cancer patients. *Anal Biochem* 2013; **433**: 227-234 [PMID: [22750103](#) DOI: [10.1016/j.ab.2012.06.018](#)]



Published by **Baishideng Publishing Group Inc**
7041 Koll Center Parkway, Suite 160, Pleasanton, CA 94566, USA

Telephone: +1-925-3991568

E-mail: bpgoffice@wjgnet.com

Help Desk: <https://www.f6publishing.com/helpdesk>

<https://www.wjgnet.com>

