

The role of subgaleal suction drain placement in chronic subdural hematoma evacuation

Yad Ram Yadav, Vijay Parihar, Ishwar D. Chourasia¹, Jitin Bajaj, Hemant Namdev

Departments of Neurosurgery, NSCB Medical College, Jabalpur, ¹Gandhi Medical College, Bhopal, Madhya Pradesh, India

ABSTRACT

Introduction: There is lack of uniformity about the preferred surgical treatment, role of drain, and type of drain among various surgeons in chronic subdural hematoma (CSDH). The present study is aimed to evaluate role of subgaleal drain.

Materials and Methods: This was a prospective study of 260 patients of CSDH treated surgically. Burr-hole irrigation with and without suction drain was done in 140 and 120 patients, respectively. Out of 120 patients without suction drain 60 each were managed by single and two burr holes. Pre- and postoperative GCS was recorded. Recurrent hematomas, CSDH secondary to tumor, due to intracranial hypotension, coagulopathy, children below 18 years, and patients treated by twist drill craniostomy or craniotomy were excluded. Subgaleal closed-system drainage with low negative pressure was used.

Results: Age of the patients ranged from 18 to 75 years with mean age of 57 years. There were 9, 47, 204 patients in GCS of 3-8, 9-12, and 13-15, respectively. Both the groups were comparable in terms of age, etiology, gender, and neurological status. There was no difference in the mortality in both the group. The recurrence and postoperative pneumocephalus was significantly less in suction drain group as compared to without drain group. There was no infection or any other complication related to suction drainage.

Conclusion: Subgaleal closed suction drainage was safe, simple, and effective in the management of CSDH. Recurrence rate was low in the suction drain group.

Key words: Chronic subdural hematoma, intracranial subdural hematoma, operative surgical procedure, subdural hematoma, subgaleal drainage

Introduction

Chronic subdural hematoma (CSDH) is one of the most common neurosurgical conditions. The preferred surgical method continues to attract debate. There is lack of uniformity about the preferred surgical treatment (burr hole, twist drill, or the craniotomy) in CSDH among various surgeons. There is also disagreement about the use of irrigation and steroid.^[1,2] The

incidence of CSDH is increasing due to an increase in aging population, associated medical diseases such as hemodialysis, anticoagulant, and/or antiplatelet therapy.^[3,4]

Although surgical techniques are simple but the recurrence remains one of the challenges in the treatment. There is controversy whether the use of drain decreases incidence of recurrence. Various types of drains have been used. Limited information is available about the role of subgaleal suction drain in CSDH.^[5,6] The present study is aimed to evaluate the role of subgaleal suction drain in CSDH.

Materials and Methods

Between Jan 2008 and Dec 2010, a total of 260 patients with CSDH were treated surgically at a tertiary care center. This prospective study was approved by the institutional ethical committee and informed consent was obtained from all the patients. Symptomatic patients with diagnosis of CSDH of traumatic etiology were included based on the CT/MRI study of brain. Recurrent hematomas, bilateral hematomas, children below 18 years, CSDH due to coagulopathy, secondary to tumor

Access this article online

Quick Response Code:



Website:

www.asianjns.org

DOI:

10.4103/1793-5482.145096

Address for correspondence:

Dr. Yad Ram Yadav, Department of Neurosurgery, NSCB (Government) Medical College, Jabalpur, Madhya Pradesh, India. E-mail: yadavyr@yahoo.co.in

and due to intracranial hypotension were excluded. Patients treated by twist drill or craniotomy were Also excluded. Patients were assigned by a simple random sampling method into two groups. One hundred and twenty patients underwent burr-hole irrigation without suction drain, while 140 patients underwent single burr-hole irrigation with suction drainage. Out of 120 patients without suction drain, 60 patients each were treated by single and two burr holes. Clinical laboratory studies before surgery included bleeding time, platelet count, prothrombin time, activated partial thromboplastin time, serum biochemical analysis, etc. Pre- and postoperative GCS were recorded. Clinical outcome was measured using the Glasgow outcome scale (GOS) at discharge and at 3 and 6 months after surgery. CT scans were done in all the 260 patients, while MRI scans were done in 23 cases due to financial constrains.

All patients were kept in bed with 15-30° head end raised postoperatively. The drainage catheters were kept for 72 hours after surgery in all the cases. Postoperative CT scans were done on 5th postoperative day and at 6 weeks after surgery in all cases. If the symptoms or clinical findings failed to improve or got worse, a repeat CT was performed. If the amount of postoperative air was more than 1 cm thickness on 5th postoperative day scan, it was considered as significant pneumocephalus. The patient received parenteral antibiotics for the first 3 postoperative days. Prophylactic anticonvulsants were given in unconscious patients. Recurrence of CSDH was defined as reappearance of clinical symptoms with evidence of CSDH in the same site on CT head after a minimum period of 1 month after surgery. For statistical analysis, chi-square and Student *t*-tests were used.

Procedure

One burr hole of 16 mm diameter was performed in all the cases. Dura matter and outer membrane were incised, and the hematoma cavity was washed out by warm physiological saline until the fluid became clear. The subdural space was filled with isotonic saline at the end of irrigation. Suction drain was inserted into the subgaleal space. Some of the openings of the suction tube were facing burr hole [Figure 1]. The end of the drain was kept away from the burr hole site to avoid any accidental slippage of the tube in the subdural cavity.

About 5 cm space was created between galea and periosteum all around the burr hole using blunt finger dissection. The suction drain was taken out from about a 5 cm away from the scalp incision. Subgaleal closed-system drainage of low negative pressure was created and left in place. We used Romovac suction drain (Romson). The collecting bag capacity of 400 ml and the catheter size of 16 French gauges were used. To create a low negative pressure, the collecting chamber was depressed to about 25% of its height only. The scalp was closed in two layers.

Results

There were 188 male and 72 female patients. Age of the patients ranged from 18 years to 75 years with mean age of 57 years. Both the groups were comparable in terms of age, etiology, gender, and neurological status. History of trauma could be ascertained in all the cases, CSDH secondary to other etiologies were excluded to make both the groups comparable.

Gait disturbance, memory loss, hemiparesis, headache, speech impairment, drowsiness were presenting features. Preoperative GCS ranged from 4 to 15. There were 9, 47, 204 patients in GCS 3-8, 9-12 and 13-15, respectively. CT scan revealed mainly hypodense lesions in 137 patients. Mainly mixed density or isodense CT lesions were seen in 120 and 3 patients. MRI could be done in 23 cases only. MRI scan on T1 W were mainly hyperintense, mixed intensity, and hypointense in 18, 4, and 1 patients, respectively. Hematomas were located in frontal, parietal, occipital, fronto-parieto-occipital, and fronto-temporo-parieto-occipital regions in 15, 9, 11, 98 and 127 patients respectively.

All the patients except eight cases showed good recovery after surgery (134 in suction drain and 114 in the without drain group). Moderate disability was seen in four each in the suction group and the without suction drainage group [Table 1]. There were two deaths each in the suction group and the without suction group ($\chi^2 = 0.07488$; $P = 0.9632$). There was one postoperative death each in single and two burr-hole group in the without suction drainage group. All the deaths were due to poor preoperative status. The hospitalization period after

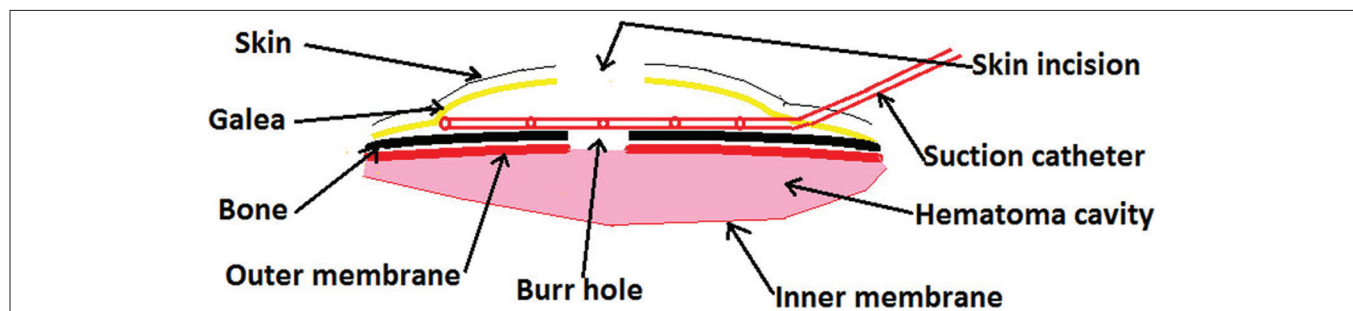


Figure 1: Line diagram showing placement of subgaleal suction drain

Table 1: A comparison of without and with suction drain groups

Groups	Suction drain group (N=140)	Without suction drain group (N=120)	Statistical analysis
Age	Ranged from 18 years to 75 years with mean age of 53±22.12	Ranged from 19 to 74 years mean 52±25.2	t=0.3407; P=0.7336
Gender	Male:Female 101:39	Male:Female 87:33	$\chi^2=0.0041$; P=0.9488
Preoperative GCS	Ranged from 4 to 15	Ranged from 4 to 15	$\chi^2=0.01915$; P=0.9905
3-8 (%)	5 (3.57)	4 (3.33)	
9-12 (%)	25 (17.86)	22 (18.33)	
13-15 (%)	110 (78.57)	94 (78.33)	
Out come (%)			$\chi^2=0.07488$; P=0.9632
Mortality	2 (1.43)	2 (1.67)	
Moderate disability	4 (2.86)	4 (3.33)	
Good recovery	134 (95.71)	114 (95.00)	
Recurrence	5 (3.57)	12 (10.00)	$\chi^2=4.37$; P=0.0366 95% CI=-0.4868, -0.036011
Postoperative significant pneumocephalus (%)	8 (5.71)	19 (15.83)	$\chi^2=7.1096$; P=0.0077
Postoperative seizures (%)	1 (0.71)	1 (0.83)	$\chi^2=0.012$; P=0.9128
Hospital stay	6.5±4.41 (range 5-19)	7±3.69 (range 4-20)	t=0.9810; P=0.3275

surgery was 6.5 (5-19) and 7 (4-20) days in the with and without drainage groups, respectively. The mean follow-up period was 21 months (4-40 months).

The recurrence rate was 3.57% (5 patients) and 10% (12 patients) in the suction drainage group and the without drainage group, respectively ($\chi^2 = 4.37$; P = 0.0366 95% CI, -0.4868, -0.036011). This difference was statistically significant. The recurrence was in 7 (11.67%) and 5 (8.33%) patients in single and two burr-hole group respectively in the without suction drain group. This difference in single and two burrhole group was statistically not significant. Significant postoperative pneumocephalus (one or more than 1 cm width) was observed in 8 (5.71%) and 19 (15.83%) patients in the suction drain group and the without suction group, respectively ($\chi^2 = 7.1096$; P = 0.0077). This difference was statistically significant. There was no infection or any other complication related to suction drainage. One patient each developed seizures in each group.

Discussion

Considerable body of evidence supporting the use of external drainage after evacuation of primary CSDH exists in the most of the reported series.^[7-12] Santarius *et al.*,^[10] Ramachandran *et al.*,^[13] Wakai *et al.*,^[14] Tsutsumi *et al.*,^[15] Gurelik *et al.*^[16] reported 9.3%, 4%, 5%, 3.1%, 10.5% recurrence rate in the drainage group as compared to 24%, 30%, 33%, 17%, and 19% respectively in the without drain group [Table 2]. Santarius *et al.*^[10] also reported lower 6 months mortality of 8.6% in the drain group as compared to 18.1% when drain was not used. On the other hand, there was no significant difference in the postoperative recurrence and the complications rates in the drainage group and the without drainage group in other studies.^[17,18] Advocates of no drain group argue that placing a drain could lead to complications such as brain injury,

Table 2: Recurrences rates in the drain and without drain groups in chronic subdural hematomas

Study	Recurrences with drain	Recurrences without drain
Ramchandran <i>et al.</i> 2007	4% (6/165)	30% (130/442)
Wakai <i>et al.</i> 1990	5%	33%
Santarius <i>et al.</i> 2009	9.3% (10/108)	24% (26/107)
Tsutsumi <i>et al.</i> 1997	3.1%	17%
Gurelik <i>et al.</i> 2007	10.5% (4/38)	19% (8/42)
Gazzeri <i>et al.</i> 2007	7.6% (17/224)	NA
Yu <i>et al.</i> 2009	6.6% (8/121). Recurrence was 16.3% (7/43) and 1.3% (1/78) in less than 3 days and 3 or more than 3 days drain, respectively	NA
Bellut <i>et al.</i> 2012	1.8 and 3.1% in subperiosteal and subdural drain, respectively	NA

hemorrhage from neomembranes, and infection without reducing recurrence.

Subdural, subperiosteal, and subgaleal drainage are being used for continuous drainage after surgery. Both the subdural and subperiosteal methods were found to be highly effective with a tendency to less mortality and fewer serious complications in subperiosteal drainage.^[19] The subperiosteal closed-drainage system is a technically easy, safe, and cost-efficient treatment strategy for CSDH. The absence of a drain in direct contact with the hematoma capsule may reduce the risk of postoperative seizure and limit the secondary spread of infection to intracranial compartments.^[20] Although the mortality and the complications of the subperiosteal drain was lower than the subdural drain but the recurrence rate was more as compared to subdural drain.^[19,20]

Subgaleal suction drain was also found to be an effective and safe method in our study. It significantly reduced the incidence of recurrence in our series. Similar observations were made in other study.^[6] It is a simple technique. Gazzeri *et al.* placed tip of suction drain on burr hole which can assist in continuous evacuation of hematoma or collected air.^[6] We placed suction tip away from burr hole site which could avoid accidental slippage of tip in subdural space. Subgaleal drainage could avoid the risk of an acute hemorrhage from neo membrane injury which may occur during introduction and the removal of a subdural drain. It also reduces chances of brain parenchymal injury especially after suction drain.^[21] A major complication of intracerebral hemorrhage could be due to a blind placement of the subdural drain. Acute subdural hematoma^[18,22] and intracerebral hematoma^[19,22] can develop into CSDH after subdural drainage. We did not come across any acute subdural hematoma or intracerebral hematoma but there is a report of one acute SDH after subgaleal drain.^[6]

The subgaleal drain reduced the chances of significant pneumocephalus in our study. The amount of subdural air is correlated negatively with the resolution of a CSDH.^[23] It impedes the adhesion of the inner and outer membranes, prolonging the widening of the subdural space thus promoting postoperative reaccumulation. The placement of subgaleal suction catheter could prevent the collection of subdural air, thus minimizing the risk of recurrence.^[6] Intraoperative saline flushing, avoiding nitrous oxide and supine position could help in preventing pneumocephalus.^[24] Introduction of saline in the cavity rather than air facilitates earlier expansion of the cerebrum.^[25] Burr hole should be at the highest point to reduce pneumocephalus and the recurrence rate.^[23]

One of the major reservations of a drain is that it may not be effective to reduce recurrence while the infective complications could be more after drain insertion. Although we did not encounter any infection in our series, subdural empyemas have been reported after subdural drain.^[18,22,26-28] Postoperative infection in the subgaleal space has also been reported after subgaleal drainage.^[6]

Acknowledgment

Authors are grateful to Mr. Arvind Kavishwar Bio statistician for his help in statistics.

References

- Santarius T, Lawton R, Kirkpatrick PJ, Hutchinson PJ. The management of primary chronic subdural haematoma: A questionnaire survey of practice in the United Kingdom and the Republic of Ireland. *Br J Neurosurg* 2008;22:529-34.
- Cenic A, Bhandari M, Reddy K. Management of chronic subdural hematoma: A national survey and literature review. *Can J Neurol Sci* 2005;32:501-6.
- Karibe H, Kameyama M, Kawase M, Hirano T, Kawaguchi T, Tominaga T. [Epidemiology of chronic subdural hematoma]. *No Shinkei Geka* 2011;39:1149-53.
- Krupa M. [Chronic subdural hematoma: A review of the literature. Part 1]. *Ann Acad Med Stetin* 2009;55:47-52.
- Mohamed EE. Chronic subdural haematoma treated by craniotomy, dorectomy, outer membranectomy and subgaleal suction drainage. Personal experience in 39 patients. *Br J Neurosurg* 2003;17:244-7.
- Gazzeri R, Galarza M, Neroni M, Canova A, Refice GM, Esposito S. Continuous subgaleal suction drainage for the treatment of chronic subdural haematoma. *Acta Neurochir (Wien)*. 2007;149:487-93; discussion 493.
- Santarius T, Qureshi HU, Sivakumaran R, Kirkpatrick PJ, Kirillos RW, Hutchinson PJ. The role of external drains and peritoneal conduits in the treatment of recurrent chronic subdural hematoma. *World Neurosurg* 2010;73:747-50.
- Kiyamaz N, Yilmaz N, Mumcu C. Controversies in chronic subdural hematoma: Continuous drainage versus one-time drainage. *Med Sci Monit* 2007;13:CR240-3.
- Komotar RJ, Starke RM, Connolly ES. The role of drain placement following chronic subdural hematoma evacuation. *Neurosurgery* 2010;66:N15-6.
- Santarius T, Kirkpatrick PJ, Ganesan D, Chia HL, Jallohl, Smielewski P, *et al.* Use of drains versus no drains after burr-hole evacuation of chronic subdural haematoma: A randomised controlled trial. *Lancet* 2009;374:1067-73.
- Carlsen JG, Cortnum S, Sørensen JC. Recurrence of chronic subdural haematoma with and without post-operative drainage. *Br J Neurosurg* 2011;25:388-90.
- Weigel R, Schmiedek P, Krauss JK. Outcome of contemporary surgery for chronic subdural haematoma: Evidence based review. *J Neurol Neurosurg Psychiatry* 2003;74:937-43.
- Ramachandran R, Hegde T. Chronic subdural hematomas—causes of morbidity and mortality. *Surg Neurol* 2007;67:367-72; discussion 372-3.
- Wakai S, Hashimoto K, Watanabe N, Inoh S, Ochiai C, Nagai M. Efficacy of closed-system drainage in treating chronic subdural hematoma: A prospective comparative study. *Neurosurgery* 1990;26:771-3.
- Tsutsumi K, Maeda K, Iijima A, Usui M, Okada Y, Kirino T. The relationship of preoperative magnetic resonance imaging findings and closed system drainage in the recurrence of chronic subdural hematoma. *J Neurosurg* 1997;87:870-5.
- Gurelik M, Aslan A, Gurelik B, Ozum U, Karadag O, Kars HZ. A safe and effective method for treatment of chronic subdural haematoma. *Can J Neurol Sci* 2007;34:84-7.
- Javadi A, Amirjamshidi A, Aran S, Hosseini SH. A randomized controlled trial comparing the outcome of burr-hole irrigation with and without drainage in the treatment of chronic subdural hematoma: A preliminary report. *World Neurosurg* 2011;75:731-6; discussion 620-3.
- Ahmed S, Agrawal D, Kale SS, Mahapatra AK. A comparative study of treatment of chronic subdural hematoma – burr hole drainage versus continuous closed drainage. *The Indian Journal of Neurotrauma* 2011;8:17-23.
- Bellut D, Woernle CM, Burkhardt JK, Kockro RA, Bertalanffy H, Krayenbühl N. Subdural drainage versus subperiosteal drainage in burr-hole trepanation for symptomatic chronic subdural hematomas. *World Neurosurg*. 2012 Jan; 77 (1):111-8. Epub 2011 Nov 15. Comment in *World Neurosurg*. 2012 Jan; 77 (1):51-2.
- Zumofen D, Regli L, Levivier M, Krayenbühl N. Chronic subdural hematomas treated by burr hole trepanation and a subperiosteal drainage system. *Neurosurgery*. 2009 Jun; 64 (6):1116-21; discussion 1121-2.
- Choudhury AR. Avoidable factors that contribute to complications in the surgical treatment of chronic subdural haematoma. *Acta Neurochir (Wien)* 1994;129:15-9.
- Nayil K, Ramzan A, Sajad A, Zahoor S, Wani A, Nizami F, *et al.* Subdural hematomas: An analysis of 1181 Kashmiri patients. *World Neurosurg* 2012;77:103-10.
- Nagata K, Asano T, Basugi N, Tango T, Takakura K. Studies on the operative factors affecting the reduction of chronic subdural hematoma, with special reference to the residual air in the hematoma cavity. *No Shinkei Geka* 1989;17:15-20.

24. Shaikh N, Masood I, Hanssens Y, Louon A, Hafiz A. Tensionpneumocephalus as complication of burr-holedrainage of chronic subdural hematoma: A casereport. *Surg Neurol Int* 2010;1. pii: 27.
25. Aung TH, Wong WK, Mo HP, Tsang CS. Management of chronic subdural haematoma: Burrholedrainage, replacement with Hartmann's solution, and closed-system drainage. *Hong Kong Med J* 1999;5:383-6.
26. Reinges MH, Hasselberg I, Rohde V, Küker W, Gilsbach JM. Prospective analysis of bedside percutaneous subdural tapping for the treatment of chronic subdural haematoma in adults. *J Neurol Neurosurg Psychiatry* 2000;69:40-7.
27. Rohde V, Graf G, Hassler W. Complications of burr-hole craniotomy and closed-system drainage for chronic subdural hematomas: A retrospective analysis of 376 patients. *Neurosurg Rev* 2002;25:89-94.
28. Mori K, Maeda M. Surgical treatment of chronic subdural hematoma in 500 consecutive cases: Clinical characteristics, surgical outcome, complications, and recurrence rate. *Neurol Med Chir (Tokyo)* 2001;41:371-81.

How to cite this article: Yadav YR, Parihar V, Chourasia ID, Bajaj J, Namdev H. The role of subgaleal suction drain placement in chronic subdural hematoma evacuation. *Asian J Neurosurg* 2016;11:214-8.

Source of Support: Nil, Conflict of Interest: None declared.