

Conservative treatment of a femoral neck fracture following nail removal

Claudio Legnani, Alessandra Dondi, Luca Pietrogrande¹

Orthopaedics and Traumatology Residency, University of Milan, ¹Department of Health Science - DISS, University of Milan, Milan, Italy

ABSTRACT

With increased longevity, the management of fragility fractures in the elderly is becoming more frequent. In particular, hip fractures have considerable importance due to the significant morbidity and mortality. A 67-year-old woman underwent intramedullary nail (IMN) removal inserted for a pertrochanteric fracture that had occurred 20 months earlier. This was indicated due to continuous discomfort related to the protruding apex of the implant over the great trochanter. Due to pain persistence two days after surgery, a computed tomography (CT) scan was performed, documenting a minimally displaced impacted subcapital femoral neck fracture. Conservative management with close radiographic follow-up was conducted. After six months, the patient had returned to previous daily activities and a satisfactory range of motion was achieved without pain on walking. The purpose of our paper is to discuss the decision of removing hardware in the elderly osteoporotic patient and to analyze the possibility to conservatively treat an impacted minimally displaced subcapital fracture occurring after the removal of an IMN inserted previously for the treatment of a trochanteric fracture. In the elderly population with decreased bone quality, the removal of intramedullary implants of the proximal femur should be carefully evaluated, and osteoporotic patients undergoing reduction and fixation of femoral fractures should be encouraged to start antiosteoporotic therapy (bisphosphonate, teriparatide) to reduce the risk of further bone loss. Conservative treatment should be considered for the management of lesser symptomatic minimally displaced impacted fractures, where the inherent stability of the fracture allows rapid healing without further surgical attempts.

Key Words: Conservative treatment, hardware removal, hip fracture, intra-medullary nail, osteoporosis, subcapital fracture

INTRODUCTION

Hip fractures are frequent among the elderly, and increasing average age and life expectancy represent a major cause of mortality and morbidity in patients aged ≥ 65 years. In Italy in 2005, the incidence of proximal femur fractures in the age group of 65–74 years was 34.8 in women and 16.2 in men per 10,000 inhabitants, increasing from 16.7 and 16.5%, respectively, in 2000.^[1] Osteoporosis is a contributing factor in most of the hip fractures caused by low-energy falls in the aging population, with an US incidence rate of fragility fractures of 400 per 100,000 inhabitants in 2006.^[2]

The treatment of hip fractures with surgery is considered the gold standard since many decades, as it can reduce

prolonged immobilization and related complications such as thromboembolic disease and decubitus ulceration.^[3] Inter-trochanteric fractures are commonly treated with open or closed reduction and internal fixation, usually performed with intramedullary nails (IMNs) or plates.

Care should be taken in the decision making of removing hardware in the elderly patient, as poor bone quality can lead to collapse and subsequent fractures. IMNs must be removed in the event of broken hardware, revision fracture surgery for nonunions, malunions, or infections, and to comply with the request of the patient to alleviate pain in case of symptomatic hardware.^[4] Routine removal

Address for Correspondence: Dr. Claudio Legnani, Orthopaedics and Traumatology Residency, University of Milan, Milan, Italy.
E-mail: clegnan@alice.it

Access this article online

Quick Response Code:



Website:
www.jmidlifehealth.org

DOI:
10.4103/0976-7800.118995

still remains an issue of debate, and femoral neck fractures following removal of the implants which were inserted for the treatment of trochanteric fracture have been reported.^[5,6]

The purpose of our paper is to discuss the decision of removing hardware in the elderly osteoporotic patient and to analyze the possibility to conservatively treat lesser symptomatic impacted minimally displaced subcapital fracture.

CASE REPORT

A 67-year-old woman was treated for a pertrochanteric fracture (AO classification 31-A1.2) following a low-energy fall at home with closed reduction and internal fixation with a locked IMN (Bi-Nail, Gruppo Bioimpianti, Peschiera Borromeo, Italy). At three weeks, she was walking with full weight bearing without support, and bony union had occurred by 12 weeks. Eighteen months after surgery, the fracture had clinical and radiographical signs of complete healing. Twenty months after the operation, the patient complained of continuous discomfort over the great trochanter; anteroposterior view documented the apex of the implant protruding proximally and the lag screw that was set in the center of the neck [Figure 1].

Due to this discomfort, the need for IMN removal was felt. The day after the removal of the hardware, the patient complained of a left inguinal pain that increased during weight bearing. No traumatic events occurred postoperatively. Standard X-rays were taken and no fracture signs were present. Due to persistence of pain, two days later, further plain radiographs were taken showing a dubious fracture of the femoral neck. In addition, a computed tomography (CT) scan was performed, documenting a subcapital femoral neck fracture, which was classified as Garden's grade II [Figure 2].

In this condition, a stable osteosynthesis could hardly be achieved as screw-holding power would have been reduced by the recent removal of a lag screw, making it more prone to the risk of cutting out and consequent screw loosening, especially in an elderly patient. In view of the minimally displaced impacted fracture and the rapid reduction of the symptoms at rest, conservative management with medication and close X-ray monitoring was conducted. The patient was allowed to walk with bilateral crutches with no weight bearing on the left limb, and was discharged after 10 days. Antiosteoporotic therapy was started with calcium and vitamin D supplementation in addition to antiresorptive drugs. At the radiographic follow-up at 30 days, no displacement was detected and the fracture line was not visible any more. Six months postoperatively, radiographs showed complete healing of the fracture [Figure 3]. At the clinical follow-up at six months, the

patient had returned to previous daily activities, and clinical assessment showed a satisfactory range of motion with no pain on walking.

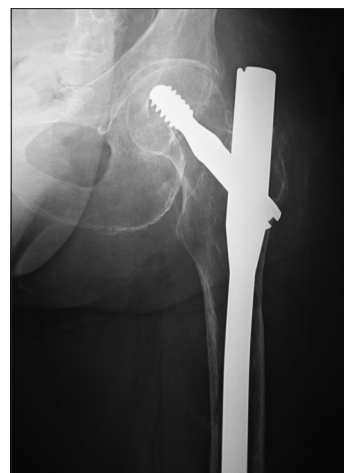


Figure 1: Preoperative X-ray documenting the protruding apex of the intramedullary nail

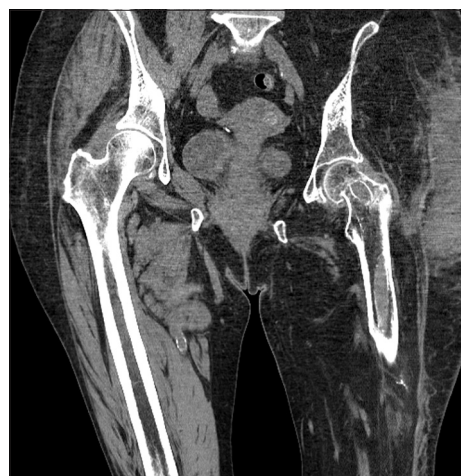

Figure 2: CT scan documenting sub-capital fracture of the femur

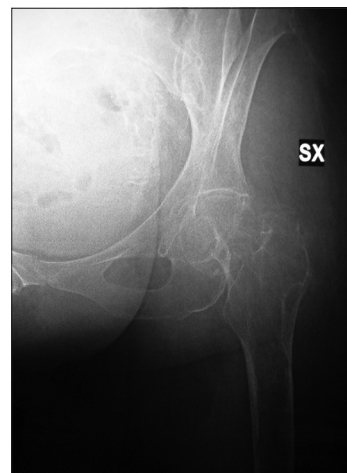


Figure 3: 6 months radiographic follow-up showed complete healing of the fracture

DISCUSSION

Surgery is routinely performed in the treatment of extra-articular hip fractures as it allows early weight bearing, reducing the risks of prolonged immobilization.^[3] IMNs have well-recognized advantages, such as controlled impaction of the fracture, decreased lever arm for load bearing, minimal dissection around the fracture site, and excellent axial and rotational control.^[3] A weakness in the use of IMNs is the security of the lag screw, as screw-holding power in the osteoporotic bone is affected by bone quality.^[7]

The indications and timing of IMN removal in femoral fractures in the osteoporotic patient are controversial. The removal of symptomatic hardware can be performed to ease pain in response to the request of the patient, but it is not mandatory unless infections or the risk of a cut-out of the implant are present. In the elderly population, the weakening of the femoral neck can lead to subcapital and pertrochanteric fractures.^[5,6,8,9]

The occurrence of iatrogenic fracture following the removal of implants is uncommon, but there are reports documenting complications in the outcome of the removal of metal devices.^[5,6,8,9] Recently, Yang *et al.*^[5] reported two cases of femoral neck fracture after extraction of IMNs inserted for the treatment of trochanteric fractures. Buciuto *et al.*^[9] reported seven spontaneous proximal femoral fractures after an average time of 19 days after the removal of dynamic hip screws (DHS) or angled plates. In a paper about biomechanics of the femur after IMN removal, Kukla *et al.*^[10] reported a decreased resistance to fracture of the femoral neck by about 41%. It was 20% after removal of DHS. The bone defect that occurs after the removal of an implant further weakens a femoral neck with pre-existing osteoporosis and can contribute to the weakening of the subcapital region of the femoral neck, making it more prone to stress.^[11] The trabecular bone of the pertrochanteric region is substantially weaker in osteoporotic patients, and the removal of nails and plates could result in the collapse of fractures that would otherwise be stable. In case of mandatory removal of the hardware, bone defect can be filled with bone grafting.^[10] Moreover, a subcapital stress fracture can sometimes be misjudged in patients complaining of hip pain prior to hardware removal.^[9]

It is thus clear that IMNs should only be removed in the presence of a convincing indication. Probably, in the case presented, the decision of removing the implant was taken underestimating the low bone density and without increasing bone quality with proper pharmacological treatment. The hypothesis that the subcapital fracture

existed before the removal of the implant does not seem to be supported by clinical observation, as the patient complained of pain in the trochanteric region, whereas subcapital fracture is electively characterized by inguinal pain. As nail extraction appears to have occurred without difficulty, the fracture has to be considered to have occurred due to the application of muscular force or due to bed-to-bed transfer that may have put a shearing force on the site of hardware removal, the fact that presumes the presence of a highly compromised bone resistance of the femoral neck. In our experience, the symptoms reported by our patient indicated a diminution in the use of the lower limb affected. It should be questioned if the reduced weight bearing consequent to pain could have contributed to the reduction of bone density and to the increase of bone fragility and susceptibility to fractures. A cadaver study investigated the biomechanics of the femur after implant removal.^[10] The authors reported a reduced bone resistance which was related to the removal of the implant itself and not to an eventual absence of weight bearing on the femoral neck due to a stress-shielding effect.

To decrease the rate of complications, an early diagnosis and proper treatment of osteoporosis are crucial. Elderly patients posted for hardware removal should undergo bone mineral density testing, dual-energy X-ray absorptiometry (DEXA), and bone metabolism studies. Then, if indicated, they should be started on a medical regimen including calcium and vitamin D supplementation and should be encouraged to start antiosteoporotic therapy (bisphosphonate, teriparatide) to reduce the risk of further bone loss.

The favorable evolution to a rapid and complete fracture healing in the present case leads to some considerations: Impacted minimally displaced femoral neck fractures do not necessarily require surgical osteosynthesis as they can be considered as stable fractures *ab initio*. Fracture repair is initially promoted by the presence of hematoma at the fracture site and the subsequent formation of granulation tissue, with various cytokines and growth factors (TGF- β , PDGF, FGF, IL-1, and IL-6).^[12] In the specific case, it can be hypothesized that due to the cavity left by the screw removal, a greater hematoma including a greater quantity of growth factor was present leading to a more efficient healing process.

We consider conservative treatment to be advantageous in eliminating the need for surgery as well as the risk of complications including infection, pulmonary embolism, and anaphylactic shock. Two recent studies have shown that conservative treatment of impacted fractures minimizes surgical intervention and leads to satisfying functional results in 48 to 54% of the patients considered.^[13,14]

CONCLUSION

In conclusion, in the elderly population with decreased bone quality, the removal of hardware should be carefully evaluated and preceded by a careful assessment of bone quality. In addition, conservative treatment for lesser symptomatic minimally displaced impacted fractures should be borne in mind, as the inherent stability of the fracture can allow rapid healing without further surgical attempts.

REFERENCES

1. Piscitelli P, Gimigliano F, Gatto S, Marinelli A, Gimigliano A, Marinelli P, *et al.* Hip fractures in Italy: 2000-2005 extension study. *Osteoporos Int* 2010;21:1323-30.
2. Nieves JW, Bilezikian JP, Lane JM, Einhorn TA, Wang Y, Steinbuch M, *et al.* Fragility fractures of the hip and femur: Incidence and patient characteristics. *Osteoporos Int* 2010;21:399-408.
3. Cornell CN. Internal fracture fixation in patients with osteoporosis. *J Am Acad Orthop Surg* 2003;11:109-19.
4. Ruedi TP, Murphy WM. *AO principles of fracture management*. New York: Thieme; 2001.
5. Yang KH, Choi YW, Won JH, Yoo JH. Subcapital femoral neck fracture after removal of Gamma/Proximal Femoral nails: Report of two cases. *Injury Extra* 2005;36:245-8.
6. Wilson-MacDonal J. Subcapital fracture complicating an intertrochanteric fracture. *Clin Orthop Relat Res* 1985;201:147-50.
7. Turner IG, Rice GN. Comparison of bone screw holding strength in healthy bovine and osteoporotic human cancellous bone. *Clin Mater* 1992;9:105-7.
8. Ovadia DN, Chess JL. Intraoperative and postoperative subtrochanteric fracture of the femur associated with removal of the Zickel nail. *J Bone Joint Surg Am* 1988;70:239-43.
9. Buciuto R, Hammer R, Herder A. Spontaneous subcapital femoral neck fracture after healed trochanteric fracture. *Clin Orthop Relat Res* 1997;342:156-63.
10. Kukla C, Pichl W, Prokesch R, Jacyniak W, Heinze G, Gatterer R, *et al.* Femoral neck fracture after removal of the standard Gamma interlocking nail: A cadaveric study to determine factors influencing the biomechanical properties of the proximal femur. *J Biomech* 2001;34:1519-26.
11. Taylor PR, Hepple S, Stanley D. Combination subcapital and intertrochanteric fractures of the femoral neck. *Injury* 1996;27:68-71.
12. Wraighte PJ, Scammel BE. *Principles of fracture healing*. Elsevier; 2006;24:198-206.
13. Verheyen CC, Smulders TC, van Walsum AD. High secondary displacement rate in the conservative treatment of impacted femoral neck fractures in 105 patients. *Arch Orthop Trauma Surg* 2005;125:166-8.
14. Helbig L, Werner M, Schneider S, Simank HG. Garden I femoral neck fractures: conservative vs operative therapy. *Orthopäde* 2005;34:1040-5.

How to cite this article: Legnani C, Dondi A, Pietrogrande L. Conservative treatment of a femoral neck fracture following nail removal. *J Mid-life Health* 2013;4:191-4.

Source of Support: Nil, **Conflict of Interest:** None declared.