

# A patient with severe acute pancreatitis who was successfully rescued by multiple disciplinary teams: a case report

Journal of International Medical Research

2019, Vol. 47(11) 5831–5838

© The Author(s) 2019

Article reuse guidelines:

[sagepub.com/journals-permissions](http://sagepub.com/journals-permissions)

DOI: 10.1177/0300060519874156

[journals.sagepub.com/home/imr](http://journals.sagepub.com/home/imr)



Linhui Zheng\*, Jun Deng\*, Xinhua Long\* and Yuanlin Zeng 

## Abstract

Severe acute pancreatitis (SAP) is a type of acute abdominal disease. SAP has a high incidence, rapid progression, many complications, high mortality rate (as high as 30%–50%), and is difficult to treat, accounting for approximately 5% to 10% cases of acute pancreatitis. We report diagnosis and treatment of a case of SAP, including a combination of the relevant guidelines and our experience. The patient, who was a 42-year-old woman, was admitted to our hospital after suffering from abdominal pain in the upper abdomen for 1 day. The results of a computed tomography scan in the upper abdomen showed changes in the pancreas accompanied by acute fluid accumulation. The blood amylase level was 1150 U/L. The patient was treated at our Gastroenterology Department for 5.5 months, and received 22 blood transfusions (including red blood cell suspension, plasma, cryoprecipitate, and platelets), four surgical operations, three angiographic interventions, and two times of embolization for hemostasis. We successfully rescued this patient with SAP using minimally invasive, staged, multidisciplinary, and diversified treatment modalities.

## Keywords

Severe acute pancreatitis (SAP), multidisciplinary team, angiographic intervention, abdomen, amylase, fluid accumulation, surgery

Date received: 31 March 2019; accepted: 15 August 2019

\*These authors contributed equally to this work.

### Corresponding author:

Yuanlin Zeng, Emergency Trauma Center, The First Affiliated Hospital of NanChang University, NanChang 330006, China.

Email: [jingyangsdu@126.com](mailto:jingyangsdu@126.com)

Emergency Trauma Center, The First Affiliated Hospital of Nanchang University, Nanchang, China



Creative Commons Non Commercial CC BY-NC: This article is distributed under the terms of the Creative Commons Attribution-NonCommercial 4.0 License (<http://www.creativecommons.org/licenses/by-nc/4.0/>) which permits non-commercial use, reproduction and distribution of the work without further permission provided the original work is attributed as specified on the SAGE and Open Access pages (<https://us.sagepub.com/en-us/nam/open-access-at-sage>).

## Introduction

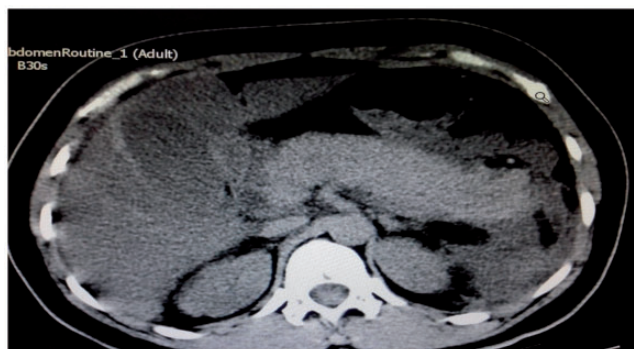
Severe acute pancreatitis (SAP) is a type of acute abdominal disease<sup>1</sup> with a high incidence, rapid progression, many complications, high mortality rate, and difficult treatment. In recent years, a certain consensus has been reached on the diagnosis and treatment of SAP. A comprehensive treatment strategy<sup>2</sup> based on individualized treatment has been formed for SAP according to different causes and stages of this disease. The early stage of SAP is mainly characterized by an acute inflammatory reaction, hemorrhagic necrosis of tissues, and severe damage of the intestinal mucosal barrier. Surgery cannot stop the progression of pancreatitis because surgery increases systemic metabolic disorders and the incidence of infection and mortality. Therefore, early treatment of SAP is mainly based on active, effective, and comprehensive non-surgical methods. These methods include fasting, gastrointestinal decompression, anti-pancreatic drugs, supplementation capacity, maintenance of electrolyte balance, nutritional support, application of antibiotics, regional arterial infusion therapy, blood purification, immunotherapy, induction of apoptosis, early peritoneal lavage, improvement of pancreatic microcirculation, Chinese medicine

treatment, endoscopic treatment, and others.<sup>3-5</sup> Despite reservations about surgery, surgical treatment is still one of the most important methods for treating SAP. Surgical indications include pancreatic necrosis and infection, pancreatic abscess or pseudocyst, biliary pancreatitis, abdominal fascia compartment syndrome, combined bleeding, and perforation and peritonitis that cannot be controlled by internal conservative treatment.<sup>6,7</sup> However, there is still controversy about the choice of surgical indications and timing of surgery to date. We report a patient with SAP who was successfully rescued using minimally invasive, staged, multidisciplinary, and diversified treatment methods.

## Case presentation

A 42-year-old woman was admitted to our hospital after suffering from abdominal pain in the upper abdomen for 1 day. At the time of admission to the hospital, the results of a computed tomography (CT) scan of the upper abdomen (Figure 1) showed changes in the pancreas accompanied by acute fluid accumulation. The blood amylase level was 1150 U/L. Therefore, pancreatitis was diagnosed.

After admission to our hospital, antibiotics, oxygen, acid-suppressing drugs,



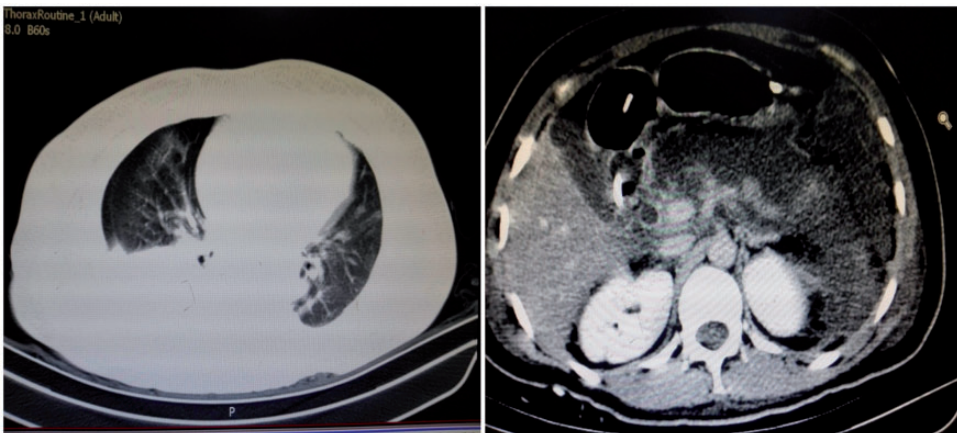
**Figure 1.** Computed tomography scan of the upper abdomen showing changes in the pancreas accompanied by acute fluid accumulation.

anti-enzyme drugs, and other treatments were administered immediately. On the 2nd day, the patient was transferred to the intensive care unit (ICU) of the Gastroenterology Department because dyspnea had progressively developed at a respiratory rate of 50 breaths/minute. CT scans in the ICU showed left pleural effusion and apparent abdominal swelling, accompanied by abdominal distension. Therefore, thoracentesis and abdominocentesis were performed. Cefoperazone sulbactam sodium was injected to induce an anti-inflammatory reaction. On the 3rd day, the patient's respiratory function and the symptoms of abdominal distension improved. The patient was fed enterally (Peptison) using a nasal jejunal tube to promote recovery of intestinal function and to reduce displacement of intestinal flora and secretion of pancreatic juice and inflammatory exudation. Anti-inflammation, acid suppression, enzyme inhibition, fluid replacement, and other treatments were continued. On the 6th to 9th days, chest and abdominal CT scans showed recognizable right pleural effusion and a considerable increase in peripancreatic effusion (Figure 2). Right thoracocentesis,

catheterization, and drainage were performed under B-ultrasound guidance. On the 9th day, the patient's temperature rose to above 39°C, and use of the thoracic and abdominal drainage tube declined. The drainage tube was subsequently removed to prevent catheter-related infections.

On the 12th day, the patient was transferred to the general ward because the abdominal symptoms and respiratory function had greatly improved. Despite the switch from sulperazone to imipenem and cilastatin sodium (Tienam) because of persistent high fever, the patient's temperature was still high. Therefore, teicoplanin (for injection) was added to the treatment regime on the 17th day and discontinued on the 22nd day when her temperature had mostly returned to normal for 1 week. From the 30th to 33rd days, the patient's temperature gradually rose again to over 39°C, possibly because the exuded pancreatic fluid was infected. This speculation was confirmed to be true when gastric metal stent implantation drainage was performed to discard a large amount of yellow purulent liquid.

Nevertheless, the patient continued to have a high fever. Therefore, sulperazone



**Figure 2.** Chest and abdominal computed tomography scans showing bilateral pulmonary infection, bilateral pleural effusion, and increased pancreatic effusion.

was discontinued, and Tienam + teicoplanin was used. Despite the change in treatment, the patient continued to have a high fever. Therefore, tigecycline (Tygacil) was added to resist infection. A metal drainage stent was used again and placed on the posterior wall of the gastric body under guidance of a gastroscope.

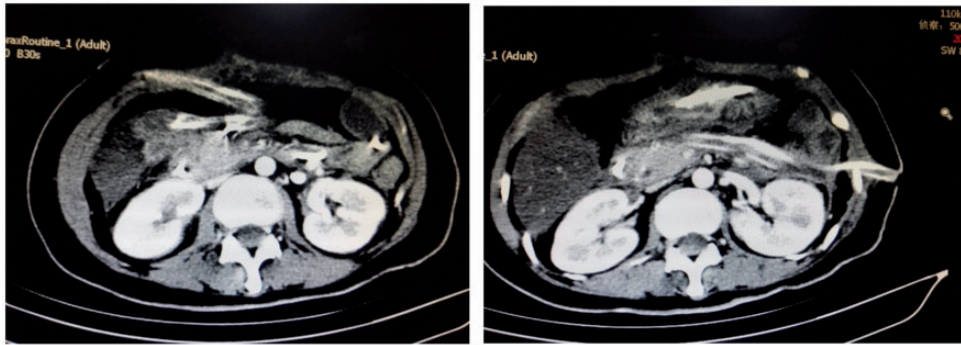
On the 33rd day, the patient developed dyspnea, her respiratory rate was reduced to 50 breaths/minute, and blood oxygen saturation continued to decline. As a result, she was transferred to the pancreatic ICU for tracheal intubation, ventilator-assisted breathing, central venipuncture, quick fluid infusion, and cooling with an ice blanket machine. However, the remaining treatments were unchanged. The patient still relied on ventilators by the 40th day. Fiberoptic bronchoscopy-guided phlegm suction plus alveolar lavage were performed, and anti-inflammation, enzyme inhibition, acid suppression, and other treatments were continued to maintain the patient's tracheal patency, strengthen drainage, control infection, and clear the inflammatory mediators in her lungs. On the 41st day, the patient developed hematemesis, necessitating angiographic intervention. Embolization with a micro spring coil was successfully carried out because of overflow of contrast of the middle colic artery, and she was returned to the ICU for further treatment.

On the 42nd day, *Acinetobacter baumannii*/*A. hemolyticus* were obtained by sputum culture, and *Candida albicans* was obtained by urine culture. The anti-fungal fluconazole (Diflucan) was added to the patient's treatment regime. The antibiotic treatment regimen was adjusted to Tienam + tigecycline + teicoplanin + fluconazole. The patient's abdomen became swollen. A B-ultrasound examination showed pancreatic encapsulated necrosis. Abdominocentesis and drainage were performed, and a B-ultrasound examination

was used to locate the point and angle of puncture. The pancreatic encapsulated necrotic fluid was drained using direct puncture with a 12 F BanTer pigtail tube (Taiwan Bangtuo, Taiwan, China). Abdominal catheterization and drainage were performed again to discharge pancreatic ascites and reduce intra-abdominal pressure.

From the 46th to 47th days, the patient's stool was smooth after *Saccharomyces boulardii* sachets were used to improve intestinal flora and promote recovery of gastrointestinal motility. *Klebsiella pneumoniae* was cultured using the patient's drainage fluid, and the antibiotics were adjusted to Tienam + tigecycline + amikacin + fluconazole. Sputum suction plus alveolar lavage were performed again under the guidance of fiberoptic bronchoscopy. On the 49th day, the patient developed hematemesis and melena, and a dark red liquid was drained from the gastric tube. Therefore, angiographic intervention was performed. Angiography did not show obvious contrast agent spillover in the celiac artery and apparent active bleeding. A metal stent was discovered on the posterior wall of the middle part of the stomach, where old blood clots had piled up. This metal stent and some old blood clots were removed with mesh baskets. Saline was used for repeated rinsing, and hemostasis and symptomatic treatment were continued.

On the 50th day, the patient developed loose melena and hematemesis again, and a dark red liquid was drained from the stomach tube. The hemoglobin level was still greatly decreased after multiple blood transfusions. A decision was made to use surgical treatment after consultation among emergency surgeons. One active bleeding point was found at the head of the pancreas and the other active bleeding point was perceived in the deep part of the tail of the pancreas during the operation. Hemostasis was thoroughly performed,



**Figure 3.** Hemostasis was thoroughly performed and double cannulae were placed for drainage.

and double cannulae were set for drainage (Figure 3). *K. pneumoniae* was cultured using the patient's blood. The sensitive antibiotic amikacin was administered, and this antibiotic was not adjusted temporarily.

On the 54th day, a yellow-brown liquid was drained from the patient's left double cannulae. Methylene blue was injected into the stomach tube, and a small amount of methylene blue was observed flowing out, which confirmed the presence of an intestinal fistula. The patient had no signs of peritonitis and defecation was normal. We considered that an encapsulated, circumscribed, intestinal fistula had developed and continuous rinsing and drainage were recommended. Sputum suction plus alveolar lavage were performed again under the guidance of fiberoptic bronchoscopy to maintain the patient's tracheal patency, strengthen drainage, control infection, and remove inflammatory mediators in her lungs. The left double cannulae were drained to the hepatic flexure of the colon, and there was fecal water flowing out.

On the 55th day, biochemical blood indicators showed that the bilirubin level was elevated and liver function was impaired, which were considered to be caused by the infection and drugs. Because of the long use of Tienam, the patient's temperature was decreased compared with previously. Therefore, Tienam was stopped, and

tigecycline + amikacin + fluconazole were used temporarily. On the 59th day, the ventilator was successfully removed, with administration of medium-flow oxygen uptake instead.

On the 60th day, *Candida smooth* from the patient's catheter tip was cultured, and the anti-fungal drug fluconazole was provided. On the 64th day, *Proteus mirabilis* was cultured from the patient's drainage fluid, and it was sensitive to amikacin. The patient's body temperature could be controlled, and thus antibiotics were not adjusted temporarily. On the 65th day, after consultation with an on-site pharmacist and considering that amikacin had been used for a long time, antibiotics were replaced with fosfomycin combined with tigecycline and fluconazole for anti-infection. The patient's condition gradually improved, and she was transferred to the general ward on the 75th day.

On the 78th day, the patient developed a fast heart rate again, dyspnea (45 breaths/minutes), and a continuous decline in blood oxygen saturation. Her symptoms did not improve after an oxygen mask was used. The possibility of a complicated acute respiratory failure was considered. Therefore, the woman was transferred to the ICU again for tracheal intubation and ventilator-assisted breathing. On the 80th day, the patient's breathing function improved, and the



ventilator was successfully removed. On the 83rd day, the patient's temperature was stable, without hyperthermia. Anti-infection treatment with fosfomycin, tigecycline, and fluconazole was stopped, and only Tazocin (piperacillin sodium and tazobactam sodium for injection) was used to resist infection. On the 85th day, the patient's condition was stable, and she was transferred to the general ward once more.

From the 97th to 100th days, the patient developed melena again. Therefore, she was transferred to the ICU ward and selective celiac angiography was performed again. Angiography showed spillover of contrast agent in the middle colic artery. Embolization with a 2-mm micro spring coil was successful, and anti-inflammatory, acid-suppressing, and anti-enzyme treatments were continued.

From the 101st to 104th days, the patient developed a dark red bloody stool again, and a dark red liquid was drained from the abdominal cavity. She was subsequently transferred to the ICU for treatment. The bleeding stopped after symptomatic supportive treatment. On the 104th day, the patient was stable and transferred to the general ward. From the 105th to 106th days, a large amount of bright red blood was extracted from the abdominal drainage tube. An intraoperative examination indicated that there were two fistula mouths in the colonic hepatic flexure and the right half of the transverse colon, and there was bloody exudation. The right half of the colon and the terminal ileal fistulization were successfully resected, hemostasis was successful, and the patient was transferred to the ICU after the operation. Tazocin was discontinued and replaced with Tienam. On the 1st day after the operation, the patient developed a high fever at 39.7°C, and a fungus from her blood was cultured. Fluconazole (Diflucan) was added to the treatment to resist infection. The ventilator

was successfully removed on the 2nd day after the operation.

The patient still had a high fever by the 107th day, and Gram-positive *C. albicans* was cultured from her blood. Therefore, Diflucan was added for treatment. By the 111th day, the patient still exhibited symptoms of a high fever, and Diflucan was discontinued and switched to caspofungin for antifungal treatment. On the 113th day, *P. mirabilis* was cultured from the drainage solution and the antibiotics were not changed. On the 115th day, during the late stage of pancreatitis, a pancreatic enzyme was insufficiently secreted, and a trypsin enteric-coated capsule was administered to aid digestion. On the 117th day, *Staphylococcus aureus* was cultured from the patient's blood. Therefore, vancomycin was added for anti-infection. On the 119th day, the patient was stable and was transferred to the general ward again.

From the 123rd to 128th days, the patient developed a high fever again. After consultation with the Pharmacy Department, Tienam was discontinued and switched to piperacillin, tazobactam, caspofungin, and vancomycin. On the 127th day, the patient's abdominal CT scan showed pelvic encapsulated effusion. Concurrent infection was suggested clinically. Paracentesis was performed under B-ultrasound guidance, and a 12 F pigtail tube was placed in the necrosis for drainage. Subsequently, the patient's body temperature dropped. On the 128th day, the patient developed melena, and colonoscopy showed a bleeding point in the intestinal mucosa. Therefore, a styptic powder was sprayed to successfully stop the bleeding.

On the 134th day, four infected lesions occurred in the abdomen of the patient (three lesions were 2 × 2 cm and one lesion was 6 × 5 cm; intraoperative gastroscopy showed that the lesions were deep in the abdominal cavity), and a large amount of purulent secretion was discharged.

The Burns Department was consulted on the decision to perform intraoperative gastroscopy and negative pressure vacuum sealing drainage (VSD) on the wound surface. After the decayed tissue was thoroughly removed, VSD was used to cover the wound surface and negative pressure VSD was performed. On the 7th day after the second operation, the four infected lesions were greatly reduced and improved after VSD was removed. At this point, operative treatments were no longer used, and only debridement and dressing treatment were performed.

All experiments and procedures were approved by the Institutional Ethics Committee of Nanchang University. Informed consent was obtained from the patient for publication of this case report and any accompanying images.

## Discussion

The mortality rate of SAP is as high as 30% to 50%.<sup>8</sup> We believe that using individualized treatment for SAP is best. Therefore, individualized treatment programs were developed according to the actual situation to achieve the best therapeutic effect in our patient. Treatment in our case focused on the patient's disease progression process and a targeted phased intervention plan was developed on the basis of an existing intervention program, which was gradual and effective. Because of accompanying infections of SAP and subsequent development to organ failure, multiple important organs and tissues were affected. Therefore, a multiple disciplinary team played an important role in rescue of this case. The Departments of Pharmacy, Laboratory Medicine, Emergency Surgery, Burns, Obstetrics and Gynecology, Imaging, Endocrinology, Psychosomatic Medicine, Rehabilitation, Infection, and Cardiology worked together to complete the treatment, select antibiotics, and handle complications.

In the process of controlling infections, our patient received a series of treatments according to the location, time, and extent of infection. The general guiding ideology is to select sensitive antibiotics and minimally invasive, and even non-invasive, drainage methods to control infection. In our case, a metal drainage stent was placed on the posterior wall of the gastric body under guidance of a gastroscope. Endoscopic pancreatic encapsulation with debridement of necrosis was performed, pelvic effusion puncture was performed under B-ultrasound guidance, and a hemostatic powder was used to stop bleeding under colonoscopy. The wound surface on the patient's body surface was covered with VSD, and negative pressure vacuum sealing drainage was carried out. Thorough debridement was switched to full drainage and infection control. The patient was treated at the Gastroenterology Department for 5.5 months. She received a total of 22 blood transfusions (including red blood cell suspension, plasma, cryoprecipitate, and platelets), four surgical operations, three angiographic interventions, and two times of embolization for hemostasis.

In conclusion, we successfully rescued our patient with SAP using minimally invasive, staged, multidisciplinary, and diversified treatment modalities.

## Declaration of conflicting interest

The authors declare that there is no conflict of interest.

## Funding

This research received no specific grant from any funding agency in the public, commercial, or not-for-profit sectors.

## ORCID iD

Yuanlin Zeng  <https://orcid.org/0000-0003-0608-2556>

## References

1. Kaplan M, Ates I, Oztas E, et al. A new marker to determine prognosis of acute pancreatitis: PLR and NLR combination. *J Med Biochem* 2018; 37: 21–30.
2. Ben QW and Yuan YZ. We must pay attention to the comprehensive treatment of severe acute pancreatitis. *Zhonghua Yi Xue Za Zhi* 2012; 92: 3187–3188.
3. Liu B, Pan AJ, Zhou SS, et al. Individualized and comprehensive therapy for severe acute pancreatitis in early stage: analysis of 110 cases. *Zhongguo Wei Zhong Bing Ji Jiu Yi Xue* 2006; 18: 169–171.
4. Lu X, Xiao W, Kang X, et al. The effect of Chinese herbal medicine on non-biliogenic severe acute pancreatitis: a systematic review and meta-analysis. *J Ethnopharmacol* 2014; 155: 21–29.
5. Heinrich S, Schäfer M, Rousson V, et al. Evidence-based treatment of acute pancreatitis: a look at established paradigms. *Ann Surg* 2006; 243: 154–168.
6. Morató O, Poves I, Ilzarbe L, et al. Minimally invasive surgery in the era of step-up approach for treatment of severe acute pancreatitis. *Int J Surg* 2018; 51: 164–169.
7. Murphy PB, Paskar D, Hilsden R, et al. Acute care surgery: a means for providing cost-effective, quality care for gallstone pancreatitis. *World J Emerg Surg* 2017; 12: 20.
8. Wig JD, Bharathy KG, Kochhar R, et al. Correlates of organ failure in severe acute pancreatitis. *JOP* 2009; 10: 271–2755.