

Paulo Gilberto Cimbalista de Alencar¹, Inácio Facó Ventura Vieira²

ABSTRACT

Bone banks are necessary for providing biological material for a series of orthopedic procedures. The growing need for musculoskeletal tissues for transplantation has been due to the development of new surgical techniques, and this has led to a situation in which a variety of hospital services have been willing to have their own source of tissue for transplantation. To increase the safety of transplanted tissues, standards for bone bank operation have been imposed by the government, which has limited the number of authorized institutions. The good performance in a bone bank depends on strict control over all stages, including: formation of well-

trained harvesting teams; donor selection; conducting various tests on the tissues obtained; and strict control over the processing techniques used. Combination of these factors enables greater scope of use and numbers of recipient patients, while the incidence of tissue contamination becomes statistically insignificant, and there is traceability between donors and recipients. This paper describes technical considerations relating to how a bone bank functions, the use of grafts and orthopedic applications, the ethical issues and the main obstacles encountered.

Keywords – Bone Banks; Allograft; Bone Transplantation; Orthopedic Surgery

INTRODUCTION

The need for replacement of musculoskeletal tissue because of losses caused by a variety of situations is an increasingly common problem in surgical practice. With greater longevity among the population, alongside the fact that surgical indications are increasingly common among young patients, the search for long-lasting solutions implies the use of biological reconstruction methods.

There is so far no better material for replacing bone losses than human tissue itself. The best type, from a biological point of view, is autologous tissue, i.e. from

the patient himself. However, donor site complications (increased duration of surgery, pain, bleeding, fractures and neurovascular lesions) and the need for specific formats and large quantities of biological material have meant that the use of tissue banks is more appropriate in most situations(1,2).

Historically, bone banks have existed in Brazil since the 1950s. In the mid-1990s, regulations were imposed on the practices followed by tissue banks, which gave rise to a series of restrictions that limited the number of tissue banks and surgeons authorized to use musculoskeletal tissue.

1 – Head of the Hip and Knee Surgery Group, Hospital de Clínicas, Federal University of Paraná.

2 – Orthopedist in the Hip and Knee Surgery Group, Hospital de Clínicas, Federal University of Paraná.

Correspondence: Av. Nossa Senhora Aparecida 286, Bairro Seminário, 80440-000 Curitiba – PR. E-mail: pa@clinicapauloalencar.com, inacioventura@hotmail.com

Work received for publication: October 5, 2010; Accepted for publication October 5, 2010.

We declare that there is no conflict of interest in this paper

BIOLOGY OF BONE GRAFTS

Consolidation of grafts into the host bone tissue takes place through the mediation of three biological phenomena: osteogenesis, osteoinduction and osteoconduction⁽³⁾. Osteogenesis is taken to be the capacity of live cells (osteoblasts) to maintain the production of osteoid substance, which may only occur with autologous grafts. Osteoinduction is the differentiation of pluripotent cells in the host into osteoblasts, through a series of mechanisms in which the various families of growth factors play an important role. Lastly, osteoconduction is the process in which the canaliculi of the transplanted bone act as a guide for the growth of osteoblast bridges of new bone tissue coming from the host. A large number of homologous grafts and bone substitutes are exclusively osteoconductive⁽⁴⁾.

TECHNICAL CONSIDERATIONS

Donor selection

Donor selection is done carefully by the coordinator of the harvesting team and by the medical director of the tissue bank, taking into consideration data such as the donor's age and sex, cause of death, previous medical history, physical examination and numerous laboratory tests.

The biggest complication to be avoided is transmission of diseases from the donor to the recipient, which might be of viral nature (HIV or hepatitis) or bacterial nature, caused by an organism present in the donor or by contamination at the time of harvesting the skeletal tissues⁽⁵⁾. To avoid this complication, sterilization methods can be used (autoclaving or use of ethylene oxide or irradiation), which each have their advantages and disadvantages, or sterile processes applied from the time of harvesting to the final storage, with serial tests performed, alternating with periods of quarantine. The protocol to be complied with before the release has the effect that in up to 30% of the cases, tissue is rejected after harvesting because of the absolute rigor of the protocol. In our tissue bank, after supplying more than 20,000 tissue samples for use in surgical procedures, there has not been a single proven case of transmission of diseases to donors⁽⁶⁻⁸⁾ (Figure 1).

Tissue harvesting

The harvesting teams need to be properly registered

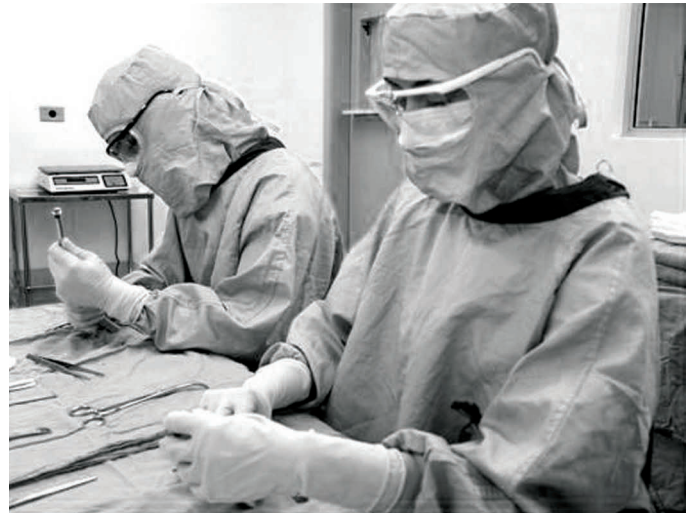

Figure 1 – Gowned team carrying out tissue processing in a sterile manner.

with the transplantation centers in order to have legal backing and to receive notifications regarding donors, not only in their own hospitals but also in other institutions, often outside of their own city or state. There are two types of donor of homologous tissues: live donors, consisting mainly of donations of femoral heads after total hip arthroplasty procedures, which have the advantage that the donor patients can be called back for new tests in suspected cases; and cadaver donors, from which much greater quantities of tissues can be harvested, from practically any segment of the skeleton, as well as generally being young donors with better quality bone tissue than seen in live donors.

Tissue harvesting

Tissue harvesting should be carried out very cautiously, and generally by a team formed by four members (two surgeons, one packer and one auxiliary), following all the guidance for antisepsis and asepsis that would be observed in a large-sized orthopedic surgical procedure (Figure 2). After the material has been removed, material for testing is collected. The specimens are packed individually, identified and transported in thermally insulated boxes, packed in dry ice or ordinary ice. There is a legal requirement, as a matter of respect for the families of donors, that the body structure of the cadaver should be reconstructed: this is done using PVC pieces that were assembled beforehand (Figure 3).

Storage

The tissues are generally kept in freezers at a temperature of 85 degrees Celsius below zero. The freezers

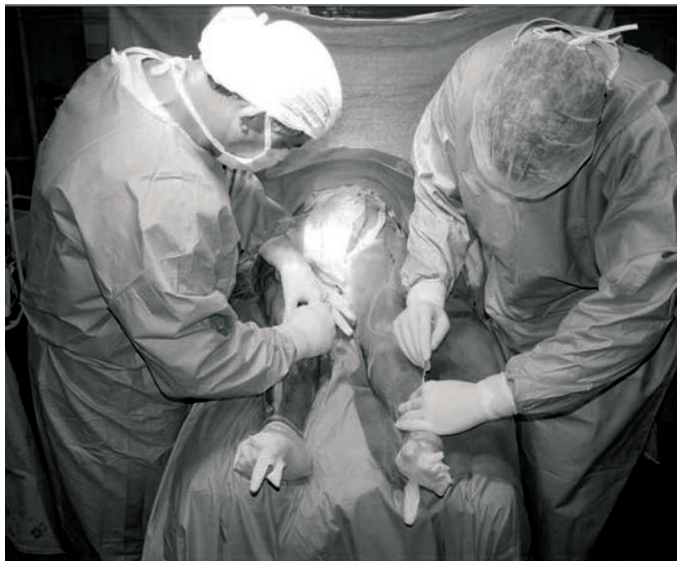

Figure 2 – Harvesting in accordance with the principles of asepsis, as in large-scale orthopedic surgery.

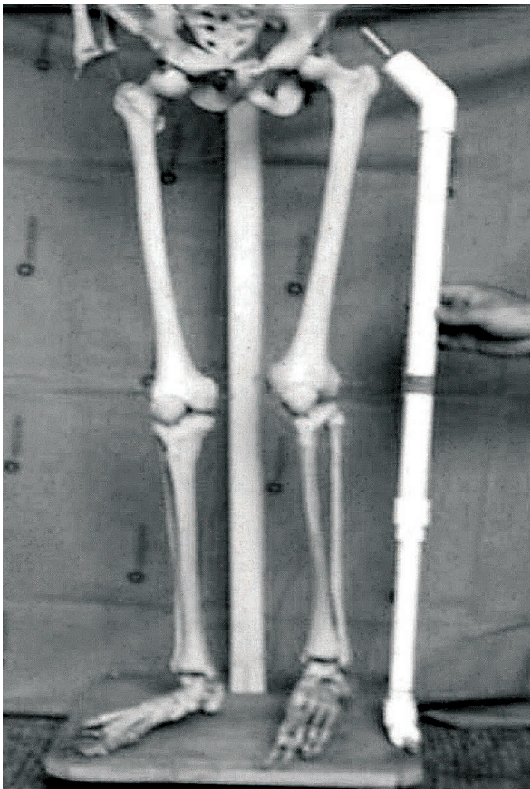


Figure 3 – PVC prosthesis for cadaver reconstruction.

have temperature control displays and are connected to the hospital's generator as a precaution against possible power cuts. They also have an alarm and a supply of liquid CO₂ for additional security. Under ideal conditions and at constant temperature, the tissues can be stored for a period of five years, according to the norms of Anvisa (Brazilian National Sanitary Surveillance Agency) and AATB (American Association of Tissue Banks).

ETHICAL AND LEGAL CONSIDERATIONS

In Brazil, the Ministry of Health formally recognized the existence of musculoskeletal tissue banks by means of an ordinance in August 2000, and from then onwards, started to regulate the way in which they functioned. Certain specific matters were defined, such as the need for an experienced individual to take technical responsibility for the activities, appropriate donor selection and minimum requirements for storage and processing.

It is mandatory to obtain consent from living donors, or from the close relatives in the case of cadaver donors, for tissue harvesting to be carried out. Authorization to harvest tissue implies obtaining data on previous medical histories and lifestyle habits, which are fundamental for donor selection.

Complementary examinations on the tissue are not, on their own, enough for their release for surgical use: there needs to be a compilation of several items. Tissue transplantation, regardless of the method used for selection and processing, is not free from the risks of disease transmission, and patients need to be notified about this and sign an informed consent statement.

After the rules for how bone banks could function in Brazil had been defined, surgical practices in this country changed. There were substantial risks in using conventional freezers, which mostly were not under adequate supervision by a physician with responsibility for this and were subject to problems regarding donor identification, power failures and lack of adequate technical control for the equipment. After the emergence of AIDS, the need for greater control led to the establishment of structures tissue banks with permanent work teams and technicians with training in the different phases of harvesting, selection, storage, processing and distribution of musculoskeletal tissues.

One issue that has given rise to polemic is whether payment for the use of human tissues should be made. Like other institutions connected with transplantation, musculoskeletal tissue banks are mandatorily of non-profit nature and only the costs relating to the different stages of the process are passed on. With cultural evolution, both the number of donations and the use of musculoskeletal tissue in surgical procedures have increased. A situation of equilibrium may be reached, including with coverage of costs by public and private payment sources, to extend the benefits of the tissue bank to the largest number of people possible⁽⁹⁾.

APPLICATIONS WITHIN ORTHOPEDICS

In a general manner, the use of tissues from musculoskeletal tissue banks has increased significantly within orthopedics over recent years. There are several reasons for this: 1) impossibility of obtaining large quantities of autologous bone; 2) morbidity at the graft harvesting site; 3) increased numbers of revision procedures on hip and knee arthroplasties; and 4) development of new surgical techniques that depend on homologous bone⁽¹⁰⁾.

The use of such tissues is widespread in the various specialties of orthopedics. In traumatology, for example, with the progressive increase in the numbers of cases of high-energy injuries and the growing rates of segmental bone loss and pseudarthrosis, the use of homologous bone has become more frequent.

Increased life expectancy and indications for arthroplasty in ever-younger patients have meant that the numbers of surgical procedures for placement of hip and knee prostheses and consequently the numbers of revision procedures have increased greatly over recent decades. In these surgical procedures, patients often present bone losses due to different etiologies (infection, osteolysis, aseptic loosening, etc), and replacement of the bone stock may both provide a better short and long-term result and facilitate possible subsequent revision, if this becomes necessary^(9,11-14) (Figures 4A, 4B and 4C).

In cases of resection of bone segments because of malignant tumors, one of the options is to use massive homologous grafts for limb reconstruction⁽¹⁵⁾. Arthrodesis, including spinal arthrodesis, is a surgical procedure in which the volume of grafting material needed fre-

quently leads to the use of homologous bone^(1,2,16).

In pediatric orthopedics, the use of tissue from a bank is of particular interest, because the possibility of using autologous grafts is smaller, particularly at very young ages. The operations in which bone tissue is frequently used include correction of scoliosis, arthrodesis on the foot and treatment for congenital pseudarthrosis, among others.

In sports medicine, treatments for young and active patients have favored the use of biological material in techniques such as transplantation of menisci. There is growing use of transplanted tissues, with an increasing range of applications. The use of tendon grafts in reconstructions on the anterior cruciate ligament of the knee is well established in the medical literature and is a routine procedure in some hospital services^(10,17-19) (Figures 5A, 5B and 5C).

A range of surgical techniques has been described in different areas of orthopedics, in all subspecialties, and not just the ones cited here, and many new techniques will be created and used routinely in surgical practice in the future. The conditions required for this, which in fact overlap, are that the number of tissue donors should increase and training in the various techniques for using musculoskeletal tissues should be provided for surgeons.

PERSPECTIVES

Despite the great potential, Brazil still has a much lower rate of use of bone grafts than seen in developed countries. This is due mainly to three factors: lack of awareness among the population regarding the pos-

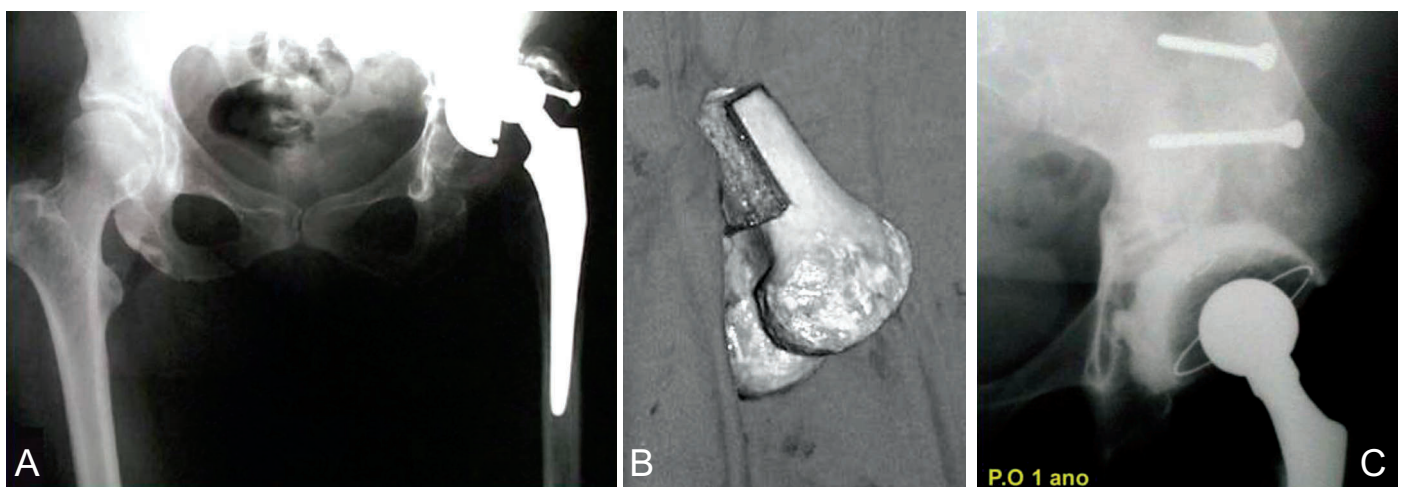


Figure 4 – Revision arthroplasty on the hip. A) Loosening of acetabular component with large bone failure. B) Homologous graft from distal femur, made into “7” shape. C) Late postoperative period, following acetabular reconstruction, showing evident consolidation of the graft.

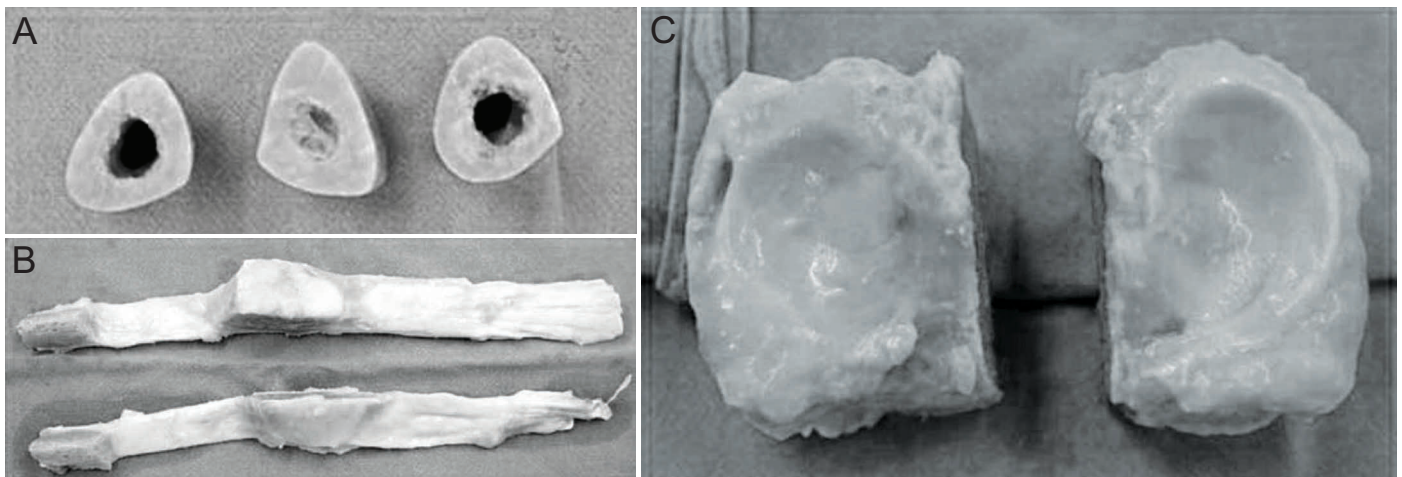


Figure 5 – Types of graft. A) Cortical “rings”, which can be used to fill wedges in osteotomy cases. B) Patellar and quadriceps tendons, for multi-ligament reconstruction. C) Osteochondral graft from the proximal tibia, for post-traumatic or post-tumor reconstructions.

sibility of donating musculoskeletal tissue, which is being overcome through a variety of campaigns and through a multidisciplinary approach towards families after the death; the lack of experience among surgeons regarding the possibilities for using homologous grafts and unfamiliarity with the surgical techniques, which is being attenuated through increasing training of specialists and greater access to tissue banks; and, primarily, bureaucratic obstacles imposed by the Ministry of Health, thereby making it difficult for surgeons and healthcare establishments to gain authorization for the use of grafts.

The veritable “dry law” that is affecting some orthopedics services has given rise to a search for other surgical solutions for the lack of human tissue for reconstructions. Through this, other methods have been disseminated, with the use of other bone substitutes, which generally have a higher cost and doubtful efficiency. It is hoped that more surgical teams – not just within orthopedics but also within other specialties – will mobilize to overcome the barriers of registration with the Ministry of Health; or that changes in the ordinances in question will make the use of musculoskeletal tissues more widespread in the near future.

REFERENCES

- Whang PG, Wang JC. Bone graft substitutes for spinal fusion. *Spine J.* 2003;3(2):155-65.
- Vaccaro AR, Chiba K, Heller JG, Patel TCh, Thalgot JS, Truumees E, et al. Bone grafting alternatives in spinal surgery. *Spine J.* 2002;2(3):206-15.
- Albrektsson T, Johanson C. Osteoinduction, osteoconduction and osseointegration. *Eur Spine J.* 2001;10(1):96-101.
- Bauer TW, Muschler GF. Bone graft materials. An overview of the basic science. *Clin Orthop Relat Res.* 2000;(371):10-27.
- Tomford WW. Transmission of disease through transplantation of musculoskeletal allografts. *J Bone Joint Surg Am.* 1995;77(11):1742-54.
- Asada N, Tsuchiya H, Kitaoka K, Mori Y, Tomita K. Massive autoclaved allografts and autografts for limb salvage surgery. A 1-8 year follow-up of 23 patients. *Acta Orthop Scand.* 1997;68(4):392-5.
- Thorén K, Aspenberg P. Ethylene oxide sterilization impairs allograft incorporation in a conduction chamber. *Clin Orthop Relat Res.* 1995;(318):259-64.
- Forsell JH. Irradiation of musculoskeletal tissues In: Tomford WW. *Musculoskeletal tissue banking.* New York: Raven Press; 1993. p.149-80.
- Villar RN. Tissue banking. In: Villar RN, Gross AE, McMinn D, editors. *Revision hip arthroplasty. A practical approach to bone stock loss.* Oxford: Butterworth Heineman; 1997. p. 26-32.
- Alencar PG. Revisão em artroplastia total de quadril. *Banco de ossos. Clínica Ortopédica.* 2001;2(4):1173-88.
- Paprosky W, Laurence J, Cameron H. Femoral defect classification: clinical application. *Orthop Rev.* 1990;19(Suppl 9):9.
- Slooff TJ, Schimmel JW, Buma P. Cemented fixation with bone grafts. *Orthop Clin North Am.* 1993 ;24(4):667-77.
- Gie GA, Linder L, Ling RS, Simon JP, Slooff TJ, Timperley AJ. Impacted cancellous allografts and cement for revision total hip arthroplasty. *J Bone Joint Surg Br.* 1993;75(1):14-21.
- Gross AE, Lavoie MV, McDermott P, Marks P. The use of allograft bone in revision of total hip arthroplasty. *Clin Orthop Relat Res.* 1985;(197):115-22.
- Matejovsky Z Jr, Matejovsky Z, Kofranek I. Massive allografts in tumour surgery. *Int Orthop.* 2006;30(6):478-83.
- Berven S, Tay BK, Kleinstueck FS, Bradford DS. Clinical applications of bone graft substitutes in spine surgery: consideration of mineralized and demineralized preparations and growth factor supplementation. *Eur Spine J.* 2001;10(Suppl 2):S169-77.
- Mc Guire DA, Hendricks D. Allografts in sports medicine. *Oper Tech Sports Med.* 2007;15(1):46-52.
- Tom JA, Rodeo SA. Soft tissue allografts for knee reconstruction in sports medicine. *Clin Orthop Relat Res.* 2002;(402):135-56.
- Willian DB. Fresh osteochondral allografting. *Oper Tech Sports Med.* 2000;8(2):158-62.